

Brief Report

Cite this article: Nabeshima T, Sato S, and Nakayashiro M (2019) Elimination of arrhythmogenesis after subtotal resection of congenital cardiac fibroma: a case report. *Cardiology in the Young* 29: 701–703. doi: [10.1017/S1047951119000180](https://doi.org/10.1017/S1047951119000180)

Received: 28 May 2018

Revised: 27 July 2018

Accepted: 5 September 2018

First published online: 17 May 2019

Keywords:

Ventricular arrhythmia; congenital cardiac fibroma; subtotal tumour resection

Author for correspondence:

Taisuke Nabeshima, MD, Fukuoka Children's Hospital, 5-1-1 Kashiiteriha, Higashi-ku, Fukuoka 813-0017, Japan. Tel: +81 92-682-7000; Fax: +81 92-682-7300; Email: nabeshima.t@fcho.jp

Elimination of arrhythmogenesis after subtotal resection of congenital cardiac fibroma: a case report

Taisuke Nabeshima^{1,2}, Seiichi Sato¹ and Mami Nakayashiro¹

¹Department of Pediatric Cardiology, Okinawa Nambu and Children's Medical Center, Okinawa, Japan and

²Department of Pediatric Cardiology, Fukuoka Children's Hospital, Fukuoka, Japan

Abstract

Subtotal tumour resection is used to treat infants with congenital cardiac fibroma and medication-resistant ventricular arrhythmias; however, complete elimination of arrhythmogenic substrates has been unclear. A 4-month-old male infant with congenital cardiac fibroma and ventricular fibrillation underwent subtotal tumour resection and implantable cardioverter-defibrillator implantation. Five years later, angiography revealed impending compression of the left coronary artery. Elimination of the arrhythmogenic substrate was confirmed and the device was removed successfully.

Congenital cardiac fibroma is the second most common benign primary cardiac tumour in children after rhabdomyoma.¹ Some patients are asymptomatic but others are prone to drug-resistant ventricular arrhythmia from infancy, which is often life-threatening.¹ In such cases, subtotal tumour resection is performed for two reasons. First, total resection is frequently difficult to achieve due to the relatively thin ventricular wall and indeterminate tumour border. Second, mid-term surgical outcomes appear optimal.^{2,3} However, no electrophysiological data have shown that subtotal resection can solely prevent further ventricular arrhythmia. Herein, we report a case of congenital cardiac fibroma in an infant treated with partial resection and implantable cardioverter-defibrillator implantation. The infant did not experience cardiovascular events since the surgery, except one episode of inappropriate shock. However, impending compression of the left coronary artery by the coil lead was suspected in coronary angiography findings later in the clinical course. We performed an electrophysiological study 5 years postoperatively and confirmed complete elimination of the arrhythmogenic substrate.

Case report

A 4-month-old male infant suspected with a large cardiac fibroma was admitted to our emergency department due to ventricular fibrillation and aborted cardiac death. His past medical history was not significant except failure to thrive. An echocardiography and contrast CT scan revealed a large cardiac tumour (35 × 28 mm) originating from the left ventricular inferior wall (Fig 1a). He was closely observed at our outpatient clinic and was admitted after several episodes of ventricular fibrillation and resuscitation at 4 months of age. Medical treatment, including maximal amiodarone and propranolol doses, were ineffective, and he underwent subtotal tumour resection and implantable cardioverter-defibrillator (Fortify Assura ICD™, St. Jude Medical, St Paul, Minnesota, USA) implantation via a pericardial approach at 19 months of age. We decided to place the device because he had experienced six episodes of ventricular fibrillation, and there was no consensus as to whether partial resection alone is sufficient to prevent further events. Intraoperatively, a coil lead was placed through the transverse pericardial sinus and sewn to the posterior pericardial wall (Fig 1b). Biopsy indicated that the tumour was a cardiac fibroma.

The patient experienced one episode of inappropriate shock due to sinus tachycardia 1 month after implantation, but no other cardiac events occurred. Antiarrhythmic medications were discontinued 2 years postoperatively. A follow-up coronary angiography performed 5 years postoperatively showed that the left circumflex artery was compressed by the shock lead (Fig 2). Although there were no signs or symptoms of acute coronary syndrome, impending compression of the coronary artery by the coil lead was suspected. The lead was thought to be pulled down as his thoraces grew longitudinally. Electrophysiology studies were performed to evaluate the possibility of device removal. A strict right ventricular stimulation program under isoproterenol infusion did not elicit ventricular tachycardia, and a thorough investigation of the left ventricular endocardium revealed neither late potential nor fractionated potential. He underwent removal of the implantable cardioverter-defibrillator and leads at 7 years of

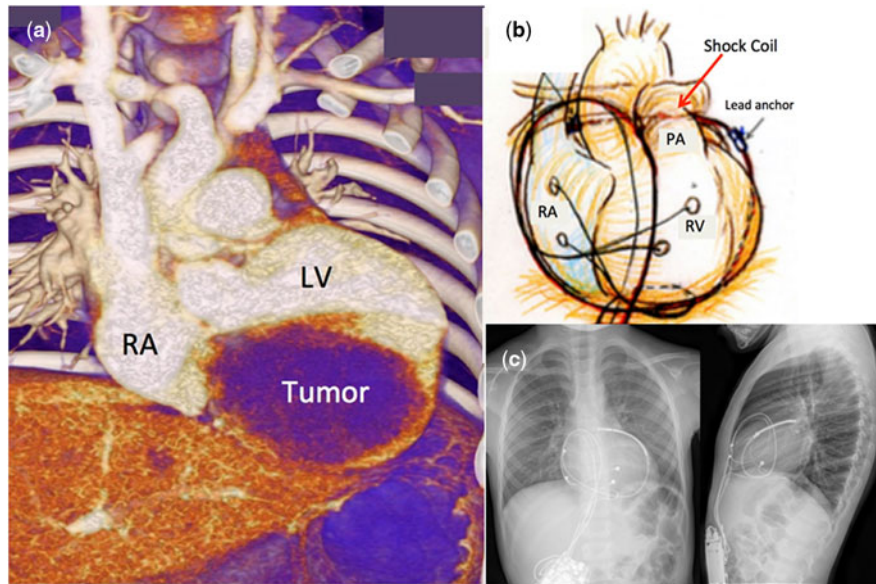


Figure 1. (a) Contrast CT scan (3D-reconstructed) showing the tumour originating from the left ventricular inferior wall. (b) A coil lead was placed through the transverse pericardial sinus and sewn to the posterior pericardial wall. (c) Post-operative chest X-ray (second-direction).

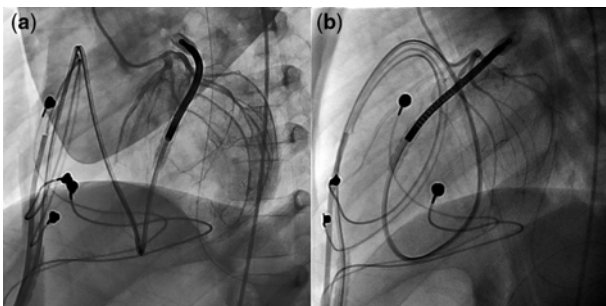


Figure 2. Left anterior oblique view (a) and lateral view (b) of left coronary angiography showing the left circumflex artery compressed by a coil lead.

age without complications. There was no postoperative change in electrocardiogram findings and he has been asymptomatic after the operation.

Discussion

The present case provides two clinical messages. First, the subtotal tumour resection can solely eliminate arrhythmogenic substrates. Second, the implantable cardioverter-defibrillator leads, particularly coil leads implanted via a pericardial approach in infants, may cause complications later during childhood.

1. The efficacy of subtotal tumour resection

It is well known that mid-term outcomes of subtotal tumour resection are optimal.^{2,3} Miyake et al. reported that 16 out of 25 patients with congenital cardiac fibroma with ventricular tachycardia who underwent total or subtotal resection had no major complications.³ They reported a lack of clinically significant arrhythmias in all the cases over a mean follow-up of 6 years. Additionally, they reported seven recent cases (including non-fibroma cases) of electrophysiology studies with negative ventricular stimulation. Subsequent clinical questions involve the

location of the arrhythmogenic substrate (inside or outside the tumour), its electroanatomical character, and its elimination via surgery.

Recently, Sakamoto et al. reported that intraoperative electroanatomical mapping of the epicardium can reveal a fractionated potential or late diastolic potential, which are considered ventricular arrhythmia substrates.⁴ They reported potentials recorded near the border between tumours and normal tissue. A plausible cause is normal myocardial tension, and debulking may be sufficient to prevent further recurrence of fatal ventricular arrhythmia even if a residual tumour exists.

Our case supports the above possibility. Clinically evident cardiovascular events never relapsed in our case after subtotal tumour resection, and there was no evidence of even subclinical ventricular arrhythmias. Further, electrophysiology studies, including ventricular stimulation, and thorough investigation of the left ventricular endocardium proved the elimination of the arrhythmogenic substrate.

Tissue hypoxia and mechano-electrical coupling may explain how a focal passive stretch of myocardium generates arrhythmogenesis at the cellular and molecular level. Stretched cardiac myocytes may be exposed to relatively scarce oxygen supply because of stretching of nearby microvasculature. The other possibility is mechano-electrical coupling. According to Orini et al., acute mechanical stress activates specific channels allowing various cations (including calcium) to cross the cell membrane, causing action potential shortening and diastolic depolarization that may lead to ventricular arrhythmias.⁵

2. Adverse effects of implantable cardioverter-defibrillator implantation

Among various surgical techniques for implantable cardioverter-defibrillator implantation in children and infants, pericardial approach is a widely accepted method in which a coil lead is placed through the transverse sinus under fluoroscopic guidance.⁶ Late complications, including lead fracture, buckling leads, constrictive pericarditis, and potential risk of cardiac strangulation,

must be considered.⁶ In our case, a coil lead was pulled down with increase in the patient's height and was found to be on the verge of coronary artery compromise.

Such complications may not be prevented until subcutaneous implantable cardioverter-defibrillators can be used in infants. Clinicians must be aware of the risks of placing leads in growing children and repeatedly assess complications via CT scan or other methods.

In conclusion, subtotal tumour resection can eliminate arrhythmogenic substrates whereas implantable cardioverter-defibrillator leads, particularly coil leads implanted via a pericardial approach in infants, can cause complications later during childhood. Avoiding device implantation in such patients may be an option, but further investigation is warranted.

Supplementary Material. To view supplementary material for this article, please visit <https://doi.org/10.1017/S1047951119000180>.

Financial Support. The authors received no specific grant from any funding agency, commercial, or not-for-profit sectors.

Conflicts of Interest. None.

Ethical Standards. The authors assert that this report complies with the ethical standards of the Helsinki convention, and consent for this publication has been granted by the patient's family.

References

1. Marx GR, Moran AM. Cardiac tumors. In: Allen HD, Driscoll DJ, Shaddy RE, Feltes TF. (eds) *Moss & Adams Heart Disease in Infants, Children, and Adolescents: Including the Fetus and Young Adult*, 8th edn. Lippincott Williams & Wilkins, Philadelphia, 2013: pp. 1549–1555.
2. Padalino MA, Vida VL, Boccuzzo G, et al. Surgery for primary cardiac tumors in children: early and late results in a multicenter European Congenital Heart Surgeons Association study. *Circulation* 2012; 126: 22–30.
3. Miyake CY, Del Nido PJ, Alexander ME, et al. Cardiac tumors and associated arrhythmias in pediatric patients, with observations on surgical therapy for ventricular tachycardia. *J Am Coll Cardiol* 2011; 58: 1903–1909.
4. Sakamoto S, Shibata M, Murata H, et al. Intraoperative cardiac mapping in the treatment of an infant congenital fibroma. *Ann Thorac Surg* 2015; 99: 1064–1066.
5. Orini M, Nanda A, Yates M, et al. Mechano-electric feedback in the clinical setting: current perspectives. *Prog Biophys Mol Biol* 2017; 130: 365–375.
6. Suzuki S, Motohashi S, Matsumoto M, et al. Surgical techniques for implanting implantable cardioverter defibrillators in children and infants. *Surg Today* 2014; 44: 1801–1806.