

Malpractice issues in modern anaesthesiology

doi:10.1017/S0265021508003591

EDITOR:

Malpractice issues in anaesthesiology remain a continued concern for practicing anaesthesiologists. The review by Mavroforou and colleagues [1] is both timely and comprehensive and will undoubtedly assist many anaesthesiologists when they attempt to provide full and informed consent to patients before their operations.

We were particularly interested in the views of Mavroforou and colleagues [1] on perioperative nerve injuries. Of particular interest is that this complication is one of the most commonly occurring, shows no sign of decrease in frequency and often occurs despite significant efforts to avoid it.

We have previously described a patient [2] who suffered such a complication, but on further testing was found to suffer from the genetically inherited condition 'hereditary neuropathy with liability to pressure palsies' (HNPP). This syndrome was first described by de Jong in 1947 [3] and is characterized by monofocal nerve palsies occurring at anatomically vulnerable sites such as the wrist, elbow or lower leg. Despite this being a relatively common abnormality (occurring at about 16 per 100 000), this is the first patient described in the anaesthetic literature. Diagnosis is first suggested by nerve conduction studies and later by molecular genetic analysis.

Correspondence to: Lara Wijayasiri, Department of Anaesthesia, Frimley Park Hospital, Porstmouth Road, Frimley, Surrey GU16 7UJ, UK. E-mail: l_wijayasiri@yahoo.co.uk; Tel: +1276 604161; Fax: +1276 604606

Accepted for publication 31 December 2007 EJA 4888
First published online 5 February 2008

At that time we highlighted the possibility that some patients who develop nerve palsies after an operation may in fact have HNPP. We suggested that along with other predisposing causes of postoperative neuropathy, such as alcoholism and diabetes, a diagnosis of HNPP should also be excluded.

We believe that if clinicians start to examine other potential causes of postoperative nerve injury, in particular to exclude HNPP as a precipitating factor, the incidence of claims made against anaesthesiologists may at last start to reduce.

N. Quiney

Department of Anaesthesia
Royal Surrey County Hospital
Guildford, UK

L. Wijayasiri

Department of Anaesthesia
Frimley Park Hospital
Frimley, Surrey, UK

References

1. Mavroforou A, Stamatiou G, Koutsias S, Michalodimitrakis E, Vretzakis G, Giannoukas AD. Malpractice issues in modern anaesthesiology. *Eur J Anaesthesiol* 2007; 24: 903–911.
2. Wijayasiri L, Batas D, Quiney N. Hereditary neuropathy with liability to pressure palsies and anaesthesia: perioperative nerve injury. *Anaesthesia* 2006; 61: 1004–1006.
3. Stogbauer F, Young P, Kuhlenbaumer G, De Jonghe P, Timmerman V. Hereditary recurrent focal neuropathies: clinical and molecular features. *Neurology* 2000; 54: 546–551.

Endotracheal tube obstruction secondary to oral medication

doi:10.1017/S0265021508003608

EDITOR:

Numerous instances of tracheal tube obstruction have been reported as a result of blood clot or dried secretions [1], endotracheal tube compression or

kinking [2], or cuff displacement [3]. Likewise, tracheal tube obstruction with foreign bodies has been reported including chewing gum [4,5], a piece of a carbon dioxide sampling tube [6] and plastic caps off prefilled syringes [7]. In this case we report an endotracheal tube obstruction due to oral medication.

Case report

An 84-yr-old female with a long-standing history of obesity, hypertension and non-insulin-dependent

Correspondence to: Miguel Angel Palomero Rodríguez, Servicio de, Anestesiología y Reanimación, Hospital Universitario de Salamanca, Paseo de San Vicente, 58-182,37007 Salamanca, Spain. E-mail: mapalomero@gmail.com; Tel: +34 92329353; Fax: +34 923 291131

Accepted for publication 31 December 2007 EJA 4877
First published online 8 February 2008

diabetes mellitus was admitted to the hospital for a vitrectomy under general anaesthesia. She gave no history of difficulty in swallowing or of any neurologic disorder. Medications included oral furosemide and metformin twice a day. At 8.00a.m. on the day of surgery, furosemide and metformin tablets were administered orally with a small sip of water. The patient arrived in the operating room at 8.45a.m. and an intravenous cannula was inserted. After monitoring, the patient was preoxygenated and anaesthesia was induced with fentanyl 200 µg, propofol 150 mg and succinylcholine 80 mg, and laryngoscopy was attempted. Visualization of the larynx was described as Grade 3, according to the Cormack and Lehane classification, and intubation was performed at the second attempt with a 7 mm armoured endotracheal tube (Safety Flex; Mallinckrodt Medical, Athlone, Ireland). After intubation, attempts to ventilate the patient encountered a high airway resistance with virtually no air entry on auscultation of the chest. There was neither chest movement nor carbon dioxide on capnography. The difficulty in ventilation was assumed to be due to equipment malfunction, but after 30 s, desaturation occurred and we decided to withdraw the endotracheal tube and proceed with mask ventilation. After removal of the tube, a foreign body plug was noted, virtually occluding the distal end of the tube (Fig. 1). Intubation was subsequently performed with another 7 mm armoured endotracheal tube and anaesthesia continued without any further incident. After examination of the object and referring to the patient's chart, we were able to identify the foreign body as a metformin tablet.

Discussion

After reviewing the medical literature we have found only one case of endotracheal tube obstruction secondary to oral preoperative medication [8]. In our case report, the signs of endotracheal tube obstruction were demonstrated by the difficulty in ventilating, the absence of carbon dioxide and the rapid desaturation. The causes of obstruction must be distinguished from other causes of difficult ventilation such as endobronchial mucous plugs or blood clots, bronchospasm, tension pneumothorax, massive aspiration, chest wall rigidity and equipment malfunction. When ventilation is impossible, a quick differential diagnosis needs to be performed. Visual inspection of the tube, fibre-optic visualization of the airway, mask ventilation and reintubation must be considered when airway obstruction occurs after intubation. An attempt to pass a suction catheter down the tube may differentiate between

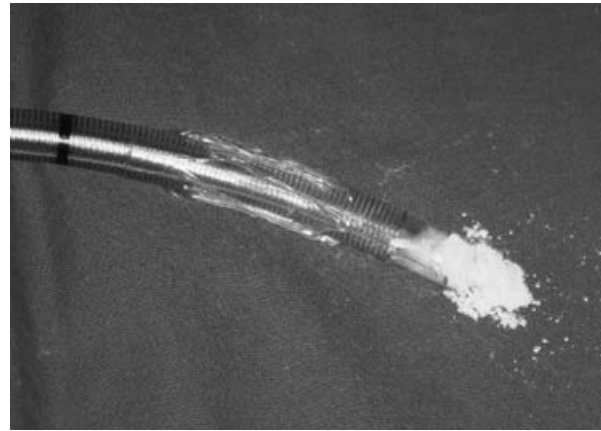


Figure 1.
Metformin tablet virtually occluding the distal end of the tube.

an endotracheal tube obstruction and other causes of increased inspiratory pressure. Reintubation will be the appropriate next step to establish a patent airway. Prompt recognition of endotracheal tube obstruction and appropriate actions are essential to prevent morbidity and mortality.

M. A. Palomero Rodríguez, M. P. Sánchez Conde
J. M. Rodríguez López, F. Hernández
J. Portillo Casado, C. Muriel-Villoria
Department of Anaesthesiology
University Hospital of Salamanca
Salamanca, Spain

References

1. Kemmotsu O. Six cases of endotracheal tube obstructions. *Jpn J Anesthesiol* 1971; 20: 259–264.
2. Leissner KB, Ortega R, Bodzin AS, Sekhar P, Stanley GD. Kinking of an endotracheal tube within the trachea: a rare cause of endotracheal tube obstruction. *J Clin Anesth* 2007; 19: 75–81.
3. Blanc VF, Tremblay NAG. The complications of tracheal intubation: a new classification with a review of the literature. *Anesth Analg* 1974; 53: 202–213.
4. Shlamovitz GZ, Helpert P. Delayed obstruction of endotracheal tubes by aspirated foreign bodies: report of two cases. *Ann Emerg Med* 2004; 43: 630–633.
5. Bevacqua BK, Cleary WF. An unusual case of endotracheal tube cuff dysfunction. *J Clin Anaesth* 1993; 5: 237–239.
6. Szekely SM, Webb RK, Williamson JA, Russell WJ. Problems related to the endotracheal tube: an analysis of 2000 incident reports. *Anaesth Intensive Care* 1993; 21: 611–616.
7. Menon R. An unusual case of tracheal tube obstruction. *Anaesthesia* 2001; 56: 690–713.
8. Ehrenpreis MB, Oliverio M. Endotracheal tube obstruction secondary to oral preoperative medication. *Anesth Analg* 1984: 867–868.