

Larval development of *Angiostrongylus chabaudi*, the causative agent of feline angiostrongylosis, in the snail *Cornu aspersum*

V. COLELLA¹, M. A. CAVALERA¹, G. DEAK², V. D. TARALLO¹, C. M. GHERMAN², A. D. MIHALCA² and D. OTRANTO^{1*}

¹ *Dipartimento di Medicina Veterinaria, Università degli Studi di Bari, Str. prov. per Casamassima km 3, 70010 Valenzano (Bari), Italy*

² *Department of Parasitology and Parasitic Diseases, University of Agricultural Sciences and Veterinary Medicine of Cluj-Napoca, Calea Mănăştur 3-5, 400372 Cluj-Napoca, Romania*

(Received 12 April 2017; revised 8 July 2017; accepted 8 July 2017; first published online 14 August 2017)

SUMMARY

Nematodes of the Angiostrongylidae family, such as *Angiostrongylus vasorum* and *Angiostrongylus cantonensis*, may cause potentially life-threatening diseases in several mammal species. Alongside these well-known species, *Angiostrongylus chabaudi* has been recently found affecting the cardiopulmonary system of domestic and wild cats from Italy, Germany, Greece, Romania and Bulgaria. Nonetheless, significant gaps in the understanding of *A. chabaudi* epidemiology include the lack of information of species acting as intermediate host and of the morphological description of larval stages. *Cornu aspersum* ($n = 30$) land snails were infected with 100 first-stage larvae of *A. chabaudi* collected from a naturally infected wildcat in Romania. Larvae at different developmental stages were found in 29 out of 30 (96.7%) infected snails and a total of 282 (mean 9.8 ± 3.02 larvae per each specimen) were collected from the gastropods. Here we demonstrate that *A. chabaudi* develops in snails and report *C. aspersum* as potential intermediate host for this parasitic nematode. Findings of this study are central to understand the ecological features of feline angiostrongylosis and its epidemiology within paratenic and intermediate hosts.

Key words: feline, cardiopulmonary nematode, lungworms, intermediate host, snails, *Cornu aspersum*.

INTRODUCTION

The long evolutionary history of mollusc parasitism resulted in more than a hundred known nematode species associated to snails and slugs, which act as definitive and intermediate hosts for rhabditids and metastrongyloids, respectively (Grewal *et al.* 2003). The main transmission pathway of metastrongyloids to mammals is represented by the ingestion of gastropod intermediate hosts, with some instances of exception of nematodes (e.g. *Oslerus osleri*) in the family Angiostrongylidae and Filaroididae (Anderson, 2000). However, in the majority of the cases, juvenile first-stage larvae (L1) of metastrongyloids develop into third-stage larvae (L3) in the molluscan tissues (Anderson, 2000). After the infection of proper vertebrate hosts, migrating larvae, adult nematodes and the newborn L1 can produce different degrees of pathogenic outcomes with reported life-threatening conditions (Spratt, 2015). For instance, the zoonotic rat metastrongyloids *Angiostrongylus cantonensis* and *Angiostrongylus costaricensis* cause thousands of cases of eosinophilic meningitis and abdominal angiostrongylosis in humans, respectively (Wang *et al.*

2012; Romero-Alegria *et al.* 2014). Additionally, *A. cantonensis* has been indicated as an agent of neurological disorders in dogs, lemurs and non-human primates and birds (Duffy *et al.* 2004; Lunn *et al.* 2012; Burns *et al.* 2014; Kim *et al.* 2014; Spratt *et al.* 2015). Likewise, *A. costaricensis* may use dogs as alternative definitive hosts to rats (Alfaro-Alarcón *et al.* 2015). Research in feline lungworms has intensified in the last years due to the increased awareness on this group of parasites. Whilst *Aelurostrongylus abstrusus* has been considered for ages the only metastrongyloid lungworm of cats, an additional species, *Troglostrongylus brevior*, has been found with increasing prevalence in domestic and wild cat populations (Brianti *et al.* 2014; Falsone *et al.* 2014). *Troglostrongylus brevior* was firstly reported from wild cats in Palestine (Gerichter, 1949) and after six decades, in domestic cats both from Spain (Jefferies *et al.* 2010) and Italy (Brianti *et al.* 2012, 2014). In few years, *T. brevior* has been reported in animals from Italy, Greece, Bulgaria, Spain and Bosnia and Herzegovina (Alić *et al.* 2015; Diakou *et al.* 2015; Giannelli *et al.* 2017) clearly indicating a wider distribution than that initially assumed.

In the same years, another species of metastrongyloid, namely *Angiostrongylus chabaudi*, has been found affecting the cardiopulmonary system of a domestic cat in insular Italy (Varcasia *et al.* 2014).

* Corresponding author: Dipartimento di Medicina Veterinaria, Università degli Studi di Bari, Str. prov. per Casamassima km 3, 70010 Valenzano (Bari), Italy. E-mail: domenico.otranto@uniba.it

Firstly reported six decades ago (Biocca, 1957), this nematode was found parasitizing the heart and lungs of 86% of a wildcat population from central Italy. Later on, *A. chabaudi* has been diagnosed at post-mortem examination of domestic cats from Italy (Varcasia *et al.* 2014; Traversa *et al.* 2015) and wildcats from Germany, Greece, Romania, Italy and Bulgaria (Steeb *et al.* 2014; Diakou *et al.* 2016; Gherman *et al.* 2016; Giannelli *et al.* 2016; Veronesi *et al.* 2016). Nonetheless, most of the aspects of the biological life cycle of this parasite (e.g. intermediate host and morphology of larval stages) are unknown, impairing the design of epidemiological investigations and the identification of control strategies. Therefore, the aim of this study was to determine the potential intermediate host in the life cycle of *A. chabaudi* and to describe the associated developmental larval stages.

MATERIALS AND METHODS

Larval collection

A fresh male road-killed wildcat was found in Bobâlna (Cluj County, Romania; 47.148855°N, 23.640511°E). At necropsy, adult *A. chabaudi* were found in the pulmonary arteries and identified morphologically according to morphological keys (Gherman *et al.* 2016) and molecularly (see below). No other pulmonary or vascular nematodes were found. Further, the cardiopulmonary system was dissected to perform a Baermann examination at the Department of Parasitology and Parasitic Diseases, University of Agricultural Sciences and Veterinary Medicine of Cluj-Napoca (Romania). Tissues were cut in small pieces and placed in a double-layer gauze, secured with a wire and settled into Baermann funnels, filled with 50 mL warm tap water and examined after 24 h. The sediment was poured into a tube and centrifuged at 600 *g* for 3 min, and the supernatant was discarded. The sediment was placed on a microscope slide for examination under light microscopy (Leica®, DM LB2, Wetzlar, Germany) and larvae isolated and stored in saline solution. The material was sent to the Parasitology Laboratory of the University of Bari (Apulia, Italy), for additional processing. L1 were morphologically identified as *A. chabaudi* according to their morphology (Gherman *et al.* 2016) and further molecularly characterized (see below).

Maintenance and infection of gastropods

Sixty land snails *Cornu aspersum* were purchased from a farming centre located in Barletta (Puglia, Italy). The snails were housed in a plastic box at controlled room temperature (21 ± 2 °C) and fed every other day with lettuce and water. In order to exclude the presence of helminth infections, 10

randomly selected snails were digested (see below for procedures) and microscopically examined on the arrival and 1 day prior to the experimental infection.

Gastropods (*n* = 30) were infected with single infective doses of about 100 L1 obtained by centrifugation at 600 *g* for 3 min of the Baermann sediments and collected under a light microscope (Leica®, DM LB2, Wetzlar, Germany). *Cornu aspersum* snails were individually placed in the infection chamber consisting of six-well cell culture plate (Corning®; CellBIND®; Sigma-Aldrich®) containing a potato slice (0.3 cm thick) with the infective dose on its surface, and left in the infection chambers for 24 h.

The potential suitability of the gastropod *C. aspersum* as intermediate host of *A. chabaudi* was assessed by artificial digestion of five snails at 3, 6, 10, 15, 20 and 30 days post-infection (dpi).

Each snail was digested in a solution of 100 mL HCl (pH 2.2) and 3 mg mL⁻¹ of powder pepsin (≥250 units mg⁻¹, P700-100G Sigma-Aldrich®, St. Louis, Missouri, USA). The suspension was heated on a magnetic stirrer at 37 ± 2 °C for 90 min, shifted through a 250 µm sieve to remove undigested material, transferred to 50 mL plastic tubes and centrifuged at 600 *g* for 5 min. At each dpi, the suspension obtained from the gastropod digestion was microscopically examined and larval stages identified according to previous descriptions of metastrongyloid larval stages (Gerichter, 1949; Ash, 1970). The nematodes were preserved in 70% ethanol, subsequently cleared and examined as temporary mounts in glycerol. Drawings were made with a compound microscope Leica DM LB2 (with differential interference contrast) and a drawing tube. Digital images and measurements were taken using Leica LAS® AF 4.1 software. Metrical data are given as the range, with the mean in parentheses.

Molecular identification

Single L1 (*n* = 10), L2 and L3 suspended in two pools (10 specimens each) were isolated using a 10 µL micropipette, washed and stored in phosphate buffer saline solution for molecular analysis. Genomic DNA was extracted using a commercial kit (DNeasy Blood & Tissue Kit, Qiagen, GmbH, Hilden, Germany), in accordance with the manufacturer's instructions, and a partial fragment of the ribosomal internal transcribed spacer-2 (ITS2) gene was amplified as previously described (Gasser *et al.* 1993). The amplicons were purified and sequenced, in both directions using the same primers as for PCR, employing the Taq Dye Deoxy Terminator Cycle Sequencing Kit (v.2, Applied Biosystems) in an automated sequencer (ABI-PRISM 377). Sequences were aligned using the Geneious R9 software package (<http://www.geneious.com>) and

Table 1. Number and developmental stages of *Angiostrongylus chabaudi* larvae collected from five experimentally infected snails at 3 (T1), 6 (T2), 10 (T3), 15 (T4), 20 (T5) and 30 (T6) days post-infection

	First-stage larvae	Second-stage larvae	Third-stage larvae	Total
T1	62 (12.4 ± 2.30)	–	–	62 (12.4 ± 2.30)
T2	21 (4.2 ± 1.6)	41 (8.2 ± 1.8)	–	62 (12.4 ± 2.6)
T3	17 (3.4 ± 2.1)	24 (4.8 ± 1.9)	2 (0.4 ± 0.5)	43 (8.6 ± 3)
T4	3 (0.6 ± 1.3)	19 (3.8 ± 1.9)	2 (0.4 ± 0.5)	24 (4.8 ± 2.6)
T5	–	24 (4.8 ± 3.5)	14 (2.8 ± 1.9)	38 (7.6 ± 4.6)
T6	–	20 (4 ± 1.6)	35 (7 ± 3.4)	55 (11 ± 1.9)

In brackets mean number of larval stages per snail and standard deviation (S.D.).

compared (BLASTn) with those available in the GeneBank database (<http://blast.ncbi.nlm.nih.gov/Blast.cgi>).

RESULTS

Development of A. chabaudi in gastropods

Specimens of *C. aspersum* digested on the arrival ($n = 5$) and 1 day prior to the infection ($n = 5$) were negative for helminths. Larval stages of *A. chabaudi* were found in 29 out of 30 (96.7%) experimentally infected snails. Number and developmental stages of larvae detected from experimentally infected snails are shown in Table 1.

A total of 284 larvae (mean 9.8 ± 3.02 larvae per each specimen) were collected from the gastropods. L2 and L3 were detected at 6 and 10 dpi, respectively (Table 1, Fig. 1). L1 were not detected after 15 dpi, whereas L3 were increasingly detected from 10 dpi until the end of the observational period (i.e. 30 dpi, Fig. 1).

Morphological characteristics of larval stages

Main measurements of L1 and L3 of *A. chabaudi* are given in micrometres (μm) and are summarized in Table 2. Morphological characteristics of L1, L2 and L3 are outlined in Fig. 2. The main features of L1 and L3 of *A. chabaudi* herein described have been compared with those of other feline lungworms (i.e. *A. abstrusus* and *T. brevior*) or members of Angiostrongylidae family (i.e. *Angiostrongylus vasorum* and *A. cantonensis*; Table 3).

First-stage larvae

First-stage larvae collected from the wildcat measured 352.7–390 (368.2 ± 13.5) in length and 14.3–16.4 (15.6 ± 0.7) in width (Figs 2A and 3A). The tail was 20.3–32.4 (24.7 ± 4.4) in length, featured by a typical L1 kinked *Angiostrongylus* morphology with a subterminal dorsal spine separated by a moderately wide and distinct notch (Fig. 3B). The tail had a small ventral indentation, which followed to a slightly short sigmoid ending (Fig. 3B). The

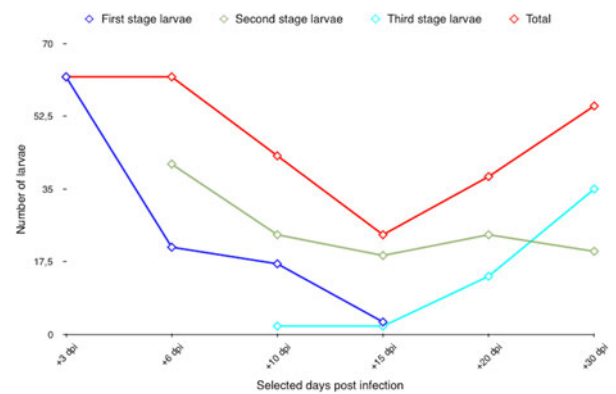


Fig. 1. Dynamics of *Angiostrongylus chabaudi* larval development in *Cornu aspersum* snails.

shape of the tail was fairly constant in all L1 examined. The anterior extremity was blunted with a terminal buccal opening (3C). The oesophagus was 154.1–177.4 (163.9 ± 6.6) in length and it was divided by a muscular procorpus (Fig. 3C) followed by a metacarpus ending with a gradually widening bulb (Fig. 2A). Nerve ring was situated at 62.8–90.1 (77.9 ± 8.5) from the anterior extremity (Fig. 2A). Excretory pore was noticeable in few specimens and situated slightly posterior to the nerve ring. Genital primordium was small and oval in shape and situated at 118.7–136.7 (124.7 ± 5.7) from the posterior extremity (Fig. 2A). The ratio of the oesophagus length to body length was 0.437–0.454 (0.445). The ratio of the distance from posterior extremity to the genital primordium to body length was 0.336–0.350 (0.343).

Second-stage larvae

Second-stage larvae collected from experimentally infected snails were coiled C-shaped and featured by numerous granules (Figs 2B and 4A). Larvae measured 434.6–514 (470.3 ± 28.6) in length and 32.5–47.2 (36.9 ± 4.5) in width. Some L2 were encased in the cuticle of the L1 and the space between the cuticle of L2 and the sheath of L1 provided an empty-like appearance at both extremities (Fig. 4B). The oesophagus was 151.9–191.8 (174.6

Table 2. Measurements (in micrometres) of first- (L1) and third-stage (L3) larvae ($n = 10$ each) of *Angiostrongylus chabaudi*

Measurements	L1	L3
Body length	352.7–390 (368.2 ± 13.5)	580.2–709.7 (618.4 ± 38.4)
Maximum body width	14.3–16.4 (15.6 ± 0.7)	28.1–42.7 (33.7 ± 5.1)
Tail length	20.3–32.4 (24.7 ± 4.4)	27.2–46.9 (38.9 ± 6)
Oesophagus length	154.1–177.4 (163.9 ± 6.6)	213–277.2 (242.2 ± 29.8)
Genital primordium, distance from posterior extremity	118.7–136.7 (124.7 ± 5.7)	180.6–221.6 (196.4 ± 13.1)
Nerve ring, distance from anterior extremity	62.8–90.1 (77.9 ± 8.5)	75.5–102 (90.8 ± 11.3)
Excretory pore, distance from anterior extremity	–	83.9–119 (98.8 ± 15)
Ratio oesophagus length to body length	0.437–0.454	0.367–0.390
Ratio distance from posterior extremity to genital primordium to body length	0.336–0.350	0.311–0.312

In brackets, mean and s.d. are given.

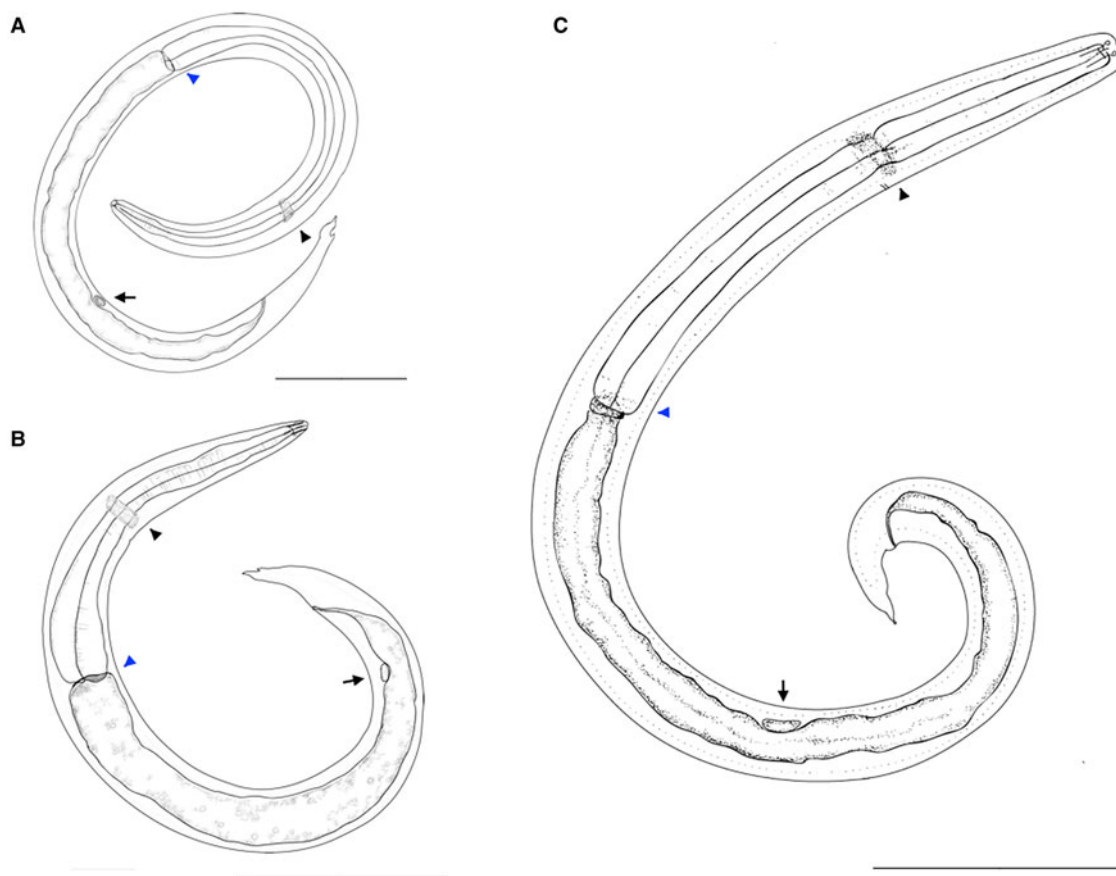


Fig. 2. Drawings of *Angiostrongylus chabaudi*. First-stage larva (A), scale bar 50 μm ; second-stage larva (B), scale bar 100 μm ; third-stage larva (C), scale bar 100 μm . Note the nerve ring (black arrowhead), oesophago-intestinal junction (blue arrowhead) and genital primordium (arrow).

± 13.2) in length and the metacarpus filled by numerous granules (Figs 2B and 4C). The anterior extremity was narrowed with a button-like extremity of circa 3.5 in length and 5 in width (Figs 2B and 4D). The anus was well evident, the tail was 34.4–49.2 (40.4 ± 5.9) in length and resembled that of the previous stage with a less wide notch (Fig. 4D). The genital primordium was 152.8–175.3 (164.5 ± 8.5) distant from the posterior extremity (Fig. 2B). The ratio of the oesophagus

length to the body length was 0.349–0.373 (0.371). The ratio of the distance from the posterior extremity to the genital primordium to body length was 0.341–0.351 (0.35).

Third-stage larvae

Third-stage larvae (Fig. 2C) were retrieved either enclosed in the cuticle (Fig. 5A and B) of the previous moulting or without the external sheaths

Table 3. Main measurements in μm of first- and third-stage larvae of *Angiostrongylus chabaudi*, *Aelurostrongylus abstrusus*, *Troglostrongylus brevior*, *Angiostrongylus vasorum* and *Angiostrongylus cantonensis*

Larval stage	Measurements	<i>A. chabaudi</i>	<i>A. abstrusus</i>	<i>T. brevior</i>	<i>A. vasorum</i>	<i>A. cantonensis</i>	Reference
First-stage larvae	Body length	307–419	210–495	203–382	310–380	230–290	Rosen <i>et al.</i> (1970); Gherman <i>et al.</i> (2016); Giannelli <i>et al.</i> (2014, 2017)
	Maximum body width	14–16	15–20	14–17	14–16	13–16	
	Oesophagus length	154–177	–	–	130–170	110–130	
	Tail length	20–32	40	33–42	30–34	23–30	
Third-stage larvae	Body length	580–710	480–591	417–450	508–610	425–524	Gerichter, (1949); Ash, (1970); Giannelli <i>et al.</i> (2014)
	Maximum body width	28–43	26–34	19–22	28–34	23–34	
	Oesophagus length	213–277	194–221	121–145	180–210	170–180	
	Tail length	27–47	34–44	30–38	35–41	39–41	

(Fig. 6A). The slender body was ventrally curved and measured 580.2–709.7 (618.4 ± 38.4) in length and 28.1–42.7 (33.7 ± 5.1) in width (Fig. 6A). The anterior end was blunt with a distinct buccal cavity featured by two knob-like structures followed by well-developed chitinous rods of circa 6–12 in length (Fig. 6B). The excretory pore was present at 83.9–119 (98.8 ± 15) slightly posterior to the nerve ring, which was at 75.5–102 (90.8 ± 11.3) from the anterior extremity (Fig. 2C). The claviform oesophagus measured 213–277.2 (242.2 ± 29.8) in length, divided in a well-distinct muscular procorpus of circa 28–38 in length followed by a granular metacarpus gradually widening in a terminal bulb (Figs 2C and 6C). The cuticle displayed slight transverse striations more evident in proximity of the middle of the body and the tail (Fig. 6D). The tail was ventrally bent, 27.2–46.9 (38.9 ± 6) in length, with a tiny dorsal subterminal indentation and a ventral notch followed by a small knob-like structure (Fig. 6E and F). The genital primordium was present at 180.6–221.6 (196.4 ± 13.1) from the posterior extremity (Figs 2C and 6D). The ratio of the oesophagus length to the body length was 0.367–0.390. The ratio of the distance from the posterior extremity to the genital primordium to body length was 0.311–0.312.

Molecular identification

The ITS2 sequences obtained from L1 of the wildcat and L1, L2 and L3 collected after the digestion of experimentally infected snails displayed 100% identity to the nucleotide sequence of *A. chabaudi* available in GenBank (accession no. KM979214).

DISCUSSION

Data presented indicate that *A. chabaudi* develops in gastropods with the land snail *C. aspersum* as the first recorded intermediate host species under laboratory condition. *Cornu aspersum* is native of Mediterranean regions, and it is one of the most globally widespread snail species (Guiller *et al.* 2012). This gastropod species has already been identified as intermediate host of other metastrongyloids affecting felids (e.g. *A. abstrusus* and *T. brevior*; Giannelli *et al.* 2014) and canids (e.g. *Crenosoma vulpis*; Colella *et al.* 2016). *Cornu aspersum* may be, therefore, a source of multiple infections of feline lungworms for cats in both urban and rural areas, and may represent a model to assess the epidemiology of snail-borne nematodes.

In the experimental infection with *A. chabaudi*, all but one *C. aspersum* harboured different developmental larval stages. The failure of the single snail to be infected by *A. chabaudi* might be due, *inter alia*, to snail immune responsiveness. Immunological reactions against larval stages of feline and canine lungworms have been demonstrated through the formation of gastropod-

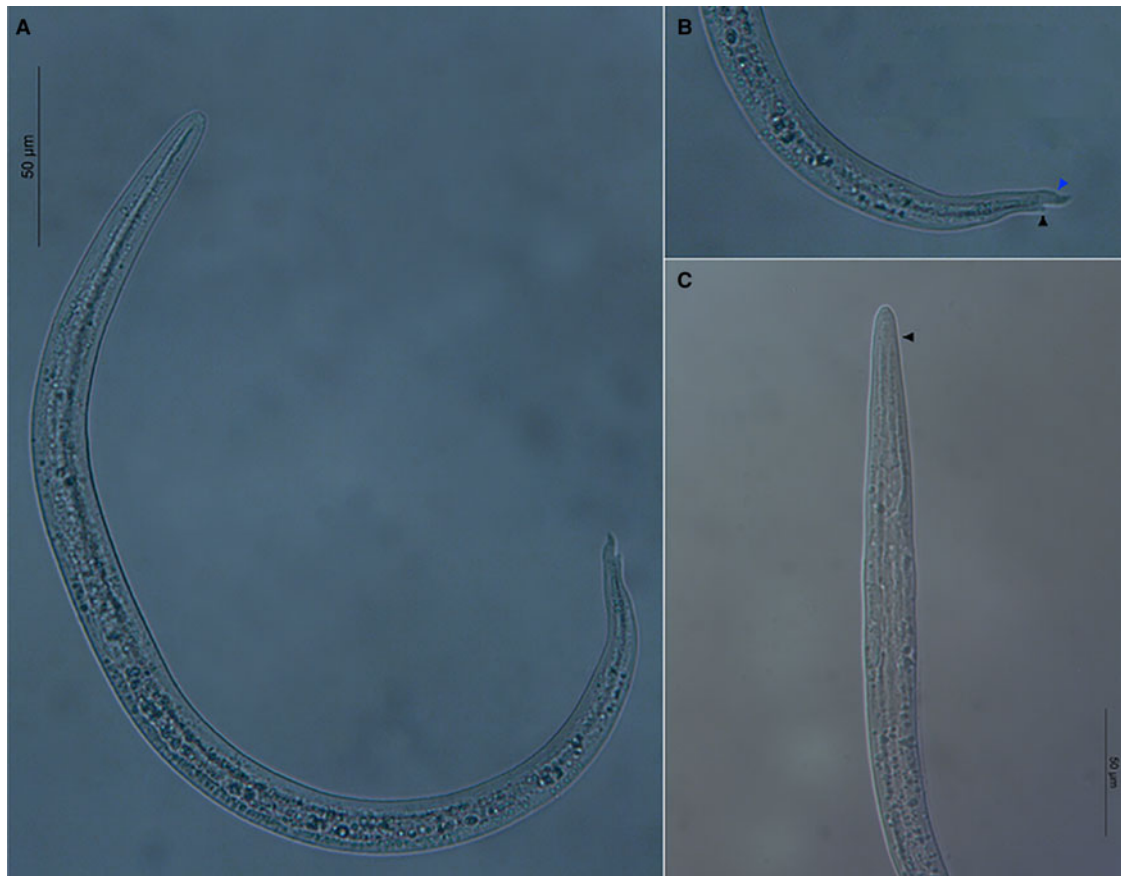


Fig. 3. First-stage larva of *Angiostrongylus chabaudi* with body ventrally curved (A). Note the kinked tail with a subterminal dorsal spine (black arrowhead) separated by a notch and a short sigmoid ending (blue arrowhead) (B). Blunted anterior extremity with a terminal buccal opening (C). Note the oesophagus muscular procorpus (arrowhead).

derived invertebrate extracellular phagocyte traps (Lange *et al.* 2017).

Availability of this experimental model allowed us to describe the infective stages for the definitive feline hosts; nonetheless, a definitive proof of infectivity of L3 herein described can be achieved by inducing a patent infection in a definitive host. Though different measurements of larval stages may be potentially recorded in other species of intermediate or definitive hosts, the mean length of L1 and L3 of *A. chabaudi* herein described falls within the ranges of other feline lungworms (i.e. *A. abstrusus* and *T. brevior*) or members of Angiostrongylidae family (i.e. *A. vasorum* and *A. cantonensis*; Table 3). L3 possess similar morphology to the above mentioned nematodes making the species discrimination ambiguous. For example, the terminal knob-like ending of L3 of *A. chabaudi* is less pronounced than in *A. abstrusus*. For diagnostics in definitive hosts, L1 of *A. chabaudi* share similar morphology of the tail and measurements of main morphological features overlap with those of closely related metastrongyloids. For non-experts, the appreciation of morphological features of larvae from feline (Deak *et al.* 2017) and gastropod hosts could be difficult. Hence, when performing epidemiological surveys in definitive, paratenic and

intermediate hosts, molecular analyses are also required.

Studies focusing on the intermediate hosts will improve current understanding of the snail-borne diseases. The microhabitat is central for the development of the lungworm life cycles and may explain the patchy distribution of snail-borne nematodes among close areas, as demonstrated for *A. vasorum* (Morgan *et al.* 2009). The recognition of *A. chabaudi* as a parasite of wild and domestic cats is a recent finding and should be followed by more in-depth prevalence studies in geographical areas where other lungworms are identified. The occurrence of *A. chabaudi* in a wildcat population from Romania updates information on the distribution of this parasite with unknown consequences to domestic cats. Indeed, metastrongyloids do not display a very high intermediate or definitive host specificity, and hypothesis of lungworms confined to wildcats (Traversa *et al.* 2015) is unlikely. The lack of a tight association of metastrongyloids to one definitive host species is further embodied by the rat lungworm *A. costaricensis*, which can occasionally use dogs as definitive hosts (Alfaro-Alarcón *et al.* 2015). Additionally, though dogs and wild canids, such as foxes, wolves, coyotes and jackals, are the main definitive hosts for

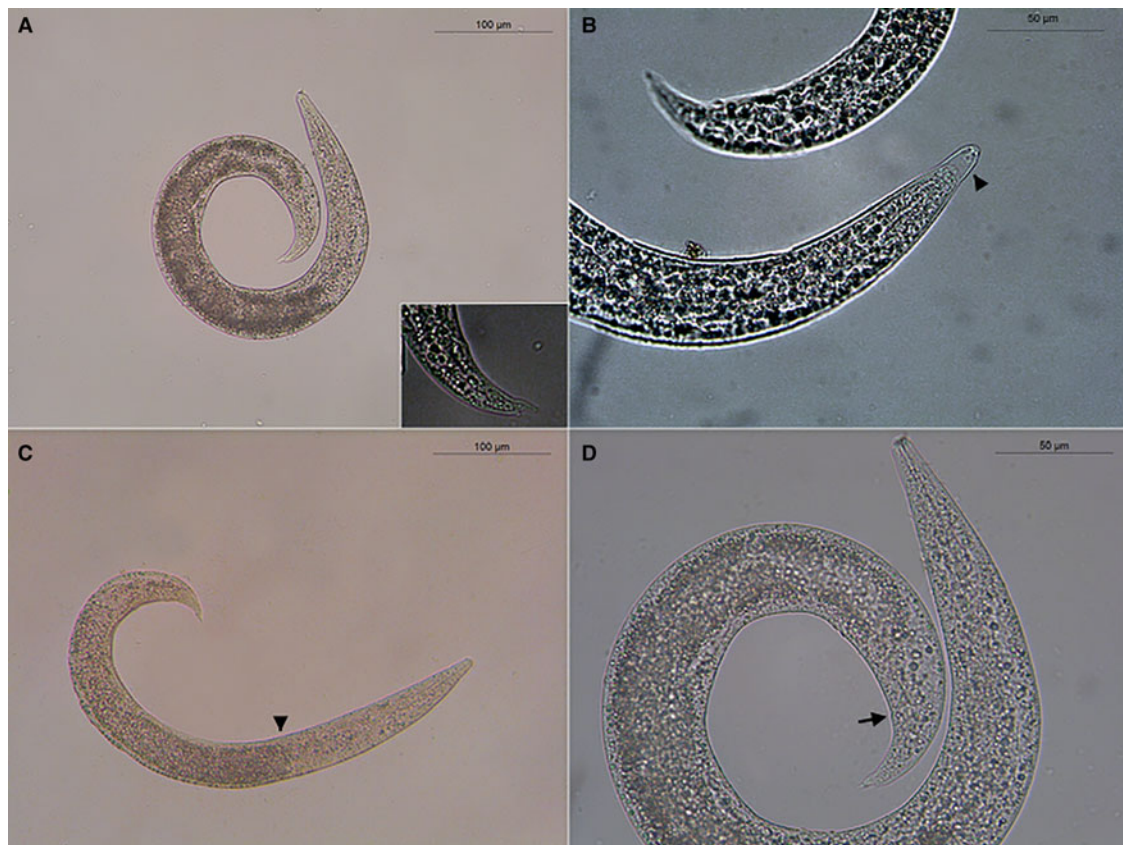


Fig. 4. Coiled C-shaped second-stage larva of *Angiostrongylus chabaudi* (A). Magnification of the tail (insert A); L2 encased in the cuticle of the L1 (arrowhead) (B); oesophago-intestinal junction (arrowhead) (C); well-evident anus (arrow) (D).

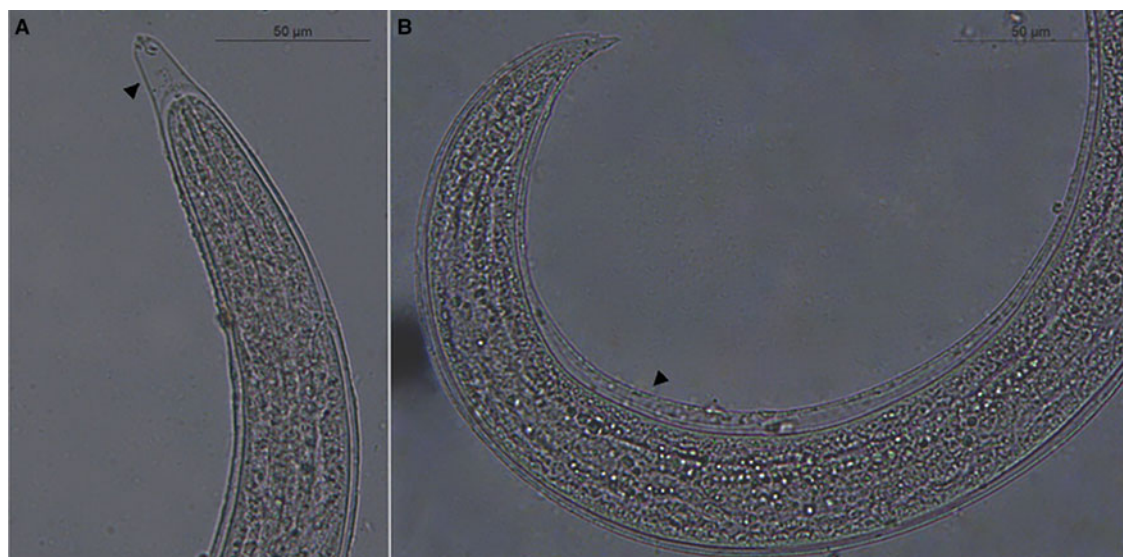


Fig. 5. Anterior (A) and posterior (B) extremities of a third-stage larva of *Angiostrongylus chabaudi* enclosed in the sheaths (arrowhead) of the previous moults.

A. vasorum (Morgan and Shaw, 2010; Elsheikha *et al.* 2014), patent infections have been described in animals belonging to the family Mustelidae (e.g. the Eurasian badger and otters; Madsen *et al.* 1999; Torres *et al.* 2001) and Ailuridae (i.e. the

red panda; Grøndahl *et al.* 2005; Patterson-Kane *et al.* 2009).

Likely, risk factors, such as living outdoors and/or the higher frequency in hunting behaviour, result in an increased chance of wildlife rather than domestic

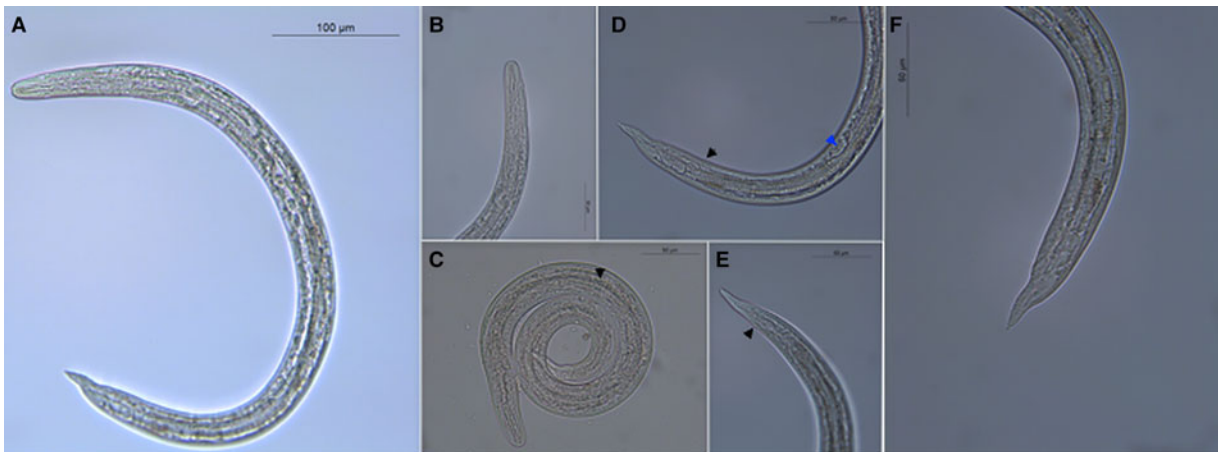


Fig. 6. Slender body of the third-stage larva of *Angiostrongylus chabaudi* (A); blunt anterior end with a distinct buccal cavity (B); claviform oesophagus widening in a terminal bulb (arrowhead) (C); slight transverse striations of the cuticle (black arrowhead) and genital primordium (blue arrowhead) (D); detail of the anus (arrowhead) (E); ventrally bent tail featured by a small knob-like structure (F).

animals to acquire parasitic infections (Otranto *et al.* 2015). The finding of co-infected domestic cats by *A. abstrusus*, *T. brevior* and *A. chabaudi* (Traversa *et al.* 2015) supports the existence of complementary transmission patterns for the complex of feline lungworms sharing the definitive (domestic and wildcats) and intermediate hosts (e.g. the snail *C. aspersum*).

Wildcats likely act as reservoir hosts of lungworms in given areas (e.g. *T. brevior*, Falsone *et al.* 2014), implying the existence of angiostrongylosis by *A. chabaudi* in domestic cats. Findings of this study fill significant gaps in the understanding of key morphogenetic and ecological features of feline angiostrongylosis by *A. chabaudi*. Indeed, the first report of snails as intermediate hosts together with the in-depth description of morphological characteristics of L1, L2 and L3 will support the design of epidemiological surveys in gastropods and feline definitive hosts, and the identification of control strategies of *A. chabaudi*. Future investigations will contribute to understand the actual distribution of this parasite and whether domestic cats can sustain the lifecycle of *A. chabaudi* in the absence of the wildlife counterpart.

ACKNOWLEDGEMENT

Authors thank Jan Šlapeta (University of Sydney) for critically reviewing the manuscript.

FINANCIAL SUPPORT

This research received no specific grant from any funding agency, commercial or not-for-profit sectors.

REFERENCES

Alfaro-Alarcón, A., Veneziano, V., Galiero, G., Cerrone, A., Gutiérrez, N., Chinchilla, A., Annoscia, G., Colella, V., Dantas-Torres, F., Otranto, D. and Santoro, M. (2015). First report of a naturally patent infection of *Angiostrongylus costaricensis* in a dog. *Veterinary Parasitology* **212**, 431–434.

Alić, A., Traversa, D., Duscher, G. G., Kadrić, M., Di Cesare, A. and Hodžić, A. (2015). *Troglostrongylus brevior* in an Eurasian lynx (*Lynx lynx*) from Bosnia and Herzegovina. *Parasites & Vectors* **8**, 653.

Anderson, R. C. (2000). The superfamily Metastrongyloidea. In *Nematode Parasites of Vertebrates. Their Development and Transmission* (ed. CAB International), pp. 163–164. CAB International, Wallingford, UK.

Ash, L. R. (1970). Diagnostic morphology of the third-stage larvae of *Angiostrongylus cantonensis*, *Angiostrongylus vasorum*, *Aelurostrongylus abstrusus*, and *Anafilaroides rostratus* (Nematoda: Metastrongyloidea). *Journal of Parasitology* **56**, 249–253.

Biocca, E. (1957). *Angiostrongylus chabaudi* n. sp. parassita del cuore e dei vasi polmonari del gatto selvatico (*Felis silvestris*). *Reale Accademia Nazionale Lincei* **22**, 526–532.

Brianti, E., Gaglio, G., Giannetto, S., Annoscia, G., Latrofa, M. S., Dantas-Torres, F., Traversa, D. and Otranto, D. (2012). *Troglostrongylus brevior* and *Troglostrongylus subcrenatus* (Strongylida: Crenosomatidae) as agents of broncho-pulmonary infestation in domestic cats. *Parasites & Vectors* **5**, 178.

Brianti, E., Giannetto, S., Dantas-Torres, F. and Otranto, D. (2014). Lungworms of the genus *Troglostrongylus* (Strongylida: Crenosomatidae): neglected parasites for domestic cats. *Veterinary Parasitology* **202**, 104–112.

Burns, R. E., Bicknese, E. J., Qvarnstrom, Y., DeLeon-Carnes, M., Drew, C. P., Gardiner, C. H. and Rideout, B. A. (2014). Cerebral *Angiostrongylus cantonensis* infection in a captive African pygmy falcon (*Polihierax semitorquatus*) in southern California. *Journal of Veterinary Diagnostic Investigation* **26**, 695–698.

Colella, V., Mutafchiev, Y., Cavalera, M. A., Giannelli, A., Lia, R. P., Dantas-Torres, F. and Otranto, D. (2016). Development of *Crenosoma vulpis* in the common garden snail *Cornu aspersum*: implications for epidemiological studies. *Parasites & Vectors* **9**, 208.

Deak, G., Gherman, C. M., Ionică, A. M., Daskalaki, A. A., Matei, I. A., D'Amico, G., Domşa, C., Pantchev, N., Mihalca, A. D. and Cozma, V. (2017). Use of a commercial serologic test for *Angiostrongylus vasorum* for the detection of *A. chabaudi* in wildcats and *A. daskalovi* in badgers. *Veterinary Parasitology* **233**, 107–110.

Diakou, A., Di Cesare, A., Barros, L. A., Morelli, S., Halos, L., Beugnet, F. and Traversa, D. (2015). Occurrence of *Aelurostrongylus abstrusus* and *Troglostrongylus brevior* in domestic cats in Greece. *Parasites & Vectors* **8**, 590.

Diakou, A., Psalla, D., Migli, D., Di Cesare, A., Youlatos, D., Marcer, F. and Traversa, D. (2016). First evidence of the European wildcat (*Felis silvestris silvestris*) as definitive host of *Angiostrongylus chabaudi*. *Parasitology Research* **115**, 1235–1244.

Duffy, M. S., Miller, C. L., Kinsella, J. M. and de Lahunta, A. (2004). *Parastrongylus cantonensis* in a nonhuman primate. Florida. *Emerging Infectious Diseases* **10**, 2207–2210.

Elsheikha, H. M., Holmes, S. A., Wright, I., Morgan, E. R. and Lacher, D. W. (2014). Recent advances in the epidemiology, clinical and diagnostic features, and control of canine cardio-pulmonary angiostrongylosis. *Veterinary Research* **45**, 92.

Falsone, L., Brianti, E., Gaglio, G., Napoli, E., Anile, S., Mallia, E., Giannelli, A., Poglayen, G., Giannetto, S. and Otranto, D. (2014).

- The European wildcats (*Felis silvestris silvestris*) as reservoir hosts of *Troglostrongylus brevior* (Strongylida: Crenosomatidae) lungworms. *Veterinary Parasitology* **205**, 193–198.
- Gasser, R. B., Chilton, N. B., Hoste, H. and Beveridge, I. (1993). Rapid sequencing of rDNA from single worms and eggs of parasitic helminths. *Nucleic Acids Research* **21**, 2525–2526.
- Gerichter, C. B. (1949). Studies on the nematodes parasitic in the lungs of Felidae in Palestine. *Parasitology* **39**, 251–262.
- Gherman, C. M., Ionică, A. M., D'Amico, G., Otranto, D. and Mihalca, A. D. (2016). *Angiostrongylus chabaudi* (Biocca, 1957) in wildcat (*Felis silvestris silvestris*, S) from Romania. *Parasitology Research* **115**, 2511–2517.
- Giannelli, A., Ramos, R. A., Annoscia, G., Di Cesare, A., Colella, V., Brianti, E., Dantas-Torres, F., Mutafchiev, Y. and Otranto, D. (2014). Development of the feline lungworms *Aelurostrongylus abstrusus* and *Troglostrongylus brevior* in *Helix aspersa* snails. *Parasitology* **141**, 563–569.
- Giannelli, A., Kirkova, Z., Abramo, F., Latrofa, M. S., Campbell, B., Zizzo, N., Cantacessi, C., Dantas-Torres, F. and Otranto, D. (2016). *Angiostrongylus chabaudi* in felids: new findings and a review of the literature. *Veterinary Parasitology* **228**, 188–192.
- Giannelli, A., Capelli, G., Hinney, B., Joachim, A., Losson, B., Kirkova, Z., Martellet, M. R., Papadopoulos, E., Farkas, R., Brianti, E., Tamponi, C., Varcasia, A., Alho, A. M., Madeira de Carvalho, L., Cardoso, L., Maia, C., Mircean, V., Mihalca, A. D., Mirò, G., Schnyder, M., Cantacessi, C., Colella, V., Cavallera, M. A., Latrofa, M. S., Annoscia, G., Halos, L., Knaus, M., Beugnet, F. and Otranto, D. (2017). Epidemiology, diagnosis and treatment of lungworm and gastrointestinal parasitic infections in cats: an European perspective. *International Journal for Parasitology*, pii: S0020-7519(17)30101-7. doi: 10.1016/j.ijpara.2017.02.003.
- Grewal, P. S., Grewal, S. K., Tan, L. and Adams, B. J. (2003). Parasitism of molluscs by nematodes: types of associations and evolutionary trends. *Journal of Nematology* **35**, 146–156.
- Grøndahl, C., Monrad, J., Dietz, H. H., Jensen, H. E., Johansen, M. V. and Kapel, C. (2005). Angiostrongylosis in red panda (*Ailurus fulgens fulgens*). *Proceedings of International Symposium of Disease in Zoo and Wild animals* **42**, 117–118.
- Guiller, A., Martin, M. C., Hiraux, C. and Madec, L. (2012). Tracing the invasion of the Mediterranean land snail *Cornu aspersum aspersum* becoming an agricultural and garden pest in areas recently introduced. *PLoS ONE* **7**, e49674.
- Jefferies, R., Vrhovec, M. G., Wallner, N. and Catalan, D. R. (2010). *Aelurostrongylus abstrusus* and *Troglostrongylus* sp. (Nematoda: Metastrongyloidea) infections in cats inhabiting Ibiza, Spain. *Veterinary Parasitology* **173**, 344–348.
- Kim, J. R., Hayes, K. A., Yeung, N. W. and Cowie, R. H. (2014). Diverse gastropod hosts of *Angiostrongylus cantonensis*, the rat lungworm, globally and with a focus on the Hawaiian Islands. *PLoS ONE* **9**, e94969.
- Lange, M. K., Penagos-Tabares, F., Muñoz-Caro, T., Gärtner, U., Mejer, H., Schaper, R., Hermosilla, C. and Taubert, A. (2017). Gastropod-derived haemocyte extracellular traps entrap metastrongyloid larval stages of *Angiostrongylus vasorum*, *Aelurostrongylus abstrusus* and *Troglostrongylus brevior*. *Parasites & Vectors* **10**, 50.
- Lunn, J. A., Lee, R., Smaller, J., Mackay, B. M., King, T., Hunt, G. B., Martin, P., Krockenberger, M. B., Spielman, D. and Malik, R. (2012). Twenty two cases of canine neural angiostrongylosis in eastern Australia (2002–2005) and a review of the literature. *Parasites & Vectors* **5**, 70–88.
- Madsen, A. B., Dietz, H. H., Henriksen, P. and Clausen, B. (1999). Survey of Danish free living Otters *Lutra lutra* – a consecutive collection and necropsy of dead bodies. *IUCN Otter Specialist Group Bulletin* **16**, 65–76.
- Morgan, E. R. and Shaw, S. E. (2010). *Angiostrongylus vasorum* infection in dogs: continuing spread and developments in diagnosis and treatment. *Journal of Small Animal Practice* **51**, 616–621.
- Morgan, E. R., Jefferies, R., Krajewski, M., Ward, P. and Shaw, S. E. (2009). Canine pulmonary angiostrongylosis: the influence of climate on parasite distribution. *Parasitology International* **58**, 406–410.
- Otranto, D., Cantacessi, C., Dantas-Torres, F., Brianti, E., Pfeiffer, M., Genchi, C., Guberti, V., Capelli, G. and Deplazes, P. (2015). The role of wild canids and felids in spreading parasites to dogs and cats in Europe. Part II: Helminths and arthropods. *Veterinary Parasitology* **213**, 24–37.
- Patterson-Kane, J. C., Gibbons, L. M., Jefferies, R., Morgan, E. R., Wenzlow, N. and Redrobe, S. P. (2009). Pneumonia from *Angiostrongylus vasorum* infection in a red panda (*Ailurus fulgens fulgens*). *Journal of Veterinary Diagnostic Investigation* **21**, 270–273.
- Romero-Alegria, A., Belhassen-García, M., Velasco-Tirado, V., Garcia-Mingo, A., Alvela-Suárez, L., Pardo-Lledias, J. and Sanchez, M. C. (2014). *Angiostrongylus costaricensis*: systematic review of case reports. *Advances in Infectious Diseases* **4**, 36–41.
- Rosen, L., Ash, L. R. and Wallace, G. D. (1970). Life history of the canine lungworm *Angiostrongylus vasorum*. *American Journal of Veterinary Research* **31**, 131–141.
- Spratt, D. M. (2015). Species of *Angiostrongylus* (Nematoda: Metastrongyloidea) in wildlife: A review. *International Journal for Parasitology: Parasites and Wildlife* **4**, 178–189.
- Steeb, S., Hirtzmann, J., Eskens, U., Volmer, K. and Bauer, C. (2014). Lungewurm-Infektionen bei der europäischen wildkatze. *KompaktVET* **3**, 9.
- Torres, J., Miquel, J. and Motjé, M. (2001). Helminth parasites of the Eurasian badger (*Meles meles* L.) in Spain: a biogeographic approach. *Parasitology Research* **87**, 259–263.
- Traversa, D., Lepri, E., Veronesi, F., Paoletti, B., Simonato, G., Diaferia, M. and Di Cesare, A. (2015). Metastrongyloid infection by *Aelurostrongylus abstrusus*, *Troglostrongylus brevior* and *Angiostrongylus chabaudi* in a domestic cat. *International Journal for Parasitology* **45**, 685–690.
- Varcasia, A., Tamponi, C., Brianti, E., Cabras, P. A., Boi, R., Pipia, A. P., Giannelli, A., Otranto, D. and Scala, A. (2014). *Angiostrongylus chabaudi* Biocca, 1957: a new parasite for domestic cats? *Parasites & Vectors* **7**, 588.
- Veronesi, F., Traversa, D., Lepri, E., Morganti, G., Vercillo, F., Grelli, D., Cassini, R., Marangi, M., Iorio, R., Ragni, B. and Di Cesare, A. (2016). Occurrence of lungworms in European wildcats (*Felis silvestris silvestris*) of central Italy. *Journal of Wildlife Diseases* **52**, 270–278.
- Wang, Q. P., Wu, Z. D., Wei, J., Owen, R. L. and Lun, Z. R. (2012). Human *Angiostrongylus cantonensis*: an update. *European Journal of Clinical Microbiology & Infectious Diseases* **31**, 389–395.