



Percutaneous self-expandable valve implantation in patients with stented pulmonary arteries: case examples

Brief Report

Cite this article: Szeliga J, Gewillig M, and Górczny S (2025) Percutaneous self-expandable valve implantation in patients with stented pulmonary arteries: case examples. *Cardiology in the Young* **35**: 208–211. doi: [10.1017/S1047951124036588](https://doi.org/10.1017/S1047951124036588)

Received: 7 August 2024
Revised: 23 November 2024
Accepted: 30 November 2024
First published online: 17 January 2025

Keywords:

tetralogy of Fallot; pulmonary regurgitation; pulmonary valve implantation; Venus-P valve; stents

Corresponding author:

Sebastian Górczny;
Email: sebastian.gorczy@uj.edu.pl

Judyta Szeliga¹ , Marc Gewillig² and Sebastian Górczny¹ 

¹Department of Paediatric Cardiology, University Children's Hospital, Jagiellonian University Medical College, Krakow, Poland and ²Department Pediatric Cardiology, University Hospitals Leuven, Leuven, Belgium

Abstract

CHDs affecting the right ventricular outflow tract often require repeated surgical or transcatheter interventions due to pulmonary insufficiency or stenosis. This study presents percutaneous implantation of large self-expanding valves in patients with complex right ventricular outflow tract anatomy after prior pulmonary branch stenting.

Introduction

CHDs involving right ventricular outflow tract dysfunction present challenges in treatment and long-term patient management. Although surgical interventions in infancy are often effective, many patients will require reoperation due to pulmonary insufficiency and/or stenosis. Transcatheter balloon-expanded valve implantation methods have gained recognition as an alternative to surgery.¹ However, a significant limitation of this approach is the width of the conduit-free patched right ventricular outflow tract. The introduction of large self-expanding valves has effectively addressed this limitation, offering new treatment possibilities.^{2–9} The complexity of CHDs, often involving hypoplastic pulmonary branches or non-standard pulmonary branch orifice/angles, along with operative anatomical modifications, may complicate pulmonary valve implantation.³ This article presents examples of large self-expanding valve implantation in paediatric patients with enlarged right ventricular outflow tract who had previously undergone pulmonary branch stenting.

Patient A

A 17-year-old patient (62 kg) was initially diagnosed with tetralogy of Fallot, right aortic arch, sub-valvular and valvular pulmonary stenosis, absent pulmonary artery confluence, and left pulmonary artery supplied by a patent ductus arteriosus originating from the left subclavian artery. Surgical patch repair and translocation of the left pulmonary artery to the pulmonary trunk were performed during the first year of life. Later, the patient underwent catheterisation twice with left pulmonary artery balloon angioplasty at the reimplantation site. At the age of 14, a Palmaz Genesis 2910 stent (Cordis) mounted on a 14 mm balloon was implanted into the narrowed proximal segment of the left pulmonary artery.

Due to worsening exercise tolerance, significant pulmonary regurgitation and narrowing in the proximal stented segment of the left pulmonary artery, the patient was referred for cardiac catheterisation. Progressive left pulmonary artery stent expansion and shortening was performed using Atlas balloons (22 and 24 mm), and right ventricular outflow tract balloon interrogation was carried out with a 40 mm PTS-X catheter (NuMed). The indentation on the proximal segment of the balloon measured 32 mm, in the middle section the diameter was 33.4 mm, and 31.5 mm at the distal main pulmonary artery (MPA). The favourable position and wide expansion of the initially implanted stent in the left pulmonary artery (Figure 1a; Supplementary video 1), as well as wide, patched right ventricular outflow tract, with significant contrast return into the enlarged right ventricle, justified the decision to consider the patient for a transcatheter self-expanding valve implantation. The short pulmonary trunk necessitated the selection of the largest and shortest Venus-P Valve (MedTech): 36–25 mm. An extra stiff guide wire (Lunderquist; Cook) was anchored in the right pulmonary artery, and a 26 Fr DrySeal sheath (Gore) was introduced into the right ventricular outflow tract (Figure 1b). Subsequently, the valve was advanced until the proximal segment of the right pulmonary artery, where the opening was initiated (Figure 1b). Gradual opening of the valve while allowing the distal flare to “fall” into the stent, aiming the distal marker (at the base of distal flare) to stay at the caudal end of the stent, allowed for proper valve positioning (Figure 1c,d). Control angiographies confirmed unobstructed contrast flow into both pulmonary branches with proper filling of the left branch through the wide distal flare of the valve (Figure 1e,f).

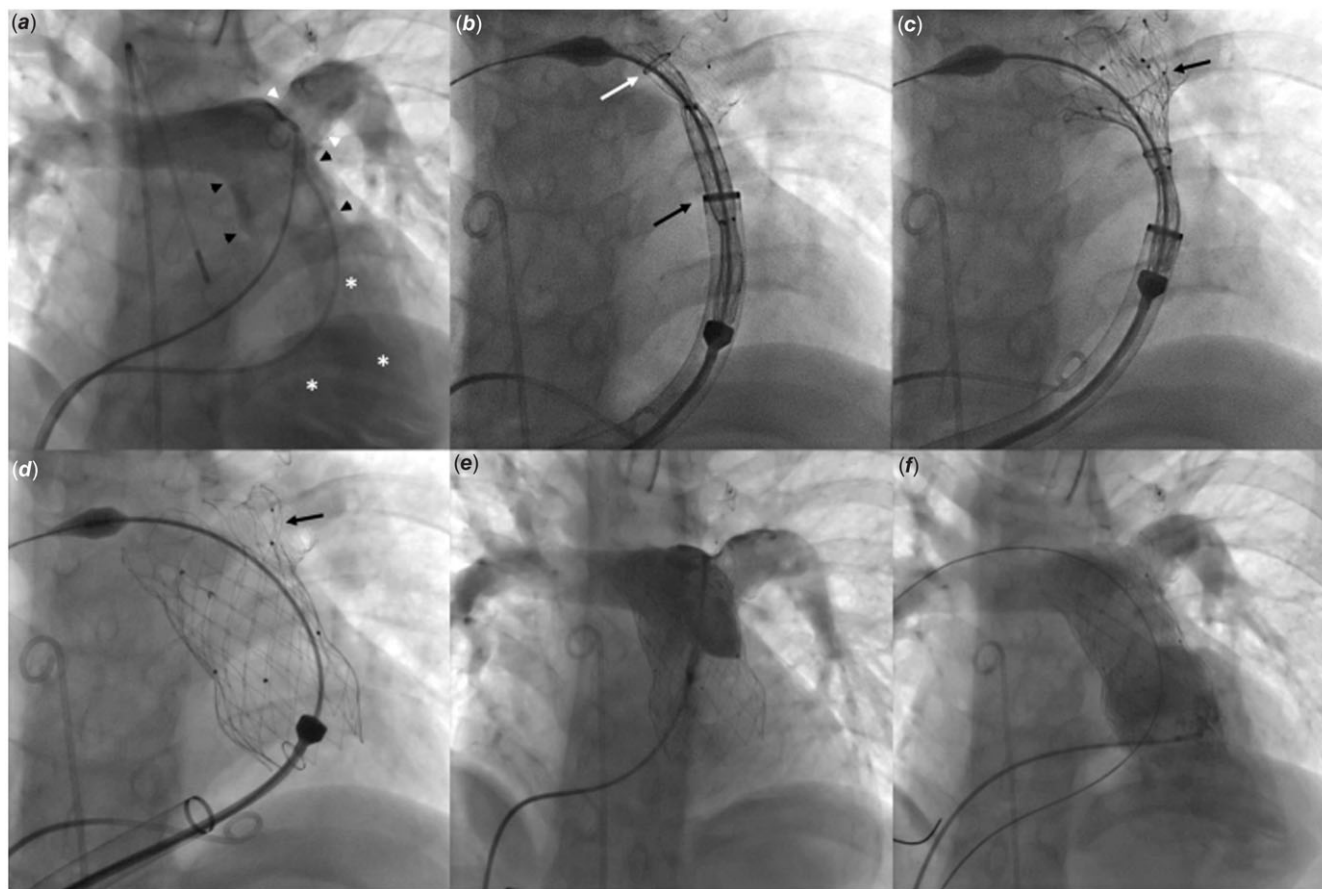


Figure 1. Percutaneous implantation of a self-expanding valve in patient with tetralogy of Fallot after surgical patch repair and stent implantation in the left pulmonary artery (LPA). (a) An initial angiography showed unobstructed pulmonary arteries with a wide stent (white arrowheads) in the LPA, short pulmonary trunk (black arrowheads) and significant retrograde contrast flow (asterisks) to the enlarged right ventricle. (b) Through a 26 Fr DrySeal sheath (Gore, black arrow) placed at the level of the native pulmonary valve, a 36 – 25 mm Venus P-Valve (MedTech) was introduced to the proximal right pulmonary artery. Opening of the distal flare was initiated at the level of the top edge of the stent in the LPA (white arrow). (c) With continuous pushing on the system the entire distal flare was gradually exposed to seat into the stent in the LPA. (d) After the entire valve was exposed the distal flare (black arrow) fit well in the stent. (e) Control angiography from the MPA showed unobstructed contrast flow to both pulmonary arteries with a trace of central regurgitation. (f) Control angiography from the right ventricle confirmed perfect position of the valve with even contrast flow to both pulmonary arteries.

The recovery was uneventful, and discharge echocardiography as well as the 6-month follow-up showed good function and trivial central regurgitation of the Venus-P valve.

Patient B

A 15-year-old patient (51 kg) underwent complete surgical correction for tetralogy of Fallot with a patch at 5 months of age, followed by right ventricular outflow tract aneurysmoplasty a month later. Subsequent years revealed stenosis of the right pulmonary artery leading to a 39 mm Cheatham Platinum stent (NuMed) implantation on an 18 mm BIB catheter (NuMed).

Worsening exercise intolerance, echocardiographic evidence of right ventricular enlargement, significant pulmonary regurgitation, and moderate tricuspid valve regurgitation prompted transcatheter intervention.

Initial haemodynamic measurements showed a 5 mmHg gradient across the right pulmonary artery stent. The stent was shortened and flared using a 34 mm Amplatzer Sizing Balloon, and further dilated using a 22 mm Atlas Gold catheter (Figure 2a, Supplementary video 2). Expansion of the sizing balloon in the right ventricular outflow tract enabled further flaring at the proximal end of the stent (Figure 2b), performing measurements of

the expanded right ventricular outflow tract (proximal, mid and distal balloon waists measuring 34 mm, 29 mm, and 29.5 mm, respectively) and evaluation of the distance to the coronary arteries. An extra stiff guidewire was anchored in the distal left pulmonary artery, and a 24 Fr DrySeal sheath (Gore) was introduced into the proximal segment of the left pulmonary artery. A 32–30 mm Venus-P valve opening was initiated in the proximal left pulmonary artery, while the distal flare of the valve was opened at the upper stent edge (Figure 2c). Further valve release maintained the distal marker position in contact with the lower edge of the right pulmonary artery stent (Figure 2d–e). Control angiography confirmed unrestricted contrast flow into both pulmonary branches and proper filling of the right branch through the distal uncovered flare of the valve (Figure 2f).

The recovery was uneventful. Discharge and the 6-month follow-up echocardiography revealed good function of the implanted Venus-P valve.

Discussion

Initially, a stent in the branch pulmonary artery was considered a relative contraindication for self-expandable Venus-P valve implantation.⁶ The distal flare of the valve could interlock with

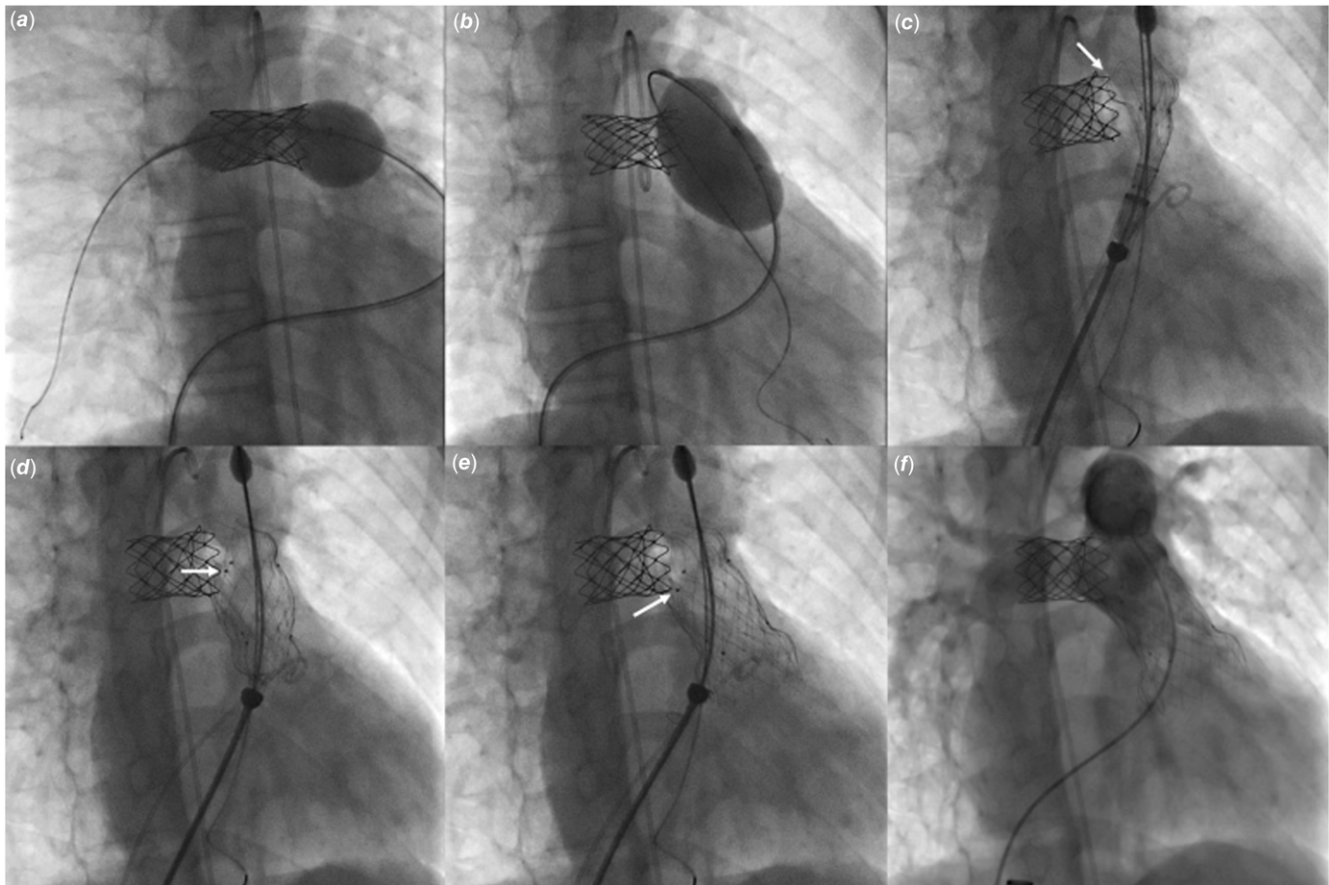


Figure 2. Percutaneous implantation of a self-expanding valve in patient with tetralogy of Fallot after surgical patch repair and stent implantation in the right pulmonary artery (RPA). (a, b) The proximal end of the stent in the RPA was adapted with a sizing balloon to create a large landing space for the distal flare of the Venus-P Valve (MedTech). (c) A 32-30 mm valve was introduced through a 24 Fr DrySeal sheath (Gore) to the proximal left pulmonary artery. Opening of the distal flare was initiated at the level of the top edge of the stent in the RPA (white arrow). (d) Exposing the remainder of the valve was performed in such a way as to keep the distal markers of the valve at the lower edge of the stent. (e) After complete exposure of the valve the distal markers (white arrows) matched the lower end of the stent and the distal flare fit in the RPA stent. (f) Control angiography from the MPA showed unobstructed contrast flow to both pulmonary arteries with a trace of central regurgitation.

the stent, the tubular covered section of the valve could obstruct flow to the stented branch, or the protruding stent could hinder proper alignment of the valve and induce a paravalvular leak.

However, the unique valve design can also be an advantage in the setting of stented pulmonary arteries. If the distal uncovered cells of the valve are deployed at the level of the stent, there is no threat to pulmonary artery blood flow. The stent should be sufficiently dilated (16–18 mm) for the distal flare of the valve to anchor into the stent and must not prolapse into the main pulmonary trunk to avoid hooking the valve into it. Both presented patients underwent stent dilation prior to the valve implantation. Achieved stents' diameters are sufficient for adult patients, hence reducing the need for future redilations. The guidewire was anchored in the non-stented branch, facilitating precise valve positioning and avoiding potential complications.

The previously implanted stent can serve as an ideal marker for positioning of the valve thus allowing reduction of the number of angiographies and radiation exposure.¹⁰

Conclusion

With careful evaluation and an individualised approach to procedure planning and execution, percutaneous large self-

expanding valve implantation can be successfully applied in patients with stented pulmonary arteries.

Supplementary material. The supplementary material for this article can be found at <https://doi.org/10.1017/S1047951124036588>.

Acknowledgements. To Anna Grondalski from Pomeranian Medical University for editing the text.

Financial support. None.

Competing interests. MG and SG are proctors for MedTech.

References

1. Fiszer R, Dryżek P, Szkutnik M et al. Immediate and long-term outcomes of percutaneous transcatheter pulmonary valve implantation. *Cardiol J* 2017; 24: 604–611.
2. Promphan W, Prachasilchai P, Siripornpitak S, Qureshi SA, Layangool T. Percutaneous pulmonary valve implantation with the Venus P-valve: clinical experience and early results. *Cardiol Young* 2016; 26: 698–710.
3. Husain J, Praichasilchai P, Gilbert Y, Qureshi SA, Morgan GJ. Early European experience with the Venus P-valve®: filling the gap in percutaneous pulmonary valve implantation. *EuroIntervention* 2016; 12: e643–e651.

4. Garay F, Pan X, Zhang YJ, Wang C, Springmuller D. Early experience with the Venus p-valve for percutaneous pulmonary valve implantation in native outflow tract. -valve for percutaneous pulmonary valve implantation in native outflow tract. *Neth Heart J* 2017; 25: 76–81.
5. Morgan GJ, Sivakumar K, Promphan W, GorecznyS, PrachasilchaiP, QureshiS. Early clinical experience with the straight design of Venus P-valveTM in dysfunctional right ventricular outflow tracts. *Catheter Cardiovasc Interv* 2020; 96: E653–E659.
6. Morgan G, Prachasilchai P, Promphan W et al. Medium-term results of percutaneous pulmonary valve implantation using the Venus P-valve: international experience. *EuroIntervention* 2019; 14: 1363–1370.
7. Sivakumar K, Sagar P, Qureshi S et al. Outcomes of Venus P-valve for dysfunctional right ventricular outflow tracts from Indian Venus P-valve database. *Ann Pediatr Cardiol* 2021; 14: 281–292.
8. Góreczny S, Szeliga J, Lazu M, Załuska-Pitak B, Gwellig M. First Polish pediatric experience with percutaneous self-expandable pulmonary valve implantation. *Kardiol Pol* 2024; 82: 101–102.
9. Góreczny S, Szeliga J, Lazu M, Becht R, Mroczek T, Qureshi S. Implantation of a large self-expanding pulmonary valve using the jugular vein approach in a teenage patient. *Kardiol Pol* 2024; 82: 549–550.
10. Goreczny S, Moszura T, Dryzek P et al. Three-dimensional image fusion guidance of percutaneous pulmonary valve implantation to reduce radiation exposure and contrast dose: A comparison with traditional two-dimensional and three-dimensional rotational angiographic guidance. *Neth Heart J* 2017; 25: 91–99.