

Early outcomes after transoral CO₂ laser resection of laryngeal and hypopharyngeal squamous cell carcinoma: one centre's experience

S C LEONG, C KATHAN*, S MORTIMORE†

Abstract

Objectives: To review early oncological outcomes following transoral CO₂ laser resection of laryngeal and hypopharyngeal squamous cell carcinoma.

Design: Retrospective review of hospital electronic database.

Setting: Large district general hospital in England, UK.

Main outcome measures: Patients' three-year disease-specific survival and disease-free survival were evaluated, including post-operative complications, voice quality and swallowing status.

Results: Seventy-seven patients (16 women and 61 men) were identified. Transoral laser excision of squamous cell carcinoma of the larynx was undergone by 65 patients, and the same procedure in the hypopharynx by 12. Patients with laryngeal cancer had statistically better disease-specific survival than those with hypopharyngeal cancer ($p = 0.021$), although the cumulative disease-free survival probability was 0.71 for both larynx and hypopharynx groups. Patients who underwent laryngectomy following failed laser treatment or as a salvage procedure had poorer outcomes.

Conclusions: The overall results of this study were comparable with those of other, larger studies. At three-year follow up, cumulative disease-specific survival probabilities were 0.92 and 0.71 for laryngeal and hypopharyngeal squamous cell carcinoma, respectively.

Key words: Larynx Neoplasms; Pharynx Neoplasms; Laser Therapy

Introduction

Controversy still exists over the optimal treatment for laryngeal cancer.¹ For early lesions (i.e. tumour (T)₁ and T_{1b}), treatment options include radiotherapy and various surgical procedures (e.g. transoral laser microsurgery and transcervical partial laryngectomy).² For more advanced laryngeal cancer, many treatment options (and outcomes) have been reported, including radiotherapy, chemo-radiation, and partial and total laryngectomy with prosthetic speech rehabilitation. Recently, some European centres have reported favourable oncological results after treating more advanced supraglottic and glottic laryngeal cancer with laser resection.^{3,4}

The aim of this paper was to review the oncological outcomes of patients undergoing transoral CO₂ laser resection of laryngeal and hypopharyngeal squamous cell carcinoma, focusing specifically on the first three years after surgery at an English cancer centre.

Methods and subjects

Patients

The ENT department at Derby Hospitals National Health Service Foundation Trust is part of the regional head and neck cancer network covering southern Derbyshire and eastern Staffordshire (England, UK), and serves a population of over 800 000. This region has a mix of rural and urban populations undertaking industrial, agricultural and non-manual employment. The ENT department is based at the Derby Royal Infirmary, a busy district general hospital. Since August 2001, the senior author (SM) had kept an electronic database prospectively recording the details for all patients treated with transoral CO₂ laser resection for mucosal tumours of the upper aerodigestive tract, within the department.

The current study included patients with histologically proven squamous cell carcinoma (SCC) of the

From the Common Cold Centre, Cardiff University, Wales, UK, the *Faculty of Economics, Administrative and Social Sciences, Bilkent University, Ankara, Turkey, and the †Department of Otolaryngology – Head and Neck Surgery, Derby Hospitals National Health Service Foundation Trust, UK.

Accepted for publication: 18 June 2009. First published online 3 December 2009.

larynx and hypopharynx. Patients lost to follow up or transferred to other hospitals were excluded, as were those who had not completed 12 months of follow up.

Methods

The management of all patients was discussed at the local head and neck multidisciplinary team (MDT) meeting.

Pre-operative tumour staging was performed by endoscopy and radiological imaging (i.e. computed tomography (CT) of the neck and chest). All patients were staged according to the International Union Against Cancer – American Joint Commission on Cancer 2002 staging system.

Transoral laser surgery was performed by the senior author with a 40 W Sharplan Acublade CO₂ laser (Lumenis, London, UK) mounted on a surgical microscope (Leica, Milton Keynes, UK). It was the standard practice of the corresponding author to perform a single resection followed by close surveillance.

A second procedure was planned if the histology report suggested involvement of the margins, or if the corresponding author was concerned about incomplete clearance. A repeat procedure to resect the margin and remove granulation tissue was also planned if the wound did not heal by six weeks post-operatively.

The post-operative follow-up regime for head and neck cancer patients in our department was as follows: monthly in the first year, bimonthly in the second year, four-monthly in the third and fourth years, and six-monthly in the fifth year.

Failed laser treatment was defined as the existence of evidence of residual tumour, due to the inability to obtain clear margins (surgically or histologically), and the requirement for another form of treatment (e.g. total laryngectomy), including palliation.

Residual disease was defined as unclear resection margins, or evidence of tumour regrowth within 12 months of the first laser resection.

Salvage surgery was undertaken for recurrence not amenable to further laser resection. In our series, salvage surgery procedures included total laryngectomy and neck dissection. Recurrence was defined as histological evidence of clear margins after resection, plus subsequent histological evidence of pathology at least 12 months after the latest laser resection. Post-operative radiotherapy was given to the primary site and neck based on clinicopathological risk factors, including: positive or close surgical margins; multiple lymph node involvement in the neck; extracapsular spread; or histopathological indicators of aggressive disease, such as perineural invasion, vascular invasion and poor differentiation.

Ethical considerations

Institutional review board approval was not required for this retrospective review. The encrypted electronic database was kept on a hospital computer in a secure location, and was accessed by a password known only to the first and third authors.

Statistical analysis

Statistical analysis of the data was performed using the Statistical Package for the Social Sciences version 11.5 software (SPSS Inc, Chicago, Illinois, USA). All survival rates were calculated by the Kaplan–Meier method from the first day of laser resection. Survival probabilities with 95 per cent confidence interval were estimated, and the log rank (Cox–Mantel) test was performed for comparison. Patients' three-year disease-specific survival and disease-free survival were evaluated. Results were regarded as statistically significant if *p* was less than 0.05. Survival data were calculated using the Kaplan–Meier method. The study was limited to reviewing oncological outcomes during the first three years after laser resection.

Results

Database entries from 1 August 2001 to 31 August 2008 were retrospectively reviewed. Seventy-seven patients (16 women and 61 men) fulfilling the inclusion criteria were identified from the database. The mean age of patients at diagnosis was 65 years (range 35–93 years).

Of the 77 patients, 65 underwent transoral laser excision of laryngeal SCC and 12 underwent transoral laser excision of hypopharyngeal SCC. A total of 161 laser procedures were performed. Each patient had an average of two laser procedures throughout the review period. The most frequent sites of laryngeal involvement were the vocal fold (31.2 per cent) and anterior commissure (19.9 per cent). The most frequent site of hypopharyngeal involvement was the pyriform fossa (63 per cent). Within the three-year post-operative period assessed by this study, the mean follow-up period was 24 months (median 27 months, standard deviation (SD) 11 months).

Tumour staging was upgraded in 26 patients at the time of first laser resection. The most common change was from T_{1b} to T₂ (occurring in five patients) and from T₃ to T₄ (in four patients), followed by T_{1a} to T₂ and T₂ to T₄ (three cases each). Staging was downgraded in only one patient, from T₄ to T₃.

Four patients (three with laryngeal SCC and one with hypopharyngeal SCC) underwent palliative laser debulking of the tumour to improve their airway, in order to avoid a tracheostomy. These patients had either T₃ or T₄ laryngeal disease at the time of presentation. Three subsequently died of their disease, one due to a second bronchogenic carcinoma.

One patient (with T₄ disease) underwent laser debulking to improve their airway whilst awaiting MDT discussion. This patient subsequently underwent total laryngectomy and bilateral selective neck dissection, and was alive at last review.

Another patient presented with a suspicious finding on a chest CT, and underwent laser debulking of a T₄ tumour whilst awaiting bronchial biopsy. This biopsy was reported as negative; however, by the time this patient was reassessed by the senior surgeon, the tumour was deemed too large for

transoral laser resection. This patient went on to undergo total laryngectomy and bilateral selective neck dissection, but died of cardiorespiratory co-morbidity 13 months post-operatively.

Primary laser resection was abandoned in two patients (both with T₄ laryngeal SCC) due to extensive tumour invasion, in favour of total laryngectomy. One patient died of metastatic lung cancer, whilst the other remained disease-free following total laryngectomy.

In the remaining 69 patients, laser resection was undertaken with curative intent; the results are described in detail below. The distribution of laryngeal and hypopharyngeal tumours is shown in Table I. The most common laryngeal tumour stage was T₂ (38 per cent), followed by T₃ (22 per cent), whilst 82 per cent of hypopharyngeal tumours were either T₃ or T₄. No patients had detectable metastatic disease (i.e. they were M₀) at the time of first laser resection. Fifty-eight patients (84 per cent) were treated for laryngeal and 11 (16 per cent) for hypopharyngeal disease. At the latest clinic consultation, 93 per cent (54/58) and 73 per cent (eight of 11) of the laryngeal and hypopharyngeal group, respectively, were alive and had no evidence of recurrent disease.

In the laryngeal group ($n = 58$), five patients received radiotherapy as the primary treatment modality; four of these subsequently underwent laser resection for recurrence, and one had laser resection for disease which was unresponsive to radiotherapy. This latter patient eventually underwent total laryngectomy for failed laser treatment.

During the review period, a total of 15 patients suffered recurrent disease following laser resection (Table II). The average delay from first laser treatment to recurrence was 18.8 months (range 17–116 months). Thirteen of these patients had recurrent disease at the primary site, whilst two suffered regional recurrence in the neck. Twelve patients with recurrent disease at the primary site underwent repeated laser resection (Table II). However, four of these patients eventually underwent total laryngectomy and neck dissection, two after failed laser treatment and two as salvage treatment. Three of these laryngectomised patients (one failed and two

salvage) were alive at latest follow up, whilst the fourth died of stomal recurrence 18 months after surgery. Of the other eight patients who underwent repeated laser resection, three also received chemo-radiotherapy and one radiotherapy. All eight patients were alive and disease-free at the last consultation. One patient with recurrence at the primary site declined any further treatment; this patient received palliative care, and died during the review period. The two patients who developed regional neck recurrence were treated with selective neck dissection. Both patients were alive at latest follow up.

The other 43 patients treated for laryngeal SCC did not suffer recurrence during the review period. These included two patients who required total laryngectomy and selective neck dissection due to failed laser treatment at the primary resection but who had since remained disease-free (Table III). Five other patients underwent neck dissections (three bilateral and two unilateral) for node (N)₀, N_{2a}, N_{2b}, N_{2c} and N₃ nodal disease, variously. All but two remained alive during the review period. The two deaths were not related to the primary laryngeal tumour; one patient died of congestive heart failure following myocardial infarction, whilst the other died of peritonitis due to a second primary carcinoma of the colon. Both cases of failed laser treatment in the laryngeal cohort underwent total laryngectomy for persistent residual tumour on the resection margins within 12 months of the first laser resection (mean 5.3 months, range three to nine months), and were alive at latest review.

A total of 11 patients (five women and six men) were treated for hypopharyngeal SCC, all of whom had laser resection as the primary treatment modality. None of these suffered recurrent disease during the review period (Table III). Nine patients also underwent neck dissection (five bilateral and four ipsilateral). Three deaths were recorded in the hypopharyngeal group, two due to metastatic pulmonary involvement and the other due to concomitant anaplastic carcinoma of the thyroid. The surviving eight patients were disease-free at the latest review, although one patient required laryngopharyngectomy, neck dissection and a gastric pull-up procedure for a second primary carcinoma of the cervical oesophagus. All patients in this cohort required percutaneous gastrostomy feeding, and 10 patients also received post-operative radiotherapy. No laryngectomies were performed for functional reasons.

Over a quarter (26 per cent) of patients in the study cohort required a percutaneous gastrostomy tube, including all those treated for hypopharyngeal SCC (Table IV). The percutaneous gastrostomy was temporary in 17 patients, remaining in place an average of 31 weeks (range 12–104 weeks, SD 24 weeks). All these patients returned to a normal oral diet except one, who managed only a liquid diet. One other patient remained reliant on long-term percutaneous gastrostomy feeding for their nutritional requirements. A small proportion of patients (4 per cent) required a temporary nasogastric tube for an

TABLE I

TNM STAGING OF PATIENTS WITH SCC OF LARYNX AND HYPOPHARYNX

Stage	N _x	N ₀	N ₁	N ₂	N _{2a}	N _{2b}	N _{2c}	N ₃
<i>Larynx</i> *								
T ₁		3						
T _{1a}	1	9						
T _{1b}		2						
T ₂		22		1	1		1	
T ₃		15	1					1
T ₄		7				1		
<i>Hypopharynx</i> †								
T ₁								1
T ₂						1		
T ₃		1				2		

Data represent patient numbers. All patients had M₀ disease. * $n = 65$; † $n = 5$.

TABLE II
OUTCOMES OF PATIENTS PRESENTING WITH RECURRENT LARYNGEAL SCC AFTER PRIMARY LASER RESECTION

Site of recurrence	Pts (<i>n</i>)	Treatment		Outcome* (<i>n</i>)	
		Technique	Pts (<i>n</i>)	Alive	Dead
Primary larynx	13	Repeat laser resection	4	4	0
		Repeat laser & post-operative radiotherapy	4	4	0
		Palliative [†]	1	0	1
		Total laryngectomy (for failed laser treatment)	2	1	1
		Total laryngectomy (for salvage procedure)	2	2	0
Neck	2	Selective neck dissection	2	2	0
Total	15		15	13	2

*At latest review. [†]Patient declined further treatment. SCC = squamous cell carcinoma; pts = patients

average of two weeks. Pre-operatively, 76 per cent of patients managed a normal diet, 11 per cent required a soft diet and 13 per cent tolerated only fluids. At one month post-operatively, 69 per cent of patients had a normal diet, 19 per cent required a soft diet, 6 per cent managed only fluids and 6 per cent were reliant on percutaneous gastrostomy feeding. At six months post-operatively, this situation had improved to 87 per cent on a normal diet and 10 per cent on a soft diet. The duration of percutaneous gastrostomy placement was longer than the delay between laser procedure and commencement of oral intake, as it was usual practice at our institution to remove the percutaneous gastrostomy tube approximately eight weeks after safe resumption of oral intake.

Of the 62 patients with a preserved larynx, at six-month follow up, 39 per cent had normal voice quality, 48 per cent managed telephone conversations and 16 per cent had only whispered voice.

There were 11 reported post-operative complications out of 161 laser procedures, giving a complication rate of 6.8 per cent. No intra-operative or anaesthetic-related complications were noted. The most common complication was supraglottic stenosis (four cases); all of these patients underwent laser release of the scar tissue, with successful outcomes. There were three cases of surgical emphysema,

which resolved spontaneously. Two patients had post-operative bleeding which was managed conservatively, one was treated for pneumonia and one patient had significant vocal fold adhesion requiring surgical release. Three patients (two with laryngeal and one with hypopharyngeal disease) required a temporary tracheostomy, which was removed an average of seven days post-operatively. One patient who was treated for hypopharyngeal SCC (T₄ N_{2c} M₀) required a long-term tracheostomy; this patient remained alive and disease-free five years post-operatively.

Survival outcomes were analysed for the cohort treated with curative intent (*n* = 69). At the latest clinic review, 93 per cent (54/58) and 73 per cent (eight of 11) of the laryngeal and hypopharyngeal group, respectively, were alive and had no evidence of recurrent disease. Of the 54 laryngeal patients who were alive, 14 (93 per cent) had T₁ tumour, 22 (92 per cent) T₂, 15 (100 per cent) T₃ and three (75 per cent) T₄. In the hypopharyngeal group, three (60 per cent) patients had T₃ tumour, three (75 per cent) had T₄, and one each had T₁ and T₂ (Table III). The overall average survival period was 32.5 months after primary laser resection. Those patients with laryngeal cancer had a mean survival period of 34.3 months, compared with 26.7 months for patients with hypopharyngeal disease.

TABLE III
PATIENT TREATMENT AND OUTCOME BY TUMOUR STAGING AND PRIMARY SITE

Primary T site	T stage	Recurrence?/site	Pts (<i>n</i>)	Total Lgtmy (<i>n</i>)	ND (<i>n</i>)	Post-op CRT (<i>n</i>)	Post-op RT (<i>n</i>)	Alive* (<i>n</i>)	Dead [†] (<i>n</i>)	DOOD (<i>n</i>)
Larynx	T ₁	No	15	0	0	0	0	14	0	1
	T ₂	No	14	0	2	0	1	14	0	0
	T ₂	Yes/local	8	2	2	2	0	6	2	0
	T ₂	Yes/neck	2	0	2	0	1	2	0	0
	T ₃	No	10	0	1	1	0	10	0	0
	T ₃	Yes/local	5	2	1	1	1	5	0	0
	T ₄	No	4	2	4	2	1	3	0	1
Total			58	6	12	6	4	54	2	2
Hypopharynx	T ₁	No	1	0	1	0	1	1	0	0
	T ₂	No	1	0	1	0	1	1	0	0
	T ₃	No	5	0	5	1	4	3	2	0
	T ₄	No	4	1	3	3	0	3	1	0
Total			11	1	10	4	6	8	3	0

*At latest review. [†]Due to squamous cell carcinoma. T = tumour; pts = patients; Lgtmy = laryngectomy; ND = neck dissection; post-op = post-operative; CRT = chemo-radiotherapy; RT = radiotherapy; DOOD = died of other disease

TABLE IV

PATIENT OUTCOMES: PERCUTANEOUS GASTROSTOMY AND NASOGASTRIC TUBE USE, DIET AND VOICE QUALITY

Primary T site (<i>n</i>)	T stage	PEG post-op (<i>n</i>)	NGT post-op (<i>n</i>)	PEG long-term (<i>n</i>)	Diet at 6 mths (<i>n</i>)			Voice at 6 mths (<i>n</i>)		
					Liquid only	Soft only	Normal	Normal	Telephone	Whispered (<i>n</i>)
Larynx*	T ₁	0	0	0	0	0	15	8	7	0
	T ₂	2	0	0	0	0	22	6	12	4
	T ₃	3	2	0	0	3	10	2	7	4
	T ₄	2	0	0	0	1	1	2	0	0
Total		7	2	0	0	4	48	18	26	8
Hypopharynx†	T ₁	1	0	0	0	0	1	1	0	0
	T ₂	1	1	0	0	0	1	1	0	0
	T ₃	5	0	1	0	2	2	2	3	0
	T ₄	4	0	0	1	0	3	2	1	0
Total		11	1	1	1	2	7	6	4	0

**n* = 58; †*n* = 11. T = tumour; PEG = percutaneous gastrostomy tube; NGT = nasogastric tube; post-op = used post-operatively; long-term = used long-term; mths = months; telephone = telephone conversation possible

At three-year follow up, the overall disease-specific survival and disease-free survival probabilities were 0.95 and 0.97, respectively. Patients with laryngeal cancer had significantly better disease-specific survival than those with hypopharyngeal cancer ($p = 0.021$, Figure 1), although the disease-free survival probability three years post-operatively was 0.71 for both the larynx and hypopharynx groups (Figure 2, Table V). Differences in disease-free survival between the two groups were not statistically significant ($p = 0.95$). The difference in survival probabilities was statistically significant ($p = 0.000$), comparing patients undergoing laser resection versus those who received radiotherapy as the primary treatment modality for laryngeal cancer (Figure 3). Patients who did not require post-operative radiotherapy

had a slightly better survival outcome than those who did, but this difference did not reach statistical significance ($p = 0.59$).

Patients who received primary radiotherapy had poorer outcomes, having a mean survival time of 30.6 months after laser resection for recurrent laryngeal disease. Patients who underwent laryngectomy either for failed laser treatment or as a salvage procedure also had poorer outcomes, although this difference did not reach statistical significance ($p = 0.30$). There was a statistically significant difference in survival probability ($p = 0.023$), comparing patients with recurrent disease (either at the primary site or cervical lymphadenopathy) versus those who remained disease-free after laser resection (Figure 4). Patients presenting with recurrent cancer

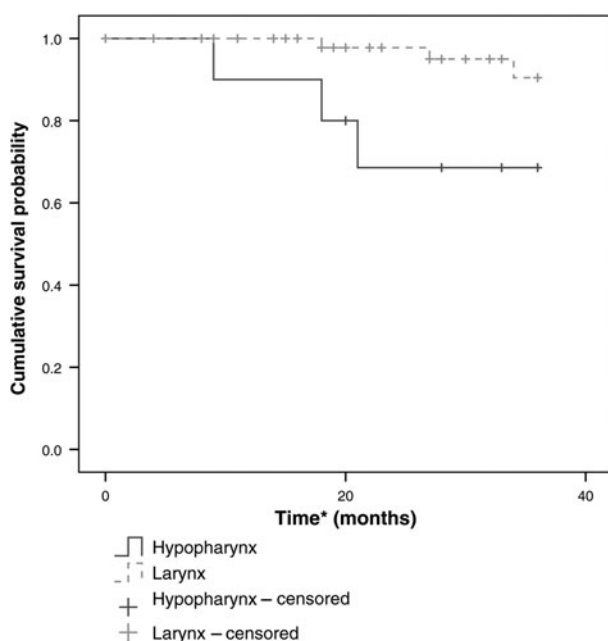


FIG. 1

Three-year disease-specific survival probability for patients with laryngeal vs hypopharyngeal squamous cell carcinoma, $p = 0.021$. *Including censored.

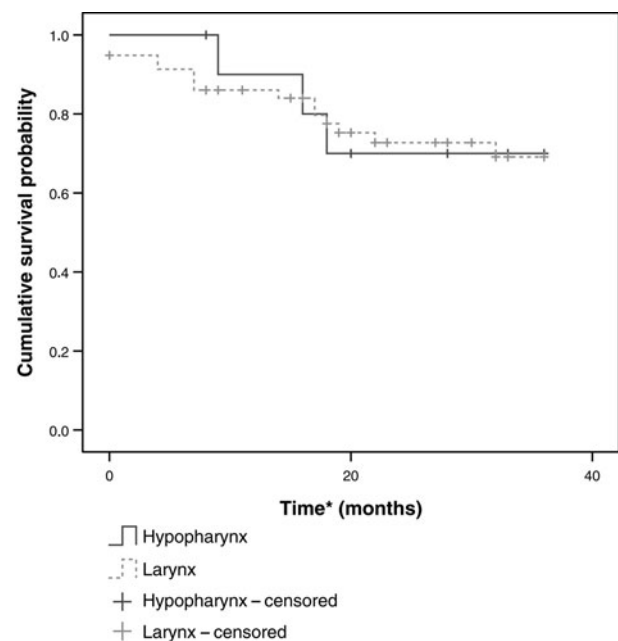


FIG. 2

Three-year disease-free survival probability for patients with laryngeal vs hypopharyngeal squamous cell carcinoma, $p = 0.71$. *Including censored.

TABLE V
CUMULATIVE PROBABILITIES FOR PATIENTS' DISEASE-SPECIFIC AND DISEASE-FREE SURVIVAL

Time since first laser (yr)	DSS		DFS	
	Larynx	Hypopharynx	Larynx	Hypopharynx
1	1.00	0.91	0.86	0.91
2	0.98	0.71	0.74	0.71
3	0.92	0.71	0.71	0.71

Yr = years; DSS = disease-specific survival; DFS = disease-free survival

had a significantly poorer outcome, as expected. In addition, patients presenting with a recurrence in the larynx had a poorer outcome than those who had a recurrence in the neck ($p = 0.59$) (Figure 5).

Discussion

Squamous cell carcinoma of the upper aerodigestive tract is the most common cancer of the head and neck, excluding the skin. External surgery and chemo-radiotherapy are commonly employed as standard treatment modalities, whilst the place of transoral laser excision of glottic cancer is less established. Use of this latter treatment modality is highly dependent on geography, being more popular in Europe and the US.^{5,6} Transoral resection of carcinoma is an emerging procedure in the UK, and is currently being evaluated in the 'EaSter' (Early Stage glottic cancer: Endoscopic excision or Radiotherapy) feasibility study.⁷ Notwithstanding laryngeal preservation, transoral laser surgery is potentially beneficial as it does not preclude further treatments such as adjuvant radiotherapy, laser retreatment or salvage surgery. To our knowledge, the current,

single-centre, retrospective study is the first from the UK to review the oncological outcomes of CO₂ transoral laser resection of upper aerodigestive tract SCC.

The survival probabilities observed in this study are comparable to previously published results. Maurizi *et al.* reported disease-specific survival and disease-free survival probabilities of 0.96 and 0.89, respectively, at three years' follow up, falling to 0.94 and 0.85 at five years.⁸ In comparison, the disease-specific survival and disease-free survival probabilities observed in the present study were 0.92 and 0.71, respectively, at three years' follow up. The differences in outcome were due to the significantly higher proportion of T₁ laryngeal tumours in Maurizi and colleagues' study (89 per cent), compared with our own (only 26 per cent at presentation). In a multicentre, retrospective review of 117 patients with advanced glottic carcinoma treated by laser resection, two- and five-year estimated disease-free survival probabilities were 0.68 and 0.58, respectively.⁹ The reported two-year overall survival rate was 75 per cent. Vilaseca *et al.*

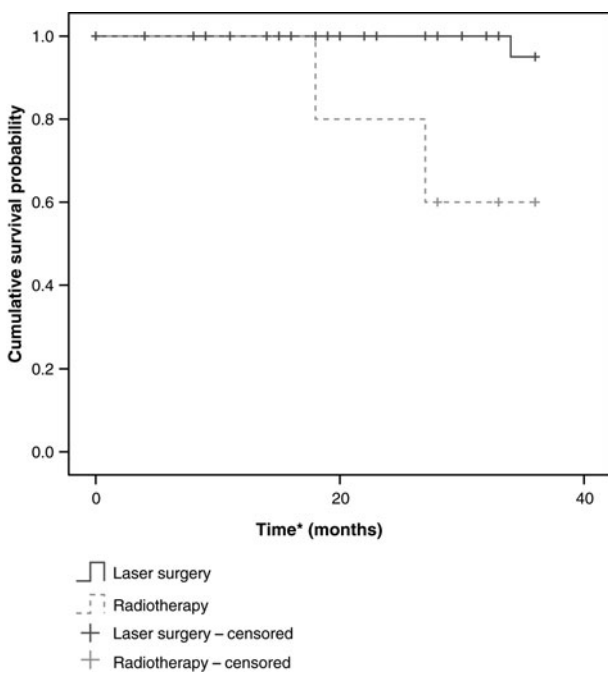


FIG. 3

Three-year survival probability for patients undergoing laser resection vs radiotherapy, as first treatment for laryngeal squamous cell carcinoma, $p = 0.000$. *Including censored.

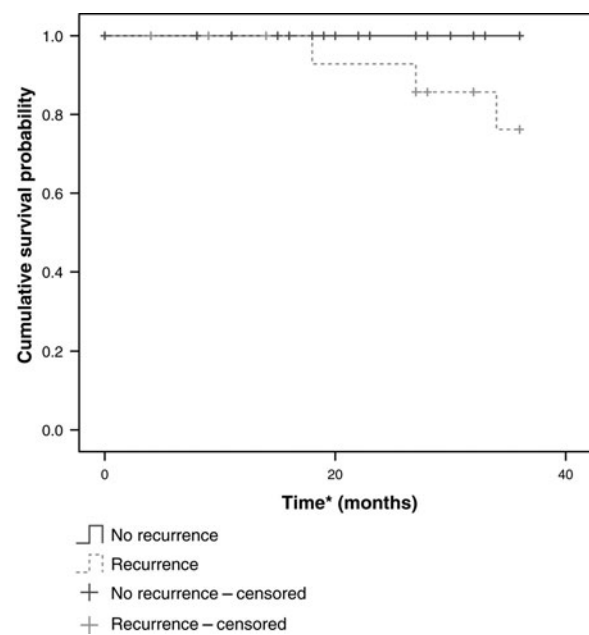


FIG. 4

Three-year survival probability for laryngeal squamous cell carcinoma patients suffering recurrence (primary site or cervical lymphadenopathy) vs those remaining disease-free, after laser resection, $p = 0.023$. *Including censored.

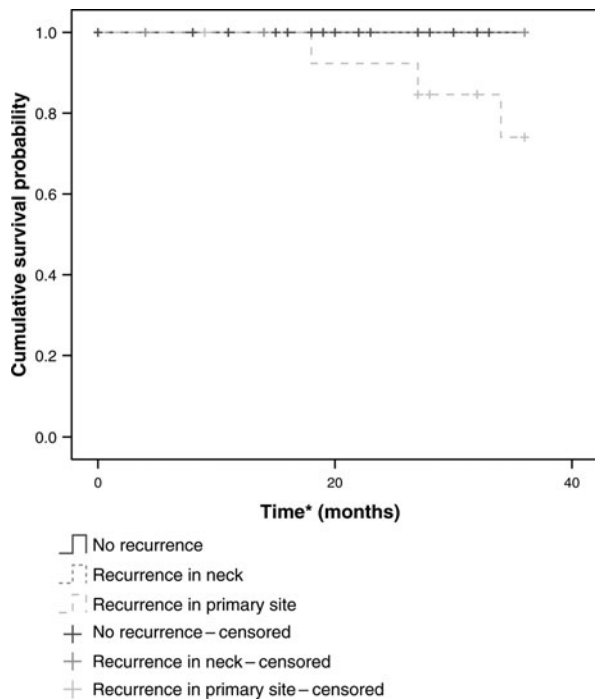


FIG. 5

Three-year survival probability for laryngeal squamous cell carcinoma patients suffering no recurrence, recurrence in the neck and recurrence in the larynx. $p = 0.59$, neck recurrence vs laryngeal recurrence. *Including censored.

reported a local recurrence rate of 23 per cent in their cohort of 28 patients treated for laryngeal SCC, with a disease-specific survival probability of 0.59 at four-year follow up.¹⁰ The local recurrence rate in the present study was similar (at 25 per cent), probably due to the comparable proportions of T₂ and T₃ tumours in both studies. The overall larynx preservation rate in this study was 90 per cent, which was comparable to other published results. Eckel *et al.* reported an organ preservation rate of 92 per cent at both two- and five-year follow up, although their cohort had predominantly lower stage cancers.¹¹

Whilst transoral laser surgery is generally regarded as safe, it is not without complications, including fatal consequences. Hinni *et al.* reported one death due to aspiration of a blood clot during a planned 'second look' procedure, and three other deaths related to patients' medical co-morbidities, within one month of surgery. In a large series of 275 cases reported by Vilaseca-González *et al.*, the only complication observed during laser resection was ignition of the adhesive strips used to attach two Teflon® injection catheters, in a patient receiving high frequency jet ventilation; however, 18.9 per cent of patients suffered post-operative complications, including local infection, emphysema, cutaneous fistula, post-operative bleeding and pneumonia.¹² No treatment-related deaths occurred in this study, although there was one case of post-operative pneumonia attributed to pre-existing poor respiratory function. In this study, the proportion of patients reliant on nasogastric tube feeding for nutritional intake (4 per cent) was lower than reported

elsewhere. In a cohort of 172 hypopharyngeal SCC cases studied by Martin *et al.*, 80 per cent of patients required a nasogastric tube for one week (range 1–110 days).⁶ The standard practice in our department was to electively insert a percutaneous gastrostomy tube in all patients with hypopharyngeal carcinoma, prior to laser resection. We did not experience any complications with percutaneous gastrostomy in the current series, and have found this practice useful in facilitating feeding during the immediate post-operative period and during post-operative radiotherapy.

Negative resection margins are an important prognostic indicator in head and neck cancer. Many cancer centres utilise intra-operative frozen-section examination to obtain clear margins. The accuracy of frozen-section diagnosis is well established, but is dependent on the experience and technique of the pathologist and supporting laboratory technicians.¹³ Frozen-section examination also allows a positive margin to be corrected before surgical closure and reconstruction.¹⁴ These factors may be important in external laryngeal surgery but are generally less relevant in transoral resection, as reconstruction of the aerodigestive tract is not normally required, and returning to the operating theatre for further laser resection is less complex than with open procedures where tissues have been reconstructed. Healing of exposed areas occurs by secondary intention. Frozen-section examination for laryngeal cancer is not without problems. Discrepancies have been reported by some authors, with up to 5 per cent of frozen-section samples obtained from laryngeal specimens being false negative.^{15,16} False positive reports have also been noted, resulting in wider resection margins which complicate surgical closure and subsequent functional outcomes.¹⁷

As frozen-section examination was not encouraged by our histopathology department, a low threshold for second look procedures was adopted in our department as an acceptable practice. All patients in the current series were made aware of this possibility during the consent process. Each patient underwent an average of two laser procedures throughout the review period (range one to seven). Some patients who had more procedures subsequently underwent total laryngectomy for failed laser treatment. The overall rate of failed laser surgery in this study was 6 per cent (four of 69), and all of these patients had their tumour staging upgraded. The second procedure was frequently planned based on either positive margins or on clinical suspicion during routine follow up. In some cases, resection of large tumours was abandoned in favour of total laryngectomy when it was realised that the tumour was too extensive for transoral resection. In a retrospective series of 1467 patients operated upon by Steiner and Abrosch, patient survival was similar regardless of whether clear resection margins were obtained during the first laser procedure or during revision surgery.¹⁸ Kim *et al.* recommended that radiological staging of laryngeal cancers be correlated with endoscopic findings.¹⁹ In their review of CT scans, the rate of false diagnosis

associated with overstaging was 21 per cent, and that associated with understaging 4 per cent. The current study observed no adverse events associated with elective returns to the operating theatre. In fact, Roh *et al.* advocated a second look procedure as an acceptable practice to detect early recurrence and to manage airway problems.

Unlike external surgery, in which the tumour is normally excised en bloc (following Halsted's principle), laser resection allows the surgeon to assess the tumour by cutting through malignant tissues without the risk of disseminating disease. This technique also allows better assessment of the extent of tumour spread and depth of invasion; this explains the change in tumour staging of 27 patients in this series. Accurate grading of laryngeal tumours is important, considering the potential choice of treatment options and subsequent prognostic implications. Tumour upgrading is not always possible with other techniques, such as CT and magnetic resonance imaging (MRI), other than by histological examination of the excised larynx. Possible discrepancies in tumour staging also makes comparison of the oncological outcomes of radiotherapy and laser resection difficult, as study cohorts may not have similar tumour stages. Transoral laser resection has the advantage of allowing the surgeon to visualise and manipulate the lesion. The tumour can be transected to enable the surgeon to estimate its depth of penetration. Tumour extension is usually clearly distinguishable under the microscope, and the lesion is resected until healthy tissue is found and an appropriate safety margin achieved. This can be seen on the cut surface under high magnification, and enables the surgeon to determine a clear surgical margin. In addition, the initial diagnostic endoscopy procedure was frequently not performed by the senior surgeon (SM), and this may have contributed to the relatively high proportion (35 per cent) of patients with altered tumour staging. As CO₂ laser vaporises tissue, the heat generated seals the exposed tissue surface.²⁰ The resultant carbonisation of the tissue edges destroys a few cell layers, thus preserving the main histological sample.²¹ The completeness of tumour excision as determined by the histopathologist should be correlated with the surgeon's intra-operative evaluation, aided by the operating microscope. Surgical experience, together with feedback from histopathological reports, helps to develop practical clinical accuracy in deciding which specific areas to resect.²¹

In the present study, of those patients with recurrent laryngeal disease at the primary site, 62 per cent (eight of 13) had T₂ tumours at presentation, and T₃ tumours were found in the remaining 38 per cent. All recurrences were confirmed histologically on the grounds of clinical suspicion during routine follow up. In order to maximise functional preservation, the senior surgeon was possibly too conservative in the resection of T₂ tumours, being aware that there is a higher expectation of preserving vocal function in lower staged tumours. The fact that there were relatively fewer recurrences in cases with more

advanced tumour may be because the surgeon undertook a more aggressive resection, as there is a lowered expectation of preserving vocal function in more advanced tumours.

The current practice in our department of frequent follow up of all patients in the first two years after surgery appears to be acceptable. Patients were not rescanned during the follow-up period unless this was clinically warranted. In fact, routine post-operative scanning has not been recommended by the National Institute for Health and Clinical Excellence.²² Magnetic resonance imaging appears to be more specific in detecting neoplastic cartilage invasion than CT, but tends to underestimate soft tissue invasion and may therefore result in undertreatment.²³ The superiority of MRI lies in its ability to detect intra-cartilaginous tumour spread. Unfortunately, MRI findings suggesting neoplastic cartilage invasion may be false positive, due to small tumour volume and abnormal MRI signal pattern in cartilage.²⁴ Overestimation of the size of the tumour is possible if the tumour is surrounded by inflammatory changes, oedema or fibrosis, again causing false positive reporting. Submucosal tumour spread or cartilaginous invasion can result in an underestimation of the extent of the lesion (i.e. a false negative). In addition, problems with movement artefacts frequently occur during imaging of the larynx, making interpretation more difficult. For instance, falsely presumed infiltration of the cricoid or thyroid cartilage (i.e. a false positive finding) on scanning a carcinoma of the anterior glottis with subglottic extension may suggest the need for laryngectomy, leading to overtreatment. Missed cartilage invasion could lead to 'undertreatment' in the form of radiation alone.

- **This study reviewed early oncological outcomes following transoral CO₂ laser resection of laryngeal and hypopharyngeal squamous cell carcinoma (SCC)**
- **Patients with laryngeal SCC had significantly better disease-specific survival than those with hypopharyngeal SCC**
- **Patients who underwent laryngectomy, either for failed laser treatment or as a salvage procedure, had poorer outcomes**
- **Patients' overall disease-specific survival probabilities were 0.92 and 0.71 for laryngeal and hypopharyngeal SCC, respectively, at three-year follow up; this is comparable to the results of other, larger studies**

Laser resection avoids the need to cut through tissues that are free of tumour, thereby maximising the function of the remaining normal tissue. Therefore, this technique has potential advantages over external surgery, including the preservation of voice function and the avoidance of

potential aspiration, dysphagia and a permanent stoma.

The present study had a comparatively smaller cohort of patients compared with previously published studies from more established centres. Nonetheless, we believe the overall results of this study are comparable to those of other, larger studies; our patients' disease-specific survival probabilities were 0.92 and 0.71 for laryngeal and hypopharyngeal SCC, respectively, at three-year follow up.

Conclusion

We intend to continue offering transoral CO₂ laser resection of laryngeal and hypopharyngeal SCC as an option to patients, and in time we will evaluate our long-term outcomes. We believe that the availability of a selection of treatment modalities (such as radiotherapy, combination chemo-radiotherapy, open surgery and transoral laser resection) is advantageous to patients and doctors alike. It is conceivable that, in time, the use of co-morbidity evaluations and retrospective quality of life assessments will enable clinicians to better determine which treatment modality is best suited to individual patients, distinguishing even between those with the same tumour stage.

References

- Ambrosch P. The role of laser microsurgery in the treatment of laryngeal cancer. *Curr Opin Otolaryngol Head Neck Surg* 2007;**15**:82–8
- Cabanillas R, Rodrigo JP, Llorente JL, Suárez C. Oncologic outcomes of transoral laser surgery of supraglottic carcinoma compared with a transcervical approach. *Head Neck* 2008;**30**:750–5
- Steiner W. Results of curative laser microsurgery of laryngeal carcinomas. *Am J Otolaryngol* 1993;**14**:116–21
- Iro H, Waldfahrer F, Altendorf-Hofmann A, Weidenbacher M, Sauer R, Steiner W. Transoral laser surgery of supraglottic cancer: follow-up of 141 patients. *Arch Otolaryngol Head Neck Surg* 1998;**124**:1245–50
- Grant DG, Salassa JR, Hinni ML, Pearson BW, Hayden RE, Perry WC. Transoral laser microsurgery for recurrent laryngeal and pharyngeal cancer. *Otolaryngol Head Neck Surg* 2008;**138**:606–13
- Martin A, Jäckel MC, Christiansen H, Mahmoodzada M, Kron M, Steiner W. Organ preserving transoral laser microsurgery for cancer of the hypopharynx. *Laryngoscope* 2008;**118**:398–402
- Dey P, Arnold D, Wight R, MacKenzie K, Kelly C, Wilson J. Radiotherapy versus open surgery versus endolaryngeal surgery (with or without laser) for early laryngeal squamous cell cancer. *Cochrane Database Syst Rev* 2002;(2):CD002027
- Maurizi M, Almadori G, Plaudetti G, De Corso E, Galli J. Laser carbon dioxide cordectomy versus open surgery in the treatment of glottic carcinoma: our results. *Otolaryngol Head Neck Surg* 2005;**132**:857–61
- Hinni ML, Salassa JR, Grant DG, Pearson BW, Hayden RE, Martin A *et al.* Transoral laser microsurgery for advanced laryngeal cancer. *Arch Otolaryngol Head Neck Surg* 2007;**133**:1198–204
- Vilaseca I, Blanch JL, Bernal-Sprekelsen M, Moragas M. CO₂ laser surgery: a larynx preservation alternative for selected hypopharyngeal carcinomas. *Head Neck* 2004;**26**:953–9
- Eckel HE, Staar S, Volling P, Sittel C, Damm M, Jungehuelsing M. Surgical treatment for hypopharynx carcinoma: feasibility, mortality, and results. *Otolaryngol Head Neck Surg* 2001;**124**:561–9
- Vilaseca-González I, Bernal-Sprekelsen M, Blanch-Alejandro JL, Moragas-Lluis M. Complications in transoral CO₂ laser surgery for carcinoma of the larynx and hypopharynx. *Head Neck* 2003;**25**:382–8
- Yilmaz T, Turan E, Gürsel B, Onerci M, Kaya S. Positive surgical margins in cancer of the larynx. *Eur Arch Otorhinolaryngol* 2001;**258**:188–91
- Black C, Marotti J, Zarovnyaya E, Paydarfar J. Critical evaluation of frozen section margins in head and neck cancer resections. *Cancer* 2006;**107**:2792–800
- Cooley ML, Hoffman HT, Robinson RA. Discrepancies in frozen section mucosal margin tissue in laryngeal squamous cell carcinoma. *Head Neck* 2002;**24**:262–7
- Remacle M, Hamoir M, Marbaix E, Deggouj N, Frederickx Y. Interest in frozen section examination of margins and lymph nodes in laryngeal surgery. *J Laryngol Otol* 1988;**102**:818–21
- Gandour-Edwards RF, Donald PJ, Wiese DA. Accuracy of intraoperative frozen section diagnosis in head and neck surgery: experience at a university medical center. *Head Neck* 1993;**15**:33–8
- Jäckel MC, Ambrosch P, Martin A, Steiner W. Impact of re-resection for inadequate margins on the prognosis of upper aerodigestive tract cancer treated by laser microsurgery. *Laryngoscope* 2007;**117**:350–6
- Kim JW, Yoon SY, Park IS, Park SW, Kim YM. Correlation between radiological images and pathological results in supraglottic cancer. *J Laryngol Otol* 2008;**122**:1224–9
- McWhorter AJ, Hoffman HT. Transoral laser microsurgery for laryngeal malignancies. *Curr Probl Cancer* 2005;**29**:180–9
- Steiner W, Ambrosch P. *Endoscopic Laser Surgery of the Upper Aerodigestive Tract: with Special Emphasis on Cancer Surgery*. Stuttgart: Thieme Medical Publishers, 2000;39–42
- National Institute for Clinical Excellence. *Improving Outcomes in Head and Neck Cancers – the Manual*. London: National Institute for Clinical Excellence, 2004
- Becker M. Neoplastic invasion of laryngeal cartilage: radiologic diagnosis and therapeutic implications. *Eur J Radiol* 2000;**33**:216–29
- Castelijns JA, Becker M, Hermans R. Impact of cartilage invasion on treatment and prognosis of laryngeal cancer. *Eur Radiol* 1996;**6**:156–69

Address for correspondence:

Mr S Mortimore,
Department of Otolaryngology – Head and Neck Surgery,
Derby Royal Infirmary,
London Road, Derby DE1 2QY, UK.

Fax: 442920876986

E-mail: sean.mortimore@derbyhospitals.nhs.uk

Mr S Mortimore takes responsibility for the integrity of the content of the paper.

Competing interests: None declared