




cambridge.org/cty

Anisa Rahmadhany¹ , Birry Karim² and Mohamad Yanuar Amal³

Brief Report

Cite this article: Rahmadhany A, Karim B, and Amal MY (2024) Case report: Prinzmetal angina in adolescent. *Cardiology in the Young* **34**: 1381–1384. doi: [10.1017/S1047951124025022](https://doi.org/10.1017/S1047951124025022)

Received: 12 June 2023
Revised: 17 February 2024
Accepted: 1 April 2024
First published online: 24 April 2024

Keywords:

Prinzmetal; angina; adolescent

Corresponding author:

Anisa Rahmadhany;
Email: dr.anisa.rahmadhany@gmail.com

¹Department of Pediatrics, Dr. Cipto Mangunkusumo General Hospital, Faculty of Medicine, University of Indonesia, Jakarta, Indonesia; ²Department of Internal Medicine, Dr. Cipto Mangunkusumo General Hospital, Faculty of Medicine, University of Indonesia, Jakarta, Indonesia and ³Department of Radiology, Dr. Cipto Mangunkusumo General Hospital, Faculty of Medicine, University of Indonesia, Jakarta, Indonesia

Abstract

Prinzmetal angina is a rare condition more likely to be reported in adults. Vasospasm is by far notable for causing this condition. We present a case of Prinzmetal angina in a 17-year-old male who experienced unexplained resting chest pain for 2 days.

Prinzmetal angina is an uncommon variant of angina pectoris caused by coronary vasospasm, also known as variant or vasospastic angina.^{1,2} It is indicated by angina at rest.² The precise incidence is unclear, considering the wide variety of cases.¹ Adults older than 50 to 60 years of age are the common population at risk. Nonetheless, there were reports of variant angina in adolescents.^{3,4} This report describes a rare case of Prinzmetal angina in a 17-year-old male.

Case presentation

A 17-year-old male presented to the outpatient clinic with chest pain which had occurred for 7 hours. The characteristic of the pain was described to be more of a slice rather than heaviness. The pain did not radiate to the left arm or the jaw, nor did it feel like penetrating the back. The pain was relieved briefly after a massage. He also consumed antacids, which helped diminish the pain for a while but recurred. Additionally, the patient also experienced cold sweat. No history of shortness of breath, fever, or cough was reported. A similar complaint was felt a day earlier which disappeared following antacids administration. There are no other known comorbidities, such as hypertension, diabetes mellitus, asthma, and kidney failure. The patient denied smoking and alcohol consumption prior to his complaint. No member of the family ever experienced a similar condition. There is also no autoimmune disease reported.

On presentation, the patient appeared highly alert. Blood pressure was 118/76 mmHg, temperature was 36.5°C, heart rate was regular with 96 beats/minute, respiratory rate was 16 breaths/minute, and oxygen saturation was 100% on room air. There was no additional heart sound, murmur, or gallop. No other abnormal findings were documented. His initial laboratory workup showed mild leukocytosis, with slightly lowered eosinophils and lymphocyte counts. Electrolyte indicators were within the normal range. Chest X-ray revealed no abnormalities within the heart and lungs.

We recorded serial electrocardiographs. The first one was obtained immediately after admission, demonstrating sinus rhythm with an 85 beats/minute rate, normal axis and p wave, PR interval was 0.16 s and elevated ST in leads II, III, and aVF. The results indicated a possibility of ST elevation myocardial infarction, with differential diagnosis of pericarditis and myocarditis. Figure 1 described the evolution of electrocardiograph. Serial electrocardiograph was recorded every 6 hours and then every 24 hours until discharge. To confirm the diagnosis, we performed coronary angiography on the day of admission which resulted in normal finding. Figure 2 showed the normal coronary angiography. Echocardiography demonstrated normal structure and function of the heart and the coronary. From these findings, ST elevation myocardial infarction became unlikely. We documented cardiac MRI. The findings included normal function of the left ventricle with an ejection fraction of 74.9% and overall normal wall movement, normal function of the right ventricle, no indication of pericardial thickening, and no pathological intensity of the myocardium. Figure 3 documented normal cardiac MRI. He was started on ibuprofen to help alleviate the possible inflammation.

The overall normal investigation results lead to a high index suspicion of Prinzmetal angina. He was continued on ibuprofen. After the clinical manifestations diminished, he was discharged. We prescribed him sublingual isosorbide dinitrate in case of recurring chest pain. We also educated him to avoid precipitating factors, such as smoking, alcohol consumption, activities resulting in causing hyperventilation, Valsava manoeuvre, and mental stress.¹ On 1-year follow-up, there was no recurrent angina. He had no limitation on doing activity. Electrocardiography showed normal findings as shown in Figure 4.

© The Author(s), 2024. Published by Cambridge University Press.



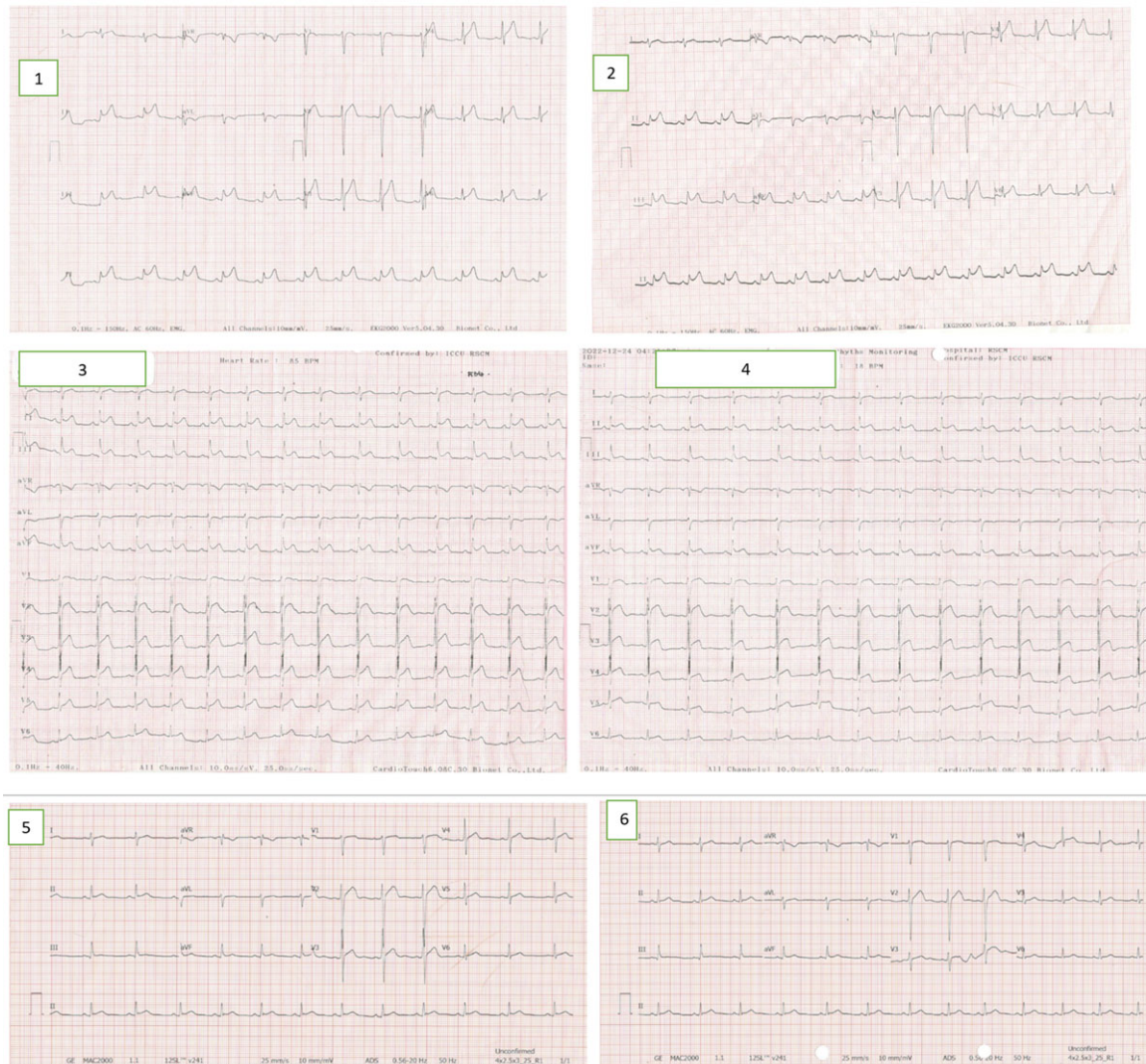


Figure 1. Serial electrocardiogram findings. Early ECG recordings (1–2) show typical ST elevation on the inferior lead, and the subsequent ECG (3–6) appear normal progressively. ECG, electrocardiograph.

Discussion

Prinzmetal angina is an uncommon variant of angina, even in adults. Vasospasm has been accused of being the underlying pathology. Its current population at risk are adults older than 50–60 years of age.³ Nonetheless, there have been reports of Prinzmetal angina in young adults.^{3,4} Smoking and specific comorbidities—migraine, Raynaud’s phenomenon—are thought to increase risks of vasospasm.¹ Additionally, certain discussions hypothesise that bronchial asthma could induce vasospasm in adolescents based on their pathogenesis similarities.⁴ Hyperventilation, Valsava manoeuvre, mental stress, and alcohol consumption precipitate vasospasm.¹ In the case of our patient, he did not have a history of smoking or alcohol consumption prior to the chest pain. He also denied any kind of comorbidities, including bronchial asthma.

The Coronary Vasomotor Disorders International Study Group (COVADIS) defines three criteria for vasospastic angina diagnosis in adults, including (1) classical clinical manifestations, (2) proof of spontaneous myocardial ischaemia,

and (3) documentation of vasospasm.⁵ Suspicion of vasospastic angina could be made out of the presence of resting angina.² However, chest pain in adolescents usually directs paediatric cardiologists to begin evaluating for inflammation until proven otherwise, for example, myocarditis.³ Our patient had chest pain 2 days in a row. We conducted a similar approach on our patient and initially put him on ibuprofen. To put into consideration, at times, the cases could be even more complicated since not all patients had chest pain as the chief complaint. Some patients might present with unrelated or no complaints but have already suffered from complications.³

As well as in most cases, our patient presented with ischaemic electrocardiogram changes, notably a symmetrically peaked T wave followed by ST elevation. The changes would normalise progressively alongside complaints improvement.^{1–3} Provocative coronary angiography using acetylcholine, ergonovine, or methylergonovine remains the gold standard for diagnosing.¹ However, due to limited resources, we did not perform chemical provocation during the procedure.

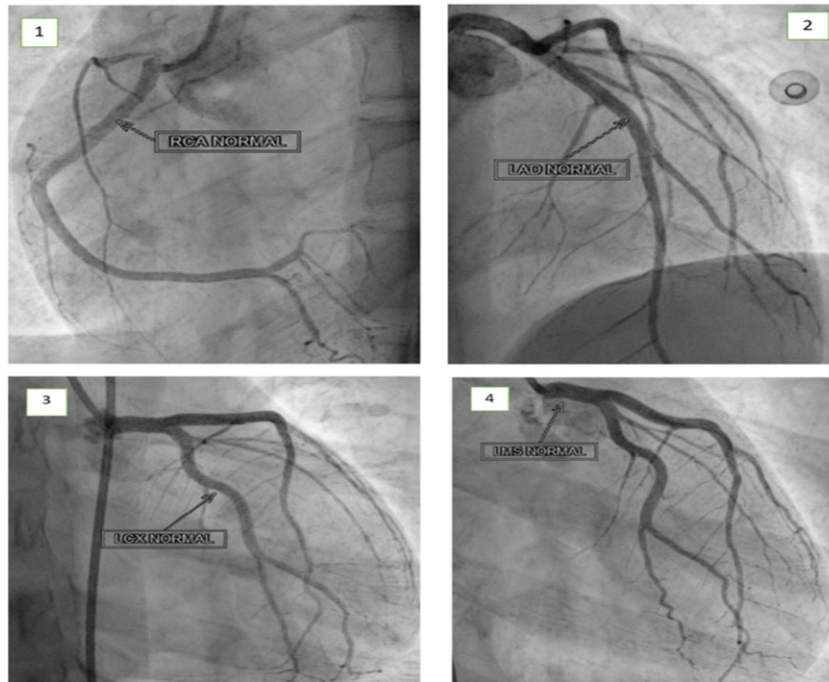


Figure 2. Coronary angiography reveals normal vessels in the right coronary artery (1), left anterior descending artery (2), left circumflex artery (3), and left main coronary artery (4).

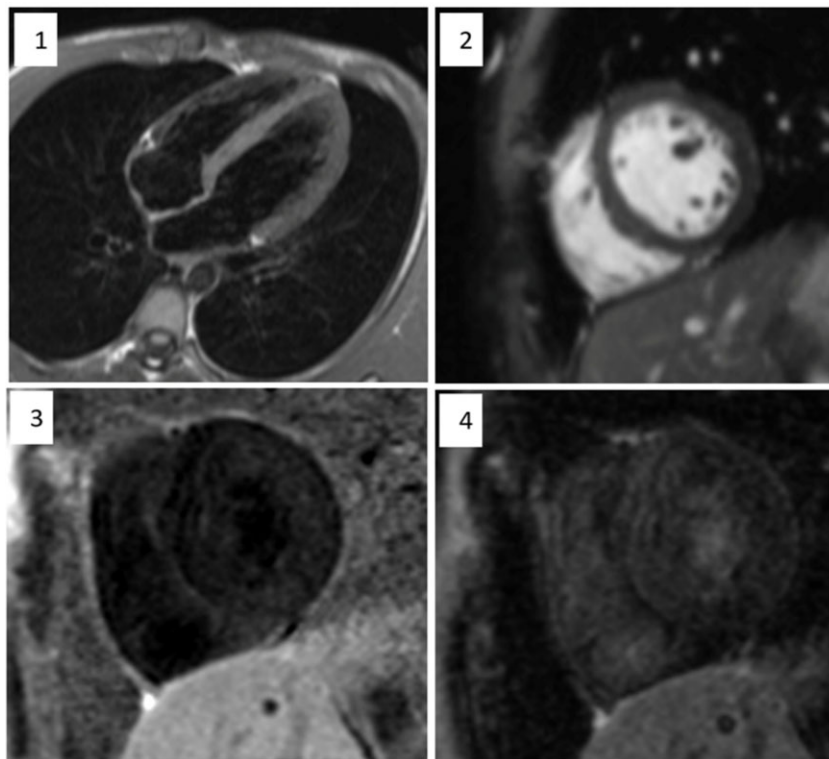


Figure 3. A cardiac MRI was performed, including a four-chamber view using the T2-weighted inversion recovery (TIRM) sequence (1) and short-axis imaging with the true fast imaging with steady precession (True FISP) technique (2). The results revealed no evidence of pericardial thickening. Additionally, post-administration of gadolinium, the short-axis imaging (3 and 4) exhibited no delayed enhancement in the myocardial wall, indicating a normal myocardial perfusion.

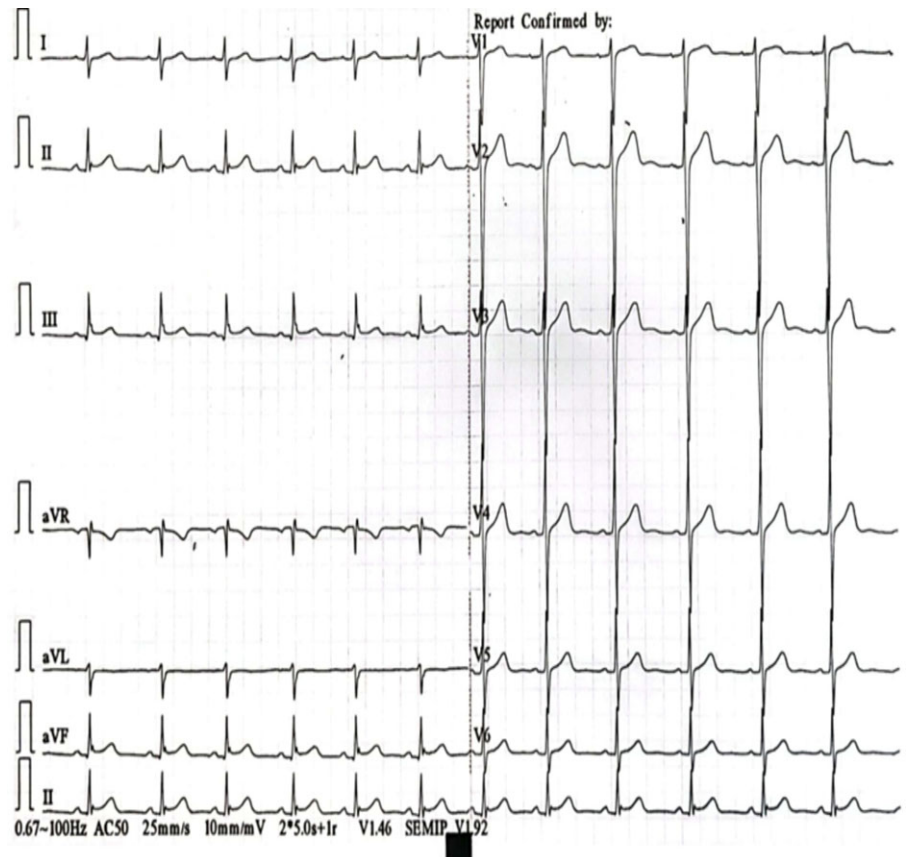


Figure 4. Normal ECG on 1-year follow-up. ECG, electrocardiograph.

Diagnosing Prinzmetal angina remains a challenge in paediatric cardiology for its indistinctive complaint. However, there have been several diagnoses recorded in young adults. Therefore, despite its low incidences, Prinzmetal angina should be considered in young adults with resting chest pain and overall normal findings.

Acknowledgements. The authors thank Kamilia Rifani Ufairah for her assistance in composing the report.

Financial support. None.

Competing interests. None.

References

1. Picard F, Sayah N, Spagnoli V, Adjedj J, Varenne O. Vasospastic angina: a literature review of current evidence. *Arch Cardiovasc Dis* 2019; 112: 44–55.
2. de Luna AB, Cygankiewicz I, Baranchuk A., et al. Prinzmetal angina: ECG changes and clinical considerations: a consensus paper. *Ann Noninvasive Electrocardiol* 2014; 19: 442–453.
3. Sueda S. Young vasospastic angina patients less Than 20 Years old. *Circ J* 2019; 83: 1925–1928.
4. Baghdasaryan L. A 16-year-old boy with bronchial asthma and prinzhmetal angina: case report. *Eur Hear J* 2018; 2: 1–5.
5. Beltrame JF, Crea F, Kaski JC, et al. International standardization of diagnostic criteria for vasospastic angina. *Eur Hear J* 2017; 38: 2565–2568.