

Clinical Records

Post-traumatic cutaneous meningioma

PEIJN A. BORGGREVEN, M.D., FLORIS H. DE GRAAF, M.D.*, PAUL VAN DER VALK, M.D., PH.D.†, C. RENÉ LEEMANS, M.D., PH.D.

Abstract

Cutaneous meningiomas are extremely rare tumours and their diagnosis is difficult. We describe the case of a patient who developed a paranasal swelling after head trauma and associated fractures in the same region years before. Histopathological examination of an incisional biopsy revealed the diagnosis of cutaneous meningioma. After one and a half years' follow up, surgical excision was performed because of progressive growth of the tumour and associated aesthetic problems. Extracranial meningiomas can develop probably secondary to trapping of meningeal tissue after trauma. If there is no intracranial connection surgical removal can be considered.

Key words: Meningioma; Face; Orbital Fractures

Introduction

Meningiomas are usually intracranial neoplasms. Extracranial meningiomas are uncommon and only a few cases have been sporadically reported in the literature.^{1–10} We describe a case of cutaneous meningioma probably due to post-traumatic trapping and discuss the histopathological findings, differential diagnosis and management.

Case report

A 68-year-old female presented to the otolaryngology service with a progressive paranasal swelling on the right side, which had existed for 14 years. The tumour began following a right orbital fracture extending into a skull base fracture complicated by an epidural haematoma, which was evacuated by operation (Figure 1). Notably, five years earlier she had consulted a general surgeon who partially excised the tumour. Histopathology did not show a conclusive diagnosis, but there was no evidence of malignancy. Because of continuing slow growth of the tumour after that operation and fear of a malignancy, she sought further medical advice.

Physical examination revealed a subcutaneous, firm paranasal tumour just beneath the right lower eyelid (Figure 2). Nasal examination was normal. Neurological examination showed no cranial nerve palsies nor specific ophthalmological abnormalities. There was no evidence of cervical adenopathy on palpation.

Magnetic resonance imaging (MRI) and a computed tomographic (CT) scan showed a sharply delineated paranasal mass on the right with some calcification but without any evidence of intracranial connection or bony defect (Figure 3). Fine needle aspiration did not yield a conclusive diagnosis. Therefore an incisional biopsy was

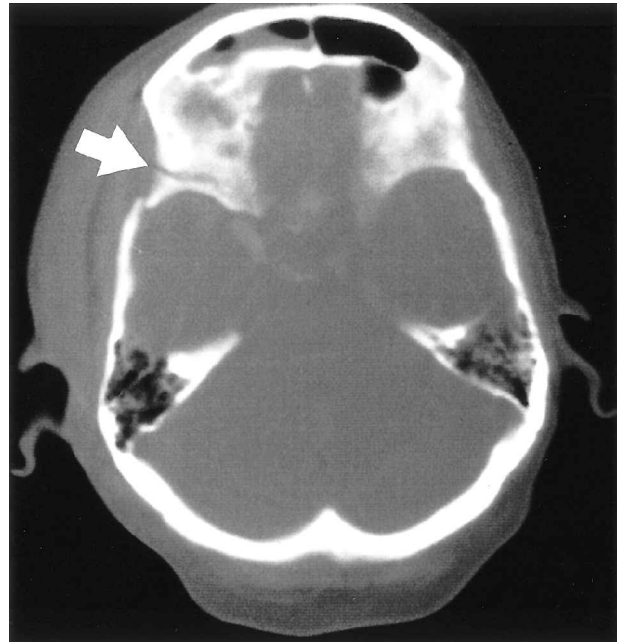


FIG. 1

CT scan. Non-contrast-enhanced axial CT image. Skull base fracture line (arrow).

performed. The histopathological findings are shown in Figure 4. Histologically the lesion showed a pattern consisting of whorls of round to oval-shaped meningothelial cells mixed with spindle-shaped cells and variable

From the Departments of Otolaryngology – Head and Neck Surgery, Plastic Surgery*, and Pathology†, VU Medical Centre, Amsterdam, The Netherlands.

Accepted for publication: 16 December 2003.

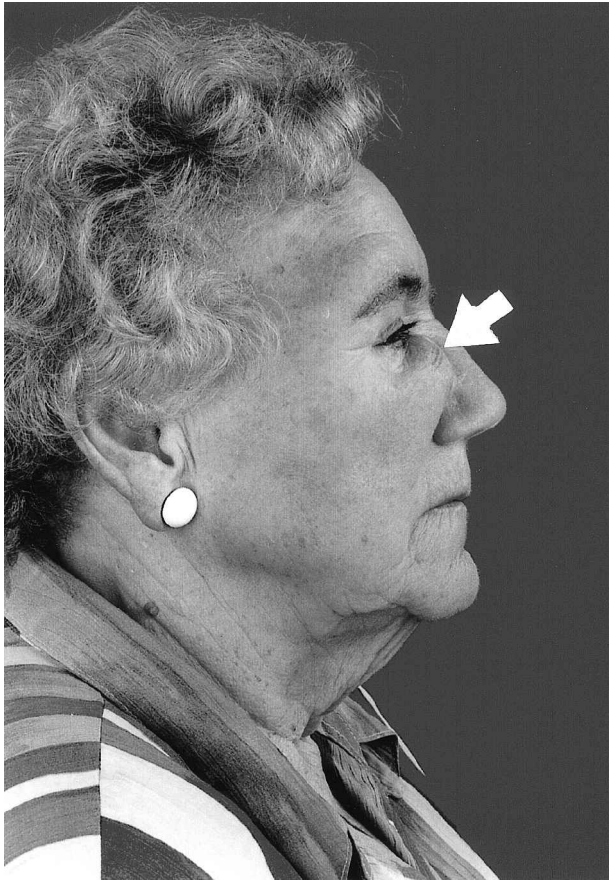


FIG. 2

Lateral photograph of the patient. Paranasal swelling on the right side (arrow).

numbers of psammoma bodies. It was diagnosed as a cutaneous meningioma. Initial conservative therapy was suggested and preferred by our patient. After one and a half years of follow up surgical excision was performed because of growth of the tumour and related aesthetic problems.

Discussion

Extracranial meningiomas are rare tumours. Of all meningiomas an incidence of one per cent for extracranial meningiomas, excluding spinal and orbital tumours, has been reported.^{1,2} Cutaneous meningiomas are the most common clinical manifestations of extracranial meningiomas in the head and the neck.³ They are derived from meningo-epithelial cells, and may be encountered in skin and soft tissue beyond the confines of the central nervous system.⁴ Based on several clinical-pathological reports over the last decades a classification into four groups can be made:

(1) Cutaneous meningiomas, which are derived from precursors of meningo-epithelial cells. During embryogenesis, these ectopic arachnoid cells are very likely to be displaced into the dermis and are primarily located in the subcutaneous tissue of the scalp or forehead but also in skin along suture lines and paravertebral areas.^{4,5} Often they are represented in epidermal cysts, neoplasms or areas of alopecia areata. Frequently an occult connection with the central nervous system exists that normally involutes but, if it persists, leakage of spinal fluid can

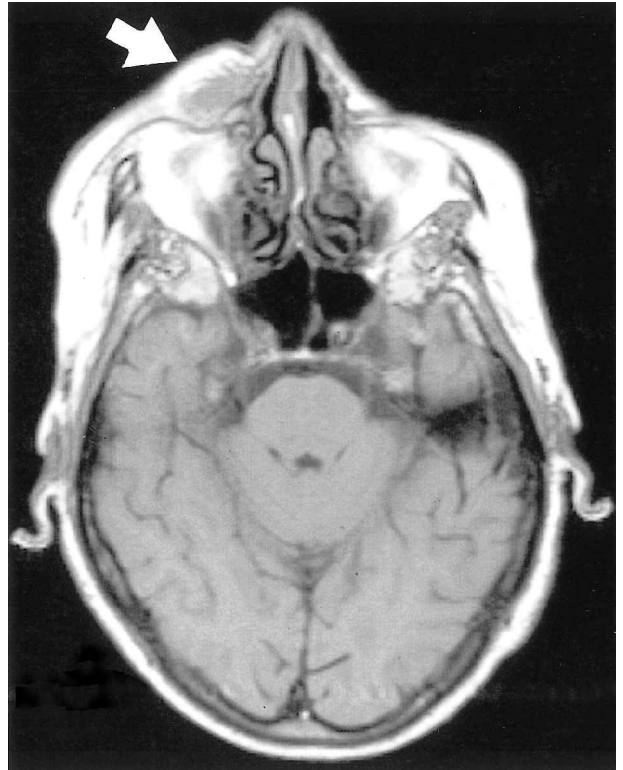

FIG. 3

MRI scan. T1-weighted axial MRI image with a 2-cm-diameter subcutaneous paranasal mass (arrow) without bone defects.

occur especially at the time of surgical exploration. This group of meningiomas is defined as primary cutaneous meningiomas.

(2) Cutaneous meningiomas, which develop out of ectopic cells distributed around sensory organs especially localized along cranial and spinal nerves. Sites of predilection are the orbital, nasal and, in some cases, auricular region. In contrast to primary cutaneous meningiomas these lesions are acquired and manifest principally at any age.⁵

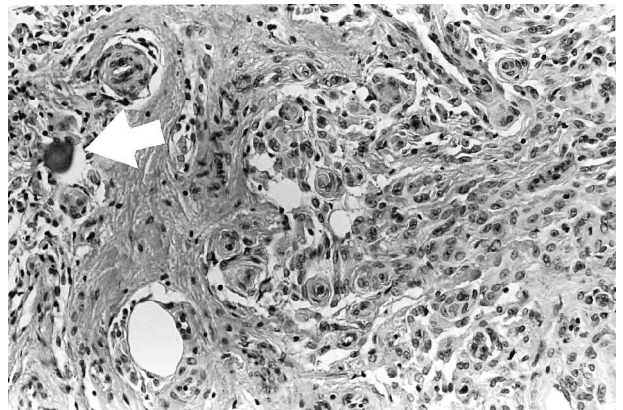


FIG. 4

Histological characteristics. Pattern consisting of whorls of round to oval shaped meningothelial cells mixed with spindle-shaped cells and a psammoma body (arrow) (H&E; ×25).

(3) Intracranial meningiomas that spread through the foramina or extend through post-traumatic lesions and old operative defects into adjacent subcutaneous and skin areas.⁵ Typically, these lesions are often accompanied by intracranial tumours shown on supplementary imaging. In addition, extension of extracranial meningeal tissue by post-traumatic trapping secondary to disruption of the craniofacial bony structure has been postulated sporadically.⁷

- **Cutaneous extracranial meningiomas are rare**
- **In this case report a lesion in the paranasal skin of a patient who had previously suffered an orbital and anterior skull base fracture was found to be a meningioma**
- **It is postulated that this was the result of meningeal tissue being sequestered at the time of injury**

(4) Finally dissemination in blood or lymphatic tissue by intracranial tumours with sarcomatous, haemangiopericytoma-like or papillary characteristics has been reported. This group of cutaneous meningiomas is also known as anaplastic (malignant) meningiomas.⁸

Histopathology and classification of meningiomas are difficult and complex, because of their different ways of manifestation. The most common form is the meningothelial type, with spindle cells, whorls of cells and sheets and nests of polygonal cells as distinguishing features. The whorl cells often show hyaline or calcification centres known as typical psammoma bodies, which are very helpful in the diagnosis. Less frequent are the fibroblastic, transitional, anaplastic and papillary type of which the latter two are clinically malignant. Many other variants have been described, but most are of interest only to the pathologist. Histological diagnostic support can be made by a positive immunohistochemical staining with vimentin, cytokeratin and epithelial membrane antigen (EMA).⁹

Differential diagnoses for heterotopic skin tumours, include meningoceles, meningomyeloceles and meningoencephalocoeles, nasal gliomas, neuroectodermal tumours, metastatic neuroblastomas and ganglioneuromas. Clinical features and essential CT and/or MRI are supporting but often not conclusive. Cytology or fine needle aspiration biopsy can be decisive but usually an incisional biopsy is necessary for distinction between these differential diagnostic options.¹⁰

If there is no indication of intracranial or intravertebral attachment the primary and neurocranial ectopic cell meningiomas can be treated in two ways; primarily conservatively, principally if there are no complaints nor side effects, or secondly, by radical excision depending on their localization, especially when there is neighbouring tissue compression or aesthetic problems. Expanding intracranial tumours accompanied by cutaneous meningiomas as well as metastatic lesions can be treated much less effectively than the aforementioned meningiomas, mainly

because of advanced stage at the time of presentation, or the underlying cerebral mass. If detected early, excision and, if necessary, additional treatment can be performed, but unfortunately palliative treatment is the only possible option in the majority of cases.

Cutaneous meningiomas of the head and neck are rare and difficult to identify. Our case can be classified as a post-traumatic entrapment meningioma (group 3). Notably the tumour can develop at any age and will often be presented to the surgeon after it has been present for a long time. A detailed history, especially for past head and neck trauma can be helpful in determining the final diagnosis. As long as there is no evidence of intracranial connection conservative therapy is an obvious option before surgical intervention is considered.

References

- 1 Whicker JH, Devine KD, McCarty CS. Diagnostic and therapeutic problems in extracranial meningiomas. *Am J Surg* 1973;**123**:452–7
- 2 Farr HW, Gray Jr, Vrana M, Panio M. Extracranial meningioma. *J Surg Oncol* 1973;**5**:411–20
- 3 Lopez DA, Silvers DN, Helwig EB. Cutaneous meningiomas: a clinicopathological study. *Cancer* 1974;**34**:728–44
- 4 Sibley DA, Cooper PH. Rudimentary meningocele: a variant of primary cutaneous meningioma. *J Cutaneous Pathol* 1989;**16**:72–80
- 5 Ragoowansi R, Thomas V, Powell BWEM. Cutaneous meningioma of the scalp: a case report and review of literature. *Br J Plast Surg* 1998;**51**:402–4
- 6 Friedman CD, Constantino PD, Teitelbaum BS, Berkold RE, Sisson GA. Primary extracranial meningiomas of the head and neck. *Laryngoscope* 1990;**100**:41–8
- 7 Walters GA, Ragland RL, Knorr JR, Malhotra R, Gelber ND. Post-traumatic cutaneous meningioma of the face. *Am J Neuroradiol* 1994;**15**:393–5
- 8 Mackay B, Bruner JM, Luna MA, Guilamondegui OM. Malignant meningioma of the scalp. *Ultrastruct Pathol* 1994;**18**:235–40
- 9 Gelli MC, Pasquinelli G, Martinelli G, Gardini G. Cutaneous meningioma: histochemical, immunohistochemical, ultrastructural investigation. *Histopathology* 1993;**23**:576–8
- 10 Kalfa M, Daskalopoulou D, Markidou S. Fine needle aspiration (FNA) biopsy of primary cutaneous meningioma: report of two cases. *Cytopathology* 1999;**10**:54–60

Address for correspondence:

Pepijn A. Borggreven, M.D.,
Department of Otolaryngology – Head and Neck Surgery,
VU Medical Centre,
P.O. Box 7057,
1007 MB, Amsterdam, The Netherlands.

Fax: +31 20 4443688

E-mail: pa.borggreven@vumc.nl

P. A. Borggreven takes responsibility for the integrity of the content of the paper.

Competing interests: None declared
