

## Submaxillary hypoglossal neurilemmoma

SEMIH SUTAY, M.D.\*, BULENT TEKINSOY, M.D.\*\*\*, KERIM CERYAN, M.D.\*, YAVUZ AKSU, M.D.† (Izmir, Turkey)

### Abstract

Neurilemmomas of the hypoglossal nerve are uncommon neoplasms. A unique case of submaxillary hypoglossal neurilemmoma is presented with radiological and surgical results. Methods of diagnosis and differential diagnosis are discussed.

**Key words:** Neurilemmoma; Hypoglossal nerve; Radiology

### Introduction

Neurilemmomas developing on cranial nerves containing only motor nerve fibres are extremely rare (Bastakis, 1974). In his discussion of 35 cases Odake (1989) stated that most of the neurilemmomas of the XIIth nerve originate from the intracranial portion, but they may extend extracranially. Of the cases he reviewed, five were clearly cases of neurofibromatosis and 23 out of the remaining 30 were entirely intracranial and seven, including his case, were dumbbell-shaped with both intra- and extracranial components.

Neurilemmomas originating from the extracranial portion of the hypoglossal nerve attract more sporadic attention. McCurdy *et al.* (1976) reported the fourth case occurring in the parapharyngeal space.

To our knowledge the case we present is the first one to be reported occurring in the submaxillary region.

### Case report

A 32-year-old male presented with a history of a slowly growing mass beneath the jaw on the left side. On physical examination a cystic mass was noted in the left submaxillary triangle. Bimanual palpation revealed its extension into the floor of mouth on the same side. Mild atrophy of the left half of the tongue was also noted. Computerized tomography (CT) and magnetic resonance imaging (MRI) showed circumscribed, sharply margined, thick-walled, homogeneous cystic lesions with internal septa formation (Figure 1 a, b, c.).

External surgical approach for the excision of the mass was performed. The submandibular gland and the tumour lying beneath were exposed and the hypoglossal nerve was identified as it crossed the carotid arteries. The nerve was followed anteriorly with blunt dissection, and its relationship with the tumour was demonstrated. The nerve was sacrificed because it

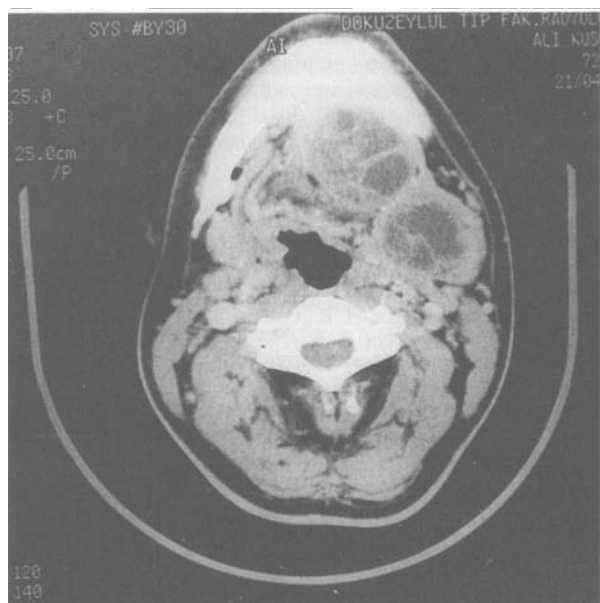

FIG. 1a

CT scan showing tumour in the left submaxillary triangle.

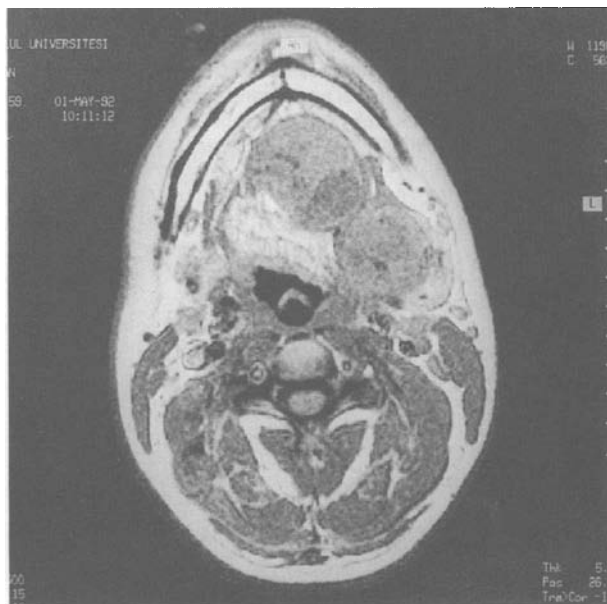

FIG. 1b

T1 dominated appearance of the tumour in MRI.

From the Department of Otolaryngology\*, Radiology\*\* and Pathology†, Dokuz Eylul University Medical School.  
Accepted for publication: 14 May 1993.

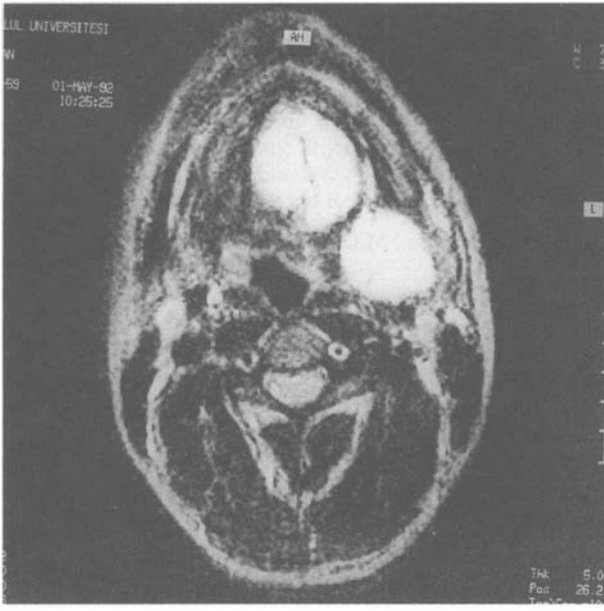

FIG. 1c

Proton density appearance of the tumour in MRI.

was not possible to dissect it from the tumour and then the mass was totally excised. The post-operative period was uneventful.

Histopathological examination revealed a neurilemmoma containing both Antoni A type tissue with interwoven bundles of long, bipolar, spindle cells, and Antoni B type tissue with its loose texture. Nuclear palisading in some areas was also typical (Figure 2).

### Discussion

Beyond the base of skull, lesions of the XIIth nerve produce a peripheral paralysis, usually without associated cranial neuropathies. Often there is a history of mechanical trauma or surgery. There may also be a coexisting mass in the submaxillary triangle (Rontal and Rontal, 1982).

A variety of congenital, inflammatory, and neoplastic processes may be encountered in the region of the suprahyoid neck and floor of the mouth (Coit *et al.*, 1987). A malignant neoplasm and a secondary hypoglossal nerve paralysis must be ruled out in the presence of hemiatrophy of the tongue. A tumour originating from the hypoglossal nerve must also be considered.

Coit *et al.* (1987) believe that critical evaluation of the cystic lesion occurring in the floor of mouth and suprahyoid neck allows differentiation in most cases. In those instances in which an exact diagnosis cannot be reached by radiological methods it is possible to define the extent of a lesion fully and to limit the differential considerations markedly.

By providing accurate anatomical detail, CT scanning can provide an outline of the precise boundaries of the cyst (Charnoff and Carter, 1986).

MRI with its improved soft-tissue contrast and ability to perform multiplanar imaging, is an appealing modality for the study of the head and neck. Direct coronal and sagittal image planes allow recognition of intrinsic tongue musculature and assessment of tumour volume and spread (Lufkin *et al.*, 1986). Therefore it is useful in determining the extent of the lesion and suggesting its nature.

In our case CT and MRI showed sharply marginated, thick-walled, homogeneous cystic lesions suggesting more a benign rather than a malignant process. Internal septa formation may be a significant finding which should remind us of neurilemmoma, but it is not possible to say that these findings are specific for neurilemmomas because of the very limited numbers of extracranial neurilemmomas reported.

We believe that total excision of the tumour *via* an external approach must be the treatment of choice. When a segment of a

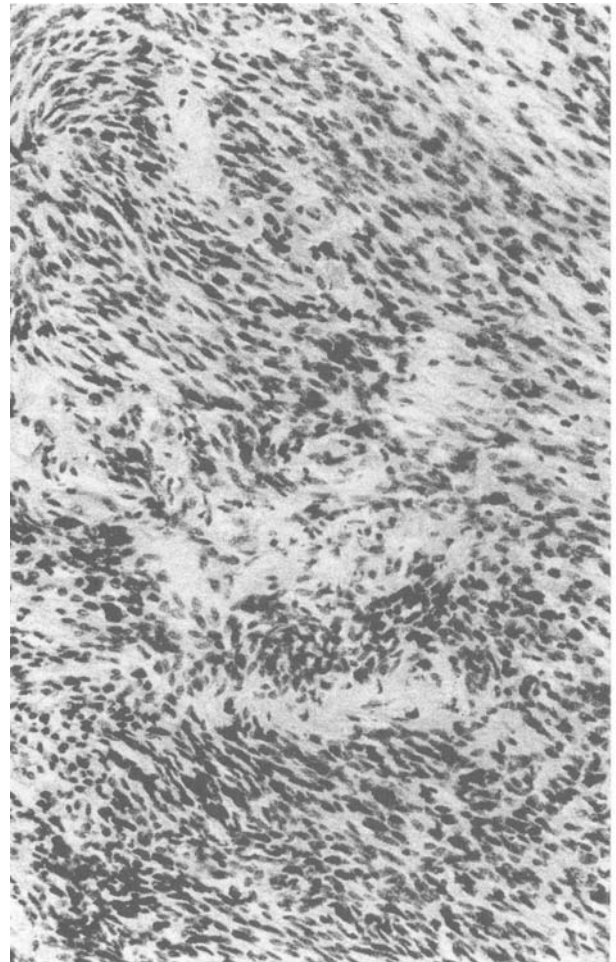


FIG. 2

Histological photograph showing neurilemmoma containing Antoni A and Antoni B tissue and palisading areas.

nerve must be excised for complete tumour removal, immediate reconstruction with nerve grafting should be performed. In the case we present reconstruction could not be carried out because it was not possible to identify distal branches of the nerve as a result of the lesion's extension into the tongue.

### References

- Batsakis, J. C. (1974) *Tumors of the Head and Neck*. Williams & Wilkins Co., Baltimore, pp. 231–249.
- Charnoff, S. K., Carter, B. L. (1986) Plunging ranula: CT diagnosis. *Radiology* **158**: 467–468.
- Coit, W. E., Harnsberger, H. R., Osborn, A. G., Smoker, W. R. K., Stevens, M. H., Lufkin, R. B. (1987) Ranulas and their mimics: CT evaluation. *Radiology* **163**: 211–216.
- Lufkin, R. B., Wortham, D. G., Dietrich, R. B., Hoover, L. A., Larson, S. G., Kangaroo, H., Hanafee, W. N. (1986) Tongue and oropharynx: findings on MR imaging. *Radiology* **161**: 69–75.
- McCurdy, J. A., Jr., Hays, L. L., Johnson, G. K. (1976) Parapharyngeal neurilemmoma of the hypoglossal nerve. *Laryngoscope* **86**: 724–727.
- Odake, G. (1989) Intracranial hypoglossal neurinoma with extracranial extension: review and case report. *Neurosurgery* **24**: 583–587.
- Rontal, E., Rontal, M. (1982) Lesions of the hypoglossal nerve—diagnosis, treatment and rehabilitation. *Laryngoscope* **92**: 927–937.

Address for correspondence:

Dr Semih Sutay,  
Dokuz Eylul Universitesi Tip Fakultesi,  
KBB Anabilim Dalı,  
35340 Inciralti Izmir,  
Turkey.