

## Laryngeal involvement in pemphigus vulgaris: a proposed classification

A MAHMOUD<sup>1</sup>, I D MIZIARA<sup>1</sup>, K C COSTA<sup>1</sup>, C G SANTI<sup>2</sup>, C W MARUTA<sup>2</sup>, V AOKI<sup>2</sup>

Departments of <sup>1</sup>ENT and <sup>2</sup>Dermatology, São Paulo University School of Medicine, Brazil

### Abstract

**Objective:** (1) To investigate the incidence of laryngeal involvement in a large series of patients with pemphigus vulgaris, using endoscopic examination, (2) to describe the lesions, and (3) to establish a classification of laryngeal involvement in pemphigus vulgaris based on the location of the lesions.

**Study design:** Prospective study.

**Methods:** A total of 40 sequentially treated pemphigus vulgaris patients, diagnosed using clinical, histological and immunofluorescence criteria, were evaluated for laryngeal manifestations using endoscopic examination. The results were used to establish a graded classification of laryngeal involvement according to the location of the lesions.

**Results:** Active laryngeal lesions (ulcers or blisters) were found in 16 patients (40 per cent). Of these, 37.5 per cent were classified as grade I, 20 per cent as grade II, 20 per cent as grade III and 17.5 per cent as grade IV.

**Conclusion:** Laryngeal involvement is common in pemphigus vulgaris and must be considered at the point of diagnosis. Grade I lesions are the most frequent.

**Key words:** Pemphigus; Larynx

### Introduction

Pemphigus vulgaris is an autoimmune bullous disease characterised by the development of intraepithelial blisters on the skin and/or mucosa secondary to immunoglobulin (Ig) G antibody synthesis against desmoglein, a desmosomal glycoprotein present in keratinocytes.<sup>1</sup>

Two clinical subtypes of pemphigus vulgaris have been defined. The mucosal form of pemphigus vulgaris is characterised by a predominant anti-desmoglein 3 autoimmune response. In contrast, the mucocutaneous form of pemphigus vulgaris shows a combined anti-desmoglein 3 and anti-desmoglein 1 autoantibody response.<sup>1</sup>

Laryngeal lesions due to pemphigus vulgaris are rarely reported, and the majority of such reports describe only the presence of such lesions, not their endoscopic location.<sup>1–6</sup>

It is important to note that pemphigus vulgaris is a very rare disease with an estimated incidence of 0.7 patients per 100 000. The mean age of patients at the time of disease presentation is 40–50 years. There is an increased incidence in Jewish individuals, especially Ashkenazic Jews, and Mediterranean populations.<sup>7,8</sup>

Generally, the mucosal lesions of pemphigus vulgaris precede the skin lesions. It is not uncommon for

the initial diagnosis of the disease to be made by an otolaryngologist, based on a biopsy of oral mucosa.<sup>9</sup>

The term pemphigus refers to a complex of diseases classified into six different types: (1) pemphigus foliaceus (erythematous, classic and endemic, also named ‘fogo selvagem’ or wild fire); (2) pemphigus vulgaris; (3) drug-induced pemphigus; (4) paraneoplastic pemphigus; (5) IgA pemphigus; and (6) herpetiform pemphigus (a clinical variant of either pemphigus vulgaris or foliaceus).

Endemic pemphigus foliaceus shares the same clinical, histological and immunological profile as the classic form; however, it shows unique epidemiological features, such as the presence of familial cases and a high prevalence in South America, especially Brazil.<sup>10</sup> This type of pemphigus has no involvement of the oral and upper airway mucosa, whereas pemphigus vulgaris does involve such mucosa.<sup>11</sup>

The most comprehensive study to date of laryngeal pemphigus vulgaris is a 2007 paper by España *et al.* describing laryngeal involvement in 16 patients undergoing ENT endoscopic examination.<sup>1</sup>

However, there is currently no uniform classification of laryngeal involvement in pemphigus vulgaris, particularly with regard to lesion characteristics and locations within the supraglottis and glottis.

Such classification is important as a guide for disease treatment. The presence of lesions in the larynx, for example, requires the use of more aggressive therapy because of the risk of acute respiratory failure.

In addition, the absence of a classification system, derived from proper endoscopic examination of a reasonable number of cases, makes it difficult to compare the various studies, and also to compare the incidence of laryngeal lesions in pemphigus vulgaris patients from different regions of the world.

Thus, the aims of our study were: (1) to investigate laryngeal involvement in a large series of patients with pemphigus vulgaris, using endoscopic ENT examination; (2) to characterise lesions according to their localisation within the larynx; and (3) to establish a classification of laryngeal involvement in pemphigus vulgaris based on the location of lesions.

To our knowledge, this is the first attempt to establish such a classification in a large series of cases.

### Materials and methods

A prospective study was conducted at the ENT outpatient unit of Hospital das Clinicas – São Paulo University Medical School over six years. This study was approved by the ethics commission at our institution (approval number 0465/08).

We included 40 sequentially treated patients with pemphigus vulgaris diagnosed by clinical, histological and immunofluorescence criteria, who were seen at either the ENT department or the dermatology department of the same institution. All patients had skin and/or oral cavity lesions.

All patients underwent endoscopic ENT examination, using a Ferrari Medicals (São Paulo, Brazil) halogen lamp light source (250 W) and either a flexible naso-pharyngo-laryngeal endoscope (Olympus 3.4 mm ENF type P4; Tokyo, Japan) or a rigid 70° laryngeal telescope (Storz Hopkins, Tuttlingen, Germany). Local anaesthesia was used, with topical application of 2 per cent tetracaine to the nose or 10 per cent lidocaine to the oral cavity. Patients underwent ENT endoscopic examination whether they complained of laryngeal symptoms or not. None of the patients in this study had received any kind of treatment prior to ENT evaluation.

The patients did not undergo laryngeal biopsy; rather, their diagnosis was confirmed from a biopsy of oral mucosa, as their laryngeal lesions were similar

TABLE II  
LARYNGEAL SYMPTOM INCIDENCE

Symptom	Patients (n (%))
Dysphonia	10 (25)
Throat pain	19 (47.5)
Pain on swallowing	23 (57.5)

to their oral cavity lesions. Fragments of oral mucosa were removed under local anaesthesia with 2 per cent xylocaine, and sent for histological examination and for direct immunofluorescence analysis.

A classification of laryngeal lesions was developed based on their location. Lesions were classified as grade I, II, III or IV, according to the number of sites affected. Grade I lesions involved only the epiglottis. Grade II lesions were situated on the supraglottis, with or without lesions on the epiglottis. Grade III lesions involved the piriform sinuses or ventricular folds, with or without grade I or II type lesions. Grade IV lesions involved the vocal folds, with or without other regions of the larynx. This classification system is summarised in Table I.

### Results and analysis

In our study females predominated over males, with respective proportions of 80 per cent ( $n = 32$ ) and 20 per cent ( $n = 8$ ). Patient age varied from 13 to 78 years, with a mean age of 46.35 years. Twenty-nine (72.5 per cent) patients had the mucocutaneous form of pemphigus vulgaris and 11 (27.5 per cent) had the mucosal form.

The incidence of laryngeal symptoms is shown in Table II. In total, 95 per cent of our patients had active lesions due to pemphigus vulgaris.

Table III shows the grading of the laryngeal lesions according to our suggested classification system. Lesions classified as grades I, II and III can be seen in Figures 1, 2 and 3, respectively. Five of the seven patients with vocal fold involvement had only corditis, while the other two had intact blisters (Figure 4). It is possible that some patients might have had subglottic lesions; however, such lesions are difficult to locate and we did not identify them in any of our patients.

### Discussion

Most of the information on laryngeal manifestations of pemphigus vulgaris has come from reports of

TABLE I  
PROPOSED CLASSIFICATION OF LARYNGEAL LESIONS

Grade	Location
I	Epiglottis
II	Supraglottis ± grade I lesions
III	Piriform sinuses & ventricular folds ± grade I and/or grade II lesions
IV	Vocal folds ± lesions of other grades

TABLE III  
LARYNGEAL LESION GRADE INCIDENCE

Grade	Patients (n (%))
I	15 (39.47)
II	8 (21.05)
III	8 (21.05)
IV	7 (18.42)

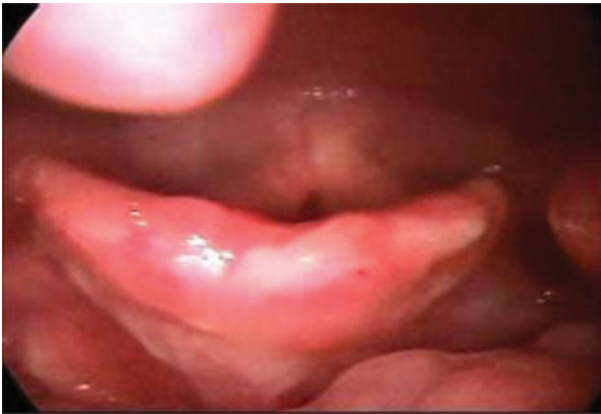

FIG. 1

Rigid laryngeal telescopic view showing active pemphigus vulgaris lesions on the epiglottis (grade I).

individual cases.<sup>3-6</sup> Only a few of the patients described in these reports underwent ENT evaluation, and reports of laryngeal lesions only describe their presence or absence. Our study is the first large series in which laryngeal lesions were reported according to their localisation in the larynx, and in which all patients with a diagnosis of pemphigus vulgaris underwent ENT endoscopic examination.

Almost half of our patients had experienced pharyngeal or laryngeal symptoms; however, upon endoscopic evaluation the proportion of these patients with active laryngeal lesions was approximately 95 per cent.

In España and colleagues' Spanish study of 16 pemphigus vulgaris patients examined via ENT endoscopy, active laryngeal lesions were found in 88 per cent ( $n = 14$ ) of their patients.<sup>1</sup> The majority of these authors' patients (67 per cent) had the mucocutaneous form of pemphigus vulgaris; similarly, 72.5 per cent of our study patients had the mucocutaneous form.

In Hale and colleagues' US study of 53 patients with pemphigus vulgaris, only 7 were submitted to ENT

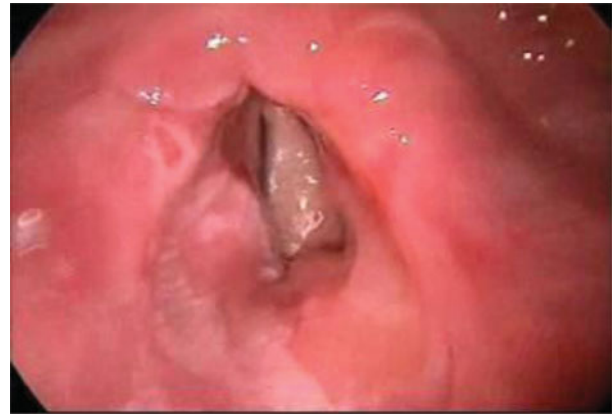

FIG. 3

Rigid laryngeal telescopic view showing active pemphigus vulgaris lesions on the laryngeal face of the epiglottis, right aryepiglottic fold and right ventricular fold (grade III).

endoscopic examination; of these 7, active laryngeal lesions were identified endoscopically in 57 per cent ( $n = 4$ ).<sup>2</sup>

In both the above studies, the authors only reported whether their patients had active lesions or not; the exact laryngeal location of lesions was not mentioned.

We found that grade I lesions (Figure 1) were the most common type of laryngeal lesion in our patients with pemphigus vulgaris. This high incidence of epiglottal lesions may be due to swallowed food causing frequent mucosal trauma at this site. It is also relevant that the histological structure of the supraglottic mucosa is similar to that of the oral cavity mucosa. This also explains why all of the grade II and III lesions were ulcers (see Figure 3), and why the majority (71.4 per cent) of patients with grade IV lesions had intact blisters on the vocal folds (see Figure 4).

The erosive and bullous lesions located in the larynx of patients with pemphigus vulgaris are sufficiently characteristic to enable an experienced ENT specialist to assess the damage caused by the disease.

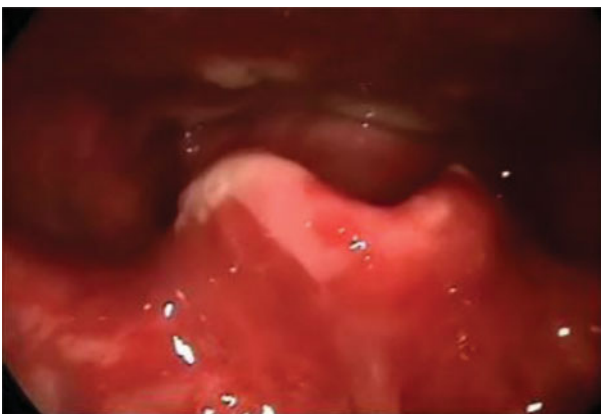


FIG. 2

Rigid laryngeal telescopic view showing active pemphigus vulgaris lesions on the epiglottis and right aryepiglottic fold (grade II).

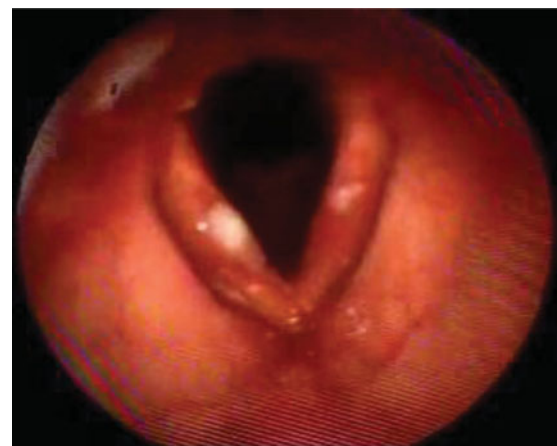

FIG. 4

Flexible naso-pharyngo-laryngeal endoscopic view showing intact blisters on both vocal folds (grade IV).

Therefore, in our study biopsy of oral mucosa or skin was considered sufficient to confirm the diagnosis of the disease, avoiding the need for biopsy of laryngeal lesions. In addition, all patients responded well to the treatment given (usually high-dose corticosteroids), confirming that their laryngeal lesions were due to pemphigus vulgaris.

The classification proposed in this paper has a clear objective: to grade the laryngeal involvement according to the extent and severity of lesions. This is important because it guides therapy: the higher the grade, the higher the corticosteroid dose that should be administered.

- **Laryngeal involvement of pemphigus vulgaris is common**
- **Knowledge of laryngeal involvement is important to improve treatment**
- **A lesion classification system is proposed based on laryngeal location**

Our classification system is not perfect. It does not include a grade for subglottic involvement; this is because these lesions are difficult to identify using endoscopic equipment. In order to describe such lesions with more precision, we recommend a bronchoscopic examination.

## Conclusion

Laryngeal involvement of pemphigus vulgaris is common and must be considered at the point of diagnosis. The supraglottic region is the most commonly involved, although involvement of the vocal folds can be present. Endoscopic examination is important in patients both with and without laryngeal symptoms, in order to enable examination of a greater area of mucosa and to guide therapy.

## References

- 1 Espana A, Fernandez S, del Olmo J, Marquina M, Pretel M, Ruba D *et al.* Ear, nose and throat manifestations in pemphigus vulgaris. *Br J Dermatol* 2007;**156**:733–7
- 2 Hale EK, Bystryk JC. Laryngeal and nasal involvement in pemphigus vulgaris. *J Am Acad Dermatol* 2001;**44**:609–11
- 3 Samy LL, Girgis IH, Wasef SA. Pharyngeal and laryngeal pemphigus. *J Laryngol Otol* 1968;**82**:111–21
- 4 Wallner LJ, Alexander RW. Pemphigus of the larynx. *Laryngoscope* 1964;**74**:575–86
- 5 Weinstein S, Sachs AR. Pemphigus of the oropharynx and larynx; report of a case. *AMA Arch Otolaryngol* 1955;**62**:214–17
- 6 Vasilou A, Nikolopoulos TP, Manolopoulos L, Yiotakis J. Laryngeal pemphigus without skin manifestations and review of the literature. *Eur Arch Otorhinolaryngol* 2007;**264**:509–12
- 7 Danczak-Pazdrowska A, Pazdrowski J, Bowszyc-Dmochowska M, Dmochowski M. Laryngeal lesions in mucosal dominant subtype of pemphigus vulgaris. *Otolaryngol Pol* 2007;**61**:509–12
- 8 Langan SM, Smeeth L, Hubbard R, Fleming KM, Smith CJ, West J. Bullous pemphigoid and pemphigus vulgaris – incidence and mortality in the UK: population based cohort study. *BMJ* 2008;**337**:a180
- 9 Mizziara ID, Ximenes Filho JA, Ribeiro FC, Brandão AL. Oral involvement in pemphigus vulgaris [in Portuguese]. *Rev Bras Otorrinolaringol* 2003;**69**:327–31
- 10 Aoki V, Huang MH, Périgo AM, Fukumori LM, Maruta CW, Santi CG *et al.* Endemic pemphigus foliaceus (fogo selvagem) and pemphigus vulgaris: immunoglobulin G heterogeneity detected by indirect immunofluorescence. *Rev Hosp Clin Fac Med Sao Paulo* 2004;**59**:251–6
- 11 Harman KE, Gratian MJ, Shirlaw PJ, Bhogal BS, Challacombe SJ, Black MM. The transition of pemphigus vulgaris into pemphigus foliaceus: a reflection of changing desmoglein 1 and 3 autoantibody levels in pemphigus vulgaris. *Br J Dermatol* 2002;**146**:684–7

Address for correspondence:

Dr Ali Mahmoud,  
Avenida Enéas de Carvalho Aguiar 155,  
6° Andar, Sala 06,  
Cerqueira César, São Paulo, SP,  
CEP 05403–900, Brazil

E-mail: alimahmoud79@gmail.com

---

Dr A Mahmoud takes responsibility for the integrity of the content of the paper

Competing interests: None declared

---