

REVIEW – STANDARD

Blood parasites of penguins: a critical review

RALPH ERIC THIJL VANSTREELS^{1*}, ÉRIKA MARTINS BRAGA² and JOSÉ LUIZ CATÃO-DIAS¹

¹ *Laboratório de Patologia Comparada de Animais Selvagens, Departamento de Patologia, Faculdade de Medicina Veterinária e Zootecnia, Universidade de São Paulo, Av. Prof. Dr. Orlando Marques de Paiva 87, São Paulo, SP 05508-270, Brazil*

² *Departamento de Parasitologia, Instituto de Ciências Biológicas, Universidade Federal de Minas Gerais, Caixa Postal 486, Avenida Antônio Carlos 6627, Pampulha, Belo Horizonte, MG 31270-901, Brazil*

(Received 12 December 2015; revised 7 January 2016; accepted 26 January 2016; first published online 13 April 2016)

SUMMARY

Blood parasites are considered some of the most significant pathogens for the conservation of penguins, due to the considerable morbidity and mortality they have been shown to produce in captive and wild populations of these birds. Parasites known to occur in the blood of penguins include haemosporidian protozoans (*Plasmodium*, *Leucocytozoon*, *Haemoproteus*), piroplamid protozoans (*Babesia*), kinetoplastid protozoans (*Trypanosoma*), spirochete bacteria (*Borrelia*) and nematode microfilariae. This review provides a critical and comprehensive assessment of the current knowledge on these parasites, providing an overview of their biology, host and geographic distribution, epidemiology, pathology and implications for public health and conservation.

Key words: blood parasite, bird, conservation, pathogen, seabird, vector-borne diseases.

INTRODUCTION

Diseases and parasites may adversely affect breeding success and lead to the mortality of penguins, potentially hampering the viability of their populations (Woods *et al.* 2009). Blood parasites are considered some of the most significant pathogens for the conservation of penguins (Brossy *et al.* 1999; Jones and Shellam, 1999b; Levin and Parker, 2011).

Since 1926, when Sir Henry Harold Scott first diagnosed avian malaria as the cause of death of a king penguin captive at the Zoological Society of London (Scott, 1927), a considerable body of literature has gradually accumulated on the blood parasites of penguins, with nearly a hundred publications. The concern that blood parasites could be a conservation threat emerges from the observation of the dramatic impacts of avian malaria outbreaks in captive penguins (e.g. Rodhain, 1939; Griner and Sheridan, 1967; Fix *et al.* 1988; Bueno *et al.* 2010), along with the existence of *Plasmodium* sp. infections in wild penguins (Fantham and Porter, 1944; Laird, 1950; Levin *et al.* 2009) as well as other potentially pathogenic blood parasites (Fallis *et al.* 1976; Jones and Woehler, 1989; Earlé *et al.* 1992; Argilla *et al.* 2013). There are a few documented cases of

mortality of wild penguins due to blood parasite infections (Fantham and Porter, 1944; Hill *et al.* 2010; Argilla *et al.* 2013; Cannell *et al.* 2013) and, because there are a number of mass mortality events of wild penguins for which the causes of death cannot be established (Gill and Darby, 1993; Kerry *et al.* 2009; Woods *et al.* 2009), the possibility that blood parasites play a role in some of these events cannot be dismissed.

In this review, we will provide a critical and comprehensive assessment of the state-of-the-art of blood parasites known to infect penguins, providing an overview of their biology, host and geographic distribution, epidemiology, pathology and implications for public health and conservation.

MATERIALS AND METHODS

This review addresses organisms that parasitize blood cells (haemosporidians and piroplasmids), as well as other organisms that can be detected in blood smears (kinetoplastids, spirochetes and nematode microfilariae). All records published in peer-reviewed journals until 01 January 2016 were considered; institutional reports, conference presentations and Ph.D. theses were included when they presented relevant data that could not be found in other peer-reviewed publications. A comprehensive list of the known records of blood parasites of penguins is provided in Appendix 1, and these data are summarized in Table 1. In light of novel evidence and critical consideration of the existing record, a

* Corresponding author: Laboratório de Patologia Comparada de Animais Selvagens, Departamento de Patologia, Faculdade de Medicina Veterinária e Zootecnia, Universidade de São Paulo, Av. Prof. Dr. Orlando Marques de Paiva 87, São Paulo, SP 05508-270, Brazil. E-mail: ralph_vanstreels@yahoo.com.br

Table 1. Summary of blood parasites recorded in each penguin species

Penguin species	<i>Plasmodium</i>	<i>Leucocytozoon</i>	<i>Haemoproteus</i>	<i>Babesia</i>	<i>Trypanosoma</i>	<i>Borrelia</i>	Microfilariae
<i>Aptenodytes forsteri</i> (Emperor)							
<i>Aptenodytes patagonicus</i> (King)	C					W	
<i>Eudyptes chrysocome</i> (Southern rockhopper)	C						
<i>Eudyptes chrysolophus</i> (Macaroni)	C	C					
<i>Eudyptes moseleyi</i> (Northern rockhopper)	W						
<i>Eudyptes pachyrhynchus</i> (Fiordland)		W, R					
<i>Eudyptes robustus</i> (Snares)	W						
<i>Eudyptes schlegeli</i> (Royal)							
<i>Eudyptes sclateri</i> (Erect-crested)							
<i>Eudyptula minor</i> (Little)	W, C	C, E		W	W		
<i>Megadyptes antipodes</i> (Yellow-eyed)	W	W					
<i>Pygoscelis adeliae</i> (Adélie)							
<i>Pygoscelis antarcticus</i> (Chinstrap)	C						
<i>Pygoscelis papua</i> (Gentoo)	C						
<i>Spheniscus demersus</i> (African)	W, R, C	R		W, R		W, R	
<i>Spheniscus humboldti</i> (Humboldt)	C		W				
<i>Spheniscus magellanicus</i> (Magellanic)	R, C						
<i>Spheniscus mendiculus</i> (Galapagos)	W		W				W

Records were classified according to the context in which the diagnosis was established: W, penguins sampled in the wild; R, penguins undergoing rehabilitation; C, penguins captive in zoos; E, penguins infected under experimental conditions.

number of records were revised or were considered inconclusive or questionable; detailed remarks on these cases are provided in Appendix 2. It is worth noting that *Aegyptianella* sp. was considered within the scope of this review, but was not included because it has not yet been conclusively demonstrated to infect penguins (see Appendix 2).

Figure 1 presents a hand-drawn summary of the parasites that can be found in the blood of penguins; these drawings were based on the descriptions and illustrations provided by Fallis *et al.* (1976), Jones and Woehler (1989), Earlé *et al.* (1993), Merkel *et al.* (2007), Yabsley *et al.* (2012), Silveira *et al.* (2013) and Vanstreels *et al.* (2014a, 2015a, b). This figure is not meant as an identification plate, but an illustration of the variations in size and shape of each parasite group. *Haemoproteus* sp. was not included in Fig. 1, because it has not yet been observed in blood smears of penguins. It is possible that *Leucocytozoon* spp. form elongated gametocytes when infecting penguin leukocytes, as occurs in

other hosts (Valkiūnas, 2005); however, these parasite forms were never documented in penguins and therefore were not represented in Fig. 1.

To evaluate if there are regions where blood parasites could infect penguins but have yet to be recorded, we juxtaposed the distribution of penguin breeding colonies (IUCN, 2015) with that of records of blood parasites in penguins and of their confirmed or suspected invertebrate hosts/vectors (Figs 2 and 3). The distribution of the following invertebrate hosts/vectors is represented: seabird soft ticks (*Argas* spp., *Carios* spp.) (Dietrich *et al.* 2011), seabird hard ticks (*Amblyomma loculosum*, *Ixodes* spp.) (Barbosa *et al.* 2011; Dietrich *et al.* 2011; Muñoz-Leal and González-Acuña, 2015), biting midges (*Culicoides* spp.) (Murray, 1975; Spinelli and Martínez, 1991; Tabachnick, 2004; Aybar *et al.* 2010; Guichard *et al.* 2014), black flies (*Austrosimulium* spp., *Cnephia* spp., *Prosimulium* spp., *Simulium* spp.) (Dumbleton, 1963; Hill *et al.* 2010; Argilla *et al.*

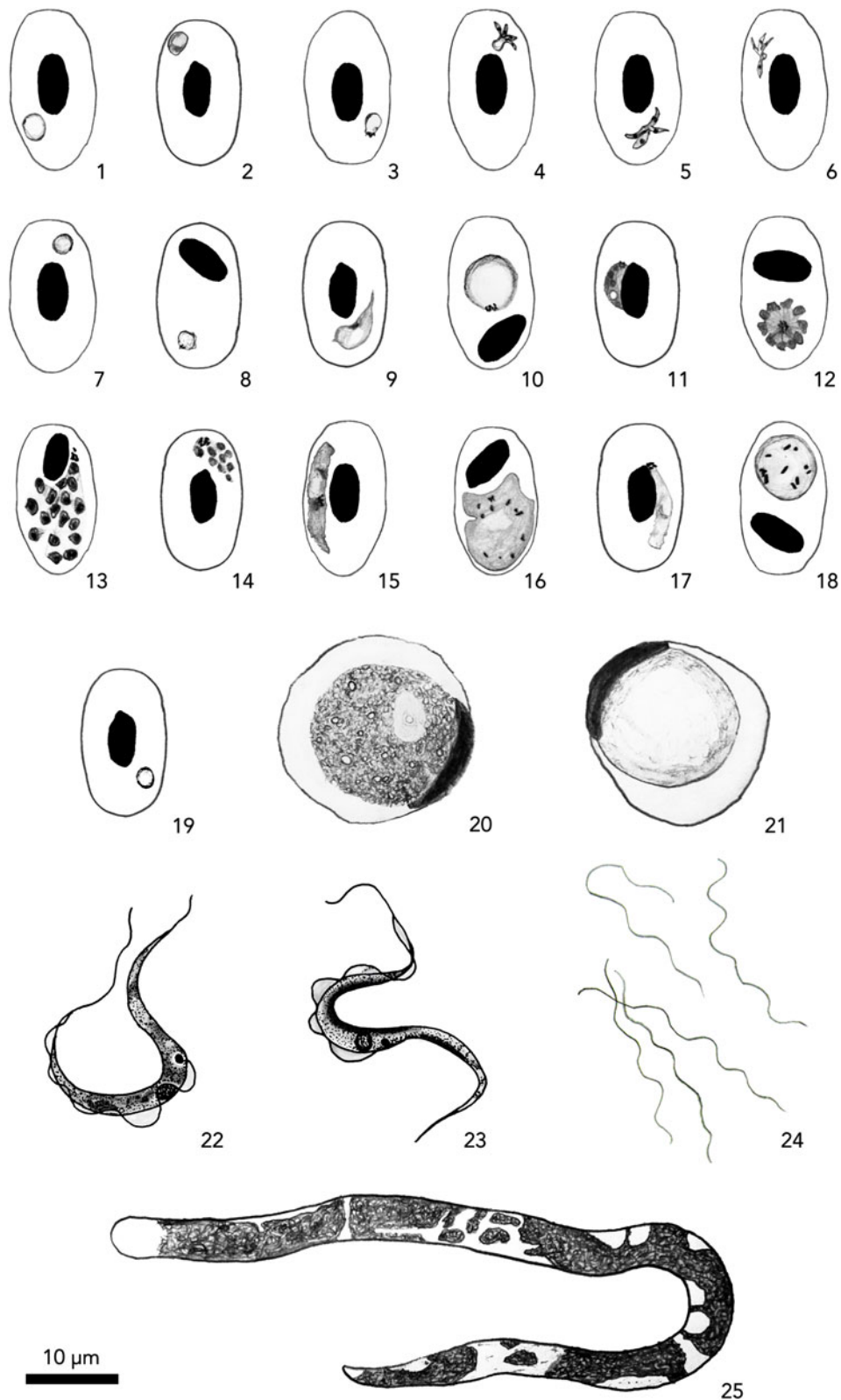


Fig. 1. Overview of the morphology of blood parasites of penguins: *Babesia peircei* (round forms = 1–3, tetrameric forms = 4–6), *Plasmodium* spp. (trophozoites = 7–8, young gametocytes = 9–10, meronts = 11–14, macrogametocytes = 15–16, microgametocytes = 17–18), *Leucocytozoon tawaki* (young gametocyte = 19, round macrogametocyte = 20, round microgametocyte = 21), *Trypanosoma eudyptulae* (trypomastigotes = 22–23), Relapsing Fever *Borrelia* (24), nematode microfilaria (25).

2013), *Culex* mosquitoes (*Culex pipiens*, *Culex quinquefasciatus*, *Culex pervigilans*) (White, 1989; WRBU, 2014), saltwater mosquito (*Ochlerotatus*

australis) (Holder, 1999; Snell, 2005; Landcare Research, 2015) and black salt marsh mosquito (*Aedes taeniorhynchus*) (WRBU, 2014).

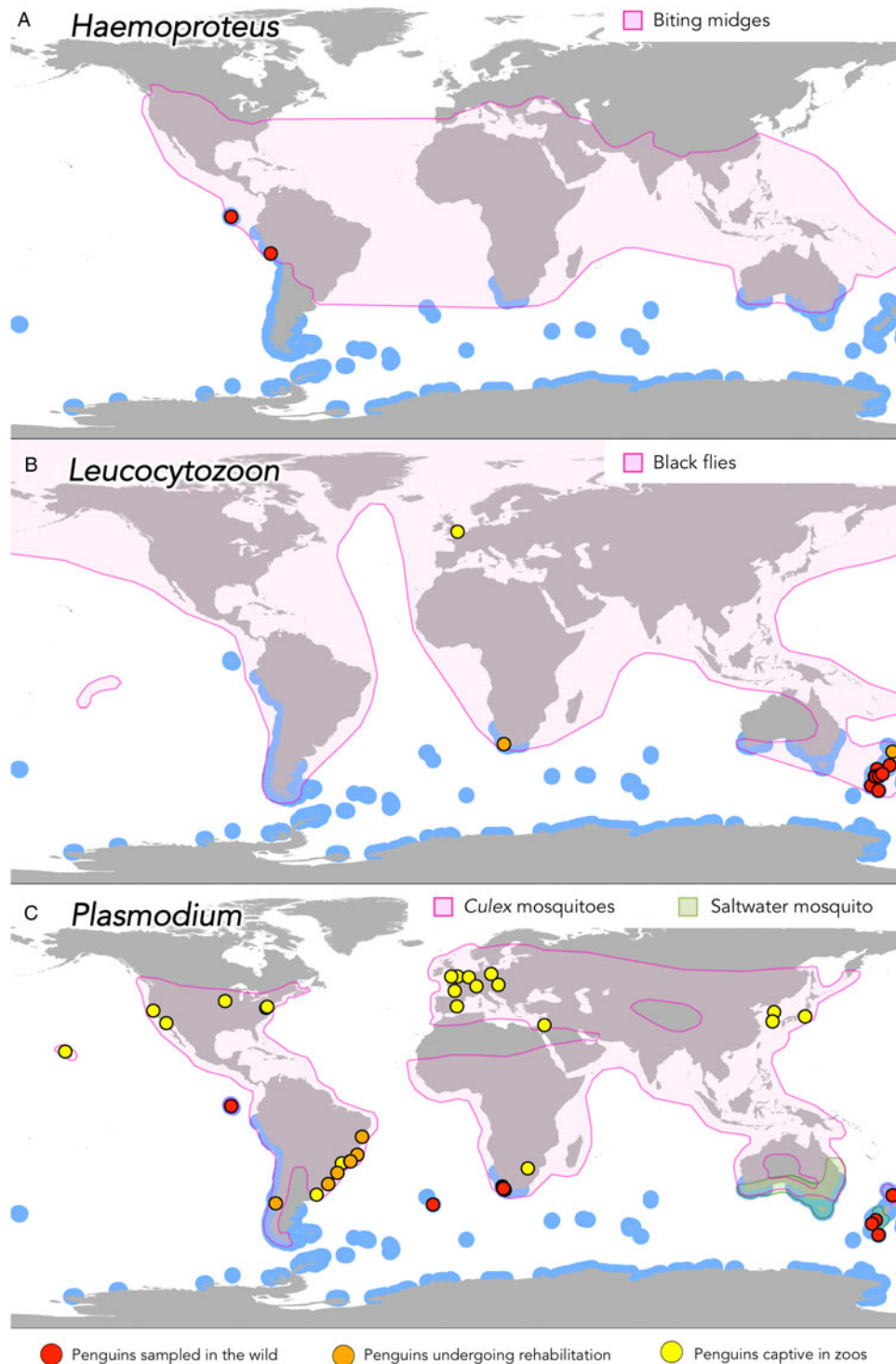


Fig. 2. Geographic distribution of records of haemosporidian blood parasites in penguins in relation to their invertebrate hosts. Blue areas represent the breeding distribution of penguins.

PLASMODIUM (AVIAN MALARIA)

Plasmodium spp. (Haemosporida: Plasmodiidae) are parasites of all tetrapod classes. More than 60 avian-infecting species have been described in five subgenera: *Bennettinia*, *Giovannolaia*, *Haemamoeba*, *Huffia* and *Novyella* (Valkiūnas, 2005; Martinsen and Perkins, 2013). In the avian blood, these parasites can be found in the cytoplasm of erythroblasts and erythrocytes (and occasionally thrombocytes,

see Silveira *et al.* 2009) in the form of trophozoites, erythrocytic meronts or gametocytes (Fig. 1); haemozoin granules are present. In the avian tissues, these parasites will invade endothelial cells and macrophages; megalomeronts are absent (Valkiūnas, 2005).

Species recorded in penguins

Five species of *Plasmodium* have been demonstrated to infect penguins through both morphological and

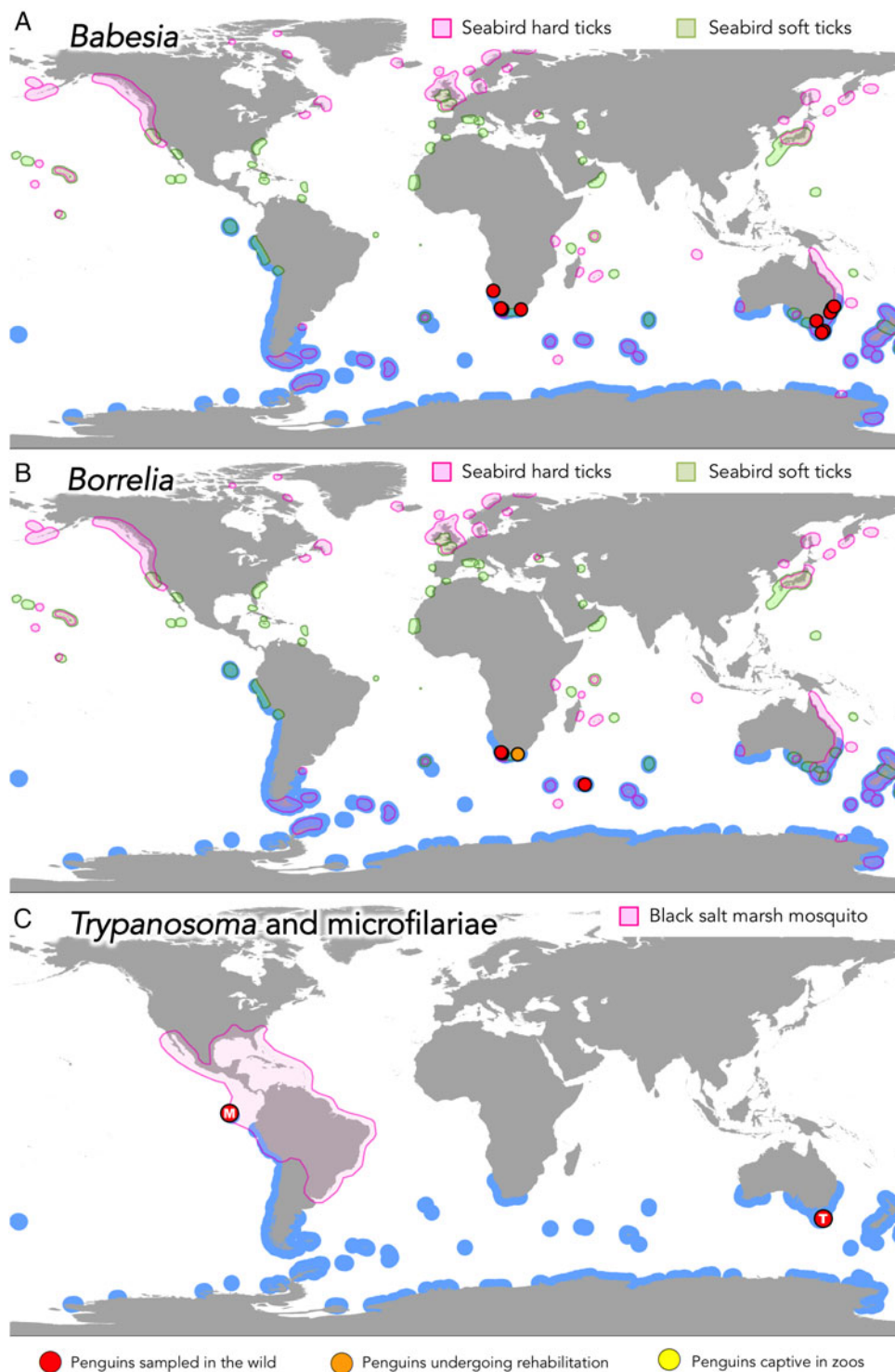


Fig. 3. Geographic distribution of records of non-hemosporidian blood parasites in penguins in relation to their confirmed or presumed vectors. Blue areas represent the breeding distribution of penguins.

genetic evidence: *Plasmodium* (*Haemamoeba*) *relictum* (Fantham and Porter, 1944), *Plasmodium* (*Huffia*) *elongatum* (Huff and Shiroishi, 1962), *Plasmodium* (*Haemamoeba*) *tejerai* (Silveira *et al.* 2013), *Plasmodium* (*Haemamoeba*) *cathemerium* and *Plasmodium* (*Novyella*) *nucleophilum* (Vanstreels *et al.* 2015a). Additionally, *Plasmodium* (*Novyella*) *unalis* was identified through genetic evidence

(Vanstreels *et al.* 2015a). There is a record of *Plasmodium* (*Bennettinia*) *juxtannucleare* infecting penguins (Grim *et al.* 2003), however that report is problematic (see Appendix 2).

Because a number of studies have not conclusively identified all *Plasmodium* lineages that were detected (see Appendix 1), it is probable that many other species of *Plasmodium* have yet to be recorded in

penguins. Additionally, concomitant infection by two or more *Plasmodium* lineages is not uncommon (Huff and Shiroishi, 1962; Fleischman *et al.* 1968a, b; Herman *et al.* 1974; Sladen *et al.* 1979; Stoskopf and Beier, 1979; Beier and Stoskopf, 1980; Beier and Trpis, 1981; Vanstreels *et al.* 2014a, 2015a, in press).

Distribution among penguin hosts

Thirteen species have been shown to be susceptible to *Plasmodium* in the wild or in captivity: king (Scott, 1927), Humboldt (Rodhain, 1939), African, northern rockhopper, yellow-eyed (Fantham and Porter, 1944), Snares (Laird, 1950) (see Appendix 2), chinstrap (Rodhain and Andrianne, 1952), little, gentoo (Griner and Sheridan, 1967), Macaroni (Herman *et al.* 1974), Magellanic (Fix *et al.* 1988), Galapagos (Levin *et al.* 2009) and Southern rockhopper penguins (Dinhopl *et al.* 2011). There are only five penguin species in which *Plasmodium* infection was never documented: Adélie, emperor, erect-crested, Fiordland and Royal penguins. These species are inhabitants of remote sub-Antarctic and Antarctic environments, were seldom examined for blood parasites in the wild and were either never maintained in captivity or are generally maintained in vector-free acclimatized enclosures. It is therefore probable that the lack of records in these species is not due to a particular resilience to these parasites, but instead reflects a lack of studies in the wild and/or lack of exposure to environmental conditions that might allow their infection *ex situ*.

Invertebrate hosts

It is well established that avian plasmodia are transmitted exclusively by mosquitoes (Culicidae), particularly *Culex* spp., *Mansonia* spp., *Culiseta* spp. and *Aedeomyia* spp. Additionally, *Aedes* spp., *Anopheles* spp. and *Armigeres* spp. can also be competent hosts in laboratory experiments (Valkiūnas, 2005; Atkinson, 2008b).

Studies in zoos indicate that *Culex* spp. play a key role in the transmission of *Plasmodium* sp. to captive penguins, particularly *C. pipiens* (Rodhain, 1939; Raethel, 1960; Grünberg and Kutzer, 1963; Beier and Trpis, 1981), *Culex quinquefasciatus* (= *Culex fatigans*) (Laird and Van Riper, 1981), *Culex tarsalis* (Huff and Shiroishi, 1962), *Culex restuans* (Beier and Trpis, 1981) and *C. (Culex) sp.* (Bueno *et al.* 2010). Fantham and Porter (1944) found *Plasmodium* sp. in *C. quinquefasciatus* collected at Saldanha Bay, South Africa, where a wild penguin was found dead with a *P. relictum* infection. The invasive *C. quinquefasciatus* is likely involved in the transmission of *Plasmodium* in New Zealand and in the Galapagos Archipelago (Tompkins and Gleeson, 2006; Levin

et al. 2009; Levin and Parker, 2011). In the Galapagos Archipelago, however, *Aedes taeniorhynchus* still has to be investigated as a potential host since this species has been recorded in Mexico carrying *Plasmodium* lineages closely related to those identified in Galapagos penguins (Levin *et al.* 2013). In New Zealand, *C. quinquefasciatus* is restricted to the North Island (White, 1989; Holder, 1999) and *Culex pervigilans* is suspected to be responsible for the transmission of *Plasmodium* sp. at South Island and other islands (Holder, 1999; Sturrock and Tompkins, 2008). *Ochlerotatus australis* (= *Aedes australis*) is an invasive species in New Zealand (Holder, 1999; Snell, 2005) that could also play a role in the transmission of avian malarial parasites.

Geographic distribution

Plasmodium relictum was documented in wild penguins in South Africa (Saldanha Bay), New Zealand (Campbell Island, Fouveaux Strait, Tiritiri Matangi Island, Snares Island) and Gough Island (Fantham and Porter, 1944; Laird, 1950), and in captive penguins in Europe (Rodhain, 1939; Fantham and Porter, 1944), North America (Griner and Sheridan, 1967; Stoskopf and Beier, 1979), Hawaii (Laird and Van Riper, 1981), Eastern Asia (Bak *et al.* 1984), South Africa (Penrith *et al.* 1994) and at rehabilitation centres in South Africa (Brossy *et al.* 1999) and Chile (Carvajal and Alvarado, 2009). *Plasmodium elongatum* was documented infecting penguins at zoos in North America (Huff and Shiroishi, 1962; Beier and Stoskopf, 1980), Europe (Dinhopl *et al.* 2011) and rehabilitation centres in Brazil (Vanstreels *et al.* 2014a, 2015a). *Plasmodium tejerai* was identified in penguins undergoing rehabilitation in Brazil (Silveira *et al.* 2013; Vanstreels *et al.* 2014a, 2015a) and Argentina (Vanstreels *et al.* in press). *Plasmodium cathemerium*, *P. nucleophilum* and *P. unalis* were reported only in penguins undergoing rehabilitation in Brazil (Vanstreels *et al.* 2015a). Additionally, unidentified lineages of *Plasmodium* have been detected in wild penguins at the Galapagos Archipelago (Isabela, Fernandina, Las Marielas and Bartolomé Islands) (Levin *et al.* 2009, 2013), as well as at zoos in North and South America, Europe and Asia, and at rehabilitation centres in South Africa, Argentina and Brazil (see Appendix 1).

All *ex situ* and most *in situ* records of *Plasmodium* spp. infecting penguins are within the distribution range of *C. pipiens*, *C. quinquefasciatus* and *C. pervigilans* or, in Southern New Zealand, *O. australis* (Fig. 2C). The record of *P. relictum* in a Northern rockhopper penguin at Gough Island (Fantham and Porter, 1944) is a surprising exception, considering this is an extremely remote island where mosquitoes are absent (Gaston *et al.* 2003); the only

neighbouring archipelago, Tristan da Cunha, is also mosquito-free (Medlock *et al.* 2010). A possible explanation is that this penguin was exposed to *P. relictum* while being vagrant in South Africa (see Rollinson *et al.* 2013).

The geographic distribution of *Culex* mosquitoes overlaps with the breeding habitat of penguins in Peru, Chile, Namibia and Australia (Fig. 2C), and it is therefore plausible that wild penguins in these countries may be infected by *Plasmodium* sp. Most sub-Antarctic islands probably do not provide environmental conditions compatible with the transmission of *Plasmodium* spp. Gough, South Georgia, Marion, Macquarie and Tristan da Cunha Islands are reportedly free from mosquitoes (Laird, 1952; Hänel *et al.* 1998; Medlock *et al.* 2010) and the climate of South Georgia, South Sandwich, Bouvet, Amsterdam, Saint Paul, Crozet, Kerguelen and Peter I Islands is likely too adverse for mosquitoes (Medlock *et al.* 2010). It is therefore reasonable to assume that there is no *Plasmodium* sp. transmission in those locations, even if there have been little to no studies on blood parasites of penguins. The Falkland Islands are reportedly free from mosquitoes (Medlock *et al.* 2010), however DNA from *P. relictum* was detected in the blood of a thin-billed prion (*Pachyptila belcheri*) at New Island; because this a pelagic seabird that only comes to land in the breeding season, it is reasonable to suspect that infection occurred on the island (Quillfeldt *et al.* 2010). The harsh climate of Antarctica and the South Shetland Islands probably also precludes the occurrence of *Plasmodium* sp., as corroborated by blood parasite studies in the region (e.g. Laird, 1961; Becker and Holloway, 1968; Jones and Shellam, 1999a; González-Acuña *et al.* 2013; Vanstreels *et al.* 2014b).

Epidemiology and pathology

In wild penguins, the prevalence of *Plasmodium* sp. varies considerably. *Plasmodium* sp. was detected in the blood smears of 0.7% of African penguins at Dyer Island, 3% at Saldanha Bay, 9% at Stony Point, 11% at Robben Island, and 34% at Dassen Island (Fantham and Porter, 1944; Brossy, 1992; Thiart, 2005). In New Zealand, blood smears revealed *P. relictum* infection in 10% of yellow-eyed penguins at Foveaux Strait, 10.7% of Snares penguins at Snares Island, and one of two yellow-eyed penguins at Campbell Island (Fantham and Porter, 1944; Laird, 1950). Furthermore, one of five Northern rockhopper penguins from Gough Island was blood smear-positive to *P. relictum* (Laird, 1950). Using molecular methods, Levin *et al.* (2009, 2013) detected *Plasmodium* sp. in the blood of 5.4% of Galapagos penguins, with prevalence varying between 2.1 and 42.9% among islands. None of the wild penguins in which

Plasmodium sp. was detected had external signs of disease, and parasitaemia was generally low or undetectable in blood smears (Fantham and Porter, 1944; Laird, 1950; Brossy, 1992; Levin *et al.* 2009). Fantham and Porter (1944) detected *P. relictum* in a deceased wild African penguin; however, because the penguin had multiple traumatic lesions it was not clear to what extent avian malaria may have contributed to its death.

It is well established that avian malaria outbreaks in zoos result from local mosquitoes inoculating penguins with *Plasmodium* sp. acquired from the native birds in the surroundings of the penguin exhibit (Beier and Trpis, 1981; Ejiri *et al.* 2009; Bueno *et al.* 2010; Leclerc *et al.* 2014; Dinhopl *et al.* 2015). Because mosquito abundance is markedly seasonal, cases of avian malaria in captive penguins tend to concentrate in spring-summer, particularly late summer (Grünberg and Kutzer, 1963; Griner and Sheridan, 1967; Sladen *et al.* 1979; Beier and Stoskopf, 1980; Vanstreels *et al.* 2015a). Mosquitoes are most active in penguin enclosures at night (Beier and Trpis, 1981). At zoos that recorded avian malaria outbreaks, the prevalence of *Plasmodium* sp. in mosquitoes near penguin exhibits is generally low (<5%) (Beier and Trpis, 1981; Bueno *et al.* 2010; Ejiri *et al.* 2009, 2011), and similar results were obtained in studies at locations where *Plasmodium* sp. was reported in wild penguins (Fantham and Porter, 1944).

Outbreaks of avian malaria in permanently captive penguins usually occur suddenly and/or in successive waves. Mortality might depend on the *Plasmodium* species/lineage involved, whether there was prior exposure to *Plasmodium* sp., and on the administration of drug treatment, with between 10 and 83% penguins dying within a few weeks or months (Fleischman *et al.* 1968a; Stoskopf and Beier, 1979; Fix *et al.* 1988; Cranfield *et al.* 1994; Graczyk *et al.* 1994a; Bueno *et al.* 2010). A similar pattern is observed for penguins kept in temporary captivity while receiving rehabilitation care in South America (Carvajal and Alvarado, 2009; Vanstreels *et al.* 2014a, 2015a). On the other hand, avian malaria is enzootic to African penguins undergoing rehabilitation, with 30–35% of penguins being positive (blood smears) upon admission (Parsons and Underhill, 2005).

Most penguins with avian malaria in captivity are in good body condition and do not present clinical signs, dying suddenly. When clinical signs are present, they are not specific and may include: anorexia, depression, lethargy, weakness, regurgitation, green faeces, hyperthermia, pale mucosae, and dyspnoea (Rodhain, 1939; Griner and Sheridan, 1967; Sladen *et al.* 1979; Stoskopf and Beier, 1979; Bak *et al.* 1984; Fix *et al.* 1988; Bueno *et al.* 2010; Vanstreels *et al.* 2014a). Haematology may reveal leucocytosis with lymphocytosis and/or monocytosis (Stoskopf and Beier, 1979; Fix *et al.* 1988; Graczyk

et al. 1994a). Infected penguins often have low parasitaemia (<2%) (Stoskopf and Beier, 1979; Graczyk *et al.* 1994a); however, occasionally much higher parasitaemia may be observed, with up to 80% of erythrocytes parasitized and multiple parasites per erythrocyte (Fantham and Porter, 1944; Bueno *et al.* 2010; Vanstreels *et al.* 2014a).

Captive penguins deceased due to avian malaria typically present hepatomegaly, splenomegaly, lung congestion and hydropericardium (Rodhain, 1939; Bak *et al.* 1984; Fix *et al.* 1988; Graczyk *et al.* 1994a; Grim *et al.* 2003; Ko *et al.* 2008; Carvajal and Alvarado, 2009). Tissue meronts are present in multiple tissues and concentrate especially in the lungs, kidneys, brain, heart, liver and spleen (Rodhain, 1939; Fleischman *et al.* 1968b; Bak *et al.* 1984; Fix *et al.* 1988; Graczyk *et al.* 1994a; Grim *et al.* 2003; Ko *et al.* 2008; Silveira *et al.* 2013; Vanstreels *et al.* 2014a, 2015a). Concurrent diseases are not uncommon, and aspergillosis is frequently reported in captive penguins that died from avian malaria (Scott, 1927; Rodhain, 1939; Rewell, 1948; Grünberg and Kutzer, 1963; Griner and Sheridan, 1967; Sladen *et al.* 1979; Fix *et al.* 1988; Carvajal and Alvarado, 2009; Grilo, 2014; Vanstreels *et al.* 2015a). Septicaemia (Grünberg and Kutzer, 1963), enteritis/diarrhoea (Scott, 1927; Fix *et al.* 1988), infestation with gastrointestinal helminthes (Rodhain and Andrianne, 1952; Fix *et al.* 1988; Vanstreels *et al.* 2015a), clostridiosis (Penrith *et al.* 1994), babesiosis (Yabsley *et al.* 2012), poxvirosis and infestation with lung or liver helminthes (Vanstreels *et al.* 2014a, 2015a) have also been documented concurrently with avian malaria.

Serological studies

Graczyk *et al.* (1993, 1994b) developed an indirect enzyme-linked immunosorbent assay (ELISA) that was extensively used to test penguins for antibodies against *Plasmodium* spp. (Graczyk *et al.* 1994a, b, c, d, 1995a, b, c; Botes, 2004; Thiart, 2005; McDonald, 2012; Palmer *et al.* 2013). Seroprevalence for *Plasmodium* sp. was 29–52% in wild African penguin in South Africa (Graczyk *et al.* 1995a, b), 33% in Gentoo and 58% in king penguins at Kerguelen and Crozet Islands (Graczyk *et al.* 1995c), 23–100% in yellow-eyed penguins in New Zealand (Graczyk *et al.* 1995b, c; McDonald, 2012) and 91–100% in Galapagos penguins at the Galapagos Archipelago (Palmer *et al.* 2013). No Adélie penguins were seropositive at Ross Island, Antarctica (Graczyk *et al.* 1995c).

Penguins in captivity or undergoing rehabilitation have also been tested for antibodies against *Plasmodium* sp. using this assay. At a rehabilitation centre in Cape Town, South Africa, oiled African penguins had higher seroprevalence to *Plasmodium* sp. upon admission (62%) than those that had been in rehabilitation for at least two weeks (38%) or

those permanently captive (20%) (Graczyk *et al.* 1995a). Seroprevalence to *Plasmodium* sp. was 92% in little penguins captive at Napier, New Zealand, and 43% in Magellanic penguins captive at San Diego, USA. Furthermore, a few studies have applied this ELISA to study the epidemiology of avian malaria in African penguins in captivity (Graczyk *et al.* 1994a, b, c) and undergoing rehabilitation (Botes, 2004; Thiart, 2005).

However, several authors have noted that there is a considerable discrepancy between the high seroprevalence to *Plasmodium* sp. detected by this assay and the rarity of individuals with detectable *Plasmodium* sp. parasitaemia in blood smears and PCR tests in the same populations (Sturrock and Tompkins, 2007; Hill, 2008; McDonald, 2012; Palmer *et al.* 2013). Some have interpreted this discrepancy as an indication of inaccuracy of the serological test (Sturrock and Tompkins, 2007; McDonald, 2012), whereas others considered it an indication of poor sensitivity of PCR tests (Palmer *et al.* 2013) or to be due to parasite latency in tissues (Hill, 2008; Palmer *et al.* 2013). It remains to be tested whether or not this assay cross-reacts with *Leucocytozoon* spp., which is plausible considering their shared phylogenetic history and genetic similarities (Cosgrove *et al.* 2006; Martinsen *et al.* 2008). Cross-reactivity with viruses (Greenberg *et al.* 1986) and helminths (Naus *et al.* 2003) have also been shown to occur in serological tests targeting *Plasmodium* sp. in humans. The results of these serological tests should therefore be interpreted cautiously until detailed studies explain the discrepancies in the results of serological and direct diagnosis tests and to determine if cross-reactivity may have influenced the serological results.

Implications for public health and conservation

There is no evidence to indicate that avian-infecting *Plasmodium* spp. can infect humans (Valkiūnas, 2005). *Plasmodium* spp. are recognized as conservation-threatening pathogens due to their well-documented impacts to the Hawaiian avifauna (Van Riper III *et al.* 1986; Atkinson and Lapointe, 2009). The high susceptibility of Hawaiian native birds and penguins is thought to result from a lack of physiological/immune adaptations to deal with the infection, as they did not co-evolve with these parasites (Valkiūnas, 2005). The high morbidity and mortality observed in penguins when they are exposed to avian plasmodia in captivity has led to concern that the introduction of mosquitoes to penguin breeding habitats where they had historically been absent could ensue in substantial morbidity and mortality (Jones and Shellam, 1999b; Miller *et al.* 2001; Meile *et al.* 2013). This is acutely concerning as climate change increases the pressure imposed by *Plasmodium* sp. on birds (Garamszegi, 2011).

In particular, *Plasmodium* sp. may constitute a significant conservation threat to the African, Galapagos and yellow-eyed penguins, three endangered species with relatively narrow geographic distribution (IUCN, 2015) in which infection has already been documented in the wild (Fantham and Porter, 1944; Levin *et al.* 2009). Fortunately the *Plasmodium* sp. lineages detected at the Galapagos Archipelago so far have failed to become established and produce significant disease in Galapagos penguins (Levin *et al.* 2009, 2013); however, this could change if more pathogenic lineages are introduced to the archipelago in the future. *Plasmodium* sp. appears to be enzootic in African and yellow-eyed penguins; however, these species' populations are already declining due to a variety of environmental impacts and pathogens (Crawford *et al.* 2011; King *et al.* 2012), and avian malaria could synergize with these existing threats. Furthermore, penguin populations at other areas with relatively warm climate such as Peru, Chile and Tristan da Cunha and Gough Islands could also become at risk if mosquitoes become successfully established near penguin breeding habitat, particularly near freshwater deposits associated with human communities. Other populations of penguins that have relatively narrow geographic distributions, such as Fiordland and Snares penguins could also be at risk, since mosquitoes are already present in their breeding habitat (Fantham and Porter, 1944; Laird, 1950).

LEUCOCYTOZOON (LEUCOCYTOZOONOSIS)

Leucocytozoon spp. (Haemosporida: Leucocytozoidae) parasitize exclusively birds. There are approximately 40 recognized species, one in the subgenus *Akiba* and the remaining in the subgenus *Leucocytozoon*. In the avian blood, young gametocytes and gametocytes of these parasites can be found in the cytoplasm of erythrocytes and mononuclear leucocytes (Fig. 1); there are neither erythrocytic meronts nor haemozoin granules. In the avian tissues, these parasites will invade endothelial cells, macrophages and hepatocytes; megalomeronts may be developed, which are very large and thick-walled (Huff, 1942; Valkiūnas, 2005).

Species recorded in penguins

Leucocytozoon (Leucocytozoon) tawaki was described from Fiordland penguins (Fallis *et al.* 1976; Allison *et al.* 1978). When Earlé *et al.* (1992) and Peirce *et al.* (2005) observed similar parasites in other species of penguins in Europe and South Africa they did not hesitate to attribute these records to *L. tawaki*. On the other hand, other authors have documented leucocytozoids in yellow-eyed penguins at locations in New Zealand but preferred not to comment on the species involved (Hill, 2008; Hill *et al.* 2010;

Argilla *et al.* 2013). Phylogenetic analyses indicated these lineages from yellow-eyed penguins belonged to the subgenus *Leucocytozoon*, and that there might be at least two distinct phylogenetic groups: cluster A is limited to Enderby Island and might be more pathogenic than cluster B, which was detected at Enderby, Campbell, South and Stewart Islands (Argilla *et al.* 2013). It is unclear whether these phylogenetic clusters are variations within the same morphospecies or correspond to different species, and their relationship to the *L. tawaki* originally described in Fiordland penguins is also not clear.

Distribution among penguin hosts

Leucocytozoon spp. have been detected in wild Fiordland (Fallis *et al.* 1976; Allison *et al.* 1978) and yellow-eyed penguins (Hill *et al.* 2010; Argilla *et al.* 2013), as well as in African (Earlé *et al.* 1992) and Fiordland penguins undergoing rehabilitation (Hill, 2008). Additionally, the infection was documented in Macaroni penguins in captivity (Peirce *et al.* 2005). Allison *et al.* (1978) demonstrated that little penguins can develop the infection when forcibly exposed to black flies near *L. tawaki*-infected Fiordland penguins. There is also evidence to suggest that *Leucocytozoon* sp. could infect wild and captive little penguins (see Appendix 2). It is worth noting that Snares, erect-crested and little penguins live in close proximity to populations of Fiordland and yellow-eyed penguins that were found to be infected with *Leucocytozoon* sp., and it is reasonable to presume they are exposed to these parasites in the wild.

Invertebrate hosts

L. (Leucocytozoon) spp. are transmitted by black flies (Simuliidae), particularly *Simulium* spp. and *Prosimulium* spp., but also *Cnephia* spp. and *Austrosimulium* spp. (Valkiūnas, 2005; Forrester and Greiner, 2008). *Cnephia* spp., *Simulium* spp. and *Prosimulium* spp. are not present in New Zealand (Dumbleton, 1963), whereas *Austrosimulium australlense*, *Austrosimulium dumbletoni* and *Austrosimulium unguatum* are abundant and were shown to be competent in the transmission of *L. tawaki* at South Island (Fallis *et al.* 1976; Allison *et al.* 1978; Desser and Allison, 1979). *Austrosimulium unguatum* is also very abundant in Stewart and South Islands, New Zealand, and could be involved in the transmission of *Leucocytozoon* sp. to yellow-eyed penguins (Hill *et al.* 2010; Argilla *et al.* 2013). On the other hand, *Austrosimulium campbellense* and *Austrosimulium vexans* are thought to be respectively responsible for the transmission at Campbell and Auckland Islands, New Zealand (Argilla *et al.* 2013). *Austrosimulium* spp. do not occur in South

Africa (Dumbleton, 1963) and thus other simuliid flies must be involved in the transmission of this parasite to African penguins (Earlé *et al.* 1992); *Cnephia* spp. and *Simulium* spp. are present in the region (Dumbleton, 1963).

Geographic distribution

Leucocytozoon tawaki is known from South Island, New Zealand (Kaikoura, Jackson Head) (Fallis *et al.* 1976; Allison *et al.* 1978). *Leucocytozoon* sp. has been documented at South Island, New Zealand (Otago Peninsula and Catlins) (Argilla *et al.* 2013) and at Campbell, Enderby and Stewart Islands (Hill *et al.* 2010; Argilla *et al.* 2013). Additionally, *Leucocytozoon* sp. has been documented in penguins undergoing rehabilitation in South Africa (Cape Town) (Earlé *et al.* 1992) and North Island, New Zealand (Auckland) (Hill, 2008), and captive in England (Peirce *et al.* 2005). Because the blood smears examined by Earlé *et al.* (1992) were prepared between 5 and 24 days after admission to the rehabilitation centre in South Africa, it is possible that infection occurred in the wild. The geographic distribution of black flies overlaps with that of penguin breeding colonies in several regions where *Leucocytozoon* sp. has not yet been reported in penguins, such as Peru, Chile, Argentina, Namibia, Australia and New Zealand (Fig. 2B).

Epidemiology and pathology

L. tawaki prevalence is very high in Fiordland penguins at South Island, New Zealand (Jackson Head) (blood smears: 77–94%) (Fallis *et al.* 1976; Allison *et al.* 1978). *Leucocytozoon* sp. prevalence is more variable in yellow-eyed penguins in New Zealand, being lower at South Island (Otago Peninsula and Catlins) (PCR: 11%) and Campbell Island (PCR: 21%), and higher at Enderby (PCR: 66%) and Stewart Islands (PCR: 83%) (Hill *et al.* 2010; Argilla *et al.* 2013). Both Fiordland and yellow-eyed penguins are infected only when they are 3-weeks-old or older, with the infection being acute and disseminated in older chicks then progressing to a subclinical chronic infection in adulthood (Allison *et al.* 1978; Hill *et al.* 2010; Argilla *et al.* 2013). Although prevalence is similar in older chicks and adults (and possibly highest in moulting adults), parasitaemia tends to be lower in adults (Fallis *et al.* 1976; Allison *et al.* 1978). In fact, parasitaemia in adults may be so low as to be undiagnosed or substantially underestimated by blood smears in comparison with molecular methods (Hill *et al.* 2010; Argilla *et al.* 2013). *Leucocytozoon* sp. occurs at low prevalence amongst African penguins undergoing rehabilitation (blood smears: 0–75%) (Earlé *et al.* 1992). Because it is generally accepted that leucocytozooids are not transmitted

among birds of different taxonomic orders (Valkiūnas, 2005), it is unlikely that birds other than penguins can serve as reservoirs of infection.

Leucocytozoon sp. can be occasionally pathogenic for penguin chicks. One yellow-eyed penguin chick found dead at Enderby Island ($n = 19$) and two at Stewart Island, New Zealand ($n = 14$), were considered to have died from leucocytozoonosis. Necropsy findings included disseminated petechial and ecchymotic haemorrhage, hepatomegaly, splenomegaly and hydropericardium; megalomeronts were abundant in the liver, spleen, kidneys, lungs and other tissues (Hill *et al.* 2010; Argilla *et al.* 2013). The tissues of an additional seven yellow-eyed penguins were PCR-positive for *Leucocytozoon* sp. at Stewart Island; however, it was not determined whether leucocytozoonosis was the cause of death or not (Hill *et al.* 2010). Furthermore, a juvenile Fiordland penguin found at North Island, New Zealand (Muriwai beach), died during rehabilitation after having been positive to *Leucocytozoon* sp. on blood smears, but it was not possible to determine if leucocytozoonosis was the cause of death (Hill, 2008). The health effects of the infection in African and Macaroni penguins are not known (Earlé *et al.* 1992; Peirce *et al.* 2005).

Implications for public health and conservation

There is no evidence to indicate that *Leucocytozoon* spp. could infect humans (Valkiūnas, 2005). Although *Leucocytozoon* sp. appears to have limited impacts to the health of adult penguins, this can be a considerably pathogenic parasite to penguin chicks and juveniles (Fallis *et al.* 1976; Allison *et al.* 1978; Hill, 2008; Hill *et al.* 2010; Argilla *et al.* 2013). This is particularly troublesome for yellow-eyed penguins, an endangered species that has faced substantial population decrease in the past decades (IUCN, 2015). Yellow-eyed penguin chicks already face a variety of stressors and diseases (Alley *et al.* 2004; Hocken, 2005; Browne *et al.* 2011; Buckle *et al.* 2014), and *Leucocytozoon* sp. might be an additional factor contributing to decrease the species' chick survival (King *et al.* 2012). In the case of African penguins, which are also endangered (IUCN, 2015), additional studies are urgent to bring better understanding on the epidemiology and pathology of this parasite. There is also evidence to suspect that wild little penguin chicks might also die as a result from leucocytozoonosis (see Appendix 2), and therefore an investigation on the occurrence of *Leucocytozoon* sp. in this species, particularly in Western Australia, would be valuable.

HAEMOPROTEUS (HAEMOPROTEOSIS)

Haemoproteus spp. (Haemosporida: Haemoproteidae) parasitize exclusively birds. There are approximately

150 recognized species, 10 in the subgenus *Haemoproteus* and the remaining in the subgenus *Parahaemoproteus* (Valkiūnas, 2005; Levin *et al.* 2011, 2012; Valkiūnas *et al.* 2010, 2013). These parasites can be found in the cytoplasm of avian erythrocytes, as trophozoites and gametocytes; haemozoin granules (dark-brown staining pigment) are present, but not erythrocytic meronts. In the avian tissues, these parasites invade endothelial cells and macrophages to form exoerythrocytic meronts; megalomeronts may be developed, which are very large and thick-walled (Huff, 1942; Paperna and Gill, 2003; Valkiūnas, 2005).

Species recorded in penguins

Haemoproteus sp. detected in penguins have not been morphologically characterized, hence their identity has not been conclusively established. Phylogenetic analyses indicate however that the lineages identified in Galapagos and Humboldt penguins belong to the subgenus *Parahaemoproteus* and are closely related to lineages found in passerines (Levin *et al.* 2009; Sallaberry-Pincheira *et al.* 2015) (see Appendix 2).

Distribution among penguin hosts

DNA from *Haemoproteus* sp. has been detected in the blood of wild Galapagos (Levin *et al.* 2009) and Humboldt penguins (Sallaberry-Pincheira *et al.* 2015). There is a report of *Haemoproteus* sp. infection in wild little penguins (Cannell *et al.* 2013), however that record is problematic (see Appendix 2).

Invertebrate hosts

Haemoproteus (*Parahaemoproteus*) spp. are transmitted by biting midges *Culicoides* spp. (Ceratopogonidae) (Valkiūnas, 2005; Atkinson, 2008a). Eleven species of *Culicoides* spp. have been associated with the transmission of these parasites (Valkiūnas, 2005).

Culicoides pusillus is the only species of its genus that occurs at the Galapagos Archipelago (Sinclair, 2014), whereas a broad variety of species occurs in Peru (Wirth and Felipe-Bauer, 1989; Borkent, 2013). It is worth noting that the *Haemoproteus*-positive penguin identified at the Galapagos Archipelago was sampled at western Isabela Island (I. I. Levin, personal communication), whereas *C. pusillus* has been recorded only at Santa Cruz Island (Sinclair, 2014). Even though DNA from *Haemoproteus* sp. was identified in the blood meals of mosquitoes *Aedes taeniorhynchus* at the Galapagos Archipelago, this was most likely an incidental finding and probably did not correspond to actual infections (Bataille *et al.* 2012). It is not clear which species of biting midges were involved in the transmission of *Haemoproteus* sp. to Humboldt penguins at Punta San Juan (Sallaberry-Pincheira *et al.* 2015), however

Culicoides spp. are not uncommon in Peru (Tabachnick, 2004; Felipe-Bauer *et al.* 2008) and the coastal range of Peru provides suitable climatic conditions to these insects (Guichard *et al.* 2014).

Geographic distribution

Haemoproteus (*Parahaemoproteus*) spp. were detected in penguins in the Galapagos Archipelago (Isabela Island) (Levin *et al.* 2009) and Peru (Punta San Juan) (Sallaberry-Pincheira *et al.* 2015). The distribution of biting midges overlaps that of penguins breeding in Namibia, South Africa and Australia, possibly providing opportunities for *H. (Parahaemoproteus)* sp. inoculation. Similarly, captive penguins in areas of North and South America, southern Europe, Africa, Asia and Oceania could also be exposed (Fig. 2A).

Epidemiology and pathology

The *Haemoproteus*-positive penguins studied by Levin *et al.* (2009) and Sallaberry-Pincheira *et al.* (2015) had no external signs of illness. Considering that no parasites were seen in blood smears and that molecular tests may produce false-positive results if DNA of recently inoculated sporozoites is present in the blood even when infection was not developed (Levin *et al.* 2013; Valkiūnas *et al.* 2014), it is possible that these *Haemoproteus* spp. were not truly capable of infecting penguins and instead represent incidental findings (i.e. abortive infections). The report of lethal haemoproteosis in wild little penguins (Cannell *et al.* 2013) is problematic, and is addressed in detail in Appendix 2.

Implications for public health and conservation

There is no evidence to indicate that *Haemoproteus* spp. could infect humans (Valkiūnas, 2005). *Haemoproteus* spp. are generally considered the least pathogenic of avian haemosporidians; however, there are exceptional cases of lethal haemoproteosis (Atkinson and Van Riper III, 1991; Donovan *et al.* 2008). In the case of penguins, however, it is still unclear whether *Haemoproteus* sp. sporozoites are able to infect and develop in penguin cells (see Levin *et al.* 2013; Valkiūnas *et al.* 2014) and, until this has been conclusively demonstrated, it seems unlikely that these parasites pose a significant threat for their conservation.

BABESIA (BABESIOSIS)

Babesia spp. (Piroplasmida: Babesiidae) parasitize birds and mammals, with 13 avian-infecting species (Peirce, 2000, 2005; Schnittger *et al.* 2012). In the avian blood, these parasites can be found in the

cytoplasm of erythrocytes either as round forms (trophozoites and pre-gametocytes) or tetrameric elongated forms (meronts) (Fig. 1); there are no haemozoin granules. There is no invasion of tissue cells; however, infected erythrocytes can occasionally be seen in the margin of blood vessels (Peirce, 2000; Chauvin *et al.* 2009; Schnittger *et al.* 2012).

Species recorded in penguins

Babesia peircei was described from African penguins (Earlé *et al.* 1993). It is not clear whether the *Babesia* sp. reported in little penguins in Australia corresponds to *B. peircei* or to a different species (Cunningham *et al.* 1993; Vanstreels *et al.* 2015b). The remarkable morphological and/or genetic similarities between *B. peircei*, *Babesia* sp. of little penguins, *Babesia poelea* (parasite of boobies *Sula* spp.) and *Babesia uriae* (parasite of common murre *Uria aalge*) has led to speculation that these taxa could in fact correspond to a single seabird-infecting species (Peirce, 2000; Vanstreels *et al.* 2015b).

Distribution among penguin hosts

Babesia peircei is known from African penguins in the wild and in rehabilitation (Coles, 1941; Earlé *et al.* 1993; Brossy *et al.* 1999; Yabsley *et al.* 2012) and *Babesia* sp. was documented in wild little penguins (Cunningham *et al.* 1993; Vanstreels *et al.* 2015b).

Invertebrate hosts

It is generally accepted that hard ticks (Ixodidae) are the most relevant invertebrate hosts of avian *Babesia* spp., but soft ticks (Argasidae) are thought to play a significant role for colonial ground-nesting birds (Peirce, 2000). Hard ticks, particularly *Ixodes uriae*, are the most probable vectors of *B. peircei* to African penguins (Earlé *et al.* 1993; Peirce, 2000), but the soft tick *Carios capensis* has also been speculated to play a role in the transmission (Brossy *et al.* 1999). The hard tick *Ixodes kohlsi* may play a key role in the transmission to little penguins at New South Wales, Australia (Cunningham *et al.* 1993), and both soft and hard ticks were observed on *Babesia*-infected little penguins in Tasmania, Australia (Vanstreels *et al.* 2015b).

Geographic distribution

Babesia peircei was documented infecting penguins in Namibia (Ichaboe Island), South Africa (Western Cape and Eastern Cape) and *Babesia* sp. infects penguins in Australia (New South Wales, Victoria and Tasmania) (Cunningham *et al.* 1993; Earlé *et al.* 1993; Vanstreels *et al.* 2015b; Parsons *et al.* in preparation). Seabird ticks, both soft and hard, are broadly distributed around the world, overlapping with the distribution of penguins in

numerous sub-Antarctic islands, Peru, Chile, Argentina, New Zealand, Antarctic Peninsula and at some locations in the Antarctic mainland (Fig. 3A); the occurrence of *Babesia* sp. in penguins at these locations is therefore plausible.

Epidemiology and pathology

Babesia sp. infects 1.6 to 4.8% (blood smears; Cunningham *et al.* 1993) and 2.7% (blood smears; Vanstreels *et al.* 2015b) of wild little penguins in south-eastern Australia. *B. peircei* is endemic at low prevalence in wild African penguins in Namibia and South Africa (blood smears: 1–4%) (Brossy, 1992; Parsons *et al.* in preparation), whereas a higher prevalence (blood smears: 11–15%) was observed in African penguins undergoing rehabilitation (Brossy, 1992). Because it is not known whether penguin-infecting *Babesia* sp. and *B. poelea* are the same species or not, it is not clear if other seabirds can serve as reservoirs of infections for penguins and vice-versa.

The clinical and pathological effects of *Babesia* spp. infections are not clear. Infected little penguins can present mild regenerative anemia, but did not show any evident signs of illness (Cunningham *et al.* 1993; Sergent *et al.* 2004). Brossy *et al.* (1999) considered that *B. peircei* ‘does not cause overt clinical symptoms except under stress or in association with other debilitating diseases’. On the other hand, Parsons *et al.* (in preparation) found that *B. peircei*-infected wild African penguins had signs of regenerative response of the erythrocytic lineage and haematological indications of active inflammatory response and hepatic function impairment.

Furthermore, approximately 50% of *Borrelia*-infected African penguins undergoing rehabilitation in South Africa are also co-infected with *B. peircei* (Yabsley *et al.* 2012), which could reflect: (a) transmission by a shared invertebrate host; (b) *Babesia* sp. infections predispose penguins or ticks to *Borrelia* sp. infections or vice versa; or (c) the poor health and immune status of penguins in rehabilitation predispose them to both of these pathogens.

Serological studies

The indirect ELISA designed for *Plasmodium* by Graczyk *et al.* (1993, 1994b) was adapted to test penguins for antibodies against *Babesia* sp., and showed that 18–22% of wild African penguins in South Africa were seropositive (47% in oiled birds) (Graczyk *et al.* 1996). However, the limitations and concerns raised regarding the use of this assay to test for *Plasmodium* sp. may also apply to its application for *Babesia* sp.

Implications for public health and conservation

There is no evidence to indicate that avian-infecting *Babesia* spp. can infect humans (Peirce, 2000). There

is evidence that *Babesia* sp. infections significantly affect the health of penguins (Cunningham *et al.* 1993; Parsons *et al.* in preparation), which is concerning because this pathogen is not uncommon in African penguins, an endangered species whose population has been steadily decreasing (Crawford *et al.* 2011; IUCN, 2015). Epidemiological and pathological studies of *Babesia* sp., particularly in African penguins, will therefore be important to clarify its potential conservation impacts.

TRYPANOSOMA (TRYPANOSOMIASIS)

Trypanosoma spp. (Kinetoplastida: Trypanosomatidae) parasitize all tetrapod classes. Avian-infecting trypanosomatids are considered part of the '*Trypanosoma avium* complex', for which more than 100 species have been described with arguable validity (Molyneux, 1977; Haag *et al.* 1998; Sehgal *et al.* 2001; Votypka *et al.* 2002; Hamilton *et al.* 2004; Zídková *et al.* 2012). These parasites remain free in the avian blood in the form of trypomastigotes, which have a characteristic elongated shape with flagella, a kinetoplast and an undulating membrane. Trypomastigotes can concentrate in blood vessels of lymphoid tissues and in the bone marrow, however in birds the asexual multiplication probably does not occur in those tissues nor in the myocardium (Diamond and Herman, 1954; Baker, 1956; Baker and Bird, 1968).

Species recorded in penguins

Only one species, *Trypanosoma eudyptulae*, has been reported in penguins (Jones and Woehler, 1989). This parasite has not been reported in other avian hosts.

Distribution among penguin hosts

Trypanosoma sp. has only been reported in wild little penguins (Jones and Woehler, 1989).

Invertebrate hosts

There is no information regarding which invertebrates are involved in the transmission of *T. eudyptulae*. Black flies (*Metacnephia lyra*, *Simulium* spp. and *Prosimulium decemarticulatum*), mosquitoes (*Aedes aegypti*), louse flies (*Ornithomya avicularia*) and mites (*Dermanyssus gallinae*) have been found to be competent hosts of other avian trypanosomes (Molyneux, 1977; Reeves *et al.* 2007). Of those, *A. aegypti* is absent in Tasmania (Kearney *et al.* 2009), whereas *Dermanyssus* spp. (including *D. gallinae*) and *Ornithomya* spp. (including *O. avicularia*) are present (Domrow, 1979; ALA, 2014). Furthermore, other species of black flies (*Austrosimulium* spp. and *Cnephia* spp.) also occur in Tasmania (Dumbleton, 1963) and could be plausible hosts.

Geographic distribution

Trypanosoma eudyptulae was originally described at a little penguin colony on Marion Bay in Tasmania, Australia (Fig. 3C) (Jones and Woehler, 1989). However, that colony was destroyed during a fire in 1994 and has not been recolonized since (Stevenson and Woehler, 2007; E. J. Woehler, personal communication). Recent efforts to detect this parasite in breeding colonies near Marion Bay have failed (Vanstreels *et al.* 2015b). Because this parasite's invertebrate hosts remain unknown, it is difficult to speculate on its potential distribution.

Epidemiology and pathology

Despite having been observed with a relatively high prevalence (blood smears: 15.8%), *T. eudyptulae* was present only with low parasitaemia (often only one parasite per blood smear) (Jones and Woehler, 1989), which suggests chronic infection. Infected penguins presented no external signs of illness.

It is worth noting that Jones and Woehler (1989) obtained blood samples by superficially scraping the skin near the brachial vein on the flipper with razorblades then collecting a drop of blood with a capillary tube or glass slide (E. J. Woehler, personal communication). This method would result in the collection of blood from capillary vessels, as opposed to blood from larger vessels as is obtained through venipuncture. This may be relevant because it has been shown that mammal-infecting trypanosomes tend to concentrate in capillaries rather than larger blood vessels (Hornby and Bailey, 1931; Banks, 1978). It is unclear whether or not avian trypanosomes behave similarly (Holmstad *et al.* 2003), but there is evidence to suggest that these parasites concentrate in the bone marrow of birds rather than in their circulating blood (Diamond and Herman, 1954). For these reasons, it is possible that studies using blood smears from samples collected by venipuncture may have systematically underestimated the occurrence of trypanosomatids in penguins. Molecular methods could also enhance the detection of these parasites in the future (see Sehgal *et al.* 2001).

Implications for public health and conservation

There is no evidence to indicate that avian-infecting *Trypanosoma* spp. can infect humans (Molyneux, 1977). Avian trypanosome infections are not usually regarded as pathogenic, but in some circumstances these parasites may have mild health impacts (Molyneux *et al.* 1983; Merino *et al.* 1996; Sehgal *et al.* 2001). Because of how little is known about *T. eudyptulae*, it is difficult to evaluate the impacts it could have on the conservation of little penguins, if any.

BORRELIA (LYME DISEASE, RELAPSING FEVER, ANIMAL SPIROCHETOSIS)

The bacteria of the genus *Borrelia* (Spirochaetales: Spirochaetaceae) are classified in three groups: Lyme disease *Borrelia* (LDB), relapsing fever *Borrelia* (RFB) and animal spirochetosis *Borrelia* (ASB) (Olsén, 2007). LDB are often referred to as '*Borrelia burgdorferi* sensu lato', a group that comprises 10 species and numerous unidentified strains, of which *Borrelia garinii* is particularly relevant for seabirds (Olsén *et al.* 1995a, b; Olsén, 2007). There are 18 species in the RFB group, of which *Borrelia hermsii*, *Borrelia parkeri*, *Borrelia recurrentis* and *Borrelia turicatae* are considered most relevant (McDowell *et al.* 2003; Cutler, 2006). Three species are associated with ASB, of which only *Borrelia anserina* infects birds (Barbour and Hayes, 1986; McDowell *et al.* 2003; Olsén, 2007). *Borrelia* spp. are present in the blood in the form of small extracellular helical filiform structures, typically 9–30 µm long and 0.2–0.5 µm wide (Fig. 1); there is no invasion of cells of the blood or other tissues (Barbour and Hayes, 1986; Olsén, 2007).

Species recorded in penguins

Borrelia sp. strains detected in king penguins had a restriction fragment length polymorphism profile identical to that of *B. garinii*, and are therefore thought to belong to the LDB group (Schramm *et al.* 2014). On the other hand, the strains identified in African penguins are phylogenetically most related to *B. parkeri* and *B. turicatae*, both of which are classified as RFB (Yabsley *et al.* 2012). Coles (1941) observed spirochetes in the blood smear of a wild African penguin chick at Dassen Island, and discarded them from being *B. anserina*; considering that RFB were later found to infect African penguins at that region (Yabsley *et al.* 2012), it is reasonable to assume these corresponded to similar strains.

Distribution among penguin hosts

RFB has been documented in African penguins in the wild (Coles, 1941; Parsons *et al.* in preparation) and undergoing rehabilitation (Yabsley *et al.* 2012; Parsons *et al.* in preparation). LDB was recorded in wild king penguins (Schramm *et al.* 2014); it is reasonable to presume that Gento, Macaroni and Southern rockhopper penguins breeding near king penguins at Crozet Archipelago (IUCN, 2015) are also exposed to LDB.

Vectors

With the exception of *B. recurrentis*, which is transmitted to humans by lice, all *Borrelia* spp. are

transmitted by ticks. LDB are transmitted by hard ticks *Ixodes* spp., RFB are transmitted by soft ticks *Carios* (= *Ornithodoros*) spp., and *B. anserina* is transmitted by soft ticks *Argas* spp. (Barbour and Hayes, 1986; Olsén, 2007; Elbir *et al.* 2013). Additionally, *B. anserina* can be transmitted through the ingestion or inoculation of faeces, fluids, and tissues (Olsén, 2007).

Soft ticks, particularly *C. capensis*, are commonly found on wild African penguins (Clarke and Kerry, 1993), and are likely responsible for the transmission of RFB to those birds (Yabsley *et al.* 2012). On the other hand, the hard ticks *Ixodes kerguelensis* and *I. uriae* are abundant in sub-Antarctic islands and are thought to play a key role in the transmission of LDB to king penguins (Olsén *et al.* 1995b; Gauthier-Clerc *et al.* 1999; Schramm *et al.* 2014).

Geographic distribution

RFB infects penguins in South Africa (Cape Town, Dassen Island) (Coles, 1941; Yabsley *et al.* 2012; Parsons *et al.* in preparation), and LDB is present in king penguins at Crozet Archipelago (Possession Island) (Olsén *et al.* 1995b; Schramm *et al.* 2014). The distribution of *Ixodes* spp. overlaps with penguin breeding habitat in Southern South America, Antarctic Peninsula, South Africa, Australia, New Zealand and at a number of sub-Antarctic islands (Fig. 3B), and LDB strains are broadly distributed in seabirds at a number of these locations (Olsén *et al.* 1995b; Olsén, 2007). Similarly, the distribution of *Carios* spp. overlaps with breeding colonies of penguins in the Galapagos Archipelago, Peru, Tristan da Cunha Archipelago, South Africa, Amsterdam and Saint-Paul Islands, Southeastern Australia, New Zealand and Chatham Islands (Fig. 3B).

Epidemiology and pathology

RFB occurs at low prevalence (blood smears: 0.9–1.1%) in African penguins undergoing rehabilitation (Yabsley *et al.* 2012; Parsons *et al.* in preparation); infection is more frequent in chicks (3.6%) than in juveniles (0.83%) and adults (0.14%). As previously discussed, approximately 50% of RFB-infected African penguins undergoing rehabilitation in South Africa are co-infected by *B. peircei* (Yabsley *et al.* 2012).

In only one RFB-infected African penguin studied by Yabsley *et al.* (2012) death was considered to result from *Borrelia* infection; that penguin presented signs of neurological disease (unsteady gait, circling, torticollis) and died after four days. On post-mortem examination, splenomegaly and hepatomegaly were noted and histological findings were consistent with relapsing fever: splenic reticuloendothelial hyperplasia

with haemosiderosis, lung congestion, and lymphocytic meningoencephalitis. On the other hand, LDB are generally considered non-pathogenic to seabirds (Olsén *et al.* 1995a, b; Olsén, 2007), and no external signs of illness were observed in LDB-infected king penguins (Schramm *et al.* 2014).

Serological studies

Gauthier-Clerc *et al.* (1999) tested king penguins with a passive haemagglutination commercial kit developed to detect human antibodies against LDB. No additional studies have employed this serological assay to test other penguin species, and it is unknown whether the assay cross-reacts with other *Borrelia* spp. or other spirochetes (see Magnarelli *et al.* 1987).

Implications for public health and conservation

Relapsing fever is a relevant disease for humans worldwide, including in South Africa, but it is presently unknown whether the RFB strains that infect African penguins could be the same involved in any of the few human cases recorded in South Africa (Yabsley *et al.* 2012; Elbir *et al.* 2013). Similarly, Lyme disease is relevant for humans, and seabirds are thought to play a role in the maintenance and transmission of LDB to humans and other mammals, especially at high latitudes (Olsén *et al.* 1995b). It seems probable that domestic and synanthropic animals play a much more significant role than penguins in transmitting this infection to humans (Gauthier-Clerc *et al.* 1999; Yabsley *et al.* 2012), however it is plausible that humans entering penguin colonies for research, tourism or guano/egg exploitation, or handling these birds in rehabilitation centers could be at risk of exposure to RFB or LDB.

LDB are generally non-pathogenic to seabirds (Olsén, 2007) and therefore are unlikely to be a conservation threat to penguins. On the other hand, RFB have been reported to cause mortality of an African penguin (Yabsley *et al.* 2012), an endangered species (IUCN, 2015); studies on the epidemiology and pathology of this pathogen in African penguins could therefore help clarifying its conservation significance.

NEMATODE MICROFILARIAE (FILARIASIS)

Microfilariae are early life stages of onchocercid nematodes (Filarioidea: Onchocercidae) that may occasionally be present in the blood. There are 17 genera of Onchocercidae known to infect birds, totaling over 160 species, of which only *Dirofilaria immitis* and *Pelecitus* spp. can also infect non-avian hosts (Sano *et al.* 2005; Bartlett, 2008). In the avian blood, microfilariae are extracellular densely stained linear structures, typically 100–250 µm long and 5–10 µm wide (Fig. 1). Adult worms can be

present at a broad variety of organs and tissues such as the skin, subcutaneous connective tissue, air sacs, heart and coelomic cavity (Friend and Franson, 1999; Anderson, 2000; Bartlett, 2008).

Species recorded in penguins

Phylogenetic analysis of microfilariae from the blood of Galapagos penguins revealed this is the same species as the one present in the blood of flightless cormorants (*Phalacrocorax harrisi*) at the Galapagos Archipelago. This parasite was closely related to mammalian-infecting Onchocercidae, but could not be conclusively identified (Merkel *et al.* 2007).

There are other instances in which Onchocercidae have been reported infecting penguins: adult *Paronchocerca straeleni* in the heart of a captive Galapagos penguin in the USA (Chabaud and Ball, 1964; Bartlett and Anderson, 1986), adult *D. immitis* in the heart of a captive Humboldt penguin in Japan (Sano *et al.* 2005), and multiple unidentified microfilariae in the eyelid skin of a Magellanic penguin undergoing rehabilitation in Brazil (Vanstreels *et al.* 2015a). In these cases, even though microfilariae were not observed in blood smears, they could have been present in the blood stream at some stage of the infection.

Distribution among penguin hosts

Microfilariae have only been observed in wild Galapagos penguins (Harmon *et al.* 1985; Merkel *et al.* 2007). However, other life stages of onchocercid worms have been documented in captive Galapagos and Humboldt penguins (Chabaud and Ball, 1964; Sano *et al.* 2005) and in a Magellanic penguin undergoing rehabilitation (Vanstreels *et al.* 2015a).

Vectors

The following insects have been incriminated in the transmission of avian-infecting onchocercids: biting midges (*Culicoides* spp.), chewing lice (*Austromenopon* spp., *Pseudomenopon pilosum*, *Trinoton anserinum*), mosquitoes (*Aedes taeniorhynchus*, *Armigeres subalbatus*, *Culex* spp., *Mansonia crassipes*), and black flies (*Simulium* spp.) (Anderson, 2000; Bartlett, 2008; Manrique-Saide *et al.* 2008). Ecological modelling suggests that *Aedes taeniorhynchus* is the most probable vector of microfilariae to Galapagos penguins (Siers *et al.* 2010; Bataille *et al.* 2012); this is corroborated by the detection of DNA from nematodes in blood meals of *Aedes taeniorhynchus* (Bataille *et al.* 2012).

Geographic distribution

Microfilariae were documented in the blood of penguins at the Galapagos Archipelago (Fernandina and

Isabela Islands) (Harmon *et al.* 1985; Merkel *et al.* 2007). However *Aedes taeniorhynchus*, its most probable vector, is distributed in salt marshes along the tropical and temperate coast of the Americas, including Peru, and could transmit onchocercid worms to wild and captive penguins in the region (Fig. 3C). Adult Onchocercidae have been reported infecting captive penguins in the USA (Chabaud and Ball, 1964) and Japan (Sano *et al.* 2005), and microfilariae were reported in the skin of penguins undergoing rehabilitation in southern Brazil (Vanstreels *et al.* 2015a).

Epidemiology and pathology

Local prevalence of microfilariae in Galapagos penguins ranges from 5.3 to 50% among locations (blood smears) (Merkel *et al.* 2007; Siers *et al.* 2010). Infection rate was higher in males than in females and was positively correlated to ambient temperature, precipitation and dry-season vegetation, whilst being negatively correlated to elevation and slope (Siers *et al.* 2010). The parasite often occurred with higher prevalence in sympatric flightless cormorants, suggesting this species might act as a reservoir of infection for penguins (Merkel *et al.* 2007). Infection rate of *Aedes taeniorhynchus* at these sites was relatively low (0.15%) (Manrique-Saide *et al.* 2008; Bataille *et al.* 2012).

Parasitaemia varied greatly among individuals, ranging from 0.04 to 12 parasites per low magnification microscope field (10× objective lens) (Merkel *et al.* 2007). With few exceptions in which they cause vasculitis, microfilariae are seldom pathogenic *per se*, and the most significant health implications tend to derive from the adult parasites (Bartlett, 2008). Because the infection site of the adult onchocercids recorded in Galapagos penguins is unknown, it is not currently possible to evaluate the health implications of these infections.

Implications for public health and conservation

The microfilariae detected in Galapagos penguins remain unidentified, but it seems unlikely that it could infect humans since the only onchocercid worm to infect both birds and humans is *D. immitis* (Bartlett, 2008), which produces pulmonary disease in the latter (Simón *et al.* 2005). However, it seems unlikely that penguins play a significant role as reservoirs of infection to humans, considering there is only one documented case of this parasite in a penguin, which is also the only known case of *D. immitis* in a bird (Sano *et al.* 2005). Considering the high prevalence and parasitaemia with which microfilariae were observed in Galapagos penguins, an endangered species (IUCN, 2015), studies to determine the identity, adult infection site and health

effects of these worms are urgent to determine their relevance as a conservation threat.

CONCLUDING REMARKS

Blood parasites are frequently studied through the examination of blood smears, which does not require an *a priori* decision on the parasites to be searched for. As a result, the fact that there is a much greater number of studies reporting some parasites but not others – for example, there are more than 50 studies reporting *Plasmodium* sp. but only one report of *Trypanosoma* sp. – suggests an actual difference in how common or widely distributed these parasites are. However, it is also possible that blood smears or blood collection methods perform differently for the detection of different parasite taxa, especially if some parasites tend to produce more acute infections than others or are distributed unevenly in the host's blood vessels (Holmstad *et al.* 2003; Valkiūnas, 2005; Garamszegi, 2010). Furthermore, sampling effort is not evenly distributed worldwide, and this review identifies a number of geographic areas in which future studies could identify blood parasites in wild and captive penguins (see Figs 2 and 3).

Among the blood parasites of penguins, *Plasmodium* sp. and *Leucocytozoon* sp. stand out as the most relevant for conservation, as both have been documented to cause the death of penguins in captivity and/or in the wild. However, other parasites such as *Babesia* sp., RFB and nematode microfilariae could also produce more subtle yet still significant impacts on the health and fitness of wild penguins. It is concerning that these parasites are known to infect wild populations of the three most endangered penguin species: Galapagos, yellow-eyed and African penguins. Considering that climate change is already changing the distribution and epidemiology of avian blood parasites (Garamszegi, 2011), the perspective of increased morbidity and mortality of these endangered penguins is troubling.

It is therefore clear that studies on the diagnosis, ecology, epidemiology and pathology of blood parasites of penguins will be valuable not only in furthering the advancement of parasitological science, but will also be important components of efforts for the conservation of these birds and their environments, especially in tropical and temperate regions.

ACKNOWLEDGEMENTS

We are grateful to Maurice R. Alley, Marcos Amaku, Lisa S. Argilla, Nayara O. Belo, Renata C. C. Bhering, Elizabeth Brown, Nicholas Carlile, Sabrina Epiphanyo, Eliana L. Faquim-Mauro, Francisco C. Ferreira-Junior, Daniel González-Acuña, Miguel Grilo, Renata Hurtado, Cristiane K. M. Kolesnikovas, Twinkles Kuwata, Iris I. Levin, Luis F. Mayorga, Simon P. McDonald, Jorge

Oyakawa, Nola J. Parsons, Michael A. Peirce, Rodolfo Pinho Silva-Filho, Patricia Silveira, Paul Thompson, Valeria Ruoppolo, Monique J. van Rensburg, Marcela Uhart, Charles Van Riper III, Peter Vertigan, and Eric J. Woehler for their direct and indirect contributions to the manuscript. Penguin breeding distribution data was obtained through the IUCN Red List website.

FINANCIAL SUPPORT

This work was supported by the São Paulo Research Foundation (FAPESP) through grants 2009/53956–9 (R.E.T.V.) and 2010/51801–5 (J.L.C.D., R.E.T.V.), by the National Council of Technological and Scientific Development (CNPq) (J.L.C.D., R.E.T.V., E.M.B.) and the Brazilian Federal Agency for the Support and Evaluation of Graduate Education (CAPES) (R.E.T.V., E.M.B.).

REFERENCES

- Alley, M. R., Morgan, K. J., Gill, J. M. and Hocken, A. G.** (2004). Diseases and causes of mortality in yellow-eyed penguins, *Megadyptes antipodes*. *Kokako* **11**, 18–23.
- Allison, F. R., Desser, S. S. and Whitten, L. K.** (1978). Further observations on the life cycle and vectors of the haemosporidian *Leucocytozoon tawaki* and its transmission to the Fiordland crested penguin. *New Zealand Journal of Zoology* **5**, 371–374.
- Anderson, R. C.** (2000). *Nematode Parasites of Vertebrates: their Development and Transmission*. CABI Publishing, New York, USA.
- Argilla, L. S., Howe, L., Gartrell, D. and Alley, M. R.** (2013). High prevalence of *Leucocytozoon* spp. in the endangered yellow-eyed penguin (*Megadyptes antipodes*) in the sub-Antarctic regions of New Zealand. *Parasitology* **140**, 672–682.
- Atkinson, C. T.** (2008a). *Haemoproteus*. In *Parasitic Diseases of Wild Birds* (ed. Atkinson, C. T., Thomas, N. J. and Hunter, D. B.), pp. 13–34. Wiley-Blackwell, Ames, USA.
- Atkinson, C. T.** (2008b). Avian malaria. In *Parasitic Diseases of Wild Birds* (ed. Atkinson, C. T., Thomas, N. J. and Hunter, D. B.), pp. 35–53. Wiley-Blackwell, Ames, USA.
- Atkinson, C. T. and Lapointe, D. A.** (2009). Introduced avian diseases, climate change, and the future of Hawaiian honeycreepers. *Journal of Avian Medicine and Surgery* **23**, 53–63.
- Atkinson, C. T. and Van Riper, C., III** (1991). Pathogenicity and epizootiology of avian haematzoa: *Plasmodium*, *Leucocytozoon*, and *Haemoproteus*. In *Bird-Parasite Interactions: Ecology, Evolution and Behaviour* (ed. Loye, J. E. and Zuk, M.), pp. 19–48. Oxford University Press, New York, USA.
- Atlas of Living Australia (ALA)** (2014). *Records of Hippoboscidae in the Queen Victoria Museum and Art Gallery*. Queen Victoria Museum and Art Gallery, Inveresk, Australia. <http://bie.ala.org.au/species/hippoboscidae/>.
- Aybar, C. A. V., Juri, M. J. D., De Grosso, M. S. L. and Spinelli, G. R.** (2010). Species diversity and seasonal abundance of *Culicoides* biting midges in northwestern Argentina. *Medical and Veterinary Entomology* **24**, 95–98.
- Bak, U.-B., Park, J.-C. and Lim, Y.-J.** (1984). An outbreak of malaria in penguins at the Farm-land Zoo. *Korean Journal of Parasitology* **22**, 267–272.
- Baker, J. R.** (1956). Studies on *Trypanosoma avium* Danilewski 1885 – III. Life cycle in vertebrate and invertebrate hosts. *Parasitology* **46**, 335–352.
- Baker, J. R. and Bird, R. G.** (1968). *Trypanosoma avium*: fine structure of all developmental stages. *Journal of Protozoology* **15**, 298–308.
- Banks, K. L.** (1978). Binding of *Trypanosoma congolense* to the walls of small blood vessels. *Journal of Protozoology* **25**, 241–245.
- Barbosa, A., Benzal, J., Vidal, V., D'Amico, V., Coria, N., Diaz, J., Motas, M., Palacios, M. J., Cuervo, J. J., Ortiz, J. and Chitimia, L.** (2011). Seabird ticks (*Ixodes uriae*) distribution along the Antarctic Peninsula. *Polar Biology* **34**, 1621–1624.
- Barbour, A. G. and Hayes, S. F.** (1986). Biology of *Borrelia* species. *Microbiological Review* **50**, 381–400.
- Bartlett, C. M.** (2008). Filarioid nematodes. In *Parasitic Diseases of Wild Birds* (ed. Atkinson, C. T., Thomas, N. J. and Hunter, D. B.), pp. 439–462. Wiley-Blackwell, Ames, USA.
- Bartlett, C. M. and Anderson, R. C.** (1986). *Paronchocerca struthionis* n.sp. (Nematoda: Filarioidea) from ostriches (*Struthio camelus*), with a redescription of *Paronchocerca ciconiarum* Peters, 1936 and a review of the genus. *Canadian Journal of Zoology* **64**, 2480–2491.
- Bataille, A., Fournié, G., Cruz, M., Cedeño, V., Parker, P. G., Cunningham, A. A. and Goodman, S. J.** (2012). Host selection and parasite infection in *Aedes taeniorhynchus*, endemic disease vector in the Galápagos Islands. *Infection, Genetics and Evolution* **12**, 1831–1841.
- Beadell, J. S. and Fleischer, R. C.** (2005). A restriction enzyme–based assay to distinguish between avian hemosporeans. *Journal of Parasitology* **91**, 683–685.
- Beadell, J. S., Ishtiaq, F., Covas, R., Melo, M., Warren, B. H., Atkinson, A. T., Bensch, S., Graves, G. R., Jhala, Y. V., Peirce, M. A., Rahmani, A. R., Fonseca, D. M. and Fleischer, R. C.** (2006). Global phylogeographic limits of Hawaii's avian malaria. *Proceedings of the Royal Society B* **273**, 2935–2944.
- Becker, D. A. and Holloway, H. L.** (1968). A survey for Haematzoa in Antarctic vertebrates. *Transactions of the American Microscopical Society* **87**, 354–360.
- Beier, J. C. and Stoskopf, M. K.** (1980). The epidemiology of avian malaria in black-footed penguins (*Spheniscus demersus*). *Journal of Zoo Animal Medicine* **11**, 99–105.
- Beier, J. C. and Trpis, M.** (1981). Incrimination of natural culicine vectors which transmit *Plasmodium elongatum* to penguins at the Baltimore Zoo. *Canadian Journal of Zoology* **59**, 470–475.
- Bennett, G. F., Earlé, R. A., Du Toit, H. and Huchzermeyer, F. W.** (1992). A host-parasite catalogue of the Haematzoa of the sub-Saharan birds. *Onderstepoort Journal of Veterinary Research* **59**, 1–73.
- Borkent, A.** (2013). *World Species of Biting Midges (Diptera: Ceratopogonidae)*. Illinois Natural History Survey, Champaign, USA. <http://www.inhs.illinois.edu/files/8413/4219/9566/CeratopogonidaeCatalog.pdf>.
- Botes, A.** (2004). Immunological and epidemiological investigations in South African ostriches and penguins. Ph.D. thesis (Biochemistry). University of Stellenbosch, Stellenbosch, Republic of South Africa, 237 pp.
- Brossy, J. J.** (1992). Malaria in wild and captive jackass penguins *Spheniscus demersus* along the Southern African coast. *Ostrich* **63**, 10–12.
- Brossy, J. J.** (1993). Haemoparasites in the African (jackass) penguin (*Spheniscus demersus*). *Penguin Conservation* **1993**, 20.
- Brossy, J. J., Plöös, A. L., Blackbeard, J. M. and Kline, A.** (1999). Diseases acquired by captive penguins: what happens when they are released into the wild? *Marine Ornithology* **27**, 185–186.
- Browne, T., Lalas, C., Mattern, T. and van Heezik, Y.** (2011). Chick starvation in yellow-eyed penguins: evidence for poor diet quality and selective provisioning of chicks from conventional diet analysis and stable isotopes. *Austral Ecology* **36**, 99–108.
- Buckle, K. N., Young, M. J. and Alley, M. R.** (2014). Investigation of an outbreak of craniofacial deformity in yellow-eyed penguin (*Megadyptes antipodes*) chicks. *New Zealand Veterinary Journal* **2014**, 1–8.
- Bueno, M. G., Lopez, R. P. G., Menezes, R. M. T., Costa-Nascimento, M. J., Lima, G. F. M. C., Araújo, R. A. S., Guida, F. J. V. and Kirchgatter, K.** (2010). Identification of *Plasmodium relictum* causing mortality in penguins (*Spheniscus magellanicus*) from São Paulo Zoo, Brazil. *Veterinary Parasitology* **173**, 123–127.
- Cabana, A. L., Vanstreels, R. E. T., Xavier, M. O., Osório, L. G., Adornes, A. C., Leite, A. M., Soares, M. P., Silva-Filho, R. P., Catão-Dias, J. L. and Meireles, M. C. A.** (2014). Lethal concurrent avian malaria and aspergillosis in Magellanic penguin (*Spheniscus magellanicus*). *Boletín Chileno de Ornitología* **20**, 28–32.
- Campos, S. D. E., Pires, J. R., Nascimento, C. L., Dutra, G., Torres-Filho, R. A., Toma, H. K., Brener, B. and Almosny, N. R. P.** (2014). Analysis of hematologic and serum chemistry values of *Spheniscus magellanicus* with molecular detection of avian malarial parasites (*Plasmodium* spp.). *Pesquisa Veterinária Brasileira* **34**, 1236–1242.
- Cannell, B. L., Krasnec, K. V., Campbell, K., Jones, H. I., Miller, R. D. and Stephens, N.** (2013). The pathology and pathogenicity of a novel *Haemoproteus* spp. infection in wild Little Penguins (*Eudyptula minor*). *Veterinary Parasitology* **197**, 74–84.
- Cannell, B. L., Krasnec, K. V., Campbell, K., Jones, H. I., Miller, R. D. and Stephens, N.** (2014). Corrigendum to “The pathology and pathogenicity of a novel *Haemoproteus* spp. infection in wild Little Penguins (*Eudyptula minor*)” [Vet. Parasitol. 197 (1–2) (2013) 74–84]. *Veterinary Parasitology* **205**, 416.
- Carvajal, E. R. and Alvarado, P. M.** (2009). Pesquisa de *Plasmodium* spp. em pingüinos de Magallanes (*Spheniscus magellanicus*) de la Región de los Ríos: malaria aviar como nueva patología de interés en la avifauna local. *Boletín Veterinario Oficial* **10**, 1–4.
- Cereghetti, N., Wenker, C., Hoby, S., Müller, P., Marti, H. and Lengeler, C.** (2012). Avian malaria and its prevention strategies in the Zoo Basel. In *Proceedings of the Joint Annual Meeting of the Swiss Society for Infectious Diseases*, p. 169. Swiss Society for Hospital Hygiene, Swiss

- Society for Microbiology and Swiss Society for Tropical Medicine and Parasitology, St. Gallen, Switzerland. <http://kongress.imk.ch/sginf2012/untitled1>
- Chabaud, A. G. and Ball, G. H.** (1964). Filarie cardiaque chez un Manchot des Galapagos. *Annales de Parasitologie* **39**, 621–626.
- Chauvin, A., Moreau, E., Bonnet, S., Plantard, O. and Malandrin, L.** (2009). *Babesia* and its hosts: adaptation to long-lasting interactions as a way to achieve efficient transmission. *Veterinary Research* **40**, 1–18.
- Clarke, J. R. and Kerry, K. R.** (1993). Diseases and parasites of penguins. *Korean Journal of Polar Research* **4**, 79–96.
- Coles, J. D. W. A.** (1941). An epizootic in seabirds: a visit to Dassen and Malgas Islands. *Journal of the South African Veterinary Medical Association* **12**, 23–30.
- Colombelli-Negrèl, D. and Kleindorfer, S.** (2014). *Penguin Monitoring and Conservation Activities in the Gulf St Vincent July 2013 – June 2014*. Flinders University, Adelaide, Australia.
- Cosgrove, C. L., Day, K. P. and Sheldon, B. C.** (2006). Coamplification of *Leucocytozoon* by PCR diagnostic tests for avian malaria: a cautionary note. *Journal of Parasitology* **92**, 1362–1365.
- Cranfield, M. R., Graczyk, T. K., Beall, F. B., Ialeggio, D. M., Shaw, M. L. and Skjoldager, M. L.** (1994). Subclinical avian malaria infections in African black-footed penguins (*Spheniscus demersus*) and induction of parasite recrudescence. *Journal of Wildlife Diseases* **30**, 372–376.
- Crawford, R. J. M., Altwegg, R., Barham, B. J., Durant, J. M., Dyer, B. M., Geldenhuys, D., Makhado, A. B., Pichegru, L., Ryan, P. G., Underhill, L. G., Upfold, L., Visagie, J., Waller, L. J. and Whittington, P. A.** (2011). Collapse of South Africa's penguins in the early 21st century. *African Journal of Marine Science* **33**, 139–156.
- Cunningham, M., Gibbs, P., Rogers, T., Spielman, D. and Walraven, E.** (1993). *Ecology and Health of the Little Penguin Eudyptula Minor Near Sydney: a Report Prepared for the Water Board*. Taronga Zoo, Sydney, Australia.
- Cutler, S. J.** (2006). Possibilities for relapsing fever reemergence. *Emerging Infectious Diseases* **12**, 369–374.
- Desser, S. S. and Allison, F.** (1979). Aspects of the sporogonic development of *Leucocytozoon tawaki* of the Fiordland crested penguin in its primary vector, *Austrosimulium unguatum*: an ultrastructural study. *Journal of Parasitology* **65**, 737–744.
- Diamond, L. S. and Herman, C. M.** (1954). Incidence of trypanosomes in the Canada Goose as revealed by bone marrow culture. *Journal of Parasitology* **40**, 195–202.
- Dietrich, M., Gómez-Díaz, E. and McCoy, K. D.** (2011). Worldwide distribution and diversity of seabird ticks: implications for the ecology and epidemiology of tick-borne pathogens. *Vector Borne Zoonotic Diseases* **11**, 453–470.
- Dinhopl, N., Mostegl, M. M., Richter, B., Nedorost, N., Maderner, A., Fragner, K. and Weissenböck, H.** (2011). Application of *in-situ* hybridization for the detection and identification of avian malaria parasites in paraffin wax-embedded tissues from captive penguins. *Avian Pathology* **40**, 315–320.
- Dinhopl, N., Nedorost, N., Mostegl, M. M., Weissenbacher-Lang, C. and Weissenböck, H.** (2015). *In situ* hybridization and sequence analysis reveal an association of *Plasmodium* spp. with mortalities in wild passerine birds in Austria. *Parasitology Research* **114**, 1455–1462.
- Domrow, R.** (1979). Dermanyssine mites from Australian birds. *Records of the Western Australian Museum* **7**, 403–413.
- Donovan, T. A., Schrenzel, M., Tucker, T. A., Pessier, A. P. and Stalis, I. H.** (2008). Hepatic hemorrhage, hemocoelom, and sudden death due to *Haemoproteus* infection in passerine birds: eleven cases. *Journal of Veterinary Diagnostic Investigation* **20**, 304–313.
- Dumbleton, L. J.** (1963). The classification and distribution of the Simuliidae (Diptera) with particular reference to the genus *Austrosimulium*. *New Zealand Journal of Science* **6**, 320–357.
- Earlé, R. A., Bennett, G. F. and Brossy, J. J.** (1992). First African record of *Leucocytozoon tawaki* (Apicomplexa: Leucocytozoidae) from the jackass penguin *Spheniscus demersus*. *South African Journal of Zoology* **27**, 89–90.
- Earlé, R. A., Huchzermeyer, F. W., Bennett, G. F. and Brossy, J. J.** (1993). *Babesia peircei* sp. nov. from the jackass penguin. *African Zoology* **28**, 88–90.
- Ejiri, H., Sato, Y., Sawai, R., Sasaki, E., Matsumoto, R., Ueda, M., Higa, Y., Tsuda, Y., Omori, S., Murata, K. and Yukawa, M.** (2009). Prevalence of avian malaria parasite in mosquitoes collected at a zoological garden in Japan. *Parasitology Research* **105**, 629–633.
- Ejiri, H., Sato, Y., Kim, K.-S., Hara, T., Tsuda, Y., Imura, T., Murata, K. and Yukawa, M.** (2011). Entomological study on transmission of avian malaria parasites in a zoological garden in Japan: bloodmeal identification and detection of avian malaria parasite DNA from blood-fed mosquitoes. *Journal of Medical Entomology* **48**, 600–607.
- Elbir, H., Raoult, D. and Drancourt, M.** (2013). Review article: relapsing fever Borreliae in Africa. *American Journal of Tropical Medicine and Hygiene* **89**, 288–292.
- Fallis, A. M., Bisset, S. A. and Allison, F. R.** (1976). *Leucocytozoon tawaki* n.sp. (Eucoccidia: Leucocytozoidae) from the penguin *Eudyptes pachyrhynchus*, and preliminary observations on its development in *Austrosimulium* spp. (Diptera: Simuliidae). *New Zealand Journal of Zoology* **3**, 11–16.
- Fantham, H. B. and Porter, A.** (1944). On a *Plasmodium* (*Plasmodium relictum* var. *spheniscidae*, n. var.), observed in four species of penguins. *Proceeding of the Zoological Society of London* **114**, 279–292.
- Felippe-Bauer, M. L., Cáceres, A., Silva, C. S., Valderrama-Bazan, W., Gonzales-Perez, A. and Costa, J. M.** (2008). New records of *Culicoides* Latreille (Diptera: Ceratopogonidae) from Peruvian Amazonian region. *Biota Neotropica* **8**, 33–38.
- Fix, A. S., Waterhouse, C., Greiner, E. C. and Stoskopf, M. K.** (1988). *Plasmodium relictum* as a cause of avian malaria in wild-caught Magellanic penguins (*Spheniscus magellanicus*). *Journal of Wildlife Diseases* **24**, 610–619.
- Fleischman, R. W., Squire, R. A., Sladen, W. J. L. and Moore, J.** (1968a). Pathologic confirmation of malaria (*Plasmodium elongatum*) in African penguins (*Spheniscus demersus*). *Bulletin of the Wildlife Diseases Association* **4**, 133–135.
- Fleischman, R. W., Squire, R. A., Sladen, W. J. L. and Melby, E. C., Jr.** (1968b). Malaria (*Plasmodium elongatum*) in captive African penguins (*Spheniscus demersus*). *Journal of the American Veterinary Medical Association* **153**, 928–935.
- Forrester, D. J. and Greiner, E. C.** (2008). Leucocytozoonosis. In *Parasitic Diseases of Wild Birds* (ed. Atkinson, C. T., Thomas, N. J. and Hunter, D. B.), pp. 54–107. Wiley-Blackwell, Ames, USA.
- Friend, M. and Franson, J. C.** (1999). *Field Manual of Wildlife Diseases: General Field Procedures and Diseases of Birds*. United States Geological Survey, Washington, USA.
- Garamszegi, L. Z.** (2010). The sensitivity of microscopy and PCR-based detection methods affecting estimates of prevalence of blood parasites in birds. *Journal of Parasitology* **96**, 1197–1203.
- Garamszegi, L. Z.** (2011). Climate change increases the risk of malaria in birds. *Global Change Biology* **17**, 1751–1759.
- Gaston, K. J., Jones, A. G., Hänel, C. and Chown, S. L.** (2003). Rates of species introduction to a remote oceanic island. *Proceedings of the Royal Society B* **270**, 1091–1098.
- Gauthier-Clerc, M., Jaulhac, B., Frenot, Y., Bachelard, C., Monteil, H., Le Maho, Y. and Handrich, Y.** (1999). Prevalence of *Borrelia burgdorferi* (the Lyme disease agent) antibodies in king penguin *Aptenodytes patagonicus* in Crozet Archipelago. *Polar Biology* **22**, 141–143.
- Gill, J. M. and Darby, J. T.** (1993). Deaths in yellow-eyed penguins (*Megadyptes antipodes*) on the Otago Peninsula during the summer of 1990. *New Zealand Veterinary Journal* **41**, 39–42.
- González-Acuña, D., Hernández, J., Moreno, L., Herrman, B., Palma, R., Latorre, A., Medina-Vogel, G., Kinsella, M. J., Martín, N., Araya, K., Torres, I., Fernandez, N. and Olsén, B.** (2013). Health evaluation of wild gentoo penguins (*Pygoscelis papua*) in the Antarctic Peninsula. *Polar Biology* **36**, 1749–1760.
- Gough, R. E., Drury, S. E., Welchman, D. B., Chitty, J. R. and Summerhays, G. E. S.** (2002). Isolation of birnavirus and reovirus-like agents from penguins in the United Kingdom. *Veterinary Record* **151**, 422–424.
- Graczyk, T. K., Cranfield, M. R. and Shift, C. J.** (1993). ELISA method for detecting anti-*Plasmodium relictum* and anti-*Plasmodium elongatum* antibody in infected duckling sera using *Plasmodium falciparum* antigens. *Journal of Parasitology* **79**, 879–885.
- Graczyk, T. K., Cranfield, M. R., Mccutchan, T. F. and Bicknese, E. J.** (1994a). Characteristics of naturally acquired avian malaria infections in naive juvenile African black-footed penguins (*Spheniscus demersus*). *Parasitology Research* **80**, 634–637.
- Graczyk, T. K., Cranfield, M. R., Skjoldager, M. L. and Shaw, M. L.** (1994b). An ELISA for detecting anti-*Plasmodium* spp. antibodies in African black-footed penguins (*Spheniscus demersus*). *Journal of Parasitology* **80**, 60–66.
- Graczyk, T. K., Shaw, M. L., Cranfield, M. R. and Beall, F. B.** (1994c). Hematologic Characteristics of avian malaria cases in African black-footed penguins (*Spheniscus demersus*) during the first outdoor exposure season. *Journal of Parasitology* **80**, 302–308.
- Graczyk, T. K., Cranfield, M. R., Shaw, M. L. and Craig, L. E.** (1994d). Maternal antibodies against *Plasmodium* spp. in African black-footed penguin (*Spheniscus demersus*) chicks. *Journal of Wildlife Diseases* **30**, 365–371.
- Graczyk, T. K., Brossy, J. J., Plös, A. and Stoskopf, M. K.** (1995a). Avian malaria seroprevalence in Jackass penguins (*Spheniscus demersus*) in South Africa. *Journal of Parasitology* **81**, 703–707.

- Graczyk, T. K., Cockrem, J. F., Cranfield, M. R., Darby, J. T. and Moore, P. (1995b). Avian malaria seroprevalence in wild New Zealand penguins. *Parasite* **2**, 401–405.
- Graczyk, T. K., Cranfield, M. R., Brossy, J. J., Cockrem, J. F., Jouventin, P. and Seddon, P. J. (1995c). Detection of avian malaria infections in wild and captive penguins. *Journal of the Helminthological Society of Washington* **62**, 135–141.
- Graczyk, T. K., Brossy, J. J., Sanders, M. I., Dubey, J. P., Plös, A. and Stoskopf, M. K. (1996). Immunological survey of babesiosis (*Babesia peircei*) and toxoplasmosis in Jackass penguins in South Africa. *Parasite* **4**, 313–319.
- Greenberg, A. E., Schable, C. A., Sulzer, A. J., Collins, W. E. and Nguyen-Dinh, P. (1986). Evaluation of serological cross-reactivity between antibodies to *Plasmodium* and HLTV-III/LAV. *Lancet* **2**, 247–249.
- Grilo, M. L. A. (2014). Characterization of infection by malaria parasites in penguins housed in zoological collections. Master's degree dissertation (Veterinary Medicine). Lisbon University, Portugal.
- Grim, K. C., van der Merwe, E., Sullivan, M., Parsons, N., McCutchan, T. F. and Cranfield, M. (2003). *Plasmodium juxtanculare* associated with mortality in black-footed penguins (*Spheniscus demersus*) admitted to a rehabilitation center. *Journal of Zoo and Wildlife Medicine* **34**, 250–255.
- Grim, K. C., McCutchan, T., Li, J., Sullivan, M., Graczyk, T. K., McConkey, G. and Cranfield, M. (2004). Preliminary results of an anticircumsporozoite DNA vaccine trial for protection against avian malaria in captive African Black-footed penguins. *Journal of Zoo and Wildlife Medicine* **35**, 154–161.
- Griner, L. A. and Sheridan, B. W. (1967). Malaria (*Plasmodium relictum*) in penguins at the San Diego Zoo. *Veterinary Clinical Pathology* **1**, 7–17.
- Grünberg, W. and Kutzer, E. (1963). Infektionen mit *Plasmodium praecox* bei Humboldt- (*Spheniscus humboldti*) und Brillenpinguinen (*Spheniscus magellanicus*) (in German). *Zentralblatt für Bakteriologie, Parasitenkunde, Infektionskrankheiten und Hygiene* **189**, 511–520.
- Guichard, S., Guis, H., Tran, A., Garros, C., Balenghien, T. and Kriticos, D. J. (2014). Worldwide niche and future potential distribution of *Culicoides imicola*, a major vector of bluetongue and african horse sickness viruses. *Plos ONE* **9**, e112491.
- Haag, J., O'huigin, C. and Overath, P. (1998). The molecular phylogeny of trypanosomes - evidence for an early divergence of the Salivaria. *Molecular and Biochemical Parasitology* **91**, 37–49.
- Hamilton, P. B., Stevens, J. R., Gaunt, M. W., Gidley, J. and Gibson, W. C. (2004). Trypanosomes are monophyletic: evidence from genes for glyceraldehyde phosphate dehydrogenase and small subunit ribosomal RNA. *International Journal of Parasitology* **34**, 1393–1404.
- Hänel, C., Chown, S. L. and Davies, L. (1998). Records of alien insect species from sub-Antarctic Marion and South Georgia Islands. *African Entomology* **6**, 366–369.
- Harmon, W., Harbecker, A. and Clark, W. A. (1985). *Report to the Charles Darwin Research Station*. Charles Darwin Research Station, Puerto Ayora, Ecuador.
- Harvey, C. and Alley, M. R. (2008). Current veterinary laboratory surveillance of avian haemoparasitic diseases in New Zealand. *Kokako* **15**, 15–19.
- Hellgren, O., Waldenström, J. and Bensch, S. (2004). A new PCR assay for simultaneous studies of *Leucocytozoon*, *Plasmodium*, and *Haemoproteus* from avian blood. *Journal of Parasitology* **90**, 797–802.
- Herman, C. M., Kocan, R. M., Snyder, E. L. and Knisley, J. O. (1968). *Plasmodium elongatum* from a penguin. *Bulletin of the Wildlife Diseases Association* **4**, 132.
- Herman, C. M., Gray, C., Knisley, J. O., Jr. and Kocan, R. M. (1974). Malarial infections in the avian collection of the National Zoo in Washington, D.C., USA and in indigenous birds. In *Proceedings of the International Congress of Parasitology*, Munich, Germany.
- Hill, A. G. (2008). An investigation of *Leucocytozoon* in the endangered yellow-eyed penguin (*Megadyptes antipodes*). Master's degree dissertation (Veterinary Science). Massey University, New Zealand.
- Hill, A. G., Howe, L., Gartrell, B. D. and Alley, M. R. (2010). Prevalence of *Leucocytozoon* spp. in the endangered yellow-eyed penguin *Megadyptes antipodes*. *Parasitology* **137**, 1477–1485.
- Hocken, A. G. (2005). Necropsy findings in yellow-eyed penguins (*Megadyptes antipodes*) from Otago, New Zealand. *New Zealand Journal of Zoology* **32**, 1–8.
- Holder, P. (1999). The mosquitoes of New Zealand and their animal disease significance. *Surveillance* **26**, 12–15.
- Holmstad, P. R., Anwar, A., Iezhova, T. and Skorping, A. (2003). Standard sampling techniques underestimate prevalence of avian hematozoa in willow ptarmigan (*Lagopus lagopus*). *Journal of Wildlife Diseases* **39**, 354–358.
- Hornby, H. E. and Bailey, H. W. (1931). Diurnal variation in the concentration of *Trypanosoma congolense* in the blood-vessels of the Ox's ear. *Transactions of the Royal Society of Tropical Medicine and Hygiene* **24**, 557–564.
- Huff, C. G. (1942). Schizogony and gametocyte development in *Leucocytozoon simondi*, and comparisons with *Plasmodium* and *Haemoproteus*. *Journal of Infectious Diseases* **71**, 18–32.
- Huff, G. C. and Shiroishi, T. S. (1962). Natural infection of Humboldt's penguin with *Plasmodium elongatum*. *Journal of Parasitology* **48**, 495.
- International Union for Conservation of Nature (IUCN) (2015). *The IUCN Red List of Threatened Species Version 2015-3*. International Union for Conservation of Nature, Gland, Switzerland. <http://www.iucnredlist.org/>.
- Jones, H. I. and Shellam, G. R. (1999a). The occurrence of blood-inhabiting protozoa in captive and free-living penguins. *Polar Biology* **21**, 5–10.
- Jones, H. I. and Shellam, G. R. (1999b). Blood parasites in penguins, and their potential impact on conservation. *Marine Ornithology* **27**, 181–184.
- Jones, H. I. and Woehler, E. J. (1989). A new species of blood trypanosome from little penguins (*Eudyptula minor*) in Tasmania. *Journal of Protozoology* **36**, 389–390.
- Jouventin, P., Cuthbert, R. J. and Ottvall, R. (2006). Genetic isolation and divergence in sexual traits: evidence for the northern rockhopper penguin *Eudyptes moseleyi* being a sibling species. *Molecular Ecology* **15**, 3413–3423.
- Kearney, M., Porter, W. P., Williams, C., Ritchie, S. and Hoffmann, A. A. (2009). Integrating biophysical models and evolutionary theory to predict climatic impacts on species' ranges: the dengue mosquito *Aedes aegypti* in Australia. *Functional Ecology* **23**, 528–538.
- Kerry, K. R., Irvine, L., Beggs, A. and Watts, J. (2009). An unusual mortality event among Adélie penguins in the vicinity of Mawson station, Antarctica. In *Health of Antarctic Wildlife: a Challenge for Science and Policy* (ed. Kerry, K. R. and Riddle, M. J.), pp. 107–112. Springer, London, UK.
- King, S. D., Harper, G. A., Wright, J. B., McInnes, J. C., van der Lubbe, J. E., Dobbins, M. L. and Murray, S. J. (2012). Site-specific reproductive failure and decline of a population of the endangered yellow-eyed penguin: a case for foraging habitat quality. *Marine Ecology Progress Series* **467**, 233–244.
- Ko, K.-N., Kang, S.-C., Jung, J.-Y., Bae, J.-H. and Kim, J.-H. (2008). Avian malaria associated with *Plasmodium* spp. infection in a penguin in Jeju Island. *Korean Journal of Veterinary Research* **48**, 197–201.
- Laird, M. (1950). Some blood parasites of New Zealand. *Zoology Publications from Victoria University of Wellington* **5**, 1–20.
- Laird, M. (1952). Protozoological studies at Macquarie Islands. *Transactions of the Royal Society of New Zealand* **79**, 583–588.
- Laird, M. (1961). A lack of avian and mammalian Haematozoa in the Antarctic and Canadian Arctic. *Canadian Journal of Zoology* **39**, 209–213.
- Laird, M. and Van Riper, C. (1981). Questionable reports of *Plasmodium* from birds in Hawaii, with the recognition of *P. relictum* ssp. *capistranae* (Russel, 1932) as the avian malaria parasite there. In *Parasitological Topics: a Presentation Volume to P.C.C. Garnham, F.R.S. on the Occasion of his 80th Birthday 1981* (ed. Canning, E. U.), pp. 159–165. Allen Press, Lawrence, USA.
- Landcare Research (2015). *Species in NZ: Ochleratus (Halaedes) Australis*. Landcare Research, Lincoln, New Zealand. <http://www.landcareresearch.co.nz/science/plants-animals-fungi/animals/invertebrates/invasive-invertebrates/mosquitoes/species-in-nz/ochleratus-australis>.
- Leclerc, A., Chavatte, J.-M., Landau, I., Snonnou, G. and Petit, T. (2014). Morphologic and molecular study of hemoparasites in wild corvids and evidence of sequence identity with *Plasmodium* DNA detected in captive black-footed penguins (*Spheniscus demersus*). *Journal of Zoo and Wildlife Medicine* **45**, 577–588.
- Levin, I. I. and Parker, P. G. (2011). Haemosporidian parasites: impacts on avian hosts. In *Fowler's Zoo and Wild Animal Medicine - Current Therapy, Volume 7* (ed. Miller, R. E. and Fowler, M.), pp. 356–363. Elsevier Saunders, St. Louis, USA.
- Levin, I. I., Outlaw, D. C., Vargas, F. H. and Parker, P. G. (2009). *Plasmodium* blood parasite found in endangered Galapagos penguins (*Spheniscus mendiculus*). *Biological Conservation* **142**, 3191–3195.
- Levin, I. I., Valkiūnas, G., Santiago-Alarcon, D., Cruz, L. L., Iezhova, T. A., O'Brien, S. L., Hailer, F., Dearborn, D., Shreiber, E. A., Fleischer, R. C., Ricklefs, R. E. and Parker, P. G. (2011). Hippoboscids-transmitted *Haemoproteus* parasites (Haemosporida) infect Galapagos pelecaniform birds: evidence from molecular and morphological studies, with a description of *Haemoproteus iwa*. *International Journal of Parasitology* **41**, 1019–1027.
- Levin, I. I., Valkiūnas, G., Iezhova, T. A., O'Brien, S. L. and Parker, P. G. (2012). Novel *Haemoproteus* species (Haemosporida: Haemoproteidae) from the swallow-tailed gull (Lariidae), with remarks on the host range of hippoboscids-transmitted avian hemoproteids. *Journal of Parasitology* **98**, 847–854.

- Levin, I. I., Zwiars, P., Deem, S. L., Geest, E. A., Higashiguchi, J. M., Iezhova, T. A., Jiménez-Uzcátegui, G., Kim, D. H., Morton, J. P., Perlut, N. G., Renfrew, R. B., Sari, E. H. R., Valkiūnas, G. and Parker, P. G. (2013). Multiple lineages of avian malaria parasites (*Plasmodium*) in the Galapagos islands and evidence for arrival via migratory birds. *Conservation Biology* **27**, 1366–1377.
- Magnarelli, L. A., Anderson, J. F. and Johnson, R. C. (1987). Cross-reactivity in serological tests for Lyme disease and other spirochetal infections. *Journal of Infectious Diseases* **156**, 183–188.
- Manrique-Saide, P., Bolio-González, M., Sauri-Arceo, C., Dzib-Florez, S. and Zapata-Peniche, A. (2008). *Ochlerotatus taeniorhynchus*: a probable vector of *Dirofilaria immitis* in coastal areas of Yucatan, Mexico. *Journal of Medical Entomology* **45**, 169–171.
- Martinsen, E. S. and Perkins, S. L. (2013). The diversity of *Plasmodium* and other Haemosporidians: the intersection of taxonomy, phylogenetics and genomics. In *Malaria Parasites: Comparative Genomics, Evolution and Molecular Biology* (ed. Carlton, J. M., Perkins, S. L. and Deitsch, K. W.), pp. 1–15. Caister Academic Press, Norfolk, USA.
- Martinsen, E. S., Perkins, S. L. and Schall, J. J. (2008). A three-genome phylogeny of malaria parasites (*Plasmodium* and closely related genera): evolution of life-history traits and host switches. *Molecular Phylogenetics and Evolution* **47**, 261–273.
- Mawson, P. M., Angel, L. M. and Edmonds, S. J. (1986). A checklist of helminths from Australian birds. *Records of the Australian Museum* **19**, 219–325.
- McConkey, G. A., Li, J., Rogers, M. J., Seeley, D. C., Graczyk, T. K., Cranfield, M. R. and McCutchan, T. C. (1996). Parasite diversity in an endemic region for avian malaria and identification of a parasite causing penguin mortality. *Journal of Eukaryotic Microbiology* **43**, 393–399.
- McDonald, S. P. (2012). Parasitology of the yellow-eyed penguin (Megadyptes antipodes). Master's degree dissertation (Science). University of Otago, New Zealand.
- McDowell, J. V., Tran, E., Hamilton, D., Wolfgang, J., Miller, K. and Marconi, R. T. (2003). Analysis of the ability of spirochete species associated with relapsing fever, avian borreliosis, and epizootic bovine abortion to bind factor H and cleave C3b. *Journal of Clinical Microbiology* **41**, 3905–3910.
- Medlock, J. M., Schaffner, F. and Fontenille, D. (2010). *Invasive Mosquitoes in the European Associate Continental and Overseas Territories*. European Centre for Disease Prevention and Control, Solna, Sweden. http://www.ecdc.europa.eu/en/activities/sciadvicelayouts/forms/review_dispform.aspx?ID=212&List=a3216f4c-f040-4f51-9f77-a96046dbfd72.
- Meile, R. J., Lacy, R. C., Vargas, F. H. and Parker, P. G. (2013). Modeling *Plasmodium* parasite arrival in the Galapagos Penguin (*Spheniscus mendiculus*). *Auk* **130**, 440–448.
- Merino, S., Barbosa, A., Moreno, J. and Potti, J. (1996). Absence of Haematzoa in a wild chinstrap penguin *Pygoscelis antarctica* population. *Polar Biology* **18**, 227–228.
- Merkel, J., Jones, H. I., Whiteman, N. K., Gottdenker, N., Vargas, H., Travis, E. K., Miller, R. E. and Parker, P. G. (2007). Microfilariae in Galapagos penguins (*Spheniscus mendiculus*) and flightless cormorants (*Phalacrocorax harrisi*). *Journal of Parasitology* **93**, 495–503.
- Miller, G. D., Hofkin, B. V., Snell, H., Hahn, A. and Miller, R. D. (2001). Avian malaria and Marek's disease: potential threats to Galapagos penguins *Spheniscus mendiculus*. *Marine Ornithology* **29**, 43–46.
- Molyneux, D. H. (1977). Vector relationships in the Trypanosomatidae. *Advances in Parasitology* **15**, 1–82.
- Molyneux, D. H., Cooper, J. E. and Smith, W. J. (1983). Studies on the pathology of an avian trypanosome (*T. bouffardi*) infection in experimentally infected canaries. *Parasitology* **87**, 49–54.
- Muñoz-Leal, S. and González-Acuña, D. (2015). The tick *Ixodes uriae* (Acari: Ixodidae): hosts, geographical distribution, and vector roles. *Ticks and Tick Borne Diseases* **6**, 843–868.
- Murray, M. D. (1975). Potential vectors of bluetongue in Australia. *Australian Veterinary Journal* **51**, 216–220.
- Naus, C. W. A., Jones, F. M., Satti, M. Z., Joseph, S., Riley, E. M., Kimani, G., Mwatha, J. K., Kariuki, C. H., Ouma, J. H., Kabatereine, N. B., Vennervald, B. J. and Dunne, D. W. (2003). Serological responses among individuals in areas where both schistosomiasis and malaria are endemic: cross-reactivity between *Schistosoma mansoni* and *Plasmodium falciparum*. *Journal of Infectious Diseases* **187**, 1272–1282.
- Oliver, W. R. B. (1953). The crested penguins of New Zealand. *Emu* **53**, 185–187.
- Olsén, B., Jaenson, T. G. T. and Bergström, S. (1995a). Prevalence of *Borrelia burgdorferi* sensu lato-infected ticks on migrating birds. *Applied Environmental Microbiology* **61**, 3082–3087.
- Olsén, B., Duffy, D. C., Jaenson, T. G. T., Gylfe, A., Bonnedahl, J. and Bergström, S. (1995b). Transhemispheric exchange of Lyme disease spirochetes by seabirds. *Journal of Clinical Microbiology* **33**, 3270–3274.
- Olsén, B. (2007). *Borrelia*. In *Infectious Diseases of Wild Birds* (ed. Thomas, N. J., Hunter, D. B. and Atkinson, C. T.), pp. 341–351. Blackwell, Ames, USA.
- Palmer, J. L., McCutchan, T. F., Vargas, F. H., Deem, S. L., Cruz, M., Hartman, D. A. and Parker, P. G. (2013). Seroprevalence of malarial antibodies in Galapagos penguins (*Spheniscus mendiculus*). *Journal of Parasitology* **99**, 770–776.
- Paperna, I. and Gill, H. (2003). Schizogonic stages of *Haemoproteus* from Wenyons Baghdad sparrows are also found in *Passer domesticus biblicus* in Israel. *Parasitology Research* **91**, 486–490.
- Parker, P. G., Whiteman, N. K. and Miller, R. E. (2006). Conservation medicine on the Galapagos Islands: partnerships among behavioral, population and veterinary scientists. *Auk* **123**, 625–638.
- Parsons, N. J. and Underhill, L. G. (2005). Oiled and injured African penguins *Spheniscus demersus* and other seabirds admitted for rehabilitation. *African Journal of Marine Science* **27**, 289–296.
- Peirce, M. A. (2000). A taxonomic review of avian piroplasmids of the genus *Babesia* Starcovici, 1893. *Journal of Natural History* **34**, 317–332.
- Peirce, M. A. (2005). A checklist of the valid avian species of *Babesia* (Apicomplexa: Piroplasmorida), *Haemoproteus*, *Leucocytozoon* (Apicomplexa: Haemosporida), and *Hepatozoon* (Apicomplexa: Haemogregarinidae). *Journal of Natural History* **39**, 3621–3632.
- Peirce, M. A., Greenwood, A. G. and Sidworthy, M. F. (2005). *Leucocytozoon* in captive penguins. *Veterinary Record* **157**, 819–820.
- Penrith, M.-L., Huchzermeyer, F. W., Wet, S. C. and Penrith, M. J. (1994). Concurrent infection with *Clostridium* and *Plasmodium* in a captive king penguin *Aptenodytes patagonicus*. *Avian Pathology* **23**, 373–380.
- Ploeg, M., Ultee, T. and Kik, M. (2011). Disseminated toxoplasmosis in black-footed penguins (*Spheniscus demersus*). *Avian Diseases* **55**, 701–703.
- Quillfeldt, P., Martínez, J., Hennicke, J., Ludynia, K., Gladbach, A., Masello, J. F., Riou, S. and Merino, S. (2010). Hemosporidian blood parasites in seabirds — a comparative genetic study of species from Antarctic to tropical habitats. *Naturwissenschaften* **97**, 809–817.
- Raethel, H. S. (1960). Plasmodieninfektionen bei Pinguinen des Berliner Zoologischen Gartens und ihre Bedeutung für die Pinguinhaltung (in German). *Kleintier-Praxis* **5**, 64–70.
- Ratcliffe, H. L. and Worth, C. B. (1951). Toxoplasmosis of captive wild birds and mammals. *American Journal of Pathology* **27**, 655–667.
- Redrobe, S. (2000). *Plasmodium* infection in a group of captive penguins including rockhopper penguins, king penguins, gentoo penguins, Macaroni penguin. In *Proceedings of the Scientific Meeting of the European Association of Zoo and Wildlife Veterinarians*, Paris, France.
- Reeves, W. K., Adler, P. H., Rätti, O., Malmqvist, B. and Strasevicius, D. (2007). Molecular detection of *Trypanosoma* (Kinetoplastida: Trypanosomatidae) in black flies (Diptera: Simuliidae). *Comparative Parasitology* **74**, 171–175.
- Rewell, R. E. (1948). Report of the pathologist for the year 1947. *Proceedings of the Zoological Society of London* **118**, 501–514.
- Rodhain, J. (1939). L'infection a *Plasmodium relictum* chez les pingouins (in French). *Annales de Parasitologie Humaine et Comparée* **17**, 139–157.
- Rodhain, J. and Andrianne, V.-F. (1952). Deux nouveaux cas d'infestation par *Plasmodium* chez des pingouins (in French). *Annales de Parasitologie Humaine et Comparée* **32**, 573–577.
- Rollinson, D. P., Reynolds, C. and Pajmans, D. M. (2013). Vagrant Northern rockhopper penguin at Soetwater beach, Western Cape. *Ornithological Observations* **4**, 36–38.
- Sallaberry-Pincheira, N., González-Acuña, D., Herrera-Tello, Y., Dantas, G. P. M., Luna-Jorquera, G., Frere, E., Valdés-Velasquez, A., Simeone, A. and Vianna, J. A. (2015). Molecular epidemiology of avian malaria in wild breeding colonies of Humboldt and Magellanic penguins in South America. *EcoHealth* **12**, 267–277.
- Sano, Y., Aoki, M., Takahashi, H., Miura, M., Komatsu, M., Abe, Y., Kakino, J. and Itagaki, T. (2005). The first record of *Dirofilaria immitis* infection in a Humboldt penguin, *Spheniscus humboldti*. *Journal of Parasitology* **81**, 1235–1237.
- Schnittger, L., Rodriguez, A. E., Florin-Christensen, M. and Morrison, D. A. (2012). *Babesia*: a world emerging. *Infection, Genetics and Evolution* **12**, 1788–1809.
- Schramm, F., Gauthier-Clerc, M., Fournier, J.-C., McCoy, K. D., Barthel, C., Postic, D., Handrich, Y., Le Maho, Y. and Jaulhac, B. (2014). First detection of *Borrelia burgdorferi* sensu lato DNA in king penguins (*Aptenodytes patagonicus halli*). *Ticks and Tick Borne Disease* **5**, 939–942.
- Scott, H. H. (1927). Report on the deaths occurring in the Society's Gardens during the year 1926. *Proceedings of the Zoological Society of London* **97**, 173–198.
- Sehgal, R. N. M., Jones, H. I. and Smith, T. B. (2001). Host specificity and incidence of *Trypanosoma* in some African rainforest birds: a molecular approach. *Molecular Ecology* **10**, 2319–2327.

- Sergent, N., Rogers, T. and Cunningham, M. (2004). Influence of biological and ecological factors on hematological values in wild Little Penguins, *Eudyptula minor*. *Comparative Biochemistry and Physiology* **138**, 333–339.
- Sherley, R. B., Waller, L. J., Strauss, V., Geldenhuys, D., Underhill, L. G. and Parsons, N. J. (2014). Hand-rearing, release and survival of African penguin chicks abandoned before independence by moulting parents. *Plos ONE* **9**, e110794.
- Siers, S., Merkel, J., Batailler, A., Vargas, F. H. and Parker, P. G. (2010). Ecological correlates of microfilariae prevalence in endangered Galápagos birds. *Journal of Parasitology* **96**, 259–272.
- Silveira, P., Damatta, R. A. and Dagosto, M. (2009). Hematological changes of chickens experimentally infected with *Plasmodium (Bennettinia) juxtamuclare*. *Veterinary Parasitology* **162**, 257–262.
- Silveira, P., Belo, N. O., Lacorte, G. A., Kolesnikovas, C. K. M., Vanstreels, R. E. T., Steindel, M., Catão-Dias, J. L., Valkiūnas, G. and Braga, É. M. (2013). Parasitological and new molecular-phylogenetic characterization of the malaria parasite *Plasmodium tejerai* in South American penguins. *Parasitology International* **62**, 165–171.
- Simón, F., López-Belmonte, J., Marcos-Atxutegi, C., Morchón, R. and Martín-Pachó, J. R. (2005). What is happening outside North America regarding human dirofilariasis. *Veterinary Parasitology* **133**, 181–189.
- Sinclair, B. J. (2014). CDF checklist of Galapagos flies. In *Charles Darwin Foundation Galapagos Species Checklist* (ed. Bungartz, F., Herrera, H., Jaramillo, P., Tirado, N., Jiménez-Uzcátegui, G., Ruiz, D., Guézou, A. and Ziemmeck, F.). Charles Darwin Foundation, Puerto Ayora, Ecuador. <http://www.darwinfoundation.org/datazone/checklists/>.
- Sladen, W. J. L., Gailey-Phipps, J. J. and Divers, B. J. (1979). Medical problems and treatment of penguins at the Baltimore Zoo. *International Zoo Yearbook* **19**, 202–209.
- Snell, A. E. (2005). The discovery of the exotic mosquito *Ochlerotatus australis* and the endemic *Opifex fuscus* (Diptera: Culicidae) on North East Island, Snares Islands. *Weta* **30**, 10–13.
- Spinelli, G. R. and Martinez, M. E. (1991). The genus *Culicoides* in Uruguay (Diptera: Ceratopogonidae). *Insecta Mundi* **5**, 175–179.
- Stevenson, C. and Woehler, E. J. (2007). Population decreases in little penguins *Eudyptula minor* in southeastern Tasmania, Australia, over the past 45 years. *Marine Ornithology* **35**, 71–76.
- Stoskopf, M. K. and Beier, J. (1979). Avian malaria in African black-footed penguins. *Journal of the American Veterinary Medical Association* **175**, 944–947.
- Sturrock, H. J. W. and Tompkins, D. M. (2007). Avian malaria (*Plasmodium* spp.) in yellow-eyed penguins: investigating the cause of high seroprevalence but low observed infection. *New Zealand Veterinary Journal* **55**, 158–160.
- Sturrock, H. J. W. and Tompkins, D. M. (2008). Avian malaria parasites (*Plasmodium* spp.) in Dunedin and on the Otago Peninsula, southern New Zealand. *New Zealand Veterinary Journal* **32**, 98–102.
- Szöllösi, E., Hellgren, O. and Hasselquist, D. (2008). A cautionary note on the use of nested PCR for parasite screening – an example from avian blood parasites. *Journal of Parasitology* **94**, 562–564.
- Tabachnick, W. J. (2004). *Culicoides* and the global epidemiology of blue-tongue virus infection. *Veterinaria Italiana* **40**, 144–150.
- Thiart, H. (2005). Immunological and epidemiological investigations into avian malaria in the African penguin during rehabilitation and in breeding colonies. Master's degree dissertation (Biochemistry). University of Stellenbosch, South Africa.
- Tollini, J., Brocksen, A. and Sureda, N. (2000). Prevention and treatment of avian malaria in a captive penguin colony. *Penguin Conservation* **13**, 28–31.
- Tompkins, D. M. and Gleeson, D. M. (2006). Relationship between avian malaria distribution and an exotic invasive mosquito in New Zealand. *Journal of the Royal Society of New Zealand* **36**, 51–62.
- Valkiūnas, G. (2005). *Avian Malaria Parasites and Other Haemosporidia*. CRC Press, Boca Raton, USA.
- Valkiūnas, G., Zehntindjev, P., Dimitrov, D., Križanauskienė, A., Iezhova, T. A. and Bensch, S. (2008). Polymerase chain reaction-based identification of *Plasmodium (Huffia) elongatum*, with remarks on species identity of haemosporidian lineages deposited in GenBank. *Parasitology Research* **102**, 1185–1193.
- Valkiūnas, G., Santiago-Alarcon, D., Levin, I. I., Iezhova, T. A. and Parker, P. G. (2010). A new *Haemoproteus* species (Haemosporida: Haemoproteidae) from the endemic Galapagos dove *Zenaidura macroura*, with remarks on the parasite distribution, vectors, and molecular diagnostics. *Journal of Parasitology* **96**, 783–792.
- Valkiūnas, G., Iezhova, T. A., Evans, E., Carlson, J. S., Martínez-Gómez, J. E. and Sehgal, R. N. M. (2013). Two new *Haemoproteus* species (Haemosporida: Haemoproteidae) from Columbiform birds. *Journal of Parasitology* **99**, 513–521.
- Valkiūnas, G., Palinauskas, V., Ilgūnas, M., Bukauskaitė, D., Dimitrov, D., Bernotienė, R., Zehntindjev, P., Ilieva, M. and Iezhova, T. A. (2014). Molecular characterization of five widespread avian haemosporidian parasites (Haemosporida), with perspectives on the PCR-based detection of haemosporidians in wildlife. *Parasitology Research* **113**, 2251–2263.
- van Rensburg, M. J. (2010). Parasitism, disease and breeding ecology of little blue penguins (*Eudyptula minor*) on Tiritiri Matangi Island, New Zealand. Master's degree dissertation (Conservation Biology). Massey University, New Zealand.
- Van Riper, C., III, Van Riper, S. G., Goff, M. L. and Laird, M. (1986). The epizootiology and ecological significance of malaria in Hawaiian land birds. *Ecology Monographs* **56**, 327–344.
- Vanstreels, R. E. T., Kolesnikovas, C. K. M., Sandri, S., Silveira, P., Belo, N. O., Ferreira-Junior, F. C., Epiphany, S., Steindel, M., Braga, É. M. and Catão-Dias, J. L. (2014a). Outbreak of avian malaria associated to multiple species of *Plasmodium* in Magellanic penguins undergoing rehabilitation in Southern Brazil. *PLoS ONE* **9**, e94994.
- Vanstreels, R. E. T., Miranda, F. R., Ruoppolo, V., Reis, A. O. A., Costa, E. S., Pessôa, A. R. L., Torres, J. P. M., Cunha, L. S. T., Piuco, R. C., Valiati, V. H., González-Acuña, D., Labruna, M. B., Petry, M. V., Epiphany, S. and Catão-Dias, J. L. (2014b). Investigation of blood parasites of pygoscelid penguins at the King George and Elephant Islands, South Shetlands Archipelago, Antarctica. *Polar Biology* **37**, 135–139.
- Vanstreels, R. E. T., Silva-Filho, R. P., Kolesnikovas, C. K. M., Bhering, R. C. C., Ruoppolo, V., Epiphany, S., Amaku, M., Ferreira-Junior, F. C., Braga, É. M. and Catão-Dias, J. L. (2015a). Epidemiology and pathology of avian malaria in penguins undergoing rehabilitation in Brazil. *Veterinary Research* **46**, 30.
- Vanstreels, R. E. T., Woehler, E. J., Ruoppolo, V., Vertigan, P., Carlile, N., Priddel, D., Finger, A., Dann, P., Vinette-Herrin, K., Thompson, P., Ferreira-Junior, F. C., Braga, É. M., Hurtado, R., Epiphany, S. and Catão-Dias, J. L. (2015b). Epidemiology and molecular phylogeny of *Babesia* sp. in little penguins *Eudyptula minor* in Australia. *International Journal of Parasitology: Parasites and Wildlife* **4**, 198–205.
- Vanstreels, R. E. T., Capellino, F., Silveira, P., Braga, É. M., Rodríguez-Heredia, S. A., Loureiro, J. and Catão-Dias, J. L. (in press). Avian malaria (*Plasmodium* spp.) in Magellanic penguins (*Spheniscus magellanicus*) captive in northern Argentina. *Journal of Wildlife Diseases*.
- Varney, K. (2006). Quarterly review of diagnostic cases – October to December 2005: Gribbles Veterinary Pathology. *Surveillance* **33**, 11–14.
- Votypka, J., Oborník, M., Volf, P., Svobodová, M. and Lukes, J. (2002). *Trypanosoma avium* of raptors (Falconiformes): phylogeny and identification of vectors. *Parasitology* **125**, 253–263.
- Walter Reed Biosystematics Unit (WRBU) (2014). *VectorMap: know the vector, know the threat*. <http://www.vectormap.org/>.
- White, G. B. (1989). Malaria. In *Geographical Distribution of Arthropod-borne Diseases and their Principal Vectors*, pp. 7–22. World Health Organization Vector Biology and Control Division, Geneva, Switzerland. <http://apps.who.int/iris/handle/10665/60575>.
- Wirth, W. W. and Felipe-Bauer, M. L. (1989). The Neotropical biting midges related to *Culicoides paraensis* (Diptera: Ceratopogonidae). *Memórias Instituto Oswaldo Cruz* **84**, 551–565.
- Woods, R., Jones, H. I., Watts, J., Miller, G. D. and Shellam, G. R. (2009). Diseases of Antarctic seabirds. In *Health of Antarctic Wildlife: a Challenge for Science and Policy* (ed. Kerry, K. R. and Riddle, M. J.), pp. 35–56. Springer, London, UK.
- Yabsley, M. J., Parsons, N. J., Horne, E. C., Shock, B. C. and Purdee, M. (2012). Novel relapsing fever *Borrelia* detected in African penguins (*Spheniscus demersus*) admitted to two rehabilitation centers in South Africa. *Parasitology Research* **110**, 1125–1130.
- Yoshio, T., Yukiko, H., Kyoko, S., Koichi, M., Yukita, S., Rei, M., Miya, U. and Nobuyuki, N. (2006). Research on infection vector and its control: survey on infectious mosquitoes for penguin malaria in zoos and aquariums. *Kansensho Baikai Bekuta no Jittai, Seisoku Boshi Taisaku ni kansuru Kenkyu Heisei 17 Nendo Sokatsu, Buntan Kenkyu Hokokusho* **2006**, 41–49.
- Zidková, L., Cepicka, I., Szabová, J. and Svobodová, M. (2012). Biodiversity of avian trypanosomes. *Infection, Genetics and Evolution* **12**, 102–112.

APPENDIX 1

Table A1. Published records of blood parasites in penguins

Host, context, location and period of sample collection	Parasite	References
King penguin (<i>Aptenodytes patagonicus</i>)		
C – London, England (1926)	<i>P. relictum</i>	Scott (1927), Fantham and Porter (1944)
C – London, England (1947)	<i>P. relictum</i>	Rewell (1948)
C – San Diego, California, USA (1965)	<i>P. relictum</i>	Griner and Sheridan (1967)
C – Praetoria, South Africa (1992)	<i>P. relictum</i>	Penrith <i>et al.</i> (1994)
C – Bristol, England (year unknown)	<i>Plasmodium</i> sp.	Redrobe (2000)
W – Possession Is., Crozet (year unknown)	<i>Borrelia</i> sp. (LDB)	Schramm <i>et al.</i> (2014)
Southern rockhopper penguin (<i>Eudyptes chrysocome</i>)		
C – Baltimore, Maryland, USA (1972–1976)	<i>Plasmodium</i> sp.	Sladen <i>et al.</i> (1979)
C – Vienna, Austria (2000–2008)	<i>Plasmodium</i> sp.	Dinhopl <i>et al.</i> (2011)
Northern rockhopper penguin (<i>Eudyptes moseleyi</i>)		
W – Gough Island, South Atlantic (year unknown)	<i>P. relictum</i>	Fantham and Porter (1944)
Rockhopper penguin (<i>E. chrysocome</i> or <i>E. moseleyi</i>)		
C – Berlin, Germany (1957–1958)	<i>Plasmodium</i> sp.	Raethel (1960)
C – Honolulu, Hawaii (year unknown)	<i>P. relictum</i>	Laird and Van Riper (1981)
Macaroni penguin (<i>Eudyptes chrysolophus</i>)		
C – Washington, DC, USA (1969)	<i>P. elongatum</i>	Herman <i>et al.</i> (1974)
C – Bristol, England (year unknown)	<i>Plasmodium</i> sp.	Redrobe (2000)
C – Unknown location, England (1999)	<i>Plasmodium</i> sp.	Gough <i>et al.</i> (2002)
C – Unknown location, England (2005)	<i>Plasmodium</i> sp.	Peirce <i>et al.</i> (2005)
C – Unknown location, England (2005)	<i>L. tawaki</i>	Peirce <i>et al.</i> (2005)
Fiordland penguin (<i>Eudyptes pachyrhynchus</i>)		
W – Kaikoura, South Is., New Zealand (1975)	<i>L. tawaki</i>	Fallis <i>et al.</i> (1976)
W – Jackson Head, South Is., New Zealand (1975–1977)	<i>L. tawaki</i>	Fallis <i>et al.</i> (1976)
W – Jackson Head, South Is., New Zealand (1976–1977)	<i>L. tawaki</i>	Allison <i>et al.</i> (1978)
R – Auckland, North Is., New Zealand (2007)	<i>Leucocytozoon</i> sp., Undetermined ^d	Harvey and Alley (2008), Hill (2008)
Snares penguin (<i>Eudyptes robustus</i>)		
W – Snares Is., New Zealand (1947)	<i>P. relictum</i>	Laird (1950)
Little penguin (<i>Eudyptula minor</i>)		
C – San Diego, California, USA (1965)	<i>P. relictum</i>	Griner and Sheridan (1967)
E – Jackson Head, South Is., New Zealand (1977)	<i>L. tawaki</i>	Allison <i>et al.</i> (1978)
W – Marion Bay and Little Spectacle Is., Australia (1986)	<i>T. eudyptulae</i>	Jones and Woehler (1989)
W – Unknown location, New South Wales, Australia (1990)	<i>Babesia</i> sp.	Cunningham <i>et al.</i> (1993)
W – Lion and Bowen Is., Australia (1991–1992)	<i>Babesia</i> sp.	Cunningham <i>et al.</i> (1993), Sergeant <i>et al.</i> (2004)
C – Auckland, North Is., New Zealand (2005)	<i>Leucocytozoon</i> sp. ^b	Varney (2006), Harvey and Alley (2008)
W – Tiritiri Matangi Is., New Zealand (2006–2007)	<i>P. relictum</i>	van Rensburg (2010)
W – Tiritiri Matangi Is., New Zealand (2006–2007)	Undetermined ^a	van Rensburg (2010)
W – Multiple locations, Western Australia, Australia (2006–2012)	Undetermined ^c	Cannell <i>et al.</i> (2013, 2014)
W – Althorpe, Granite, Kangaroo and Troubridge, Australia (2013)	Undetermined ^d	Colombelli-Negrél and Kleindorfer (2014)
W – Cabbage Tree Is., Australia (2012–2013)	<i>Babesia</i> sp.	Vanstreels <i>et al.</i> (2015b)
W – Phillip Is., Australia (2012–2013)	<i>Babesia</i> sp.	Vanstreels <i>et al.</i> (2015b)
W – Maria and Bruny Is., Australia (2012–2013)	<i>Babesia</i> sp.	Vanstreels <i>et al.</i> (2015b)
Yellow-eyed penguin (<i>Megadyptes antipodes</i>)		
W – Fouveaux Strait, New Zealand (1929)	<i>P. relictum</i>	Fantham and Porter (1944)
W – Campbell Is., New Zealand (1948)	<i>P. relictum</i>	Laird (1950)
W – Otago Peninsula, South Is., New Zealand (1997–1999)	Undetermined ^e	McDonald (2012)
W – Codfish and Stewart Is., New Zealand (2005–2008)	<i>L. (Leucocytozoon)</i> sp.	Alley <i>et al.</i> (2004), Harvey and Alley (2008), Hill (2008), King <i>et al.</i> (2012)
W – Stewart Is., New Zealand (2006–2007)	<i>L. (Leucocytozoon)</i> sp.	Hill <i>et al.</i> (2010)
W – Multiple locations, South Is., New Zealand (2008)	<i>L. (Leucocytozoon)</i> sp.	Argilla <i>et al.</i> (2013)
W – Campbell Is., New Zealand (2006–2009)	<i>L. (Leucocytozoon)</i> sp.	Argilla <i>et al.</i> (2013)
W – Enderby Is., New Zealand (2006–2009)	<i>L. (Leucocytozoon)</i> sp.	Argilla <i>et al.</i> (2013)
Chinstrap penguin (<i>Pygoscelis antarcticus</i>)		
C – Antwerp, Belgium (1952)	<i>P. relictum</i>	Rodhain and Andrianne (1952)

Table A1. (Cont.)

Host, context, location and period of sample collection	Parasite	References
Gentoo penguin (<i>Pygoscelis papua</i>)		
C – San Diego, California, USA (1965)	<i>P. relictum</i>	Griner and Sheridan (1967)
C – Bristol, England (year unknown)	<i>Plasmodium</i> sp.	Redrobe (2000)
African penguin (<i>Spheniscus demersus</i>)		
C – Antwerp, Belgium (1936)	<i>P. relictum</i>	Rodhain (1939), Rodhain and Andrianne (1952)
W – Saldanha Bay, South Africa (1927–1929)	<i>P. relictum</i>	Fantham and Porter (1944)
W – Dassen Is., South Africa (1938)	<i>Babesia</i> sp., <i>Borrelia</i> sp. ^b	Coles (1941), Bennett <i>et al.</i> (1992)
C – Vienna, Austria (1958–1962)	<i>P. relictum</i>	Grünberg and Kutzer (1963)
C – San Diego, California, USA (1965)	<i>P. relictum</i>	Griner and Sheridan (1967)
C – Baltimore, Maryland, USA (1967–1996)	<i>P. relictum</i> , <i>P. elongatum</i>	Fleischman <i>et al.</i> (1968a, b), Herman <i>et al.</i> (1968), Sladen <i>et al.</i> (1979), Stoskopf and Beier (1979), Beier and Stoskopf (1980), Beier and Trpis (1981), Cranfield <i>et al.</i> (1994), Graczyk <i>et al.</i> (1994a, b, 1995a), McConkey <i>et al.</i> (1996), Grim <i>et al.</i> (2004)
C – Yongin, South Korea (1983)	<i>P. relictum</i>	Bak <i>et al.</i> (1984)
R – Cape Town, South Africa (1990)	<i>B. peircei</i>	Brossy (1992), Earlé <i>et al.</i> (1993)
R – Cape Town, South Africa (1991)	<i>L. tawaki</i>	Earlé <i>et al.</i> (1992)
W – Multiple locations, South Africa (1992–1999)	<i>Babesia</i> sp.	Brossy (1993), Brossy <i>et al.</i> (1999)
R – Cape Town, South Africa (1992–1999)	<i>P. relictum</i>	Brossy <i>et al.</i> (1999)
R – Cape Town, South Africa (unknown year)	<i>Plasmodium</i> sp.	Grim <i>et al.</i> (2003)
C – Unknown location, England (1999)	<i>Plasmodium</i> sp.	Gough <i>et al.</i> (2002)
R – Dassen and Robben Is., South Africa (2004)	<i>Plasmodium</i> sp.	Thiart (2005)
R – Stony Point, South Africa (2004)	<i>Plasmodium</i> sp.	Thiart (2005)
R – Cape Town, South Africa (2001–2003)	<i>Plasmodium</i> sp.	Botes (2004), Thiart (2005), Parsons and Underhill (2005)
R – Cape Town, South Africa (2006–2007)	<i>Plasmodium</i> sp.	Sherley <i>et al.</i> (2014)
C – Baltimore, Maryland, USA (unknown year)	<i>P. elongatum</i> ^b	Beadell and Fleischer (2005)
U – Unknown location, South Africa (unknown year)	<i>Plasmodium</i> sp. ^b	Beadell <i>et al.</i> (2006)
R – Cape Town, South Africa (2002–2013)	<i>Babesia</i> sp., <i>Borrelia</i> sp. (RFB)	Yabsley <i>et al.</i> (2012), Parsons <i>et al.</i> (in preparation)
W – Ichaboe Is., Namibia (2009)	<i>Babesia</i> sp.	Parsons <i>et al.</i> (in preparation)
W – Dassen, Robben and Dyer Is., South Africa (2010–2012)	<i>Babesia</i> sp.	Parsons <i>et al.</i> (in preparation)
W – Bird Is., South Africa (2012)	<i>Babesia</i> sp.	Parsons <i>et al.</i> (in preparation)
C – La Palmyre, France (2013–2014)	<i>Plasmodium</i> sp.	LeClerc <i>et al.</i> (2014), Grilo (2014)
C – Hilvarenbeek, Netherlands (2013–2014)	<i>Plasmodium</i> sp.	Grilo (2014)
C – Basel, Switzerland (2013–2014)	<i>P. relictum</i>	Cereghetti <i>et al.</i> (2012), Grilo (2014)
C – West Jerusalem (2013–2014)	<i>Plasmodium</i> sp.	Grilo (2014)
Humboldt penguin (<i>Spheniscus humboldti</i>)		
C – Antwerp, Belgium (1938)	<i>P. relictum</i>	Rodhain (1939), Rodhain and Andrianne (1952)
C – Washington, DC, USA (1956)	<i>P. elongatum</i> , <i>P. (Haemamoeba)</i> sp.	Huff and Shiroishi (1962)
C – Vienna, Austria (1958–1962)	<i>Plasmodium</i> sp.	Grünberg and Kutzer (1963)
C – San Diego, California, USA (1965)	<i>P. relictum</i>	Griner and Sheridan (1967)
C – Kanagawa, Japan (year unknown)	<i>Plasmodium</i> sp.	Yoshio <i>et al.</i> (2006), Ejiri <i>et al.</i> (2009)
C – Vienna, Austria (2000–2008)	<i>Plasmodium</i> sp.	Dinhopl <i>et al.</i> (2011)
W – Punta San Juan, Chile (2010–2013)	<i>Haemoproreus (Parahaemoproreus)</i> sp. ^b	Sallaberry-Pincheira <i>et al.</i> (2015)
C – Valencia, Spain (2013–2014)	<i>Plasmodium</i> sp.	Grilo (2014)
Magellanic penguin (<i>Spheniscus magellanicus</i>)		
C – Des Moines, Iowa, USA (1986)	<i>P. relictum</i>	Fix <i>et al.</i> (1988)
C – San Francisco, California, USA (1997–2000)	<i>Plasmodium</i> sp.	Tollini <i>et al.</i> (2000)
R – Salvador, Brazil (1999–2012)	<i>P. cathemerium</i> , <i>P. nucleophilum</i> , <i>Plasmodium</i> sp.	Vanstreels <i>et al.</i> (2015a)
R – Rio de Janeiro, Brazil (1999–2012)	<i>Plasmodium</i> sp.	Vanstreels <i>et al.</i> (2015a)
R – Rio Grande, Brazil (1999–2012)	<i>P. nucleophilum</i> , <i>P. unalis</i> , <i>Plasmodium</i> sp.	Cabana <i>et al.</i> (2014), Vanstreels <i>et al.</i> (2015a)
R – Cariacica, Brazil (1999–2013)	<i>P. cathemerium</i> , <i>P. elongatum</i>	Vanstreels <i>et al.</i> (2015a)
C – Jeju Is., South Korea (2005)	<i>Plasmodium</i> sp.	Ko <i>et al.</i> (2008)
C – São Paulo, Brazil (2007)	<i>P. elongatum</i> , <i>Plasmodium</i> sp. ^b	Bueno <i>et al.</i> (2010)
R – Valdivia, Chile (2009)	<i>P. relictum</i>	Carvajal and Alvarado (2009)
R – Florianópolis, Brazil (2009–2013)	<i>P. cathemerium</i> , <i>P. elongatum</i> , <i>Plasmodium tejeraei</i> , <i>Plasmodium</i> sp.	Silveira <i>et al.</i> (2013), Vanstreels <i>et al.</i> (2014a, 2015a)
R – Niterói, Brazil (2010)	<i>Plasmodium</i> sp.	Campos <i>et al.</i> (2014)
R – Rio de Janeiro, Brazil (2010)	<i>Plasmodium</i> sp.	Campos <i>et al.</i> (2014)
C – San Clemente del Tuyú, Argentina (2010)	<i>P. tejeraei</i> , <i>P. (Novyella)</i> sp., <i>P. (Huffia)</i> sp.	Vanstreels <i>et al.</i> (in press)

Table A1. (Cont.)

Host, context, location and period of sample collection	Parasite	References
Galapagos penguin (<i>Spheniscus mendiculus</i>)		
W – Unknown location, Galapagos (unknown year)	Microfilariae	Harmon <i>et al.</i> (1985)
W – Fernandina and Isabela Is., Galapagos (2003–2005)	Microfilariae	Parker <i>et al.</i> (2006), Merkel <i>et al.</i> (2007), Siers <i>et al.</i> (2010)
W – Isabela Is., Galapagos (2003–2005)	<i>H. (Parahaemoproteus)</i> sp.	Parker <i>et al.</i> (2006), Levin <i>et al.</i> (2009)
W – Isabela, Fernandina, Las Marielas and Bartolomé Is., Galapagos (2003–2009)	<i>Plasmodium</i> sp.	Parker <i>et al.</i> (2006), Levin <i>et al.</i> (2009, 2013)

Records were classified according to the context in which the diagnosis was established: W, penguins sampled in the wild; R, penguins undergoing rehabilitation; C, penguins captive in zoos; E, penguins infected under experimental conditions; U, samples obtained from penguins in unknown context.

Notes (see Appendix 2): ^a Small round intraerythrocytic inclusions were observed, which could be compatible with early life stages of *Babesia* sp., *Haemoproteus* sp., *Leucocytozoon* sp. or *Plasmodium* sp.

^b Revised records, which had originally attributed to a different parasite species.

^c Molecular and morphological evidence produced conflicting results.

^d Morphological evidence inconclusive, not clear if structures observed were parasites or artefacts.

^e Molecular testing for *Haemoproteus/Plasmodium* produced conflicting and inconclusive results.

APPENDIX 2

Remarks On Revised, Inconclusive Or Questionable Records Of Blood Parasites In Penguins

Plasmodium

Laird (1950) reported to have examined ‘*E. pachyrhynchus* (drooping-crested penguin) collected at the Snares Islands’; however this taxon was later revised and specimens breeding in the Snares Archipelago are currently considered a separate species, *Eudyptes robustus* (Oliver, 1953). Additionally, some records refer to rockhopper penguins as *Eudyptes crestatus* (Raethel, 1960; Sladen *et al.* 1979; Laird and Van Riper III, 1981), but because this taxon was later split into two species, *Eudyptes chrysocome* and *Eudyptes moseleyi* (Jouventin *et al.* 2006), it is not always possible to determine to which species these records correspond. In the case of the Baltimore Zoo (Sladen *et al.* 1979), records indicate the penguins had been captured at the Falkland Islands (E. Brown, personal communication) and therefore were *E. chrysocome*. It should be noted that although Grilo (2014) did not list which penguin species had been positive at each zoo, this information was obtained through personal communication.

Early reports refer to *P. praecox* or *P. praecox relictum* (Rodhain, 1939; Rodhain and Andrianne, 1952; Grünberg and Kutzer, 1963), which were later revised as synonyms of *P. relictum* (Valkiūnas, 2005). It is worth considering that in some reports the identification of *P. relictum* was based solely on the presence of large round gametocytes and absence of rod-shaped pigment granules and/or no photomicrographs or detailed morphological descriptions were provided (e.g. Rodhain, 1939; Raethel, 1960; Stoskopf and Beier, 1979; Fix *et al.* 1988). Because *P. relictum* is remarkably pleomorphic

and many other species of the subgenus *Haemamoeba* share these general morphological characteristics (Laird and Van Riper, 1981; Valkiūnas, 2005), such records should be considered with caution. Records of *P. elongatum* are probably more reliable as this species has a number of unique morphological characteristics (see Valkiūnas, 2005).

Grim *et al.* (2003) reported *P. (Bennettinia) juxtannucleare* while examining African penguins undergoing rehabilitation at Cape Town, South Africa. However, the photomicrographs and morphological description of the parasites are not consistent, since the fully grown gametocytes of *P. juxtannucleare* should not exceed the size of the nuclei of infected erythrocytes (Valkiūnas, 2005). Genetically, the parasite was identified as *P. juxtannucleare* solely on the basis of highest sequence identity in BLAST search, a method that can be inadequate to identify avian haemosporidians (Valkiūnas *et al.* 2008; Vanstreels *et al.* 2014a). Because the gene sequences were not deposited in public databases, it is impossible to conduct further phylogenetic analyses that might contribute in establishing the identity of the parasite. It is therefore more judicious to attribute this record to *Plasmodium* sp. until further information is obtained.

The identity of some *Plasmodium* sp. lineages for which mitochondrial *cytochrome b* gene sequences are publicly available were later revised and found to correspond to different species. The lineage obtained by Beadell and Fleischer (2005) was revised as *P. elongatum* (Valkiūnas *et al.* 2008). The lineage obtained by Beadell *et al.* (2006) was revised as *Plasmodium* sp. (Vanstreels *et al.* 2015a). The lineages obtained by Bueno *et al.* (2010) were revised as *P. elongatum* and a lineage of *Plasmodium* sp. closely related to *P. lutzi* (Vanstreels *et al.* 2014a).

It is well established that *Leucocytozoon* spp. invade hepatocytes to form tissue meronts, whereas

Plasmodium spp. does not (Atkinson and Van Riper III, 1991; Valkiūnas, 2005). The preliminary records provided by Alley *et al.* (2004) and Varney (2006) regarding wild yellow-eyed penguins at Otago Peninsula (South Island, New Zealand) and captive little penguins at Auckland Zoo (North Island, New Zealand) are therefore more consistent with *Leucocytozoon* sp. than with *Plasmodium* sp. as originally attributed. There are unconfirmed reports of wild little penguin chicks suspected to have died from avian malaria at Tiritiri Matangi Island (van Rensburg, 2010).

Thiart (2005) found an unusually high PCR prevalence to *Plasmodium* sp. (88–94%) in wild African penguins that was not consistent with blood smear and serological results and with previous studies in the region (see Fantham and Porter, 1944; Brossy *et al.* 1999; Parsons and Underhill, 2005). Because the electrophoresis of amplification products showed multiple bands with inconsistent patterns that often did not match that of the positive control, non-specific annealing of PCR primers is likely to have occurred.

Leucocytozoon

As previously discussed (see ‘*Plasmodium*’), the preliminary records provided by Alley *et al.* (2004) and Varney (2006) are more consistent with *Leucocytozoon* sp. than with *Plasmodium* sp. as originally attributed. Similarly, the wild little penguins studied by Cannell *et al.* (2013, 2014) at Western Australia may have been infected by *Leucocytozoon* sp. (see ‘*Haemoproteus*’).

Haemoproteus

Vanstreels *et al.* (2014a) reported *Haemoproteus* sp. infection in a Magellanic penguin, however later found this to have been a false-positive result due to a laboratory contamination (Vanstreels *et al.* 2014b). Sallaberry-Pincheira *et al.* (2015) found two different *Haemoproteus* sp. lineages in Humboldt penguins and considered that one belonged to the subgenus *Haemoproteus* and the other to the subgenus *Parahaemoproteus*. Closer inspection of the phylogenetic tree therein presented, however, reveals that both lineages cluster consistently with lineages of the subgenus *Parahaemoproteus*.

Cannell *et al.* (2013, 2014) reported *Haemoproteus* sp. as the cause of death of ten little penguins found dead on Penguin Island, Western Australia. However, they report that the parasites were present intracellularly in hepatocytes, which does not occur in *Haemoproteus* spp. infections (Valkiūnas, 2005); their histopathological findings are therefore most compatible with *Leucocytozoon* sp. The intraerythrocytic inclusion photographed in that study is compatible with either *Babesia* sp., *Haemoproteus* sp., *Leucocytozoon* sp. or *Plasmodium*

sp., and therefore does not allow for conclusive morphological identification. Although the authors were able to obtain DNA sequences from *Haemoproteus* sp., several aspects of the molecular analyses of that study are concerning: (a) the nested PCR test had a high false negative rate (60%) and poor repeatability; (b) 35 thermal cycles were employed in the HaemNFI/HaemNR3 reaction instead of the 20 recommended in the original protocol (Hellgren *et al.* 2004), which could result in co-amplification of other parasites (see Cosgrove *et al.* 2006; Szöllősi *et al.* 2008); (c) no information was provided on the identity/sequence of the positive control, hence the possibility laboratory contamination, which is not uncommon (see van Rensburg, 2010; Vanstreels *et al.* 2014b), cannot be dismissed. As a result, the results reported by Cannell *et al.* (2013) should be interpreted judiciously, requiring further investigation to verify the identity of the parasite and the possibility of infection by *Leucocytozoon* sp.

Babesia

The intracellular parasites observed by Coles (1941) were revised by Bennett *et al.* (1992) as corresponding to *Babesia* sp.

Nematode microfilariae

The record of an unidentified filarioid worm in the heart of a little penguin at Kangaroo Island, Australia (Mawson *et al.* 1986), was later revised as belonging to the superfamily Ascaridoidea (Merkel *et al.* 2007), and therefore would not have produced circulating microfilariae.

Aegyptianella

Coles (1941) observed intraerythrocytic inclusions in the blood smear of a wild African penguin and speculated it to be *Aegyptianella* sp.; however, this record was later revised as *Babesia* sp. (Bennett *et al.* 1992). Gough *et al.* (2002) briefly mention *Aegyptianella* sp. infection in a captive penguin in England. However, the fact that avian malaria was confirmed through histopathology in the same bird suggests that the intraerythrocytic inclusions most likely corresponded to early life stages of *Plasmodium* sp., especially when it is considered that chloroquine treatment can lead *Plasmodium* sp. to develop abnormal shapes that may resemble *Aegyptianella* sp. (see Vanstreels *et al.* 2014a). We therefore consider there is not sufficient evidence to demonstrate that *Aegyptianella* sp. infects penguins.

Undetermined or inconclusive records

It is possible that the cases of toxoplasmosis reported by Ratcliffe and Worth (1951) in captive Humboldt

penguins actually corresponded to avian malaria, considering the unusual epidemiological and pathological characteristics of those cases and the morphological similarity between *Toxoplasma gondii* tachyzoites and *Plasmodium* spp. tissue meronts (see Fleischman *et al.* 1968b; Ploeg *et al.* 2011).

Round intraerythrocytic inclusions were reported in the blood smears of wild little penguins at Tiritiri Matangi Island (Cook Strait, New Zealand) (van Rensburg, 2010) and of a Fiordland penguin rescued at Muriwai beach and treated in Auckland (North Island, New Zealand) (Hill, 2008), and could be compatible with early life stages of *Babesia* sp., *Haemoproteus* sp., *Leucocytozoon* sp. or *Plasmodium* sp.

McDonald (2012) did not observe parasites in blood smears of yellow-eyed penguins in South Island (New Zealand) however obtained conflicting results when employing different PCR and serological tests targeting *Plasmodium* sp., and it was ultimately not possible to determine whether these or other parasites were present or not. Colombelli-Negrél and Kleindorfer (2014) examined the blood smears of little penguins in South Australia and found structures they considered could correspond to *Plasmodium*, *Shellakia*, *Trypanosoma*, *Hepatozoon* or *Leucocytozoon*; upon closer inspection, however, the photomicrographs provided in that report are most compatible with staining artefacts (pseudoparasites).