

Adenoidectomy: does it work?

P J ROBB

Abstract

Adenoidectomy is a common, routine paediatric operation for which the evidence base for effectiveness is lacking. While there is a broad evidence base of variable quality for other common children's ENT operations, most published data including adenoidectomy is combined with the effect of combined tonsillectomy or grommet surgery. For the common indications for adenoidectomy, does it work?

Key words: Adenoidectomy; Otorhinolaryngologic Surgical Procedures; Outcome Assessment

Introduction

In contrast to the tonsils, which have enjoyed popular and professional attention for thousands of years, the adenoid has rather been neglected and is, perhaps, the *Cinderella* of Waldeyer's ring.

Santorini described the nasopharyngeal lymphoid aggregate (Lushka's tonsil) in 1724. Wilhelm Meyer coined the term 'adenoid' to describe what he described as 'nasopharyngeal vegetations' in 1870. He subsequently reported a series of 48 'adenoidotomies' performed by the pernasal route, leading to a wide popularization of the operation. This led Waterhouse in the 1911 textbook, *Diseases of the Ear, Nose and Throat* to enthuse 'it is beyond question that 99 of every 100 children from whom adenoid vegetations have been removed improve markedly in every way within a few weeks of the operation'. A more cynical view was taken by Wright in 1914 writing in the *History of Laryngology and Rhinology*, concluding that Meyer had 'furnished a generation of rhinologists with their most lucrative source of income'. In contemporary practice, income from adenoidectomy varies widely (see Figure 1). Despite enthusiastic claims for the efficacy of adenoidectomy, the evidence base is poor. A typical on-line literature search will yield less than 1000 references, many of which are level three or less, and typically include tonsillectomy and/or grommet surgery as part of the study. In searching the topic, many references to adenoid cystic carcinoma appear.

Notwithstanding the lack of high-level evidence, the empirical indications for adenoidectomy include obstructive sleep apnoea, rhinosinusitis and otitis media with effusion. Sense of smell and taste may

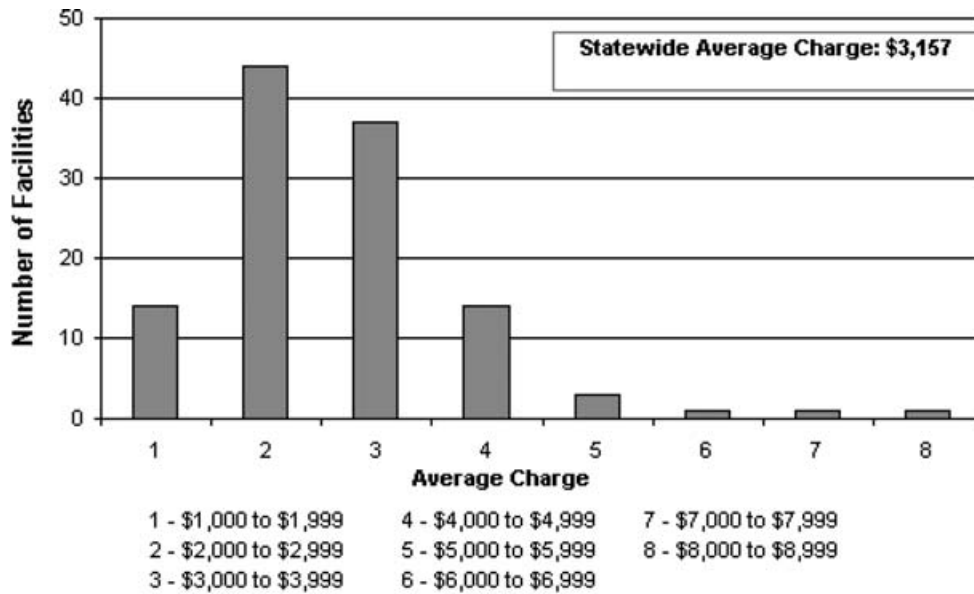
also improve following adenoidectomy and there are emerging considerations regarding the immune function of the adenoid. Removing the adenoid in very young children may have a detrimental effect on early development of immunity. Conversely, the adenoid, when diseased, may act as a source of infection, supporting bacteria in a biofilm with resultant inflammatory changes in the mucosa of the nose, nasopharynx, paranasal sinuses and middle ear.

Expert advice as to the indications for adenoidectomy has been published by the American Association of Otolaryngology – Head and Neck Surgery (AAO-HNS). These include obstructive sleep apnoea and upper airway obstruction to improve the airway by physically removing the obstruction. Surgery is recommended for infective causes including adenoiditis, where two courses of antibiotics have failed, and for recurrent purulent rhinorrhoea on four occasions in the preceding 12 months. Adenoiditis is a term that is less well recognized in the UK, and the distinction between adenoiditis as an entity and purulent rhinorrhoea as a symptom of this is not clear. The advice from the AAO-HNS for the management of otitis media with effusion is different from the UK. In the US, irrespective of age, adenoidectomy in conjunction with insertion of ventilation tubes is recommended only when tubes are inserted on the second occasion. In the UK, adenoidectomy is indicated in children over the age of three years, whether or not it is the first or subsequent insertion of tubes. Poor orthodontic development is also an indication in the American guidance. In the UK, the rate of adenoidectomy is falling (see Figure 2).

From the ENT Department, Epsom and St Helier University Hospitals NHS Trust, Epsom, Surrey, UK.

An abridged version of this paper was presented to the Section of Laryngology and Rhinology, Paediatric Rhinology session at the Royal Society of Medicine, 2 December 2005.

Accepted for publication: 20 February 2006.



Source: Ambulatory Surgery Data, Bureau of Health Information, Division of Health Care Financing, Department of Health and Family Services.

Note: Eight facilities that reported fewer than 5 of these procedures in 2002 were excluded from average charge calculations.

FIG. 1
Average charge for Tonsillectomy/Adenoidectomy, Wisconsin, 2002.

Sleep apnoea

A Cochrane review of 2001, updated in 2005, found no randomized controlled trials, which met inclusion criteria for tonsillectomy and adenoidectomy in the management of obstructive sleep apnoea in childhood. Although some data indicated benefit, there was lack of strong evidence to support surgical treatment. The review did not examine the independent benefits of adenoidectomy and tonsillectomy separately.¹

The American Academy of Pediatrics Subcommittee on Obstructive Sleep Apnea Syndrome (OSAS), reviewed 2115 articles related to OSAS in childhood, including 113 which provided original data for analysis.² The Committee concluded that adenotonsillectomy was curative in 75–100 per cent of children with

OSAS. The role of adenoidectomy alone was unclear. The report also noted that disordered breathing at night with snoring, but not OSAS, could not be considered benign and that there was evidence of neurobehavioural sequelae. While polysomnography (PSG) was recognized as the diagnostic test of choice for OSAS, this was performed in less than 6 per cent of children with suspected OSAS. This is the only reliable diagnostic test to differentiate OSAS from primary habitual snoring.³

Further evidence supports the benefit of adenoidectomy with tonsillectomy rather than tonsillectomy alone in a study of 400 children with sleep disordered breathing (SDB) short of OSAS, assessed pre- and post-operatively by PSG. Sixty-eight per cent underwent surgical treatment, in which SDB was abolished in 85 per cent of these. Adenotonsillectomy was more effective than either procedure alone. A limitation of the study was that the surgical interventions were undertaken by a total of seventeen different surgeons.⁴

A regression analysis of 2462 children aged between the ages of five months and 18 years undergoing adenoidectomy, examined the relative risk of subsequent tonsillectomy. Within five years of adenoidectomy, 108 of the children required subsequent tonsillectomy. The relative risk decreased by 0.83 per year for each increasing year at the age of adenoidectomy. For those children undergoing adenoidectomy for OSAS, the relative risk of subsequent tonsillectomy was doubled.⁵ OSAS in infancy is uncommon, but a study of 29 infants aged 18 months or less diagnosed OSAS in these children with full PSG. Pre-operative weight loss, failure to thrive and male gender were all markers for

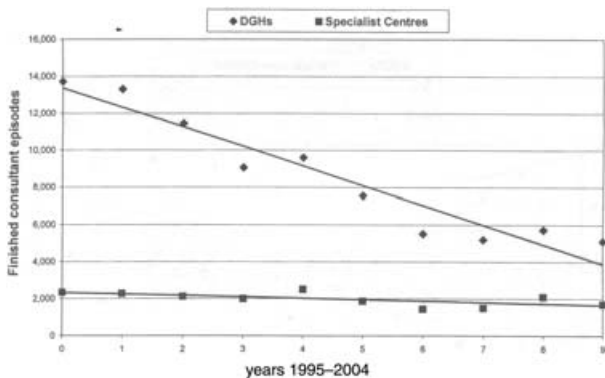


FIG. 2

Source: Cochrane & Tanner. Trends in Children’s Surgery. Royal College of Surgeons of England, Children’s Surgical Forum, London, 2005. DGHs = District General Hospitals

OSAS in the study group. Adenotonsillectomy was effective in abolishing OSAS in 84 per cent of the infants.⁶ In children who are obese and have OSAS, adenotonsillectomy significantly reduces respiratory distress and quality of life. OSAS is not improved and body mass index was unchanged following surgery.⁷

Adenoidectomy appears helpful as part of the management of OSAS and SDB. The benefit is largely due to removal of both the tonsils and the adenoid. In children undergoing adenoidectomy alone for upper airway obstruction, a proportion will require tonsillectomy at a later date, and the role of adenoidectomy as the sole procedure is uncertain. In more than 90 per cent of children, the decision to operate is based on clinical history and examination alone; pulse oximetry is a helpful screening tool, but while specific, it is diagnostically insensitive.

In some groups of children (infants, the obese and those with severe OSAS) surgery alone may be ineffective. Evidence from randomized controlled trials is not available to support or refute the effectiveness of surgical treatment for OSAS and SDB, but case series and cross-sectional studies support the benefit of adenoidectomy and tonsillectomy performed together.

Rhinosinusitis

The American Academy of Pediatrics published guidelines for the management of sinusitis in childhood. These addressed diagnosis and medical management, while no clear recommendations on surgical treatment were made.⁸ There is however, growing evidence that adenoidectomy is appropriate first-line surgical management of chronic rhinosinusitis in children. Antral puncture at the same time will allow culture and identification of specific bacteria.⁹

In a prospective study of 37 children aged from 2.3–12.7 years who suffered recurrent bouts of rhinosinusitis, there was a statistically significant reduction in episodes following adenoidectomy. Mean follow up was 450.2 days. The authors recommend that if surgical management is indicated, adenoidectomy should be the initial surgical option before considering endoscopic sinus surgery.¹⁰ Another small, uncontrolled observational study combined parenteral antibiotic treatment based on antral culture, with or without adenoidectomy for the management of rhinosinusitis that had failed to respond to one month of oral antibiotics. Eighty-nine per cent of cases resolved completely. There remains however, no good evidence that adenoidectomy is more effective than watchful waiting, allowing the immune system of the child to mature and the adenoid to involute. An uncontrolled study comparing endoscopic sinus surgery and adenoidectomy concluded that endoscopic sinus surgery was more effective. The study was small and from a highly selected group of children, referred to a tertiary centre. Outcome measures were based on a non-validated parental questionnaire.¹¹ In a review of the management of acute and chronic rhinosinusitis in children, the author concludes the place of sinus

surgery in children is limited, and the condition is not a surgical disease. Conservative measures, including nose-blowing, saline nasal sprays and topical anti-inflammatory nasal sprays, should be the first-line treatment before considering surgery, except where specific indications such as abscess or neoplasm warrant surgical treatment.¹²

For the small number of children with uncomplicated recurrent or chronic rhinosinusitis who fail conservative management, adenoidectomy and antral punctures are the least invasive, potentially helpful interventions.

Otitis media with effusion

The benefit of adenoidectomy in the management of otitis media with effusion (OME) has traditionally been ascribed to the relief of anatomical obstruction of the eustachian tube.¹³ While this may be a contributory factor, it is clear that adenoid size and physical obstruction alone cannot account for the benefit following adenoidectomy where the adenoid is small.¹⁴ Adenoid size in children with and without OME is not significantly different. It is likely that recurrent acute or chronic inflammation of the adenoid and increased bacterial load, particularly of *Haemophilus influenzae*,^{15,16} results in squamous cell metaplasia, reticular epithelium extension, fibrosis of the interfollicular connective tissue and reduced mucociliary clearance in children with OME compared to those without OME.¹⁷ These changes increase bacterial adherence. This is likely to contribute to the development of a 'biofilm' infection resulting in middle-ear effusion. (A biofilm infection may be defined as 'a structured community of bacterial cells enclosed in a self-produced polymeric matrix and adherent to an inert or living surface'.)¹⁸ There is now evidence, particularly from the TARGET and other studies to support adjuvant adenoidectomy as part of the surgical management of OME in children of three years of age and above, undergoing insertion of tympanostomy tubes.¹⁹

The concept that removal of the adenoid relieves physical obstruction of the eustachian tube is no longer tenable.²⁰ There remains, however, a popular and, to some extent, professional misconception that relieving physical blockage of the eustachian tubes allows fluid to drain from the middle ear. The description of the operation on a patient information web site, 'the surgeon scrapes out the adenoid with an instrument like a spoon with a sharp edge', [sic] is less than encouraging.²¹

Children with OME have a higher bacterial load in the adenoid²² and it is likely that this contributes to a chronic biofilm infection resulting in inflammation and sub-clinical infection of the nasopharynx, eustachian tube and middle ear.

The Medical Research Council Trial of Alternative Regimens in Glue Ear Treatments was a multi-centre, randomized controlled trial in the UK. A cohort of 639 children, between the ages of 3.25 and 6.75 years, with bilateral OME that had no previous ear or throat surgery, were included in the study. Those that failed watchful waiting were

managed by insertion of ventilation tubes (VTs) alone, or in combination with adenoidectomy. Adenoidectomy conferred additional advantage over VTs alone in terms of improved respiratory health over a two year period following surgery. The modest benefits to hearing in the VT group were limited to 12 months following surgery. Adding adenoidectomy to VTs was cost effective. (Haggard MP, 2005, personal communication.)

A retrospective case notes review from Ontario, Canada was carried out of all 37 316 children aged 19 years of age or younger who received ventilation tubes as their first surgical treatment for OME between 1995 and 1997. Compared with VTs alone, adjuvant adenoidectomy was associated with a reduction in the likelihood of reinsertion of VTs. The benefit of adjuvant adenoidectomy was most marked in the age group older than two years.²³

In the United States, published guidelines indicate that adenoidectomy should not be part of initial surgical management of OME. 'When a child becomes a candidate for surgery, tympanostomy tube insertion is the preferred initial procedure; adenoidectomy should not be performed unless a distinct indication exists (nasal obstruction, chronic adenoiditis). Tonsillectomy alone or myringotomy alone should not be used.'²⁴ While apparently contradictory, the US guidelines cover a younger group, below three years of age, in whom adenoidectomy is generally inappropriate for the management of otitis media with effusion.

Smell and taste

Very little published research has addressed the possible loss of sensation of smell and taste in children with adenoid hypertrophy. It is likely that some of the benefit in eating habits and growth following adenoidectomy are in part due to improved appreciation of food and not relief of nasal obstruction alone. Two small studies confirmed the improvement in nasal airflow and olfaction following adenoidectomy.^{25,26} Another small, but elegantly designed study, prospectively measured both orthonasal and retronasal sensation before and after adenoidectomy to attempt to assess both smell and taste before and after adenoidectomy.²⁷ Of an initial group of 35 children with a mean age of 5.9 years, 28 could be followed up post-adenoidectomy. The control group was 30 children of comparable mean age with no adenoidal symptoms or signs. Orthonasal sensation was assessed using 12 standard Sniffin[®] Sticks. Retronasal olfaction was assessed with 12 grocery powders applied to the oral cavity. For both types of smell sensation, the scores were significantly lower in the pre-operative group than the control group. Following adenoidectomy in the surgical group, olfaction significantly improved, and retronasal olfaction improved more than orthonasal olfaction. The authors concluded that children with adenoid hypertrophy have a reduced ability to smell, with retronasal olfactory function being more affected than orthonasal olfaction. Adenoidectomy had a greater impact on retronasal olfaction.

Surgical technique

Adenoidectomy with or without tonsillectomy and/or insertion of ventilation tubes is one of the most frequently performed surgical procedures in children. The rate of surgical intervention varies considerably within and across countries (see Figure 3), leading public health analysts to question the criteria and efficacy of the operation.

Traditional adenoidectomy is carried out under general anaesthesia, with the child in the tonsillectomy position, using the blind technique of curettage. Assessment of the adenoid is made digitally prior to curetting the adenoid from the nasopharynx, and haemostasis achieved with gauze swab tamponade. Techniques employing direct vision have the advantage of reduced blood loss (<4 ml versus >50 ml),²⁹ and the ability to remove adenoid tissue from the choanae, while avoiding trauma to the eustachian cushions.³⁰ Of these techniques, those with the largest clinical experience are the suction coagulator and the microdebrider. In a randomized controlled trial, the microdebrider was 20 per cent faster than the curettage technique,³¹ but the suction coagulator is significantly cheaper than the microdebrider. Single use instruments such as these abolish any potential risk of infection transmission.³² The Coblator[®] plasma field device may prove suitable for adenoidectomy, but as yet no published data are available. The KTP laser is associated with a high incidence of post-operative nasopharyngeal stenosis and is not recommended for adenoidectomy.³³

Complications of adenoidectomy

Significant complications include per-operative blood loss, post-operative haemorrhage, damage to teeth or the cervical spine and velopharyngeal insufficiency. No data assessing the risk of death following adenoidectomy independent of tonsillectomy or general anaesthesia was found. The reactionary haemorrhage rate, that is bleeding following adenoidectomy within six to 12 hours of operation, is less than 0.7 per cent. If severe enough to require a return to theatre, postnasal packing is the preferred management in the UK for haemostasis.³⁴ Blood may pool and clot in the nasopharynx during the procedure. The nasopharynx should be gently suctioned to clear any clot before removing the gag. Failure to

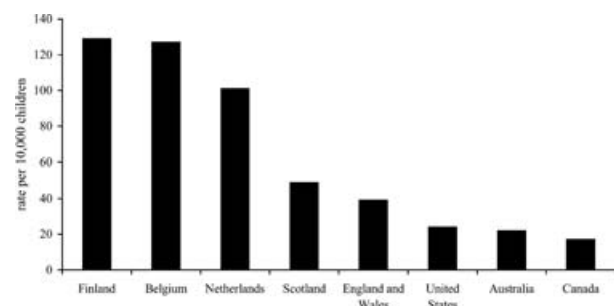


FIG. 3

Rates of adenoidectomy in different countries (Source: Schilder *et al.*, 2004).²⁸

do so may lead to the clot falling onto the larynx during recovery and causing potentially fatal acute airway obstruction. (The 'coroner's clot'.) Children with Down's syndrome may have atlanto-axial instability. Traditionally, such children had plain imaging of the cervical spine prior to surgery but this is no longer considered necessary in uncomplicated cases. Vigilant attention to the child's peri-operative neck position is essential.

Severe velopharyngeal incompetence is rare following adenoidectomy, estimated to occur in between 1:1500 and 1:10 000 procedures. It may lead to significant problems with hypernasal speech and swallowing, severe enough to cause nasal regurgitation of fluids. It is mandatory to assess the palate and uvula for submucous cleft of the palate prior to surgery as surgery often unmasks pre-existing palatal dysfunction.³⁵

Unsuspected neoplasia of the adenoid (and tonsils) in childhood is rare. Non-Hodgkins lymphoma is reported in a series of six children.³⁶ Atypical lymphadenopathy, and persistent and asymmetric enlargement of the tonsils and adenoid, in the absence of infection, are suspicious and should prompt early imaging and biopsy.

Regrowth of the adenoid following surgery is uncommon. A cross-sectional follow-up study of children after adenoidectomy, two to five years after surgery, concluded that 71 per cent had no residual obstructing adenoid. However, the criterion for adenoid sufficient to cause nasal obstruction was tissue occupying more than 40 per cent of the nasopharynx.³⁷ Empirically, many surgeons may consider this significant enough to warrant further surgery.

Immune status following adenoidectomy

The adenoid is similar to nasal associated lymphoid tissue in rodents. Animal *in vivo* and human *in vitro* research indicates that the CD5⁺ B cells are a first line of defence in the upper respiratory tract. The CD5⁺ B cells also form part of the natural memory immunity. These cells are in their greatest number in those less than three years of age. This and other immunological evidence suggests that removal of adenoid in young children should be avoided if possible to minimize the risk of immune compromise.³⁸ In children aged 4–10 years, adenotonsillectomy does not appear to cause significant immune deficiency, although a slight decrease in IgG, IgA and IgM levels was found in the post-operative period four to six weeks after surgery.³⁹ The authors concluded that this represents a compensatory response of the developing immune system following a reduction of chronic antigen stimulation. Specific reduction in IgG may represent a reduction in antigenic stimulation. There appears to be no decrease in IgE after adenoidectomy.⁴⁰ The evidence that immune status is compromised by removal of the adenoid alone is inconclusive, as studies generally include children also having tonsillectomy.⁴¹

Conclusions

Adenoidectomy is a common childhood operation that has attracted little in the way of high quality

primary research. Most of the evidence that is available includes data combined with tonsil and grommet surgery. Adenoidectomy appears to be effective as part of the management of childhood sleep apnoea syndrome, when combined with tonsillectomy, although high-level evidence of efficacy is lacking.

Adenoidectomy alone improves nasal airflow and the sense of smell and taste. Growth after adenoidectomy may in part be due to an improved appetite associated with the improvement in smell and taste.

As part of the surgical management of glue ear where watchful waiting has failed and the child is over three years of age, adenoidectomy with grommet surgery appears to be more effective than adenoidectomy alone. In the face of this relatively new information, it is surprising, perhaps, that the rate of adenoidectomy is falling. The benefit from adenoidectomy is likely to be shown to be the result of removing a source of biofilm infection in the nasopharynx. Removal of the adenoid in children over three years of age does not have a clinically significant effect on the immune status of the child.

References

- 1 Lim J, McKean M. Adenotonsillectomy for obstructive sleep apnoea in children. *The Cochrane Database of Systematic Reviews* 2001, Issue 3. Art. No.: CD003136. DOI: 10.1002/14651858.CD003136
- 2 Schechter MS, and the Section on Pediatric Pulmonology, Subcommittee on Obstructive Sleep Apnea Syndrome. Technical Report: Diagnosis and Management of Obstructive Sleep Apnea Syndrome. *Pediatrics* 2002;**109**:69–89
- 3 Kotagal S. Childhood obstructive sleep apnoea. *Br Med J* 2005;**330**:978–79
- 4 Guillemainault C, Li KK, Khramtsov A, Pelayo R, Martinez S. Sleep disordered breathing: surgical outcomes in prepubertal children. *Laryngoscope* 2004;**114**:132–7
- 5 Kay DJ, Bryson PC, Casselbrant M. Rates and risk factors for subsequent tonsillectomy after prior adenoidectomy. A regression analysis. *Arch Otolaryngol Head Neck Surg* 2005;**131**:252–5
- 6 Greenfeld M, Tauman R, DeRowe A, Sivan Y. Obstructive sleep apnea syndrome due to adenotonsillar hypertrophy in infants. *Int J Pediatr Otorhinolaryngol* 2003;**67**:1055–60
- 7 Mitchell RB, Kelly J. Adenotonsillectomy for obstructive sleep apnea in obese children. *Otolaryngol Head Neck Surg* 2004;**131**:104–8
- 8 American Academy of Pediatrics. Clinical Practice Guideline: Management of Sinusitis. Subcommittee on Management of Sinusitis and Committee on Quality Improvement. *Pediatrics* 2001;**108**:798–808
- 9 Lieser JD, Derkay CS. Pediatric sinusitis: when do we operate? *Curr Op Otolaryngol Head Neck Surg* 2005;**13**:60–6
- 10 Ungkanont K, Damrongsak S. Effect of adenoidectomy in children with complex problems of rhinosinusitis and associated diseases. *Int J Pediatr Otorhinolaryngol* 2004;**68**:447–51
- 11 Ramadan HH. Adenoidectomy vs endoscopic sinus surgery for the treatment of pediatric sinusitis. *Arch Otolaryngol Head Neck Surg* 1999;**125**:1208–11
- 12 Jones NS. Acute and chronic sinusitis in children. *Curr Op Pulm Med* 2000;**6**:221–5
- 13 Nguyen LHP, Manoukian JJ, Yoskovitch A, Al-Sebeih KH. Adenoidectomy: selection criteria for surgical cases of otitis media. *Laryngoscope* 2004;**114**:863–6
- 14 Gates GA. Adenoidectomy for otitis media with effusion. *Ann Otol Rhinol Laryngol Suppl* 1994;**163**:54–8
- 15 Suzuki M, Watanabe T, Mogi G. Clinical, bacteriological and histological study of adenoids in children. *Am J Otolaryngol* 1999;**20**:85–90

- 16 Brook I, Shah K, Jackson W. Microbiology of healthy and diseased adenoids. *Laryngoscope* 2000;**110**:994–9
- 17 Yasan H, Dogru H, Tuz M, Candir O, Uygur K, Yariktas M. Otitis media with effusion and histopathologic properties of adenoid tissue. *Int J Pediatr Otorhinolaryngol* 2003;**67**:1179–83
- 18 Fergie N, Bayston R, Pearson JP, Birchall JP. Is otitis media with effusion a biofilm infection? *Clin Otolaryngol* 2004;**29**:38–46
- 19 Maw AR. Chronic otitis media with effusion and adenotonsillectomy—a prospective randomized controlled study. *Int J Pediatr Otorhinolaryngol* 1983;**6**:239–46
- 20 Wright ED, Pearl AJ, Manoukian JJ. Laterally hypertrophic adenoids as a contributing factor in otitis media. *Int J Pediatr Otorhinolaryngol* 1998;**45**:207–14
- 21 Adenoidectomy – information for parents and patients published at a. <http://www.besttreatments.co.uk/btuk/electsurgeryside/18623.html> and b. London: BMJ Publishing Group, 2005.
- 22 Tomonga K, Kuroono Y, Chaen T, Mogi G. Adenoids and otitis media with effusion: nasopharyngeal flora. *Am J Otolaryngol* 1989;**10**:204–7
- 23 Coyte PC, Croxford R, McIsaac W, Feldman W, Friedberg J. The role of adjuvant adenoidectomy and tonsillectomy in the outcome of the insertion of tympanostomy tubes. *New Eng J Med* 2001;**344**:1188–95
- 24 Rosenfeld RM, Culpepper L, Doyle KJ, Grundfast KM, Hoberman A, Kenna MA *et al.* American Academy of Pediatrics Subcommittee on Otitis Media with Effusion; American Academy of Family Physicians; American Academy of Otolaryngology – Head and Neck Surgery. Clinical practice guideline: Otitis media with effusion. *Otolaryngol Head Neck Surg* 2004;**130**(Suppl 5):S95–118
- 25 Ghorbanian SN, Paradise JL, Doty RL. Odor perception in children in relation to nasal obstruction. *Pediatrics* 1983;**72**:510–16
- 26 Delank KW. Olfactory sensitivity in adenoid hyperplasia. *Laryngorhinootologie* 1992;**71**:293–7
- 27 Konstantinidis I, Triaridis S, Triaridis A, Petropoulos I, Karagiannidis K, Kontzoglou G. How do children with adenoid hypertrophy smell and taste? Clinical assessment of olfactory function pre- and post-adenoidectomy. *Int J Pediatr Otorhinolaryngol* 2005;**69**:1343–9
- 28 Schilder AG, Lok W, Rovers MM. International perspectives on management of acute otitis media: a qualitative review. *Int J Pediatr Otorhinolaryngol* 2004;**68**:29–36
- 29 Clemens J, McMurray JS, Willging JP. Electrocautery versus curette adenoidectomy: comparison of postoperative results. *Int J Pediatr Otorhinolaryngol* 1998;**43**:115–22
- 30 Havas T, Lowinger D. Obstructive adenoid tissue: an indication for powered-shaver adenoidectomy. *Arch Otolaryngol Head Neck Surg* 2002;**128**:789–91
- 31 Elluru RG, Johnson L, Myers CM III. Electrocautery adenoidectomy compared with curettage and power-assisted methods. *Laryngoscope* 2002;**112**:23–5
- 32 Walker P. Pediatric adenoidectomy under vision using suction diathermy ablation. *Laryngoscope* 2001;**111**:2173–7
- 33 Giannoni C, Sulek M, Friedman EM, Duncan M III. Acquired nasopharyngeal stenosis. A warning and review. *Arch Otolaryngol Head Neck Surg* 1998; **124**:163–6
- 34 Tzifa KT, Skinner DW. A survey on the management of reactionary haemorrhage following adenoidectomy in the UK and our practice. *Clin Otolaryngol* 2004;**29**:153–6
- 35 Saunders NC, Hartley BEJ, Sell D, Sommerlad B. Velopharyngeal insufficiency following adenoidectomy. *Clin Otolaryngol* 2004;**29**:686–8
- 36 Ridgway D, Wolff LJ, Neerhout RC, Tilford DL. Unsuspected non-Hodgkins lymphoma of the tonsils and adenoids in children. *Pediatrics* 1987;**79**:399–402
- 37 Buchinsky FJ, Lowry MA, Isaacson G. Do adenoids grow after excision? *Otolaryngol Head Neck Surg* 2000;**123**:576–81
- 38 Arita M, Kodama S, Suzuki M, Mogi G. Single cell analysis of adenoid CD5+B cells and their protective contributions to nasopharyngeal immunity. *Laryngoscope* 2003;**113**:484–491
- 39 Ikinciogullari A, Dogu F, Ikinciogullari A, Egin Y, Babacan E. Is the immune system influenced by adenotonsillectomy in children? *Int J Pediatr Otorhinolaryngol* 2002;**66**:251–7
- 40 Modrzynski M, Zawisza E, Rapiejko P. Serum immunoglobulin E levels in relation to Waldeyer's ring surgery. *Przegi-Lek* 2003;**60**:325–8
- 41 Friday GA Jr, Paradise JL, Rabin BS, Colborn DK, Taylor FH. Serum immunoglobulin changes in relation to tonsil and adenoid surgery. *Ann Allergy* 1992;**69**:225–30

Address for correspondence:
Mr Peter J Robb,
ENT Department,
Epsom & St Helier University Hospitals NHS Trust,
Epsom, Surrey KT18 7EG, UK.

E-mail: peter.robb@epsom-sthelier.nhs.uk

Mr Peter J Robb takes responsibility for the integrity of the content of the paper.
Competing interests: None declared
