

Comparative evaluation of conventional versus endoscopic septoplasty for limited septal deviation and spur

J Laryngol Otol 2008;122:1–5

Dear Sirs

We sincerely congratulate Drs Bothra and Mathur for their very interesting paper on comparative evaluation of conventional versus endoscopic septoplasty, published recently in *The Journal of Laryngology & Otology*.¹ We have read this manuscript with great interest.

Even so, we would like to highlight some points which in our opinion are very much connected to the problem described in this paper. In our opinion, describing the morphological appearance of a septal deformity based exclusively on the author's subjective impression, usually expressed literally, leads to confusion and may also diminish the value of any attempts to standardise the management of nasal septal deformities. It is obvious to us that such descriptions as '(septal) deviation', '(septal) deformity', 'cartilaginous (septum) deviation', 'bony (septum) deviation' etc potentially constitute a terminological mess, and that standardisation would be beneficial. This problem will be solved only by accepting one 'gold standard' of septal deformity classification.

More than 20 years ago, Mladina published a systematic classification of septal deformities.² He defined precisely the clinical findings at the nasal septum, proposing seven different types of deformity. This relatively simple but very 'user-friendly' classification of septal deformities has had great impact on the understanding of sino-nasal pathophysiology. The usefulness and simplicity of this classification system have been confirmed by numerous international studies.^{3–5}

In Mladina's classification (Figure 1), the first three types of septal deformity are unilateral and almost vertical. The type four deformity is still vertical but bilateral (the so-called S-shaped septum), whereas types five and six are quite horizontal. Type seven comprises a combination of the above types.

The type one deformity consists of a unilateral vertical septal ridge in the valve region, which superiorly does not reach the valve itself and which does not change the physiological valve angle (15°); therefore, it usually plays only a mild role in nasal pathophysiology. Type two comprises almost the same unilateral vertical septal ridge in the valve region but is much more emphasised: it involves the nasal valve, touching it closely, and thus greatly diminishes the physiological valve angle (to less than 15°).

The type three septal deformity also consists of a unilateral vertical ridge, but this time located more deeply in the nasal cavity, just opposite the head of the middle turbinate.

The type four defect is a bilateral deformity which consists of a type two defect on one side and a type three defect on the other. This type is well known in the literature under the term 'S-shaped septum'.

The type five deformity comprises an almost horizontal septal spur which protrudes laterally and is deeper in the nasal cavity. The opposite side of the nasal septum is always flat.

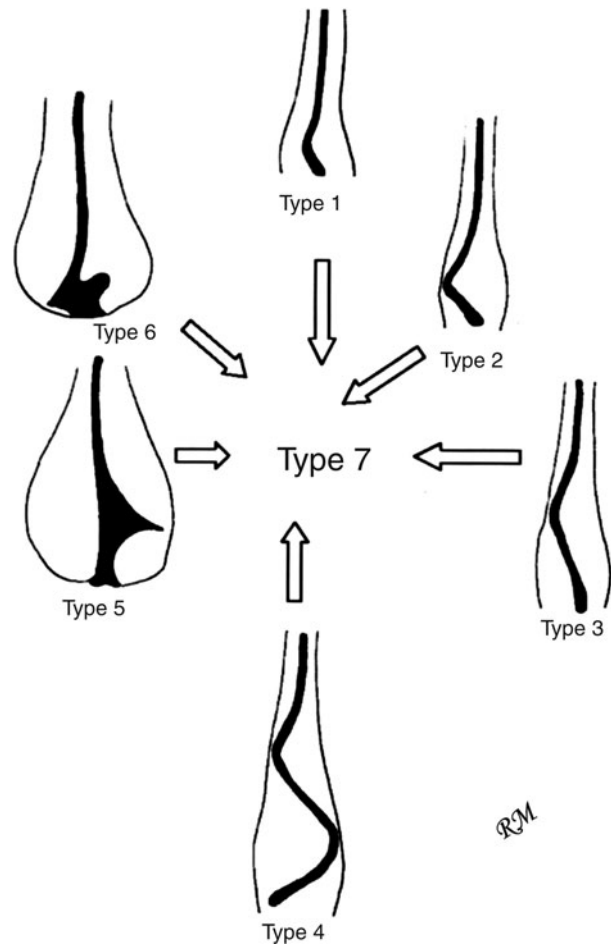


FIG. 1

Mladina's classification of septal deformities. (Published with permission)

The type six deformity consists of, on one side, a unilateral, massive, intermaxillary bone wing and more or less deep gutter between it and the rest of the septum and, on the other side, an anteriorly positioned, basal septal crest.

Types one, five and six septal deformities have practically no effect on the external appearance of the nose, whereas types two, three, four and seven may greatly influence the general shape of the nose.

N B Skitarelic

K Vukovic*

N P Skitarelic†

From the Departments of Otolaryngology Head and Neck Surgery and †Pediatrics, Zadar General Hospital, and the *Department of Otolaryngology Head and Neck Surgery, University Hospital Zagreb, Croatia.

First published online 27 May 2009.

References

- 1 Bothra R, Mathur NN. Comparative evaluation of conventional versus endoscopic septoplasty for limited septal deviation and spur. *J Laryngol Otol* 2008;**122**:1–5
- 2 Mladina R. The role of maxillar morphology in the development of pathological septal deformities. *Rhinology* 1987;**25**:199–205
- 3 Yildirim I, Okur E. The prevalence of nasal septal deviation in children from Kahramanmaras, Turkey. *Int J Pediatr Otorhinolaryngol* 2003;**67**:1203–6
- 4 Zielnik-Jurkiewicz B, Olszewska-Sosińska O. The nasal septum deformities in children and adolescents from Warsaw, Poland. *Int J Pediatr Otorhinolaryngol* 2006;**70**:731–6
- 5 Mladina R, Čujić E, Šubarić M, Vuković K. Nasal septal deformities in ear, nose, and throat patients: an international study. *Am J Otolaryngol* 2008;**29**:75–82

Author's reply

Dear Sirs

I thank Drs Neven Skitarelic, Katarina Vukovic and Natasa Skitarelic for reading our report and making some very

relevant comments. I fully agree with their view of the need for standardisation in assessing and reporting septal deviations. However, I must emphasise that our assessment was as objective as the system they have suggested. In our series, we standardised our findings and results as per Cottle areas. We feel that the Cottle's nomenclature and classification that we used in our series was also very convenient, especially when assessing the deviation endoscopically.

However, consensus on a classification system for reporting septal deviations would most certainly go a long way when comparing and analysing the results of different studies. At present, such classification must involve input from a detailed endoscopic assessment of the septum in relation to the lateral nasal wall and its attachment to the wings of the premaxilla.

N N Mathur
Department of ENT,
Lady Hardinge Medical College,
New Delhi,
India