

Geographical distribution of *Angiostrongylus vasorum* in foxes (*Vulpes vulpes*) in the Republic of Ireland

G. MCCARTHY^{1*}, M. FERRAND², T. DE WAAL³, A. ZINTL³, G. MCGRATH⁴,
W. BYRNE⁵ and E. J. O'NEILL¹

¹ *Veterinary Clinical Sciences, School of Veterinary Medicine, University College Dublin, Belfield, Dublin 4, Republic of Ireland*

² *Département de Génie Biologique, Institut Universitaire de Technologie, Université Claude Bernard Lyon 1, France*

³ *Veterinary Pathobiology, School of Veterinary Medicine, University College Dublin, Belfield, Dublin 4, Republic of Ireland*

⁴ *Centre for Veterinary Epidemiology and Risk Analysis, School of Veterinary Medicine, University College Dublin, Belfield, Dublin 4, Republic of Ireland*

⁵ *Central Veterinary Research Laboratory, Backweston Campus, Young's Cross, Celbridge, Co. Kildare, Republic of Ireland*

(Received 11 December 2015; revised 22 December 2015; accepted 4 January 2016)

SUMMARY

The reported incidence of the metastrongylid nematode *Angiostrongylus vasorum*, that infects dogs and other canids, is increasing worldwide outside recognized endemic foci. This apparent expansion of the parasite's range is causing concern to veterinary clinicians as the disease caused in dogs can be life threatening and its treatment is not straightforward. The red fox is thought to be a reservoir host for dogs. To investigate the spatial distribution of infection in foxes in Ireland, the hearts and lungs of 542 foxes from all over Ireland were examined. The incidence of infection was found to be 39.9% [95% confidence interval (CI) 35.7–44.1] with positive samples occurring in each of the country's 26 counties. This report confirms that the parasite is endemic in Ireland and the overall prevalence is the second highest in Europe. This is the first survey of *A. vasorum* infection in Irish foxes and highlights the potential exposure of the Irish dog population to high risk of cross-infection. Additionally, *Crenosoma vulpis* was found in seven of the foxes, a parasite not previously reported in the Irish fox.

Key words: *Angiostrongylus vasorum*, angiostrongylosis, fox, dog, Ireland, reservoir, endemic.

INTRODUCTION

Angiostrongylus vasorum is a metastrongylid nematode known to infect dogs and wild canids using gastropod molluscs as intermediate hosts. Dogs are highly susceptible to infection and the subsequent disease can be life-threatening. A wide range of clinical presentations have been recognized including coagulopathies, respiratory, neurological, locomotor and cardiovascular signs, with some dogs being asymptomatic (Morgan *et al.* 2010). *Angiostrongylus vasorum* infection has been reported in several areas of Europe, Africa, Canada, and North and South America (Helm *et al.* 2010). New reports of its occurrence in several countries, in which it has previously been unreported, have sparked interest in its current distribution and the apparent expansion in its geographical range. Canine infection in the UK was initially reported to have occurred in Cornwall (Martin and Neal, 1992) and South Wales (Patteson *et al.* 1993), then to have spread across into Southeast England and later, into Northern England

(Yamakawa *et al.* 2009) and Scotland (Helm *et al.* 2009).

The first UK report of *A. vasorum* infection in red foxes (*Vulpes vulpes*) was made in Cornwall, with five cases reported close to the location of the first canine cases reported in that country (Simpson, 1996). Two of these cases were clinically symptomatic for the infection and had severe lung lesions closely resembling those observed in dogs dying from angiostrongylosis. Studies of foxes in Denmark, close to Copenhagen, showed a high incidence of infection; however, in contrast, these foxes were not known to be clinically ill and showed minimal pathology (Bolt *et al.* 1992). This group proposed that there is a good degree of host–parasite adaptation and it is now known that red foxes are the major wildlife reservoir for dogs in Europe (Tolnai *et al.* 2015). Hence, knowledge about infection rates in foxes is of relevance to canine health. Surveys of foxes carried out in Great Britain between 2005 and 2006 found an overall infection rate of 7.3% (Morgan *et al.* 2008) increasing to 18.3% in 2013–2014 (Taylor *et al.* 2015). It is of interest, that this apparent increase in fox infection rate mirrors the increase in canine angiostrongylosis cases in the UK.

* Corresponding author: Veterinary Clinical Sciences Section, School of Veterinary Medicine, University College Dublin, Belfield, Dublin 4, Republic of Ireland. E-mail: grainne.mccarthy@ucd.ie

The first canine case reported in Ireland was in a greyhound in 1968 (Roche and Kelliher, 1968). Further Irish cases have been reported sporadically over the years (Dodd, 1973; Brennan *et al.* 2004; O'Neill *et al.* 2010; Gallagher *et al.* 2012; Zarelli *et al.* 2012). However, while *A. vasorum* has been identified previously in Irish foxes around the Dublin region (Wolfe *et al.* 2001), it was reported to be of low prevalence and no indication of the number of infected animals was provided. The distribution and rate of infection in foxes, or indeed in dogs, in Ireland has never been formally examined. This is important to facilitate evidence-based decision-making with regard to risk management and the need for preventative healthcare for dogs with respect to their potential exposure to *A. vasorum*.

The aims of this study were to confirm the presence and the geographical distribution of *A. vasorum* in red foxes throughout Ireland, providing an estimate of the countrywide wildlife reservoir of infection. This information will, in turn, serve as a baseline to monitor any future spread of the parasite in the fox population.

MATERIALS AND METHODS

Acquisition of foxes

Samples examined in this study were obtained from the Department of Agriculture, Food and the Marine and from the Irish Equine Centre. Foxes were sourced through the Irish governmental screening programme for *Echinococcus multilocularis* status under EU Regulation 1152/2011. The sampling strategy included the objective to obtain foxes from all regions and counties in Ireland. The foxes were culled, by shooting, for pest and predator control and some were inadvertently captured in traps set for other wildlife as part of wildlife disease control measures. The fox population in Ireland has been estimated between 150 000 and 200 000 (Hayden and Harrington, 2000; Marnell *et al.* 2009). In terms of sampling size to estimate infection prevalence for *A. vasorum*, assuming an expected 30% prevalence with 95% confidence interval (CI) and 5% precision, 323 fox samples needed to be examined (Thrusfield, 1986). However, as 550 samples were available, all were examined. Plucks (trachea, heart and lungs) from these foxes, killed between July 2014 and May 2015, were collected and examined as described below. Precise information (within 0.5 km) about the location of where each fox was found was available for all but two animals included in the survey. All plucks obtained were frozen and maintained at -20°C until thawed for examination.

Parasitological investigation

To examine for *A. vasorum*, the heart was removed from the pericardium, an incision made through

the right atrium and ventricle, the pulmonary arterial trunk opened by cutting along its length towards the lungs and the arterial supply to each of the seven lung lobes opened in turn. This dissection necessitated cutting through some small airways and pulmonary tissues. The cardiac chambers and arteries were inspected visually for the presence of parasites. The pluck was then immersed in a white, shallow bowl of water and washed thoroughly and the process was repeated twice. Parasites were identified visually and removed. All blood clots were manually disrupted and examined for the presence of worms. Recovered parasites were collected and stored in 10% buffered formalin for microscopic confirmation of identity. Parasites for microscopic identification were cleared in lactophenol for 48 h prior to examination at $40\times$ magnification. Confirmation of identification was carried out by a European College Board certified parasitologist (TdW).

RESULTS

Overall, 550 fox plucks were examined; 394 were obtained from the Department of Agriculture, Food and the Marine and a further 156 plucks from the Irish Equine Centre. Eight samples were severely damaged by shooting and were excluded from the study. Of the remaining 542 plucks, 216 (39.9%) were positive for *A. vasorum* based on visual inspection and later confirmed by microscopy of collected parasites. *Crenosoma vulpis* adult parasites were coincidentally identified in seven of these foxes (1.3%), four foxes showing dual infection. The geographical distribution of *A. vasorum* positive and negative foxes is shown in Fig. 1. Positive samples were obtained from each of the 26 counties in the Republic of Ireland (Table 1). The prevalence of infection ranged from 11.1 to 72.7%, with one county having the prevalence in excess of 70%, seven in excess of 50%, and three counties with a low prevalence of less than 13% (Fig. 2).

DISCUSSION

Angiostrongylus vasorum is found in Europe, Africa, North and South America (Taylor *et al.* 2015). Dogs and wild canids such as foxes, wolves, coyotes and jackals are known to be definitive hosts (Morgan and Shaw, 2010; Elsheikha *et al.* 2014). The parasite primarily uses gastropods (slugs and snails) as its intermediate hosts and as many as 25 species have been identified as being suitable (Tonsberg, 2006). Overall the best documented wildlife reservoir of *A. vasorum* is the red fox (Otranto *et al.* 2015).

In affected countries, angiostrongylosis had previously occurred in well-defined, endemic areas, with only sporadic cases reported outside these locations (Bolt *et al.* 1994). However, recent reports of disease prevalence suggest an apparent expansion

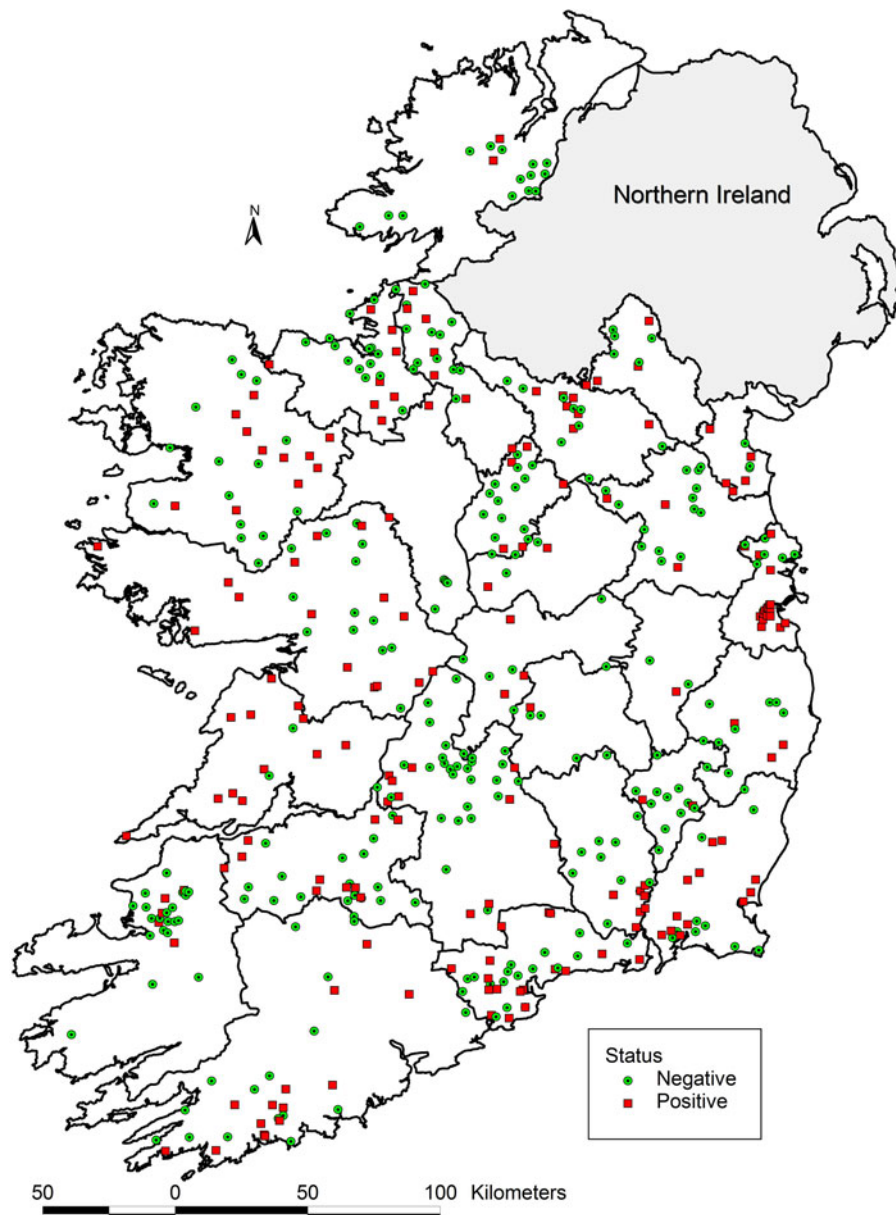


Fig. 1. Geographical distribution of fox samples screened for *Angiostrongylus vasorum*. Red squares represent positive samples. Green circles represent negative samples.

in the parasite's range to areas outside known endemic areas. For instance, *A. vasorum* has been newly identified in dogs in Slovakia (Hurnikova *et al.* 2013), Serbia (Simin *et al.* 2014) and Belgium (Jolly *et al.* 2015) and in foxes in Poland (Demiaszkiewicz *et al.* 2014) and USA (Kistler *et al.* 2014). Such an expansion pattern was predicted by a model of potential global distribution of *A. vasorum* presented by Morgan *et al.* (2009).

Interestingly, the first reported cases in the UK, and in the USA, were in greyhounds that had been imported from the Irish Republic (Jacobs and Prole, 1975; Williams *et al.* 1985). In Ireland, *A. vasorum* is considered endemic.

In 2009 in Europe, the reported prevalence of *A. vasorum* infection in the fox ranged from 5 to 49% and was reported to be higher than that in

dogs (range 0.3–9.8%) from the same geographical area (Koch and Willeßen, 2009). This suggests that foxes may serve as reservoir hosts for infection in dogs. This hypothesis is supported by studies showing that the parasite can be transmitted between fox and dog (Guilhon, 1965; Bolt *et al.* 1992). In addition, Jefferies and colleagues found no evidence of genetic disparity between *A. vasorum* isolates from foxes and dogs (Jefferies *et al.* 2009).

In 2014/2015, the reported prevalence of *A. vasorum* infection in foxes in various European countries ranged from 4.2 to 51.8% [51.8% ($n=329$) in Italy, 17.9% ($n=937$) in Hungary, 5.2% ($n=76$) in Poland and 4.2% ($n=96$) in the Netherlands (Demiaszkiewicz *et al.* 2014; Eleni *et al.* 2014; Franssen *et al.* 2014; Magi *et al.* 2015; Santoro *et al.*

Table 1. Total numbers of samples examined and prevalence per county

County	Total	Positive [<i>n</i> (%)]	95% CI
Carlow	16	2 (12.5)	1.6–38.3
Cavan	17	9 (52.9)	27.8–77
Clare	11	8 (72.7)	39–94
Cork	34	17 (50.0)	32.4–67.6
Donegal	16	2 (12.5)	1.6–38.3
Dublin	39	26 (66.7)	49.8–80.9
Galway	28	16 (57.1)	37.2–75.5
Kerry	26	6 (23.1)	9–43.6
Kildare	5	2 (40.0)	5.3–85.3
Kilkenny	19	7 (36.8)	16.3–61.6
Laois	5	1 (20.0)	0.5–71.6
Leitrim	21	7 (33.3)	14.6–57
Limerick	36	16 (44.4)	27.9–61.9
Longford	21	6 (28.6)	11.3–52.2
Louth	8	5 (62.5)	24.5–91.5
Mayo	26	11 (42.3)	23.4–63.1
Meath	17	3 (17.6)	3.8–43.4
Monaghan	8	3 (37.5)	8.5–75.5
Offaly	8	3 (37.5)	8.5–75.5
Roscommon	9	1 (11.1)	0.3–48.2
Sligo	21	8 (38.1)	18.1–61.6
Tipperary	51	10 (19.6)	9.8–33.1
Waterford	41	21 (51.2)	35.1–67.1
Westmeath	3	1 (33.3)	0.8–90.6
Wexford	40	20 (50.0)	33.8–66.2
Wicklow	14	3 (21.4)	4.7–50.8
No county identified	2	2 (100.0)	
All samples	542	216 (39.9)	35.7–44.1

Confidence Intervals (95% CI) were calculated using GraphPad Prism version.6, GraphPad Software, California, USA.

2015; Tolnai *et al.* 2015)]. A survey of 546 UK foxes, carried out between 2005 and 2006, found an overall prevalence of infection of 7.3% (Morgan *et al.* 2008). This was followed by a survey of 442 foxes carried out in 2013–2014 which found an overall prevalence of 18.3% with an infection rate of 7.4% occurring in Northern UK; an area that had previously had zero prevalence (Taylor *et al.* 2015).

This study represents the first comprehensive survey of *A. vasorum* in foxes in the Republic of Ireland. Red foxes have been observed in all parts of Ireland (National Biodiversity Data Centre, 2015) and the survey sampling strategy included the objective to obtain samples from all regions and counties. Additionally, from the point of view of coverage of the country, a large number of foxes were examined compared with the geographical area (Republic of Ireland 70 273 km²) with an average of 21 foxes collected from each of the country's 26 counties (range 3–52). In view of this, and the total number of samples examined, the report provides robust evidence of widespread distribution of *A. vasorum* infection in the Irish fox population.

This report confirms that the parasite is endemic in the Republic of Ireland and that, based on these current figures, the overall prevalence in Irish foxes is second highest in Europe. Prevalence rates varied throughout the 26 counties ranging from

72.7% (Co Clare) to 11.1% (Co Roscommon) indicating that the infected fox reservoir spans the country with an overall prevalence rate of 39.9%.

In a previous study, 79 faecal samples were collected from Irish foxes on the east coast of Ireland ('Dublin and the surrounding counties' *sic*) and *A. vasorum* larvae were recorded to be of 'low prevalence' in these samples (Wolfe *et al.* 2001). However, faecal samples were only examined by saturated sugar flotation and not by modified Baermann flotation technique. In Dublin and the surrounding counties (Meath, Kildare and Wicklow) in this study, the overall prevalence rate was 36.4% which is close to the national average. This may suggest that the prevalence of infection is increasing in this part of the country.

C. vulpis, another metastrongylid parasite which uses gastropods as intermediate hosts, has a worldwide distribution in dogs and foxes (Levine, 1980) where it inhabits the trachea, bronchi and bronchioles. The only clinical case reported to date in Ireland was from a 1-year-old Cavalier King Charles Spaniel from Northern Ireland (Reilly *et al.* 2000). To our knowledge, it has not been previously reported on the island of Ireland in the fox but its presence was presumed (Conboy *et al.* 2009). Its coincidental discovery in seven foxes in this study, confirms its presence in foxes in

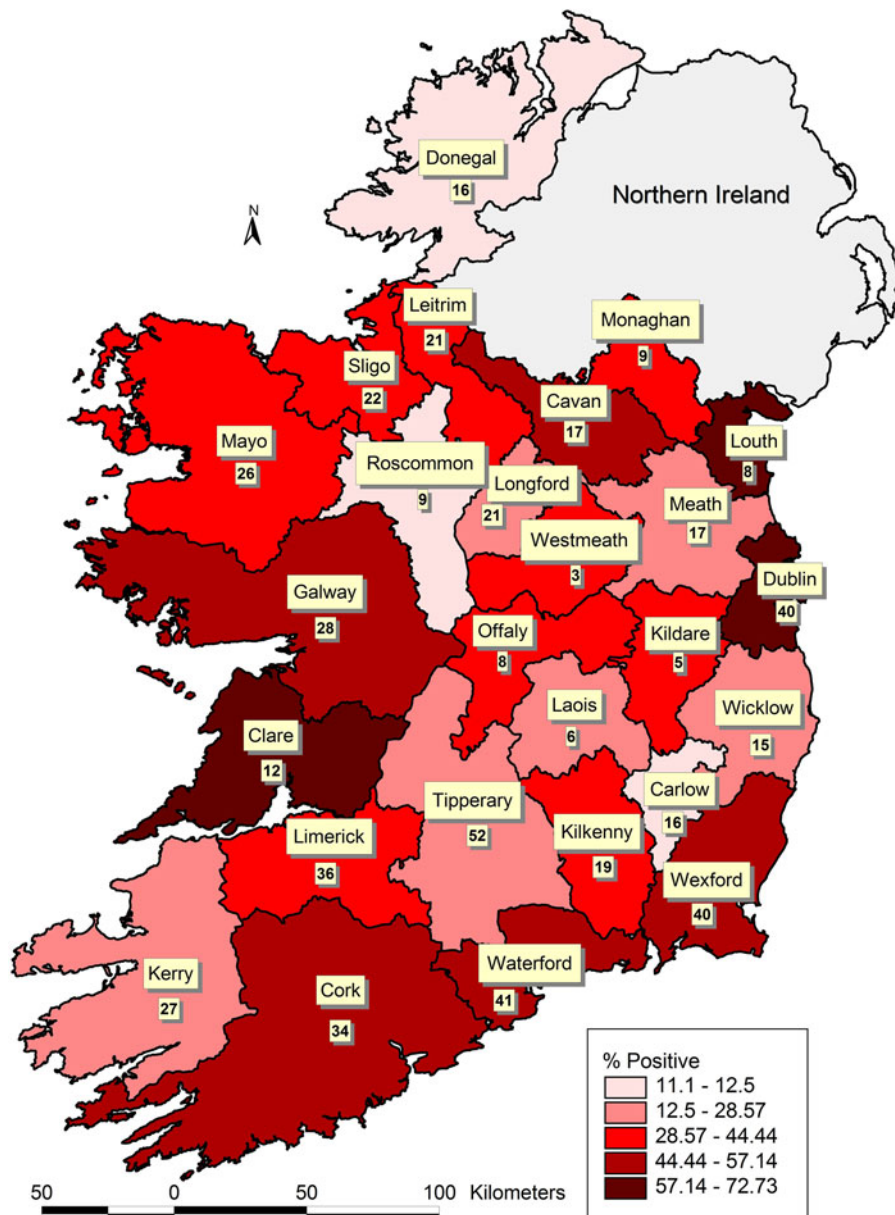


Fig. 2. Percentages of foxes positive for *Angiostrongylus vasorum* per county in the Republic of Ireland. Numbers in each county represent the total number of foxes screened in that county.

Ireland. However, our dissection method was not designed to investigate airway parasites. Therefore, our findings most likely underestimate the true prevalence of infection. Further work needs to be carried out to investigate its actual prevalence.

This high prevalence and wide distribution of *A. vasorum* in foxes in Ireland has implications for the diagnosis and treatment of infections in dogs. Case management decisions and prophylactic regimes should take into consideration the local risk and regional variation and prevalence in infected foxes. Routine screening of dogs using the commercially available canine *A. vasorum* antigen detection tests or faecal parasitology should be considered in areas which have high prevalence of infection in foxes and in any animals with suggestive clinical signs.

Much still remains to be determined about the ecology of *A. vasorum*. In particular, knowledge about intermediate and reservoir hosts and how this information relates to disease transmission and expression in dogs is of significant clinical relevance. The dynamics of infection in wild populations and factors underpinning the spill-over to domestic dogs is highly relevant and requires considerable further investigation (Elsheikha *et al.* 2014).

In conclusion, this is the first national survey of *A. vasorum* infection in the Irish fox population. It identifies a high prevalence of parasite infection in this species and highlights the exposure of the Irish dog population to serious risk of cross-infection. In addition, it confirms the presence of *C. vulpis* in Irish foxes for the first time.

ACKNOWLEDGEMENTS

The authors would like to thank the Veterinary research Officers at the Regional Veterinary Laboratories and Ursula Fogarty at the Irish Equine centre for their assistance in the collection of the fox samples.

FINANCIAL SUPPORT

This research received no specific grant from any funding agency, commercial or not-for-profit sectors.

REFERENCES

- Bolt, G., Monrad, J., Henriksen, P., Dietz, H., Koch, J., Bindseil, E. and Jensen, A.** (1992). The fox (*Vulpes vulpes*) as a reservoir for canine angiostrongylosis in Denmark. Field survey and experimental infection. *Acta Veterinaria Scandinavica* **33**, 357–363.
- Bolt, G., Monrad, J., Koch, J. and Jensen, A.** (1994). Canine angiostrongylosis: a review. *Veterinary Record* **135**, 447–452.
- Brennan, S., McCarthy, G., McAllister, H., Basset, H. and Jones, B.** (2004). Clinical signs, diagnosis and treatment of three dogs with angiostrongylosis in Ireland. *Irish Veterinary Journal* **57**, 103–109.
- Conboy, G., Hare, J., Charles, S., Steeje, T. and Heine, J.** (2009). Efficacy of a single topical application of Advantage Multi R (=Advocate R) Topical solution (10% Imidocloprid + 2.5% Moxidectin) in the treatment of dogs naturally infected with *Crenosoma vulpis*. *Parasitology Research* **105**(Suppl.), S49–S54.
- Demiaszkiewicz, A., Pyziel, A., Kuligowska, I. and Lachowicz, J.** (2014). The first report of *Angiostrongylus vasorum* (Nematoda; Metastrongyloidea) in Poland, in red foxes (*Vulpes vulpes*). *Acta Parasitologica* **59**, 758–762.
- Dodd, K.** (1973). *Angiostrongylus vasorum* (Baillet, 1866) infestation in a Greyhound Kennels. *Veterinary Record* **92**, 195–197.
- Eleni, C., Grifoni, G., Di Egidio, A., Meoli, R. and De Liberato, C.** (2014). Pathological findings of *Angiostrongylus vasorum* infection in red foxes (*Vulpes vulpes*) from Central Italy, with the first report of a disseminated infection in this host species. *Parasitology Research* **113**, 1247–1250.
- Elsheikha, H., Holmes, S., Wright, I., Morgan, E. and Lacher, D.** (2014). Recent advances in the epidemiology, clinical and diagnostic features and control of canine cardio-pulmonary angiostrongylosis. *Veterinary Research* **45**, 92–104.
- Franssen, F., Nijse, J., Cremers, H., Dam, C., Takumi, K. and van der Giessen, J.** (2014). Increase in number of helminth species from Dutch red foxes over a 35-year period. *Parasites and Vectors* **7**, 166–176.
- Gallagher, B., Brennan, S., Zarelli, M. and Mooney, C.** (2012). Geographical, clinical, clinicopathological and radiographic features of canine angiostrongylosis in Irish dogs: a retrospective study. *Irish Veterinary Journal* **65**, 5–14.
- Guilhon, J.** (1965). Transmission of *Angiostrongylus vasorum* (Baillet, 1866) to wild Canidae. *Comptes Rendus de l'Academie des Sciences (Paris) Groupe 12*. 261, 4496–4497.
- Hayden, T. and Harrington, R.** (2000). *Exploring Irish Mammals*. Town House and Country House Ltd., Dublin, Ireland.
- Helm, J., Gilleard, J., Jackson, M., Redman, E. and Bell, R.** (2009). A case of canine *Angiostrongylus vasorum* in Scotland confirmed by PCR and sequence analysis. *Journal of Small Animal Practice* **50**, 255–259.
- Helm, J., Jackson, M. and Bell, R.** (2010). Canine angiostrongylosis: an emerging disease in Europe. *Journal of Veterinary Emergency and Critical Care* **20**, 98–109.
- Hurnikova, Z., Miterpakova, M. and Mandelik, R.** (2013). First autochthonous case of canine *Angiostrongylus vasorum* in Slovakia. *Parasitology Research* **112**, 3505–3508.
- Jacobs, D. and Prole, J.** (1975). *Angiostrongylus vasorum* and other nematodes in British greyhounds. *Veterinary Record* **96**, 180.
- Jefferies, R., Shaw, S., Viney, M. and Morgan, E.** (2009). *Angiostrongylus vasorum* from South America and Europe represent distinct lineages. *Parasitology* **136**, 107–115.
- Jolly, S., Poncelot, L., Lempereur, L., Caron, Y., Bayrou, C., Cassart, D., Grimm, F. and Losson, B.** (2015). First report of a fatal autochthonous canine *Angiostrongylus vasorum* infection in Belgium. *Parasitology International* **64**, 97–99.
- Kistler, W., Brown, J., Allison, A., Nameth, N. and Yabsley, M.** (2014). First report of *Angiostrongylus vasorum* and *Hepatozoon* from a red fox (*Vulpes vulpes*) from West Virginia, USA. *Veterinary Parasitology* **200**, 216–220.
- Koch, J. and Willeesen, J.** (2009). Canine pulmonary angiostrongylosis: an update. *Veterinary Journal* **179**, 348–359.
- Levine, N.** (1980). In *Nematode Parasites of Domestic Animals and of Man*, 2nd Edn. Burgess, Minneapolis, USA.
- Magi, M., Guardone, L., Prati, M., Mignone, W. and Macchioni, E.** (2015). Extraintestinal nematodes of the red fox *Vulpes vulpes* in north-west Italy. *Journal of Helminthology* **89**, 506–511.
- Marnell, F., Kingston, N. and Looney, D.** (2009). *Ireland Red List No. 3: Terrestrial Mammals*. National Parks and Wildlife Service, Department of the Environment, Heritage and Local Government, Dublin, Ireland. <http://www.npws.ie/sites/default/files/publications/pdf/RL3.pdf>
- Martin, M. and Neal, C.** (1992). Distribution of angiostrongylosis in Cornwall. *Journal of Small Animal Practice* **33**, 327–330.
- Morgan, E. and Shaw, S.** (2010). *Angiostrongylus vasorum* infection in dogs: continuing spread and developments in diagnosis and treatment. *Journal of Small Animal Practice* **51**, 616–621.
- Morgan, E., Tomlinson, A., Hunter, S., Nichols, T., Roberts, E., Fox, M. and Taylor, M.** (2008). *Angiostrongylus vasorum* and *Eucoleus aerophilus* in foxes (*Vulpes vulpes*) in Great Britain. *Veterinary Parasitology* **154**, 48–57.
- Morgan, E., Jefferies, R., Krajewski, M., Ward, P. and Shaw, S.** (2009). Canine pulmonary angiostrongylosis: the influence of climate on parasite distribution. *Parasitology International* **58**, 406–410.
- Morgan, E., Jeffries, R., van Otterdijk, L., McEniry, R., Allen, F., Bakewell, M. and Shaw, S.** (2010). *Angiostrongylus vasorum* infection in dogs: presentation and risk factors. *Veterinary Parasitology* **173**, 255–261.
- National Biodiversity Data Centre.** (2015). <http://www.biodiversityireland.ie>
- O'Neill, E., Acke, E., Tobin, E. and McCarthy, G.** (2010). Immune-mediated thrombocytopenia associated with *Angiostrongylus vasorum* in a Jack Russell terrier. *Irish Veterinary Journal* **63**, 434–440.
- Otranto, D., Cantacessi, C., Dantas-Torres, F., Brianti, E., Pfeiffer, M., Genchi, C., Guberti, V., Capelli, G. and Deplazes, P.** (2015). The role of wild canids and felids in spreading parasites to dogs and cats in Europe. Part II: Helminths and arthropods. *Veterinary Parasitology* **213**, 24–37.
- Patterson, M., Gibbs, C., Wotton, P. and Day, M.** (1993). *Angiostrongylus vasorum* infection in seven dogs. *Veterinary Record* **133**, 565–570.
- Reilly, G., McGarry, J., Martin, M. and Belford, C.** (2000). *Crenosoma vulpis*, the fox lungworm, in a dog in Ireland. *Veterinary Record* **146**, 764–765.
- Roche, M. and Kelliher, D.** (1968). *Angiostrongylus vasorum* infestation in the dog: a case report. *Irish Veterinary Journal* **22**, 108–113.
- Santoro, M., D'Alessio, N., Di Prisco, F., Neola, B., Restucci, B., Pagano, T. and Veneziano, V.** (2015). *Angiostrongylus vasorum* infection in red foxes (*Vulpes vulpes*) in southern Italy. *Acta Parasitologica* **60**, 356–359.
- Simin, S., Kotic, L., Kuruca, L., Pavlovic, I., Savovic, M. and Lalosevic, V.** (2014). Moving the boundaries to the South-East: first record of autochthonous *Angiostrongylus vasorum* infection in a dog in Vojvodina Province, northern Serbia. *Parasites and Vectors* **7**, 396–400.
- Simpson, V.** (1996). *Angiostrongylus vasorum* infection in foxes (*Vulpes vulpes*) in Cornwall. *Veterinary Record* **139**, 443–445.
- Taylor, C., Gato, R., Learmount, J., Aziz, N., Montgomery, C., Rose, H., Couthwaite, C., McGarry, J., Forman, D., Allen, S., Wall, R. and Morgan, E.** (2015). Increased prevalence and geographic spread of the cardiopulmonary nematode *Angiostrongylus vasorum* in fox populations in Great Britain. *Parasitology* **142**, 1190–1195.
- Thrusfield, M.** (1986). *Veterinary Epidemiology*, 1st Edn. Butterworth-Heinemann, Oxford, UK.
- Tolnai, Z., Szell, Z. and Sreter, T.** (2015). Environmental determinants of the spatial distribution of *Angiostrongylus vasorum*, *Crenosoma vulpis* and *Eucoleus aerophilus* in Hungary. *Veterinary Parasitology* **207**, 355–358.
- Tonsberg, H.** (2006). Epidemiological study of snail intermediate hosts in the life cycle of *Angiostrongylus vasorum* in Denmark. MSc. thesis. Department of Small Animal Clinical Sciences, KVL, Copenhagen.
- Williams, J., Lindemann, B., Padgett, G. and Smith, O.** (1985). Angiostrongylosis in a greyhound. *Journal of the American Veterinary Medical Association* **186**, 1101–1103.
- Wolfe, A., Hogan, S., Maguire, D., Fitzpatrick, C., Vaughan, L., Wall, D., Hayden, G. and Mulcahy, G.** (2001). Red foxes in Ireland as hosts for parasites of potential zoonotic and veterinary significance. *Veterinary Record* **149**, 759–763.
- Yamakawa, Y., McGarry, J., Denk, D., Dukes-McEwan, J., Macdonald, N., Mas, A., McConnell, E., Tattou, B., Valentine, E., Williams, J. and Hetzel, U.** (2009). Emerging canine angiostrongylosis in northern England: five fatal cases. *Veterinary Record* **164**, 149–152.
- Zarelli, M., Shiel, R., Gallagher, B., Skelly, C., Calahan, S. and McAllister, H.** (2012). CT findings in a dog with intracranial haemorrhage secondary to angiostrongylosis. *Veterinary Radiology and Ultrasound* **53**, 420–423.