

positioning,  $P_{peak}$  increased to 40 cmH<sub>2</sub>O and  $ETCO_2$  increased to 45 mmHg. We could not pass a suction catheter beyond a distance of 24 cm from the entrance of the tracheal tube. Using a fibroscope, we could see the appearance of a meniscus and a crescent shape on the inner wall. Because of the prone position, we could not change the tube but managed to maintain ventilation, saturation and  $ETCO_2$  within the normal range by a change of ventilatory mode for the remaining 5 h of the procedure. After returning to the supine position at the end of the operation, we extubated the patient and her self-respiration was good. Unfortunately, we found mild left lower lobe atelectasis post-operatively, which responded to physiotherapy. Her lung condition had returned to normal without complication by the second postoperative day.

Examination of the reinforced tube showed two internal blisters, one at the entrance and one at 24 cm from the entrance. Examination using a rigid fibroscope and computed tomography (Fig. 1) showed a dissection of the inner layer of the tube. The dissection had caused longitudinal blisters of 2.8 and 4.2 cm length and reduction of the internal diameter to 3.5 and 2.9 mm at the proximal and distal parts, respectively.

We assumed that the damage of the tube was caused by faulty manufacture. However, we subsequently discovered that the cause was multiple reuse of the single-use tube. Similar complications have been reported during anaesthesia with use of N<sub>2</sub>O [2,3] or even without N<sub>2</sub>O [4], exposure of heat, ethylene oxide [4–6] and glutaraldehyde solution [6] and stretching of a reinforced endotracheal tube [6]. The tube in this case had been

cleaned after each use with hypochlorous acid (Medilox solution; Hicro-S<sup>®</sup>, Soosan GIC Co Ltd, Seoul, Korea) after ultrasonic cleansing for 30 min. We should bear in mind that repeated reuse of reinforced endotracheal tubes that are designed for single use is unwise.

Y. S. Jeon, Y. S. Kim, J. D. Joo, E. G. Kang  
J. H. In, J. W. Choi, S. M. Cho  
Department of Pain Medicine and Anesthesiology  
Saint's Vincent Hospital  
The Catholic University of Korea  
Suwon, South Korea

## References

1. Santos IA, Oliveira CA, Ferreira L. Life-threatening ventilatory obstruction due to a defective tracheal tube during spinal surgery in the prone position. *Anesthesiology* 2005; 103: 214–215.
2. Populaire C, Robard S, Souron R. An armored endotracheal tube obstruction in a child. *Can J Anaesth* 1989; 36: 331–332.
3. Kopp KH, Wehmer H. Nitrous oxide induced intraluminal tube obstruction during endotracheal intubation with armored tubes. *Anaesthesist* 1981; 30: 577–579.
4. Tose R, Kubota T, Hirota K, Sakai T, Ishihara H, Matsuki A. Obstruction of a reinforced endotracheal tube due to dissection of internal tube wall during total intravenous anaesthesia. *Masui* 2003; 52: 1218–1220.
5. Paul M, Dueck M, Kampe S, Petzke F. Failure to detect an unusual obstruction in a reinforced endotracheal tube with fiberoptic examination. *Anesth Analg* 2003; 97: 909–910.
6. Rao GS, Ali Z, Ramkiran S, Chandrasekhar HS. The dissection of a reinforced endotracheal tube causing near-fatal intraoperative airway obstruction. *Anesth Analg* 2006; 103: 1624–1625.

## Changes in renal function in valvular and coronary patients

doi: 10.1017/S0265021507001263

### EDITOR:

I read with interest the article by Landoni and colleagues [1] regarding acute renal failure and mitral valve surgery. Acute renal failure is one of the most serious complications of cardiac surgery, with high morbidity and mortality, although the subject is still not completely understood. Most of the research related to valve surgery and cardio-

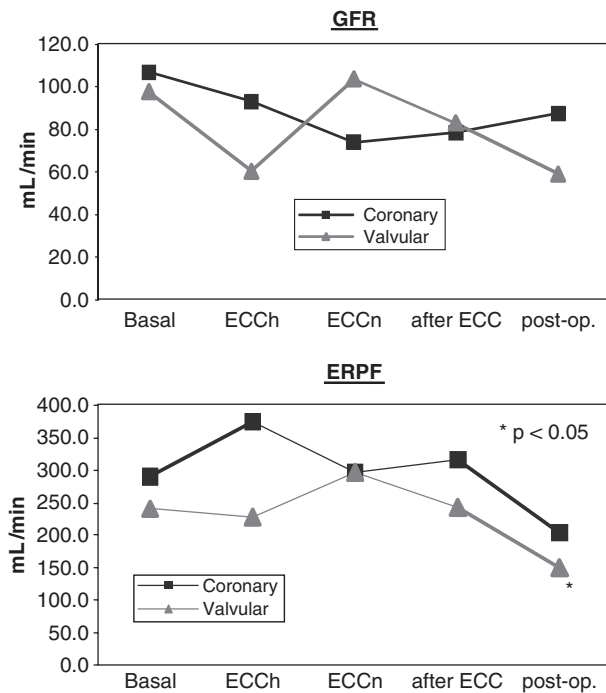
pulmonary bypass (CPB) is from the 1960s and 1970s [2,3]. The current practice of valve surgery, recent development in CPB and new postoperative strategies offers us a different situation.

Early work in valvular surgery patients stated that CPB was the main cause of renal dysfunction and acute renal failure. There are a number of papers, showing that, contrary to this belief, CPB is not the main cause of this morbidity. However, most of this work has been performed in patients undergoing coronary artery surgery [4,5].

A recent study by our group (unpublished results) [6] shows that in valvular surgery patients (mitral

Correspondence to: Guillermo Lema, Department of Anesthesiology, Pontificia Universidad Católica de Chile, Santiago, Chile. E-mail: glema@med.puc.cl; Tel: +56(2) 6863415; Fax: +56(2) 6394409

Accepted for publication 25 June 2007 EJA 4611  
First published online 2 August 2007



**Figure 1.** Renal function during cardiopulmonary bypass. GFR: glomerular filtration rate; ERPF: effective renal plasma flow; ECC: extracorporeal circulation; b: hypothermia; n: normothermia; post-op: postoperative.

and aortic valve), the pattern of renal function during CPB, studied with inulin infusion for glomerular filtration rate (GFR) and  $I^{131}$  Hipuran for effective renal plasma flow (ERPF) is well preserved and no differences were found when compared with our own earlier studies in coronary patients [4,5] (Fig. 1). To our knowledge, that was the first such study in valvular surgery patients. GFR and ERPF were well preserved throughout, but ERPF was reduced before surgery. Similar results have been found in others types of surgery [7].

We agree with Landoni and colleagues that the risk for renal dysfunction and acute renal failure depends on many other factors: fasting, hypovolaemia, low cardiac output, emergencies, bleeding and preoperative renal dysfunction. Perioperative factors other than CPB should be considered the main reasons for acute renal failure in patients undergoing coronary and valvular surgery.

G. Lema, W. Merino, C. Salinas  
Department of Anesthesiology  
Pontificia Universidad Católica de Chile  
Santiago, Chile

## References

1. Landoni G, Roberti A, Boroli F *et al.* Mitral valve surgery and acute failure. *Eur J Anaesthesiol* 2006; 24: 100–101.
2. Porter GA, Kloster FE, Herr RJ *et al.* Renal complications associated with valve replacement surgery. *J Thorac Cardiovasc Surg* 1967; 53: 145–152.
3. Porter GA, Kloster FE, Herr RJ *et al.* Relationship between alterations in renal hemodynamics during cardiopulmonary bypass and postoperative renal function. *Circulation* 1966; 34: 1005–1021.
4. Lema G, Meneses G, Urzua J *et al.* Effects of extracorporeal circulation on renal function in coronary surgical patients. *Anesth Analg* 1995; 81: 446–451.
5. Lema G, Urzúa J, Jalil R *et al.* Renal protection in patients undergoing cardiopulmonary bypass with preoperative abnormal renal function. *Anesth Analg* 1998; 86: 3–8.
6. Lema G, Canessa R, Carvajal C *et al.* Renal function in valvular and coronary patients undergoing surgery with extracorporeal circulation. Abstract. 29th Annual Meeting & Workshops, Society of Cardiovascular Anesthesiologist, Montreal, Canada, 2007.
7. Colson P, Ribstein J, Seguin JR *et al.* Mechanisms of renal hemodynamic impairment during infrarenal aortic cross-clamping. *Anesth Analg* 1993; 76(2): 458–460.

## Effect of dexmedetomidine on blood pressure and bleeding in maxillo-facial surgery

doi: 10.1017/S0265021507001081

### EDITOR:

We read with great interest the study report by Durmus and colleagues [1] concerning the effect of

dexmedetomidine on bleeding during tympanoplasty or septorhinoplasty. The authors showed that, compared to placebo, dexmedetomidine decreased intraoperative mean arterial pressure (MAP), heart rate (HR) and bleeding in the surgical field.

In a similar prospective study, we have assessed the efficacy of dexmedetomidine in achieving controlled hypotension during maxillofacial surgery [2]. Twenty consecutive ASA I patients undergoing

Correspondence to: Freda Richa, Anesthesia and Intensive Care Department, Hotel-Dieu de France Hospital, Alfred Naccache Street, Ashrafieh, 166830 Beirut, Lebanon. E-mails: fredrich24@yahoo.com and fredrich8@hotmail.com; Tel: +961 3 872077; Fax: +961 1 615295

Accepted for publication 25 May 2007 EJA 4592  
First published online 1 August 2007