



Case Report

Personalized high-definition transcranial direct current stimulation improves cognition following carbon monoxide poisoning induced amnesia: A case report

Brett S Schneider^{1,2,3} , Melvin McInnis³, Victor Di Rita² and Benjamin M Hampstead^{1,2,3} 

¹Mental Health Service, VA Ann Arbor Healthcare System, Ann Arbor, MI, USA, ²Research Program on Cognition and Neuromodulation Based Interventions, Department of Psychiatry, University of Michigan, Ann Arbor, MI, USA and ³Department of Psychiatry, University of Michigan, Ann Arbor, MI, USA

Abstract

Objective: High-definition transcranial direct current stimulation (HD-tDCS) has the potential to improve cognitive functioning following neurological injury and in neurodegenerative conditions. In this case report, we present the first use of HD-tDCS in a person with severe anterograde amnesia following carbon monoxide poisoning. **Method:** The participant underwent two rounds of HD-tDCS that were separated by 3 months (Round 1 = 30 sessions; Round 2 = 31 sessions). We used finite element modeling of the participant's structural MRI to develop an individualized montage that targeted multiple brain regions involved in memory encoding, as identified by Neurosynth. **Results:** Overall, the participant's objective cognitive functioning improved significantly following Round 1, declined during the 2 months without HD-tDCS, and again improved following Round 2. Subjective informant reports from family and medical personnel followed this same pattern of improvement following each round with a decline in between rounds. We also provide preliminary evidence of altered brain activity during a learning/memory task using functional near-infrared spectroscopy, which may help establish the physiological effects of HD-tDCS in future work. **Conclusion:** Overall, these findings reinforce the potential value of HD-tDCS as a user-friendly method of enhancing cognition following anoxic/hypoxic brain injury.

Keywords: Transcranial direct current stimulation; memory training; spectroscopy; electric stimulation; near-infrared; brain plasticity

(Received 29 January 2024; final revision 20 May 2024; accepted 17 June 2024; First Published online 3 December 2024)

Introduction

In this case report, we describe the application of high-definition transcranial direct current stimulation (HD-tDCS) to treat a case of dense anterograde amnesia following carbon monoxide (CO) poisoning. CO poisoning causes anoxic brain damage due to CO's high affinity to bind with hemoglobin and formation of carboxyhemoglobin, calcium influx toxicity, perfusion and reperfusion injuries, apoptosis, and other cellular processes within neural tissue (Hopkins & Bigler, 2012; Weaver, 2009). Areas of the brain with high metabolic demand due to their dense concentrations of neurons (e.g., hippocampus, basal ganglia, and thalamus) are particularly vulnerable to CO poisoning, in addition to cerebral white matter (Allen et al., 2006; Hopkins & Bigler, 2012; Wolstenholme & Moore, 2010). Cognitive and affective sequelae occur in up to 46% of individuals in the acute phase following CO poisoning and 25–50% beyond 1 month after injury (Anderson & Arciniegas, 2010; Weaver, 2009). A meta-analysis found CO poisoning leads to acute difficulties in attention, processing speed, and forming new memories, which generally improved 6 weeks after injury (Watt et al., 2018). However, in rare cases, CO poisoning leads to irreversible dense anterograde amnesia

(Allen et al., 2006; Craver et al., 2014; Di Paola et al., 2008; Wright et al., 2017).

tDCS

Transcranial direct current stimulation (tDCS) is a form of noninvasive neuromodulation that passes a weak electrical current, traditionally 1–2 milliamperes (mA), between scalp-based electrodes to modulate the excitability of the underlying neural tissue. Preliminary evidence suggests tDCS can improve cognitive abilities following age-related declines (Indahlastari et al., 2021), stroke (Elsner et al., 2020; Yan et al., 2020), and neurodegenerative conditions (Hampstead et al., 2017; Rahman-Filipiak et al., 2019). We used high definition (HD-) tDCS in the current case study, as prior evidence suggests HD-tDCS enhances stimulation focality (Datta et al., 2009) and induces more robust and longer-lasting physiological effects compared to traditional tDCS (Kuo et al., 2013). We previously reported subjective and objective cognitive improvement following HD-tDCS in a patient with post-anoxic leukoencephalopathy (Garcia & Hampstead, 2022), a group-level normalization of network segregation in patients with mild cognitive impairment (Jordan et al., 2022), as well as enhanced

Corresponding author: Benjamin M Hampstead; Email: bhampste@med.umich.edu

Cite this article: Schneider B.S., McInnis M., Di Rita V., & Hampstead B.M. (2024) Personalized high-definition transcranial direct current stimulation improves cognition following carbon monoxide poisoning induced amnesia: A case report. *Journal of the International Neuropsychological Society*, 30: 1015–1021, <https://doi.org/10.1017/S1355617724000304>

© Department of Veterans Affairs, 2024. This is a work of the US Government and is not subject to copyright protection within the United States. Published by Cambridge University Press on behalf of International Neuropsychological Society.

regional GABA in older adults following HD-tDCS (Lengu et al., 2021).

The current case study (PT60) was referred to our Research Program after suffering dense anterograde amnesia following severe CO poisoning resulting from a suicide attempt, to improve learning and memory. We predicted that stimulating areas involved in memory and encoding (e.g., left fronto-parietal network) would improve performance on associated objective neuropsychological measures of learning and memory. Herein, we discuss multiple methodological advancements in HD-tDCS administration that hold promise for future neurorehabilitative efforts. First, we developed a personalized montage optimized to stimulate the left fronto-parietal network memory using the patient's structural MRI. Then, we used an internally developed process to 3D-print headgear that ensured accurate, rapid electrode placement. Our research staff then trained PT60's spouse to deliver HD-tDCS at home (under supervision via HIPPA-compliant video conference). We used an A-B-A design to evaluate the cognitive effects of 61 total HD-tDCS sessions, completed in two separate Rounds over six months. The HD-tDCS montage delivered 6 milliamps (mA) total (two anodes at 3 mA each) over key nodes of the fronto-parietal cortex involved in memory encoding. We then acquired and integrated a user-friendly measure of brain activation (functional near-infrared spectroscopy – fNIRS) to assess the neurophysiological effects of stimulation during Round 2, predicting HD-tDCS would increase blood oxygenation in the targeted areas during memory encoding.

Case study history

PT60 was a 55-year-old, right-handed, White, non-Hispanic male with 16 years of education and a history of Bipolar I disorder (onset age 18), with multiple periods of prolonged mania followed by severe depression. The patient had two prior suicide attempts and a polysubstance history including alcohol, benzodiazepine, and marijuana abuse, though he was reportedly sober for 1.5 years before the CO injury. His medications at the time of enrollment included daily Vraylar 1.5 mg, Wellbutrin 300 mg, and Lithium 1200 mg.

CO injury

PT60 attempted suicide via prolonged CO exposure (poisoning) approximately six months before study enrollment. The duration of exposure was unknown, but he was unresponsive upon hospital presentation (Glasgow Coma Scale = 3) and subsequently intubated with 100% oxygen. Accompanying laboratory testing revealed elevated carboxyhemoglobin (30%; > 25% requires immediate medical attention; Weaver, 2009) and severe hypoglycemia (glucose = 27mg/dL; hypoglycemia defined as < 50 mg/dL; Zoungas et al., 2010). A head CT revealed mild cerebral edema and an MRI conducted 10 days later revealed medial temporal lobe hyperintensities, which the radiologist determined was concerning for potential limbic encephalopathy (Figure 1). PT60 was extubated three days after hospital admission. Medical records during his initial hospitalization describe profound anterograde amnesia and marked retrograde amnesia persisting at least several months before the injury. He underwent neuropsychological evaluation three weeks after the injury that revealed severe deficits in learning, delayed memory, and executive functioning (Supplementary Table ST1). He was treated with 20 sessions of hyperbaric oxygen treatment two months post-injury, though

records indicate his marked anterograde amnesia persisted following treatment.

Methods

HD-tDCS methods

All methods and data collection were approved by the University of Michigan Medical School Institutional Review Board and performed following the Declaration of Helsinki. PT60 and their spouse provided written and verbal consent to publish this case report. Given the primary presenting complaints of anterograde learning/memory deficits, we attempted to identify participant-specific brain regions engaged during memory encoding using functional magnetic resonance imaging (fMRI). Unfortunately, the participant was unable to tolerate the MRI environment, though PT60 and his spouse did provide consent to use his clinical T1 MRI for this intervention. The clinical T1-weighted image was acquired using a 1.5-T GE scanner with repetition time (TR) = 744 ms, echo time (TE) = 10 ms, slice thickness = 4 mm, matrix size = 512 × 512 × 34, and voxel dimensions of 0.45 × 0.45 × 5.00 mm³. We used SynthSR to enhance the resolution of the clinical T1 to increase modeling precision given the decreased quality of the image compared to the high-quality T1 images normally collected in our Research Program (Iglesias et al., 2023), which changed the matrix size to 230 × 230 × 171 with voxel dimensions of 1 × 1 × 1 mm³. We then used Neurosynth (Yarkoni et al., 2011) to identify brain regions associated with memory encoding; the resulting activation map primarily identified regions of the left fronto-parietal network (i.e., the inferior frontal gyrus (IFG) and superior parietal cortex (SPL); Figure 2B). After identifying these regions, we used PT60's clinical T1 scan to model the electric field using finite element modeling via the ROAST software (Huang et al., 2019). The resulting montage based on the 10-5 electrode map (Oostenveld & Praamstra, 2001) included anodes at F7 and CPP1 (each delivering 3 milliamps (mA)) and eight Cathodes at AFp7, F3, F9, FTT7, CCP1h, CCP3h, P5, and POz (each collecting 0.75 mA). This montage resulted in an average electric field of 0.28 V/m in the IFG and 0.24 V/m in the SPL (Figure 2B). We selected 3mA per anode given the prior evidence in motor physiology of improved response to tDCS using 3mA for 20 minutes (Farnad et al., 2021). We then used our patented 3D-print headgear (Figure 2C) that allows for rapid and reliable electrode placement (headgear is now available from Soterix Medical Inc.).

Figure 3 provides a timeline of HD-tDCS procedures. We trained PT60's spouse during the first five sessions in our laboratory using our standardized methods to ensure that she could consistently and accurately place the headgear and electrodes (procedural manuscript *in progress*). PT60's spouse also completed a questionnaire assessing her confidence in performing HD-tDCS. The questionnaire consisted of 7 items, rated using an anchored Likert scale (0 = not at all confident; 10 = extremely confident), including confidence in using the stimulation equipment, placing electrodes, caring for the equipment, and using videoconferencing during the virtual sessions. After a single training session, PT60's spouse reported feeling extremely confident (10) on 6 of the 7 items, while rating a "9" when asked about her confidence placing the headgear. She rated all items as "10" following the fifth training session. We also measured the deviation between PT60's electrode placement and research staff during training sessions. The average deviation across electrodes after the first session was 1.81 mm and 1.45 mm after the 5th training session.

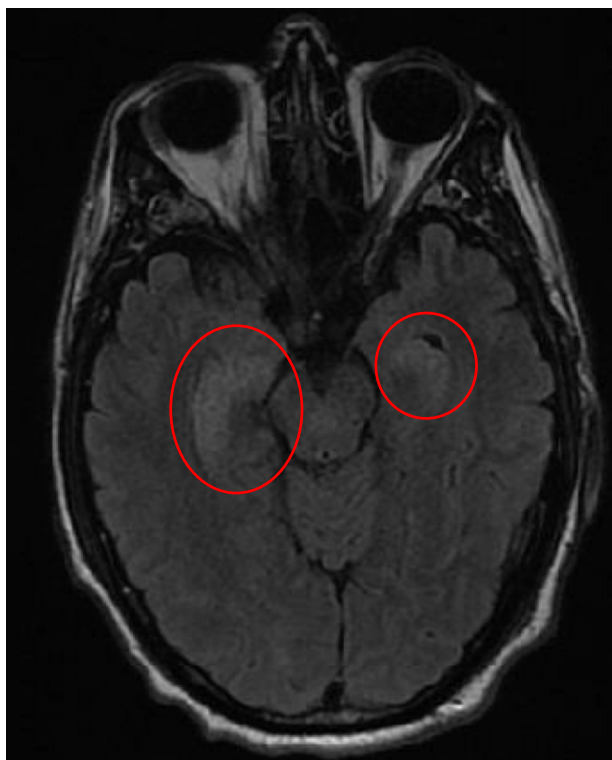


Figure 1. Brain T2 FLAIR image captured 10 days after the carbon monoxide injury showing hyperintensity and evidence of limbic encephalopathy (circled in red).

The couple then returned home and performed the remainder of the sessions remotely. For each remote session, the spouse joined a HIPAA-compliant videoconference to allow study staff supervision of the HD-tDCS session. Under staff monitoring, PT60's spouse placed the headgear, filled the electrode holders with gel, placed the electrodes, and tested impedances following our previously described methods (Hampstead et al., 2020). Sessions 6–30 of Round 1 and sessions 1–31 of Round 2 were all conducted at home under video supervision. PT60's spouse specifically requested Round 2 after reporting significant memory improvements during Round 1 that diminished after stimulation was discontinued. The participant received 3–5 HD-tDCS sessions each week. Stimulation was 20 minutes with a 30-second ramp up and ramp down, delivered using a Soterix Medical Inc. tES duo 4 x 1 unit. During stimulation, PT60 completed a face name encoding task designed to engage task-relevant brain areas and “shape” the effects of tDCS (i.e., functional targeting; Bikson & Rahman, 2013). The participant completed a tolerability questionnaire (Reckow et al., 2018) before and after each HD-tDCS session and returned to our office for all evaluations (Figure 3).

Cognitive, mood, and functional measures

We used the Repeatable Battery for the Assessment of Neuropsychological Status (RBANS; Randolph, 1998) as the primary cognitive assessment since this measure was available from the initial clinical evaluation. Other tasks were included in an exploratory manner (Supplementary Table ST1). Significant changes in RBANS Index performance between each time point and its preceding time point were determined by calculating a reliable change index (RCI). We defined a significant change as an RCI value > 1.64 calculated while accounting for practices effects

(Iverson, 2001) and based on a 90% confidence interval (Duff, 2012).

fNIRS analysis

We acquired two NIRx NIRSport2 continuous wave fNIRS units before Round 2, which we used to evaluate neurophysiological change following HD-tDCS. Our fNIRS full-head montage consisted of 112 channels across 32 sources and 31 detectors. Our units used dual-tipped optodes and included 8 short-separation channels which were each fixed at 8 mm. During Pre- and Post-Round 2 fNIRS sessions, we measured the hemodynamic response to two ecologically valid memory block design tasks, the Face Name task (FN; Hampstead et al., 2011) and an adapted version of the Object Location Association task (OLA; Hampstead et al., 2011). Each run consisted of 6 active blocks (3 showing novel stimuli and 3 showing repeated stimuli), that contained five 5-second trials separated by a 5-second inter-stimulus interval. Each OLA trial included a 1-second object-only phase immediately followed by a 4-second object-location phase. For FN, each trial displayed a unique face and its associated name for 5 s. An active control condition involved 2 stimuli (either OLA or FN as appropriate) that were alternated throughout each block (referred to hereafter as repeated stimuli). The order of active blocks was initially randomized within each paradigm (i.e., OLA or FN), and then held constant. Each block was separated by a 20-second rest. Pre-Round 2 fNIRS was completed before the first session of Round 2 and Post-Round 2 was completed 24 hours after the final tDCS session.

fNIRS data were processed and analyzed with the Brain AnalyzIR toolbox (Santosa et al., 2018). First, raw intensity data ($F_s = 3.18$ Hz) were converted to optical density (OD). We then applied the temporal derivative distribution repair algorithm (Fishburn et al., 2019) to remove motion artifacts from the OD data. Corrected OD data were converted to oxy- and deoxyhemoglobin using a modified Beer-Lambert law with a partial pathlength of 0.1. To account for the unique statistical properties of fNIRS data (Huppert, 2016), we used the autoregressive iteratively reweighted least squares (AR-IRLS) algorithm to solve the general linear model. AR-IRLS automatically accounts for serially correlated errors that arise from physiological noise and motion artifacts and uses robust weighted regression to iteratively down-weight outliers, including those caused by motion artifacts (Barker et al., 2013). Here we used a canonical HRF basis set, which has been shown to outperform other basis sets (e.g., Gamma function, FIR) for tasks at or above 10 s in length (Santosa et al., 2019). Given the preliminary nature and uniqueness of these data, we examined the differences between beta coefficients from the Pre and Post-tDCS sessions as a measure of effect size rather than fixed p-values. To improve statistical power in detecting changes in response to HD-tDCS stimulation, we combined the memory encoding trials of both OLA and FN into one analysis. We first contrasted the novel and repeat conditions (Novel $>$ Repeat) to identify activation associated with novel memory encoding. We then compared this contrast between the two sessions (Post $>$ Pre).

Results

Safety and tolerability

There were no safety concerns or adverse events. The participant experienced tingling (54% of sessions - mostly mild) and burning

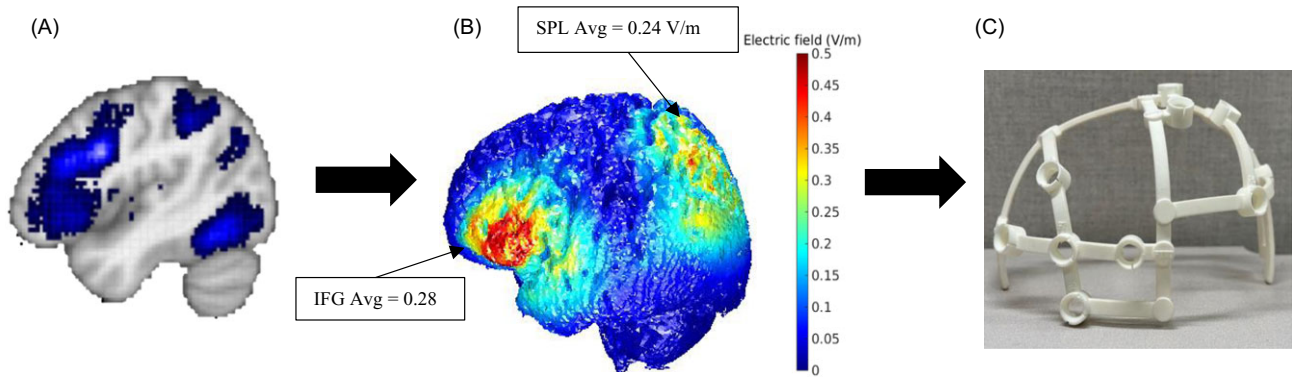


Figure 2. A) Activation map derived from Neurosynth from keywords “memory encoding.” B) ROAST finite element modeling of the montage using PT60’s anatomical scan targeting the regions derived from Neurosynth and the level of delivered current at the inferior frontal gyrus and superior parietal lobule. C) 3D-printed headgear of the selected montage customized for PT60.

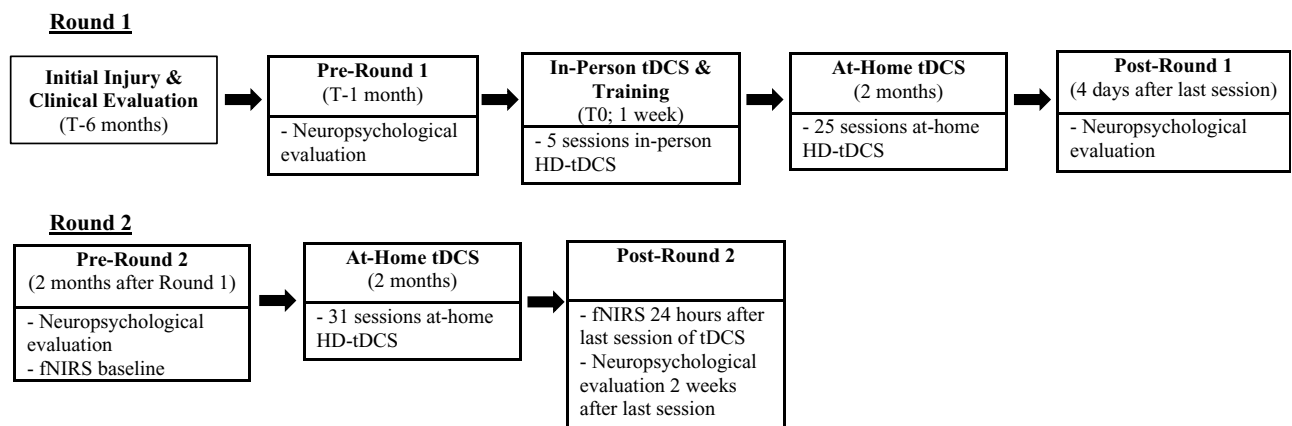


Figure 3. Intervention timeline over one year from initial injury to post-round 2 evaluation.

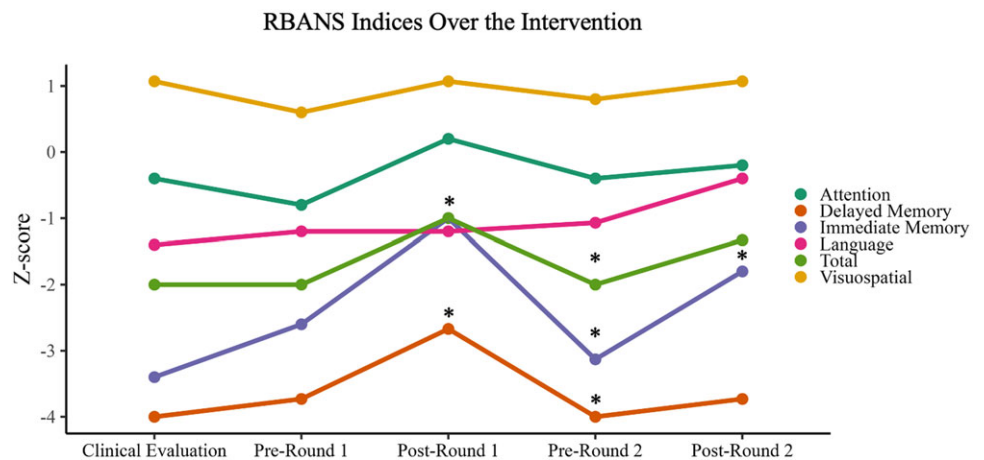


Figure 4. *Indicates a clinically significant reliable change for each Repeatable Battery for the Assessment of Neuropsychological Status index from the preceding timepoint (reliable change index > 1.64).

sensations (11% of sessions - mostly moderate) and skin redness (mostly mild) was observed for 34% of the sessions.

Cognitive changes

Reliable change indices (Table 1) revealed no significant change across RBANS indices in the five months between the clinical

evaluation to Pre-Round 1 (Figure 4). In contrast, PT60 significantly improved on the Immediate Memory Index (RCI = 2.4) and Delayed Memory Index (RCI = 1.69) following Round 1. Moreover, performances on Immediate Memory (RCI = -3.08), Delayed Memory (RCI = -2.28), and Total (RCI = -1.69) Indices significantly declined over the 8 weeks between Round 1 and Round 2. Following the second round of

Table 1. Reliable change index (RCI) between each time point

RBANS Index	Clinical eval– pre-round 1	Pre-round 1– post-round 1	Post-round 1– pre-round 2	Pre-round 2– post-round 2
Attention	−0.69	1.15	−0.95	0.1
Visuospatial	−1.61	−0.39	−0.46	−0.65
Language	0.5	0	0.58	1.15
Immediate memory	1.13	2.4	−3.08	1.97
Delayed memory	0.23	1.69	−2.67	0.23
Total	0	1.45	−1.69	0.8

Reliable change indices between each assessment. Bold values indicate significant change as defined by >1.64 RCI value falling outside the 90% confidence interval accounting for practice effects (Iverson, 2001).

stimulation, Immediate Memory once again significantly improved (RCI = 1.97) and no significant changes across the other RBANS Indices (Table 1).

Qualitative data

Research staff recorded comments from PT60 and his spouse during each Round of stimulation. During Round 1, PT60's spouse and psychiatrist observed improvements throughout the intervention. The participant showed more engagement in activities and improved recall of recent events during the third week (after the 13th session) such that he appeared to track and retain information better throughout the remainder of the Round. He also spontaneously expressed persistent familiarity with, and recalling details about, the research staff and study tasks following the 26th session. In the two months between Round 1 and Round 2, PT60's spouse observed significant cognitive decline and requested Round 2. During Round 2, PT60 again spontaneously reported greater familiarity with the research tasks and further personal details of the study team between sessions. His spouse and psychiatrist again reported improved memory day-to-day during Round 2.

fNIRS changes after round 2

We examined the raw unstandardized beta weights comparing activation during memory encoding (Novel > Repeat) comparing Post relative to Pre-Round 2 (Post > Pre) combining the FN and OLA tasks to measure network engagement agnostic to stimulus type (Figure 5). Compared to Pre-Round 2, the bilateral inferior frontal gyrus, left superior temporal, and right supramarginal areas showed increased activation. We also observed mild decreases in oxygenated blood (HbO) within the bilateral occipital and inferior parietal regions.

Discussion

This case is the first to demonstrate that HD-tDCS over regions of the left fronto-parietal network enhanced learning and possibly memory in a person with chronic, dense, anterograde amnesia following CO poisoning. Our current A-B-A design and neurophysiological change following Round 2 strongly suggest that HD-tDCS was responsible for the observed changes in both objective and subjective cognitive functioning. Memory encoding improved significantly following both Round 1 and Round 2, while other cognitive processes (e.g., language, visuospatial ability, processing speed) remained stable across all evaluations. We also demonstrated significant improvements in delayed memory performance following Round 1 but not Round 2. The specificity of this improvement supports our brain network approach

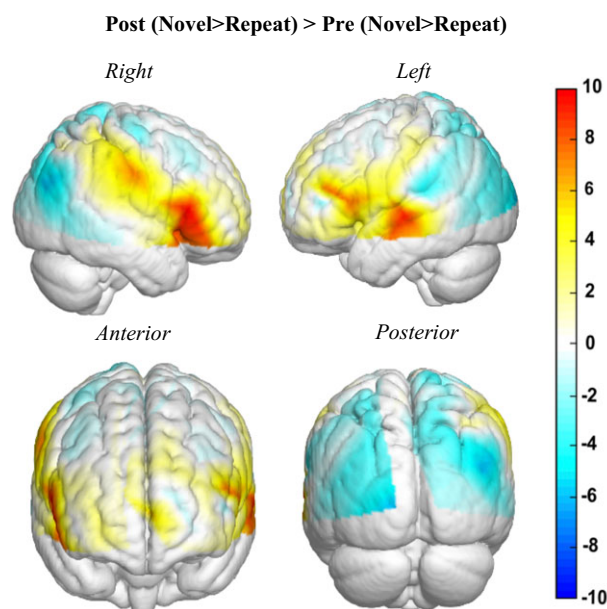


Figure 5. Raw beta values of memory activity relationships with memory encoding, combined for both Face Name and Object Location Touchscreen Test (OLTT).

informed by Neurosynth (Figure 2A) and prior fMRI evidence demonstrating left front-parietal involvement in memory encoding (Hampstead et al., 2011; Hampstead et al., 2016; Kim, 2019). Moreover, the altered patterns of fNIRS activation following Round 2 provide physiological evidence that HD-tDCS drove the observed effects. Our findings are especially meaningful given the lack of current treatments for chronic cognitive deficits following CO poisoning. Hyperbaric oxygen has been proposed as beneficial for cognition, though prior studies have cast doubt on its effectiveness in treating chronic cognitive deficits (Buckley et al., 2011; Chenoweth et al., 2021; Rose et al., 2017). While PT60 underwent 20 sessions of hyperbaric oxygen treatment before enrolling in our study, the lack of cognitive change relative to baseline (i.e., Pre-Round 1 vs. the clinical evaluation) suggests that hyperbaric treatment had little impact on PT60's cognitive functioning. Of course, we cannot rule out a synergistic or sequential effect of hyperbaric oxygen and HD-tDCS but suggest such possibilities be evaluated in future studies.

The observed changes in fNIRS-based brain activity following Round 2 are especially intriguing and add to our prior reports of fMRI-related change after HD-tDCS (Hampstead et al., 2017; Jordan et al., 2022), including in a patient with post-anoxic leukoencephalopathy (Garcia & Hampstead, 2022). Our findings are well aligned with a systematic review of studies examining

changes in blood oxygenation using fNIRS that showed stimulated areas have increased HbO measured more than 24 hours after tDCS (Patel et al., 2020), similar to the effect of tDCS on BOLD signal in fMRI (Esmailpour et al., 2020). The pattern of change in our case is intriguing since we found task-related increases in HbO at one site of stimulation (left IFG) as well as other brain regions involved in memory encoding (left superior temporal, right inferior frontal, and right supramarginal); regions that were also evident in the Neurosynth derived map. These results may suggest a network-level effect from unilateral stimulation, recruiting contralateral brain regions involved in memory encoding, particularly the right inferior frontal gyrus (Figure 5). Our prior work has demonstrated increased engagement of task-relevant brain networks following HD-tDCS using fMRI in a case report (Garcia & Hampstead, 2022) and neurodegenerative populations (Jordan et al., 2022). The reason for the observed decrease in HbO at the second stimulation site (left SPL) and other bilateral “posterior” regions is less clear. We cannot rule out the possibility that these regions were initially up-regulated in a compensatory manner and hence down-regulated by increased prefrontal engagement (as reflected by the increased frontal HbO). Given the case study nature of this report, we encourage additional studies of both local and whole-brain HD-tDCS effects.

Our study provides several notable methodological advances that may ultimately advance the clinical translation of neuro-modulation approaches like HD-tDCS. First, we administered remote HD-tDCS loosely following methods reported in prior studies of pad-based tDCS (Charvet et al., 2020; Eilam-Stock et al., 2021; Piloni et al., 2022). We developed HD-tDCS specific training methods and associated criteria to address the unique needs of HD-tDCS. Finite element modeling allowed us to create multi-electrode montages that increase the focality of stimulation compared to pad-based methods (Alam et al., 2016) and allowed us to shape current delivery for this specific participant. Performing finite element modeling before stimulation informed our decision to use a higher per anode (i.e., 3 mA) and total electrical current (i.e., 6 mA) than prior studies to increase the dosage of current at the brain level and increase the likelihood of inducing neuroplastic change (Stagg et al., 2018). The use of personalized headgear enabled our staff to train PT60’s spouse to successfully administer HD-tDCS, using a complex montage, in their home under video-conference supervision. These advancements improve the precision, reliability, and feasibility of HD-tDCS for future clinical use and supporting long-term home treatment.

Limitations

The clinical presentation of PT60 and rare injury provided a unique opportunity to examine the effects of HD-tDCS. While these initial findings are promising, this personalized HD-tDCS approach will have to demonstrate consistent benefits compared to easier, one-size-fits-all approaches to justify widespread implementation. Additionally, the benefits in cognition were not sustained between Round 1 and Round 2, which suggests ongoing stimulation is needed to sustain effects (we note that this is no different than many other interventions, including medication effects such as those for high blood pressure).

Conclusions

This case report demonstrates the potential of personalized, network-based neuromodulation for treating severe learning

and, potentially, memory impairment following CO poisoning. Our on-off-on findings suggest the need to identify optimal treatment parameters to maintain the positive benefits. We suspect that user-friendly neuroimaging methods like fNIRS may be helpful in this regard as booster sessions could be timed to coincide with declines in HbO. Our methods may also facilitate personalized, ongoing, remote treatment, though we encourage the replication and extension of our preliminary findings.

Supplementary material. The supplementary material for this article can be found at <https://doi.org/10.1017/S1355617724000304>.

Acknowledgements. We gratefully acknowledge the efforts of PT60 and their family.

Funding statement. This work was supported by funding awarded to BMH by the National Institute of Aging (NIA R35AG072262), and by support from the Heinz C Prechter Bipolar Research Program (MGM).

Competing interests. MGM has received research support and consultant fees from Janssen Pharmaceuticals. BMH and the University of Michigan and Department of Veterans Affairs hold a patent for the headgear, which has been licensed to Soterix Medical, Inc. and that may ultimately provide royalty payments.

References

- Alam, M., Truong, D. Q., Khadka, N., & Bikson, M. (2016). Spatial and polarity precision of concentric high-definition transcranial direct current stimulation (HD-tDCS). *Physics in Medicine and Biology*, *61*(12), 4506–4521.
- Allen, J. S., Tranel, D., Bruss, J., & Damasio, H. (2006). Correlations between regional brain volumes and memory performance in anoxia. *Journal of Clinical and Experimental Neuropsychology*, *28*(4), 457–476.
- Anderson, C. A., & Arciniegas, D. B. (2010). Cognitive sequelae of hypoxic-ischemic brain injury: A review. *NeuroRehabilitation*, *26*(1), 47–63.
- Barker, J. W., Aarabi, A., & Huppert, T. J. (2013). Autoregressive model based algorithm for correcting motion and serially correlated errors in fNIRS. *Biomedical Optics Express*, *4*(8), 1366–00–1379.
- Bikson, M., & Rahman, A. (2013). Origins of specificity during tDCS: Anatomical, activity-selective, and input-bias mechanisms. *Frontiers in Human Neuroscience*, *7*, 688.
- Buckley, N. A., Juurlink, D. N., Isbister, G., Bennett, M. H., Lavonas, E. J., Cochrane Injuries Group (2011). Hyperbaric oxygen for carbon monoxide poisoning. *Cochrane Database of Systematic Reviews*, *2011*(4), CD002041.
- Charvet, L. E., Shaw, M. T., Bikson, M., Woods, A. J., & Knotkova, H. (2020). Supervised transcranial direct current stimulation (tDCS) at home: A guide for clinical research and practice. *Brain Stimulation*, *13*(3), 686–693.
- Chenoweth, J. A., Albertson, T. E., & Greer, M. R. (2021). Carbon monoxide poisoning. *Critical Care Clinics*, *37*(3), 657–672.
- Craver, C. F., Graham, B., & Rosenbaum, R. S. (2014). Remembering mr B. *Cortex*, *59*, 153–184.
- Datta, A., Bansal, V., Diaz, J., Patel, J., Reato, D., & Bikson, M. (2009). Gyri-precise head model of transcranial direct current stimulation: Improved spatial focality using a ring electrode versus conventional rectangular pad. *Brain Stimulation*, *2*(4), 201–207.e1.
- Di Paola, M., Caltagirone, C., Fadda, L., Sabatini, U., Serra, L., Carlesimo, G. A. (2008). Hippocampal atrophy is the critical brain change in patients with hypoxic amnesia. *Hippocampus*, *18*(7), 719–728.
- Duff, K. (2012). Evidence-based indicators of neuropsychological change in the individual patient: Relevant concepts and methods. *Archives of Clinical Neuropsychology*, *27*(3), 248–261.
- Eilam-Stock, T., George, A., & Charvet, L. E. (2021). Cognitive telerehabilitation with transcranial direct current stimulation improves cognitive and emotional functioning following a traumatic brain injury: A case study. *Archives of Clinical Neuropsychology*, *36*(3), 442–453.

- Elsner, B., Kugler, J., & Mehrholz, J. (2020). Transcranial direct current stimulation (tDCS) for improving aphasia after stroke: A systematic review with network meta-analysis of randomized controlled trials. *Journal of NeuroEngineering and Rehabilitation*, 17(1), 88.
- Esmailpour, Z., Shereen, A. D., Ghobadi-Azbari, P., Datta, A., Woods, A. J., Ironside, M., O'Shea, J., Kirk, U., Bikson, M., & Ekhtiari, H. (2020). Methodology for tDCS integration with fMRI. *Human Brain Mapping*, 41(7), 1950–1967.
- Farnad, L., Ghasemian-Shirvan, E., Mosayebi-Samani, M., Kuo, M.-F., & Nitsche, M. A. (2021). Exploring and optimizing the neuroplastic effects of anodal transcranial direct current stimulation over the primary motor cortex of older humans. *Brain Stimulation*, 14(3), 622–634.
- Fishburn, F. A., Ludlum, R. S., Vaidya, C. J., & Medvedev, A. V. (2019). Temporal derivative distribution repair (TDDR): A motion correction method for fNIRS. *NeuroImage*, 184, 171–179.
- Garcia, S., & Hampstead, B. M. (2022). HD-tDCS as a neurorehabilitation technique for a case of post-anoxic leukoencephalopathy. *Neuropsychological Rehabilitation*, 32(6), 946–966.
- Hampstead, B. M., Ehmann, M., & Rahman-Filipiak, A. (2020). Reliable use of silver chloride HD-tDCS electrodes. *Brain Stimulation: Basic, Translational, and Clinical Research in Neuromodulation*, 13(4), 1005–1007.
- Hampstead, B. M., Sathian, K., Bikson, M., & Stringer, A. Y. (2017). Combined mnemonic strategy training and high-definition transcranial direct current stimulation for memory deficits in mild cognitive impairment. *Alzheimer's & Dementia: Translational Research & Clinical Interventions*, 3(3), 459–470.
- Hampstead, B. M., Stringer, A. Y., Stilla, R. F., Amaraneni, A., & Sathian, K. (2011). Where did I put that? Patients with amnesic mild cognitive impairment demonstrate widespread reductions in activity during the encoding of ecologically relevant object-location associations. *Neuropsychologia*, 49(9), 2349–2361.
- Hampstead, B. M., Stringer, A. Y., Stilla, R. F., Deshpande, G., Hu, X., Moore, A. B., & Sathian, K. (2011). Activation and effective connectivity changes following explicit-memory training for face-name pairs in patients with mild cognitive impairment: A pilot study. *Neurorehabilitation and Neural Repair*, 25(3), 210–222.
- Hampstead, B. M., Khoshnoodi, M., Yan, W., Deshpande, G., & Sathian, K. (2016). Patterns of effective connectivity during memory encoding and retrieval differ between patients with mild cognitive impairment and healthy older adults. *NeuroImage*, 124, 997–1008.
- Hopkins, R. O., & Bigler, E. D. (2012). Neuroimaging of anoxic injury: Implications for neurorehabilitation. *NeuroRehabilitation*, 31(3), 319–329.
- Huang, Y., Datta, A., Bikson, M., & Parra, L. C. (2019). Realistic volumetric approach to simulate transcranial electric stimulation—ROAST—a fully automated open-source pipeline. *Journal of Neural Engineering*, 16(5), 056006.
- Huppert, T. J. (2016). Commentary on the statistical properties of noise and its implication on general linear models in functional near-infrared spectroscopy. *Neurophotonics*, 3(1), 010401-0–10401.
- Iglesias, J. E., Billot, B., Balbastre, Y. B. I., Magdamo, C., Arnold, S. E., Das, S., Edlow, B. L., Alexander, D. C., Golland, P., & Fischl, B. (2023). SynthSR: A public AI tool to turn heterogeneous clinical brain scans into high-resolution T1-weighted images for 3D morphometry. *Science Advances*, 9(5), eadd3607.
- Indahlstari, A., Hardcastle, C., Albizu, A., Alvarez-Alvarado, S., Boutzoukas, E. M., Evangelista, N. D., Woods, A. J., & (2021). A systematic review and meta-analysis of transcranial direct current stimulation to remediate age-related cognitive decline in healthy older adults. *Neuropsychiatric Disease and Treatment Volume*, 17, 971–990.
- Jordan, A. D., Ryan, S., Tyszkowski, T., Peltier, S. J., Rahman-Filipiak, A., & Hampstead, B. M. (2022). High-definition transcranial direct current stimulation enhances network segregation during spatial navigation in mild cognitive impairment. *Cerebral Cortex*, 32(22), 5230–5241.
- Iverson, G. L. (2001). *Interpreting change on the WAIS-III/WMS-III in clinical samples*. Archives of Clinical Neuropsychology.
- Kim, H. (2019). Neural activity during working memory encoding, maintenance, and retrieval: A network-based model and meta-analysis. *Human Brain Mapping*, 40(17), 4912–4933.
- Kuo, H.-I., Bikson, M., Datta, A., Minhas, P., Paulus, W., Kuo, M.-F., & Nitsche, M. A. (2013). Comparing cortical plasticity induced by conventional and high-definition 4 × 1 ring tDCS: A neurophysiological study. *Brain Stimulation*, 6(4), 644–648.
- Lengu, K., Ryan, S., Peltier, S. J., Tyszkowski, T., Kairys, A., Giordani, B., Hampstead, B. M., & Hornberger, M. (2021). Effects of HD-tDCS on local GABA and glutamate levels among older adults with and without mild cognitive impairment: An exploratory study. *Journal of Alzheimer's Disease*, 84(3), 1091–1102.
- Oostenveld, R., & Praamstra, P. (2001). The five percent electrode system for high-resolution EEG and ERP measurements. *Clinical Neurophysiology*, 112(4), 713–719.
- Patel, R., Dawidziuk, A., Darzi, A., Singh, H., & Leff, D. R. (2020). Systematic review of combined functional near-infrared spectroscopy and transcranial direct-current stimulation studies. *Neurophotonics*, 7(02), 1.
- Pilloni, G., Vogel-Eyny, A., Lustberg, M., Best, P., Malik, M., Walton-Masters, L., George, A., Mirza, I., Zhovtis, L., Datta, A., Bikson, M., Krupp, L., & Charvet, L. (2022). Tolerability and feasibility of at-home remotely supervised transcranial direct current stimulation (RS-tDCS): Single-center evidence from 6,779 sessions. *Brain Stimulation*, 15(3), 707–716.
- Rahman-Filipiak, A., Reckow, J. M., Woods, A. J., Nitsche, M. A., & Hampstead, B. M. (2019). The use and efficacy of transcranial direct current stimulation in individuals with neurodegenerative dementias. In Nitsche, M. A., Bikson, M., Knotkova, H., Woods, A. J. (Eds.), *Practical Guide to Transcranial Direct Current Stimulation* (pp. 473–507). Springer.
- Randolph, C. (1998). *Repeatable Battery for the Assessment of Neuropsychological Status (RBANS)*. Psychological Corporation.
- Reckow, J., Rahman-Filipiak, A., Garcia, S., Schlaeflin, S., Calhoun, O., DaSilva, A. F., Bikson, M., & Hampstead, B. M. (2018). Tolerability and blinding of 4x1 high-definition transcranial direct current stimulation (HD-tDCS) at two and three milliamps. *Brain Stimulation*, 11(5), 991–997.
- Rose, J. J., Wang, L., Xu, Q., McTiernan, C. F., Shiva, S., Tejero, J., & Gladwin, M. T. (2017). Carbon monoxide poisoning: Pathogenesis, management, and future directions of therapy. *American Journal of Respiratory and Critical Care Medicine*, 195(5), 596–606.
- Santosa, H., Fishburn, F., Zhai, X., & Huppert, T. J. (2019). Investigation of the sensitivity-specificity of canonical- and deconvolution-based linear models in evoked functional near-infrared spectroscopy. *Neurophotonics*, 6(2), 025009.
- Santosa, H., Zhai, X., Fishburn, F., & Huppert, T. (2018). The NIRS brain analyzIR toolbox. *Algorithms*, 11(5), 73.
- Stagg, C. J., Antal, A., & Nitsche, M. A. (2018). Physiology of transcranial direct current stimulation. *The Journal of ECT*, 34(3), 144–152.
- Watt, S., Prado, C. E., & Crowe, S. F. (2018). Immediate and delayed neuropsychological effects of carbon monoxide poisoning: A meta-analysis. *Journal of the International Neuropsychological Society*, 24(4), 405–415.
- Weaver, L. K. (2009). Carbon monoxide poisoning. *New England Journal of Medicine*, 360(12), 1217–1225.
- Wolstenholme, N., & Moore, B. (2010). The clinical manifestations of anoxic brain injury. *Progress in Neurology and Psychiatry*, 14(4), 8–13.
- Wright, K. L., Kirwan, C. B., Gale, S. D., Levan, A. J., & Hopkins, R. O. (2017). Long-term cognitive and neuroanatomical stability in patients with anoxic amnesia: A case report. *Brain Injury*, 31(5), 709–716.
- Yan, R., Zhang, X., Li, Y., Hou, J., Chen, H., & Liu, H. (2020). Effect of transcranial direct-current stimulation on cognitive function in stroke patients: A systematic review and meta-analysis. *PLOS ONE*, 15(6), e0233903.
- Yarkoni, T., Poldrack, R. A., Nichols, T. E., Van Essen, D. C., & Wager, T. D. (2011). Large-scale automated synthesis of human functional neuroimaging data. *Nature Methods*, 8(8), 665–670.
- Zoungas, S., Patel, A., Chalmers, J., de Galan, B. E., Li, Q., Billot, L., Woodward, M., Ninomiya, T., Neal, B., MacMahon, S., Grobbee, D. E., Kengne, A. P., Marre, M., & Heller, S. (2010). Severe hypoglycemia and risks of vascular events and death. *New England Journal of Medicine*, 363(15), 1410–1418.