

Original Article

Cite this article: Kurup HKN, Gopalakrishnan A, Sasikumar D, and Krishnamoorthy KM (2023) Safety of drug-eluting stents for stenting patent arterial duct in neonates. *Cardiology in the Young* **33**: 437–443. doi: [10.1017/S104795112200110X](https://doi.org/10.1017/S104795112200110X)





Received: 24 May 2021
Revised: 9 March 2022
Accepted: 14 March 2022
First published online: 5 May 2022

Keywords:

PDA Stenting; neonates; safety; ductal stenting

Author for correspondence:

Dr Arun Gopalakrishnan, DM, Associate Professor, Department of Cardiology, Sree Chitra Tirunal Institute for Medical Sciences and Technology, Thiruvananthapuram, Kerala 695011, India.
E-mail: arungopalakrishnan99@gmail.com

Harikrishnan K.N. Kurup , Arun Gopalakrishnan , Deepa Sasikumar  and Kavassery M. Krishnamoorthy 

Department of Cardiology, Sree Chitra Tirunal Institute for Medical Sciences and Technology, Thiruvananthapuram, Kerala 695011, India

Abstract

Objectives: The primary objective was to evaluate the trend of blood sirolimus concentrations in neonates following ductal stenting. The long-term outcomes and incidence of infections were also evaluated. **Methods:** Prospective open-label observational study in a tertiary referral centre over a 1-year period. Serum sirolimus levels were estimated at 1 hour and 24hrs post-stent insertion followed by 7 days in neonates who underwent ductal stenting. The trend in sirolimus levels, incidence of infections, complications and outcomes following ductal stenting were studied. **Results:** Seven neonates with duct-dependent pulmonary circulation underwent ductal stenting at median age of 8.5 days and weight of 2.83kg. The average stent size was 3.5 ± 0.4 mm, and average stent length was 16.3 ± 5.1 mm. The mean sirolimus concentrations at 1 hour, 24 hours and 7 days were 41.3 ± 6.9 ng/ml, 15.4 ± 7.1 ng/ml and 3.1 ± 0.85 ng/ml respectively. Levels fell below therapeutic range for all patients by 7 days. Three patients had sepsis or necrotising enterocolitis, but responded well to antibiotics; 1 patient had aspiration related sudden death. There were no further events at a mean follow-up of 207 days, and 4 patients underwent elective surgery at 238 ± 81 days after ductal stenting. **Conclusions:** This study demonstrates applicability of drug-eluting stents for ductal stenting in newborns. Drug-eluting stents with abluminal drug delivery are associated with high sirolimus levels in initial hours but rapidly taper to negligible levels within a week of implantation. Neonates with high pre-procedure likelihood of infection developed sepsis but responded well to conservative management. The patency of drug-eluting ductal stents is preserved over long-term follow-up.

Neonates with certain complex CHDs are dependent on the patent arterial duct for blood flow to their systemic circulation or the pulmonary vascular bed. Blalock–Taussig shunt for palliation of cyanotic babies has revolutionised the management of these sick subset of patients. However, a lot of adverse effects are noted following Blalock–Taussig shunt including early shunt thrombosis, chylothorax, diaphragmatic paralysis, and distortion and stenosis of branch pulmonary arteries in the long term. The mortality following neonatal Blalock–Taussig shunt is as high as 7.2% with a composite morbidity of 13.1% according to STS data.^{1,2}

Multiple meta-analyses have documented the benefits of ductal stenting compared to Blalock–Taussig shunt in duct-dependent pulmonary circulation, although reintervention rates are higher.^{3–6} Stenting of patent arterial duct was conventionally performed using bare-metal stents. Bare-metal stents of the sizes needed for ductal stenting have slowly gone out of market because of the established advantages of drug-eluting stents in coronary artery disease. Hence, drug-eluting stents are being evaluated for ductal stenting although the drug levels eluted, and their effects have been primarily tested only in adult population. The rapamycin group of drugs used in drug-eluting stents have immunosuppressive actions. It has been shown to attain toxic blood levels in neonatal population although with no clinically relevant adverse effects.⁷

Since the rates of neonatal infections and sepsis are higher in the developing world, it is important to characterise the safety, drug levels attained, and consequences of immunosuppression due to systemic drug levels. The primary objective of the study was to evaluate the trend of blood sirolimus concentrations in neonates following ductal stenting. The immediate and long-term outcomes of ductal stenting and the incidence of infections were also evaluated.

Methodology

This was a prospective open-label observational study done in a tertiary referral centre, a university-level hospital from January 2020 to February 2021. The study was cleared by the Technical Advisory Committee and the Institute Ethics Committee of the institute. Neonates with duct-dependent pulmonary circulation and planned for ductal stenting were discussed at a Joint Cardiac Conference before catheterisation. Written informed consent for use of a sirolimus drug-eluting stent was obtained from parents. Consent for a protocol of serial

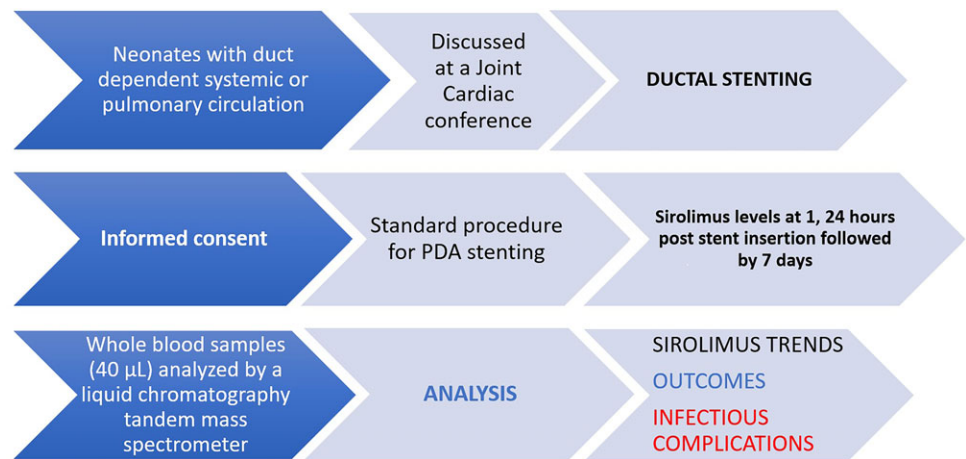


Figure 1. Represents the flow chart of the study methodology.

sirolimus measurements coordinated with routine blood samples taken for other clinical reasons was also signed by parents. Standard procedure for ductal stenting according to the Institute protocol was followed.

The usual procedure of ductal stenting involved use of stents of 3–4 mm diameter (3 mm for weight < 2.5 kg, 3.5 mm for weight 2.5–3.5 kg and 4 mm for weight > 3.5 kg), the sirolimus dose being dependent on the stent length.⁸ Drug-eluting stents have a drug-free polymer layer applied on top of the drug-polymer matrix as a diffusion barrier to prolong the release of the drug with 50% of the sirolimus eluted over the 1st week, 80% over 30 days, and 100% over 90 days.⁷ The Abluminus stent (Concept Medical, Florida, USA) was used in six patients, and one of the neonates received a Yukon Choice PC (Translumina, Hechingen, Germany) stent. The sirolimus concentration is 0.7 µg/mm² and 1.80 µg/mm² in Abluminus and Yukon Choice PC stents, respectively. All the patients were on regular dual antiplatelet therapy with 3mg/kg/day of aspirin and 0.5–1 mg/kg/day of clopidogrel.

Blood sampling for sirolimus levels was coordinated with sampling for other clinical reasons and drawn at 1 hour, 24 hours post-stent insertion followed by every 7 days until the sirolimus level was below the limit of quantification (<2.27 µg/mL) where feasible (Fig 1). Sirolimus levels from whole blood samples (40 µL) of patients were analysed by a liquid chromatography tandem mass spectrometer. Complete blood counts, liver and renal function were also assessed at 24 hours and repeated if abnormal.

All consecutive neonates with an indication for ductal stenting (duct-dependent pulmonary circulation) were considered for inclusion in the study. Those who were not willing to participate in the study were excluded.

Data collection and analysis

The data on the cardiac diagnoses, procedural aspects of the ductal stent implantation, and any other subsequent catheter or surgically based cardiac interventions were collected. The clinical outcomes, including procedural complications, and ductal stent patency on follow-up determined by echocardiography were studied. Drug concentrations were measured as described, and the participants were on periodic follow-up twice weekly for the 1st month after discharge and then monthly till next surgery. A minimum follow-up of 1 month was ensured for the last recruited patient before data analysis. Specific aspects on follow-up included weight gain, incidence of major/minor infections, oxygen saturation, patency

of the stent, growth of the pulmonary arteries, and any further interventions.

Data were collected based on the predesigned pro forma, and data entry was done in Microsoft Excel 2013 (Microsoft, Redmond, WA, USA). The statistical analysis was performed on SPSS software version 26 (IBM Corp. 2012, IBM SPSS Statistics for Windows, Version 26.0, Armonk, NY, USA). The baseline categorical variables were summarised as frequency (percentage), and continuous variables were summarised as mean (SD) or median (range). Line diagrams were used to represent the drug concentration of each patient and the growth in size of individual pulmonary arteries. Spearman's correlation analysis was used to test the correlation between drug content of the stent and serum Sirolimus levels.

Results

A total of 7 patients were enrolled during the study period. There were 5 males and 2 female neonates who underwent ductal stenting and were followed up for a median 204 (12 – 360) days. The median age at the time of ductal stenting was 8.5 (3 – 30) days with an average weight of 2.83 ± 0.1 kg. All the patients underwent ductal stenting for duct-dependent pulmonary circulation. The various anatomic diagnosis with duct dependency and the outcomes of the patients are depicted in Table 1. All except two neonates had usual atrial arrangement, and one of them had dextrocardia. Four neonates had pulmonary atresia, and two of them had severe pulmonary stenosis; the first patient required ductal stenting because of non-confluent pulmonary arteries, and the left pulmonary artery was arising from the patent arterial duct. The aortic arch was right-sided in two neonates. Two children were taken up for the procedure with pre-existing sepsis. There was one early and one late mortality.

Procedural characteristics

The average stent size used was 3.5 ± 0.4 mm, and the average length of stent used was 16.3 ± 5.1 mm. Two patients required multiple stents as the aortic end was uncovered following the first stent deployment. The Abluminus stent (Concept Medical, Florida, USA) was used in six patients, and one of the neonates received a Yukon Choice PC (Translumina, Hechingen, Germany) stent. The details of the procedure are summarised in Table 1.

Table 1. Characteristics of patients who underwent stent implantation, procedural and stent details and serum sirolimus levels

Neonate	Age (days)	Weight (kg)	Diagnosis	Stent size (mm)	Stent length: mm	Sirolimus eluted (mcg)	Sirolimus levels ng/ml		
							1 hour	24 hours	7 days
1	4	2.8	Left isomerism, double outlet right ventricle, VSD, non-confluent PAs	3	12	25.2	38.84	Sample not taken	<2.27
2 [#]	4	2.8	Congenitally corrected TGA, VSD, Pulmonary atresia, confluent PAs	3.5 3.5	16 8	58.8	>49.6	13.78	3.8
3	30	2.9	TOF, critical PS, confluent PAs, with recurrent spells, large canal crossing RVOT	3.5	12	29.4	42.38	15.3	3.3
4	3	2.7	VSD, pulmonary atresia, confluent PAs	3.5	18	113.4	33.84	9.38	3.28
5	7	2.8	D-TGA, VSD, severe PS, restrictive ASD	3.5	20	49.0	>49.6	29.0	3.92
6	20	3	Unbalanced atrioventricular canal defect, RV dominant, left isomerism, pulmonary atresia, confluent PAs, interrupted IVC	4 3.5	12 20*	33.6	36.8	12.4	<2.27
7	4	2.8	VSD, pulmonary atresia, confluent PAs	3.5	16	39.2	38	16.8	3.8

Abbreviations: VSD-Ventricular septal defect, PA-Pulmonary artery, PDA-Patent ductus arteriosus, LPA-Left pulmonary artery, TGA-Transposition of great arteries, TOF-Tetralogy of Fallot, PS-Pulmonary stenosis, IVC-Inferior caval vein, ASD-Atrial septal defect.

[#]2 stents used; *2nd stent was everolimus-eluting stent.

Characteristics post-ductal stenting and sirolimus level trends

The mean oxygen saturations increased from a mean of 69.5% to 84.3% following ductal stenting with drug-eluting stent. The mean hospital stay was 6 ± 4.2 days. Prolonged admission up to 2 weeks was required in neonate 4 for treatment of sepsis. This baby received the Yukon Choice PC stent and had the highest quantum of Sirolimus eluted upon ductal stenting in the cohort.

The serum sirolimus levels were documented at 1 hour, 24 hours, and 7 days post-procedure. Since none of the patients had levels >4 ng/ml at 7 days (below therapeutic concentration in transplant recipients), a repeat sampling at 1 month was not performed. Table 1 shows the sirolimus levels for individual patients, and Figure 2 represents the trends in sirolimus levels.

The mean sirolimus concentrations at 1 hour, 24 hours, and 7 days post-procedure were 41.3 ± 6.93 ng/ml, 15.4 ± 7.1 ng/ml, and 3.1 ± 0.85 ng/ml, respectively. Two patients had undetectable sirolimus levels at 7 days, and both had a 12-mm stent implanted. Sirolimus level less than 4 ng/ml is considered less than therapeutic range for immunosuppression. The amount of sirolimus eluted depended on the length of the stent implanted. The mean drug amount eluted was 49.8 ± 32.1 μ g. The mean drug elution by Abluminus stents was 39.2 ± 14.2 μ g. The serum drug levels at 1 hour and 24 hours did not show statistical correlation with the mean drug eluted. The values on the 7th day showed a low correlation to the drug eluted (Spearman coefficient 0.445).

Follow-up data

Follow-up data were available in all patients recruited for the study. The average saturation at a median follow-up of 204 days was $78.8 \pm 5.4\%$. The patient no.3 had an uneventful post-procedure period and was discharged on dual antiplatelets. However, the child had aspiration of feeds and sudden unresponsiveness 6 days after discharge with deepening cyanosis, and the baby succumbed on the way to hospital. An autopsy could not be performed. Out of the five neonates on regular follow-up, parents of two patients did not report any complaints, while there was worsening cyanosis in

two patients and respiratory distress in one of them. All the infants had appropriate development for age. Echo performed on follow-up showed patent stent in all the five neonates, with good growth of both branch pulmonary arteries (Supplemental figure).

None of the patients had significant branch pulmonary artery stenosis after ductal stenting. The z scores of the right and left pulmonary artery sizes improved from -0.75 ± 0.67 and -1.34 ± 1.60 , respectively, prior to ductal stenting to 0.07 ± 0.74 and -0.05 ± 0.96 at latest follow-up. All the patients had good compliance to dual antiplatelets without any bleeding complications. Patient no. 1 with left isomerism and non-confluent pulmonary arteries developed complete heart block and developed stent occlusion perioperatively and had a stormy course and expired. Two patients underwent bidirectional Glenn shunt on follow-up with left pulmonary artery plasty, one underwent intracardiac repair, and remaining 2 patients were planned for definitive repair/ bidirectional Glenn shunt on follow-up (Table 2).

Discussion

This study demonstrates that serum sirolimus levels are high on the day of stent implantation in newborns after ductal stenting and rapidly taper thereafter. The early mortality in this small study was 14% but offered excellent growth of the pulmonary arteries on follow-up suggesting its applicability for ductal stenting in newborns. Sirolimus-eluting stents may have clinical advantages over bare-metal stents in the extremely proliferative environment of the neonatal arterial duct. However, sirolimus has immunosuppressive actions and little is known regarding sirolimus pharmacokinetics in the newborn. Lee et al reported pharmacokinetics of sirolimus in neonates after sirolimus-eluting stent implantation where peak sirolimus levels were 20 times higher and clearance rates 30 times lower than previously reported in older children and adults.⁷ Sirolimus levels were within the immunosuppressive range for a prolonged period. The levels were >5 μ g/L (trough level used in transplant recipients) for a variable time (mean 8.4 to 15.9 days) depending on the total dose of sirolimus in the implanted stents. They did not note any clinically significant adverse outcomes

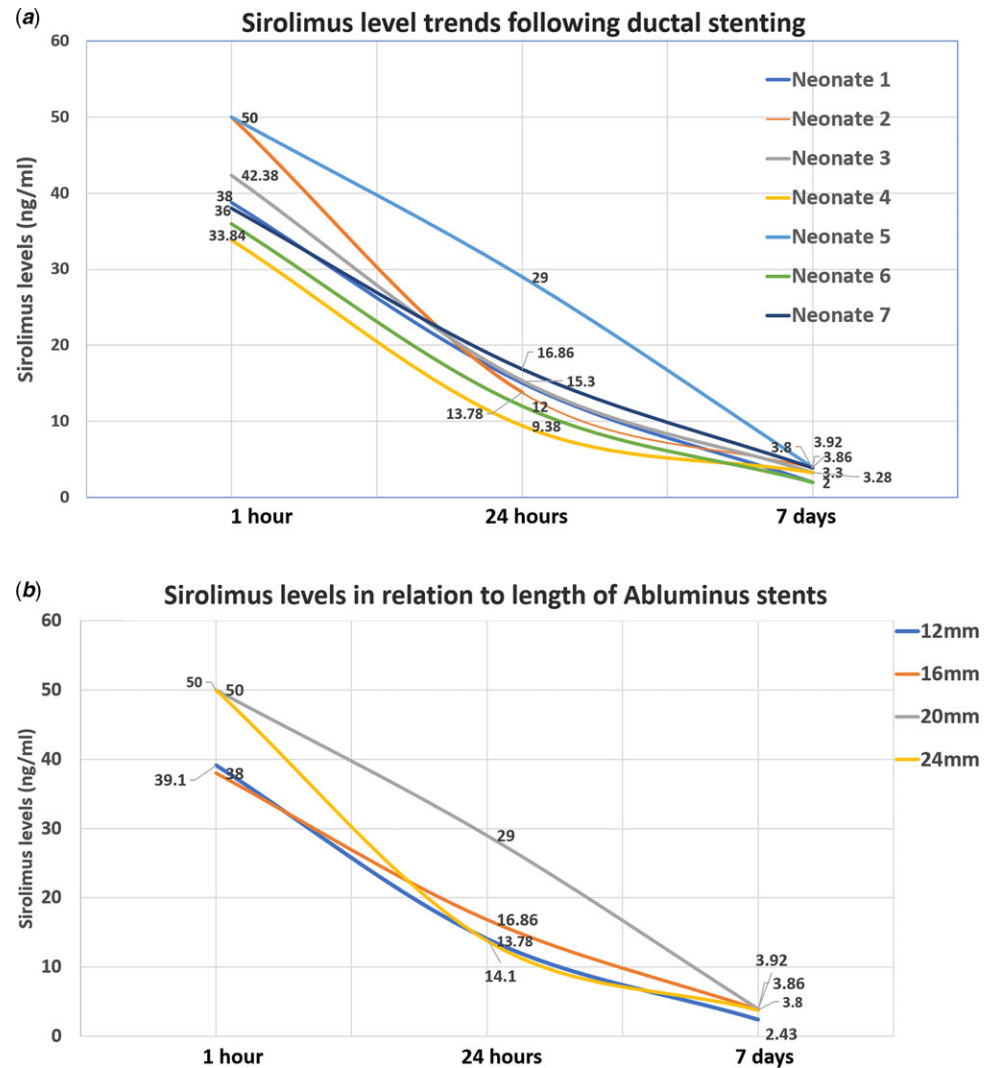


Figure 2. Panel 2A is the graphical representation of serum sirolimus levels in individual patients taken at 1 hour, 24 hours, and 7 days post-ductal stenting. Panel 2B is the graphical representation of serum sirolimus levels at 1 hour, 24 hours, and 7 days post-ductal stenting in stents of various lengths (all Abluminus stents).

although immunosuppression was prolonged. Another study reported the serum sirolimus levels attained in 12 neonates following ductal stenting using a third-generation cobalt chromium drug-eluting stent.⁹ Their cohort involved 11 neonates with duct-dependent pulmonary circulation and one with pulmonary atresia and rhabdomyoma. The sirolimus levels were less than 5 ng/ml in patients who received a single stent or even two stents where the total length was less than 22 mm. However, immunosuppressive levels were documented in neonates with stent length > 22 mm which decreased to acceptable levels by 7th day of implantation.

This study demonstrates the applicability of drug-eluting stents in newborns weighing less than 3kg. The average age of our cohort was 11.3 days, and the mean weight was 2.8 kg, as compared to 3kg and 3.2 kg in the other series.^{7,9}

Bare-metal stents are not readily available in our country which limits their application for interventions. It has been established that drug-eluting stents fare much better than bare-metal stents in terms of long-term patency/ luminal loss. Drug coating in drug-eluting stents may be conformal or abluminal. The former inhibits smooth cell proliferation over the entire surface of the stent. Abluminal drug coating is a technological improvement which helps controlled release of the drug onto the surface in

contact with the vessel wall. This reduces drug dose and polymer exposure. Abluminal stents were developed for use in coronary artery disease primarily for the concept that they reduce thrombogenicity due to lower polymer content while having a minimal effect on endothelial cell strut coverage. Prior studies have demonstrated delivery of sirolimus to the coronary artery in a controlled way with abluminal drug delivery.^{10,11} The stent preserved a safe and effective local drug concentration without significant toxicity. Sirolimus-eluting stents have been used for reopening occluded Blalock–Taussig shunts in infants.¹² There are no studies on the use of abluminal drug-eluting stents in the paediatric population. Abluminal stent systems with reduced total Sirolimus content and a drug-free luminal surface offer a conceptual advantage for choice of drug-eluting stents in newborns. This is the first study to explore the concept.

The stent sizes and length of the stent are comparable to the earlier drug-eluting stent studies for ductal stenting. There are certain characteristics of the stent which is unique in the present study. We had implanted Abluminus stent in six out of seven patients. This stent and similar stents with abluminal drug delivery facilitate drug release only into the abluminal surface where their action is needed most to prevent neointimal proliferation and thus decrease the systemic exposure of drug. This is relevant in the

Table 2. Complications following ductal stenting and long-term outcomes

Neonate	Complications	Outcome	Follow-up(days)
1	Suspect NEC, anaemia	Patent stent; CHB, planned BDG and pacemaker implantation, developed stent occlusion perioperatively, underwent redilatation of stent, stormy course, expired at 1year	360
2	Nil	Patent stent, underwent BDG	320
3	Sepsis	Sudden death after 6 days of discharge	12
4	Sepsis, NEC, Acute kidney injury	Patent stent	296
		Good PA growth	
		Underwent Intracardiac repair	
5	Nil	Patent stent	204
		Planned for BDG	
6	Nil	Patent stent	200
		Underwent BDG	
7	Nil	Patent stent, planned for ICR	60

Abbreviations: CHB-Complete heart block, BDG-Bidirectional Glenn, NEC-Necrotising enterocolitis, ICR-Intracardiac repair, PA-Pulmonary artery.

population studied because the drug is originally designed for adult coronary arteries, and hence, the concentration of drug attained in neonates is high. It was seen that the drug levels attained depended on the original level of sirolimus eluted per stent which in turn depends on the length of the stent (Fig 2B). While abluminal drug delivery systems offer directional drug release and reduced systemic drug exposure, the amount of drug eluted still depends on the nature of the coating and the polymer. Both Abluminus and Yukon Choice PC stents are abluminal systems, but with marked difference in the drug concentrations ($0.7 \mu\text{g}/\text{mm}^2$ versus $1.80 \mu\text{g}/\text{mm}^2$). The Abluminus stent has a cobalt chromium alloy platform with strut thickness of $73 \mu\text{m}$, while Yukon Choice PC has a stainless steel platform with strut thickness $87 \mu\text{m}$. The study by Sivakumar et al on 12 neonates used BioMime stent (Meril Life Sciences, Gujarat, India) which contains sirolimus at a dosage of $1.25 \mu\text{g}$ per square millimetre of stent surface area and elutes the drug luminally too.⁹ Studies involving larger number of patients with head-to-head comparison of abluminal and conformal drug-eluting stents are required to clarify the comparative drug levels after ductal stenting in newborns.

Sirolimus levels are considered to be therapeutic (for immunosuppression in renal transplant recipients) when the levels are 4 to 20 ng/ml as estimated by tandem mass spectrometry.¹³ All of our patients had sirolimus levels reaching more than 33 ng/ml immediately post-stenting. Two of our patients with longer stents had sirolimus concentrations which were above the upper limit of detection ($>49.7 \text{ ng/ml}$). Lee et al documented a biphasic release of sirolimus in the first 12 hours in 4 subjects. We did not observe this phenomenon in any patient. In fact, there was more than 30% fall in sirolimus levels in all 6 patients by 24 hours. It is possible that this phenomenon is missed because of the 24-hour period between our first 2 samples. Lee et al attributed this phenomenon to biphasic sirolimus elution or an enterohepatic recirculation.⁷ After absorption in the intestine, sirolimus undergoes extensive metabolism by CYP3A family of enzymes in the liver and enterocytes before being secreted back into the intestinal lumen by p-glycoprotein efflux pump. The metabolism of sirolimus in neonates varies from adults because of the predominant hydroxylation pathway

compared to O-methylation in adults. Newborns have decreased clearance of the drug because of the immaturity of neonatal liver.

Our study demonstrated that sirolimus levels remain much above the recommended therapeutic range immediately and remain in the immunosuppressive concentrations at 24 hours after stent implantation. The levels at 24 hours documented in our study are much higher than that noted by Sivakumar et al. They have not evaluated sirolimus concentrations at 1 hour. However, the median sirolimus level at 24 hours was 4.49 ng/ml compared to a much higher level of 15.2 ng/ml in our cohort. It is also noteworthy that the 7-day concentration of sirolimus also differs significantly between our patient cohort and those in the other study (3.1 ng/ml versus 0.4 ng/ml). This is even with the original concentration of sirolimus eluted being higher in their population because of use of a luminal drug-coated stent with higher drug content for surface area. They have documented therapeutic concentration of $5\text{--}15 \text{ ng/ml}$. It is possible that there are differences in the method of estimation in different labs, and the lower and higher limit of detection may be different. The lower and higher limits prescribed by our laboratory were 2.27 ng/ml and 49.7 ng/ml , respectively.

Sirolimus is used as an immunosuppressive agent, and it is well known that recurrent infections or flare-up of indolent infections like tuberculosis can occur during sirolimus treatment. Although the previous published series do not report on adverse effects following sirolimus-eluting stents, there have been reports of toxicity following use of rapamycin group of drugs for other indications in the paediatric population. The other indications where sirolimus or everolimus is used in current practice include renal transplant recipients, ependymomas in tuberous sclerosis, and off-label use in cardiac rhabdomyomas. Saffari and colleagues characterised the adverse effects following systemic use of everolimus in a cohort of 17 patients with tuberous sclerosis.¹⁴ Recurrent infections, transient neutropenia and lymphopenia, transient anaemia, increase in cholesterol/ triglyceride levels, elevation of lactate dehydrogenase, transient stomatitis, and worsening of infantile acne were the reported side effects.

Our group of patients are more susceptible to infections compared to other children receiving sirolimus. Neonatal period,

immaturity of immune system, ICU stay, use of invasive catheters and lines, hypoxemia, and specific associations like Di George syndrome or asplenia in right isomerism are some of the factors increasing the susceptibility to infection in newborns with duct-dependent pulmonary blood flow. Presence of a large arterial duct itself has been recognised to be a contributing factor to the development of necrotising enterocolitis in these sick neonates.^{15,16} Hence, infection, necrotising enterocolitis, abnormalities of leucocyte counts, and liver function tests are not uncommon clinical problems in such patients. It is difficult to attribute such episodes to the presence of systemic sirolimus in immunosuppressive levels or even toxic doses. We did not note any alteration in leucocyte counts or liver and kidney function parameters.

In our cohort, two patients had pre-existing sepsis. Neonate 3 had prolonged hospital admission elsewhere prior to the stenting procedure. Hence, it may not be directly attributable to the ductal stenting. Since almost all the patients had been admitted elsewhere for stabilisation prior to shifting to our tertiary level centre, the risk of contracting infection is high and the contribution of sirolimus in sepsis cannot be determined. One patient had suspected necrotising enterocolitis while the neonate 4 with sepsis had frank features of necrotising enterocolitis. There were no long-term clinical consequences from any of these complications, and none of the patients required admission for treatment of infectious complications in the follow-up period. Consideration should be given to delay live vaccine administration, while sirolimus levels remain in the immunosuppressive range, especially when multiple drug-eluting stents are used or stent lengths more than 16 mm are used. It was observed that the sirolimus levels remain in the immunosuppressive range for up to 7 days after stent implantation. This is a critical period wherein the neonate requires close monitoring in hospital or at home for features of frank infection or early signs like poor feeding or activity. Routine immunisation must be offered only after 1 week following stenting as drug levels fall to low values by 1 week.

The cause for death in neonate 3 is unlikely due to an immunosuppression induced major infection because the blood level of sirolimus at the time of discharge itself was 3.3 ng/ml which is below the therapeutic range. It could be attributed to aspiration of feeds as understood by the verbal autopsy. Acute stent thrombosis could not be ruled out, although the child remained well after discharge till the index event associated with aspiration.

All the patients on follow-up had patent stents and good growth of pulmonary arteries. Although mean follow-up was only 207 days, that is the period when most patients who undergo ductal stenting are taken up for the definitive/palliative surgical procedures. It is reassuring to note that there were no significant stent occlusions requiring emergency interventions/surgeries. The patient who developed complete heart block at 5 months of age had an anatomical substrate for heart block with left isomerism. No reinterventions were required in this cohort as the stents were patent and infants were clinically well. This study demonstrates good patency rates when patients are compliant with dual antiplatelet therapy. Vida et al documented that the patients with ductal stents require additional surgical manoeuvres on pulmonary arteries in 53% of the patients on follow-up.¹⁷

It has been reported that patency rates and unplanned reinterventions due to luminal narrowing are comparably less with drug-eluting stents compared to bare-metal stents.¹⁶ Although it is difficult to comment based on the small numbers in our study, it is probably a better option to use drug-eluting stents than bare-metal stents because of prolonged patency rates especially in those

patients requiring long-term palliation on ductal stent. A study using third-generation sirolimus stent demonstrated patency of the stent up to 8–16 months in univentricular lesions and 21–27 months in patients destined for biventricular repair.⁹

Limitations

This is a prospective study with a small sample size. There were significantly lesser number of patients than expected because of the COVID-19 pandemic and lockdowns imposed. The availability of various diameters and, specifically, lengths of sirolimus-eluting stents was a concern. In certain cases, we had to use other available everolimus or zotarolimus-eluting stents as the specific length of sirolimus-eluting stent was not available. These cases could not be enrolled.

There were no objective tests performed to document immunosuppression. It may be overzealous to make any conclusions regarding the better safety in terms of drug levels in abluminal drug delivery.

Conclusions

This prospective observational study demonstrates the applicability of drug-eluting stents for ductal stenting in newborns. Drug-eluting stents with abluminal drug delivery are associated with high sirolimus levels in the initial hours after ductal stenting and rapidly taper to negligible levels within a week of implantation. Neonates with high pre-procedure likelihood of infection developed sepsis but responded well to conservative management.

This study documents high sirolimus levels in the 1st week after stent implantation, and hence, appropriate precautions (antibiotic cover and heightened surveillance) may be recommended for such neonates.

Randomised studies are required to confirm our speculations on the selection of abluminal stents over conformal drug-eluting stents for ductal stenting.

The use of drug-eluting stents is associated with excellent long-term patency following ductal stenting and is useful for relatively prolonged palliation. There is adequate symmetrical growth of pulmonary arteries following neonatal ductal stenting with drug-eluting stents.

Supplementary material. To view supplementary material for this article, please visit <https://doi.org/10.1017/S104795112200110X>

Acknowledgements. The authors would like to thank Mr. Kiran. C.L of Concept Medicals for clarifications regarding the technical details of the stent.

Financial support. None of the authors have any financial relationship (within the past 12 months) with a biotechnology manufacturer, a pharmaceutical company, or other commercial entity that has been involved in the subject matter or materials discussed in the manuscript to disclose.

Disclosures. The authors have no competing interests, funding, or financial relationships to disclose.

Ethical standards. The study was conducted in accordance with the ethical standards laid down in the 1964 Declaration of Helsinki and its amendments. Informed written consent was taken from the parent concerned. No patient identity particulars have been disclosed.

References

1. Do N, Hill KD, Wallace AS, et al. Shunt failure-risk factors and outcomes: An analysis of the society of thoracic surgeons congenital heart surgery

- database. *Ann Thorac Surg* 2018; 105: 857–864. doi: [10.1016/j.athoracsur.2017.06.028](https://doi.org/10.1016/j.athoracsur.2017.06.028).
2. Dorobantu DM, Pandey R, Sharabiani MT, et al. Indications and results of systemic to pulmonary shunts: results from a national database. *Eur J Cardiothorac Surg* 2016; 49: 1553–1563. doi: [10.1093/ejcts/ezv435](https://doi.org/10.1093/ejcts/ezv435).
 3. Alwi M, Choo KK, Latiff HA, Kandavello G, Samion H, Mulyadi MD. Initial results and medium-term follow-up of stent implantation of patent ductus arteriosus in duct-dependent pulmonary circulation. *J Am Coll Cardiol* 2004; 44: 438–445. doi: [10.1016/j.jacc.2004.03.066](https://doi.org/10.1016/j.jacc.2004.03.066).
 4. Alsagheir A, Koziarz A, Makhdoum A, et al. Duct stenting versus modified Blalock-Taussig shunt in neonates and infants with duct-dependent pulmonary blood flow: A systematic review and meta-analysis. *J Thorac Cardiovasc Surg*. Published online June 22, 2020. doi: [10.1016/j.jtcvs.2020.06.008](https://doi.org/10.1016/j.jtcvs.2020.06.008).
 5. Glatz AC, Petit CJ, Goldstein BH, et al. Comparison between patent ductus arteriosus stent and modified Blalock-Taussig shunt as palliation for infants with ductal-dependent pulmonary blood flow: Insights from the congenital catheterization research collaborative. *Circulation* 2018; 137: 589–601. doi: [10.1161/CIRCULATIONAHA.117.029987](https://doi.org/10.1161/CIRCULATIONAHA.117.029987).
 6. Bentham JR, Zava NK, Harrison WJ, et al. Duct stenting versus modified Blalock-Taussig shunt in neonates with duct-dependent pulmonary blood flow: Associations with clinical outcomes in a multicenter national study. *Circulation* 2018; 137: 581–588. doi: [10.1161/CIRCULATIONAHA.117.028972](https://doi.org/10.1161/CIRCULATIONAHA.117.028972).
 7. Lee K-J, Seto W, Benson L, Chaturvedi RR. Pharmacokinetics of sirolimus-eluting stents implanted in the neonatal arterial duct. *Circ Cardiovasc Interv* 2015; 8: e002233. doi: [10.1161/CIRCINTERVENTIONS.114.002233](https://doi.org/10.1161/CIRCINTERVENTIONS.114.002233).
 8. Alwi M. Stenting the ductus arteriosus: Case selection, technique and possible complications. *Ann Pediatr Cardiol* 2008; 1: 38–45. doi: [10.4103/0974-2069.41054](https://doi.org/10.4103/0974-2069.41054).
 9. Sivakumar K, Pavithran S, Sonawane B, Rajendran M, Ramasamy R. Serum sirolimus levels after implantation of third generation drug eluting cobalt chromium coronary stent in ductus arteriosus in neonates with duct-dependent pulmonary circulation. *Pediatr Cardiol* 2020; 41: 1354–1362. doi: [10.1007/s00246-020-02381-4](https://doi.org/10.1007/s00246-020-02381-4).
 10. Tijssen RYG, Kraak RP, Lu H, et al. Evaluation of the MiStent sustained sirolimus eluting biodegradable polymer coated stent for the treatment of coronary artery disease: does uniform sustained abluminal drug release result in earlier strut coverage and better safety profile? *Expert Rev Med Devices* 2017; 14: 325–334. doi: [10.1080/17434440.2017.1318057](https://doi.org/10.1080/17434440.2017.1318057).
 11. Zhu J, Liu H, Cui H, Tang Z, Song C, Zhang R. Safety and efficacy of a novel abluminal groove-filled biodegradable polymer sirolimus-eluting stent. *J Mater Sci Mater Med* 2017; 28: 54. doi: [10.1007/s10856-017-5864-0](https://doi.org/10.1007/s10856-017-5864-0).
 12. Gopalakrishnan A, Sasidharan B, Menon S, Krishnamoorthy KM. Drug-eluting stent for acute Blalock-Taussig shunt thrombosis in a child—case report. *Egypt Heart J* 2020; 72: 54. doi: [10.1186/s43044-020-00084-y](https://doi.org/10.1186/s43044-020-00084-y).
 13. Sehgal SN. Sirolimus: its discovery, biological properties, and mechanism of action. *Transplant Proc* 2003; 35 (3 Suppl): 7S–14S. doi: [10.1016/s0041-1345\(03\)00211-2](https://doi.org/10.1016/s0041-1345(03)00211-2).
 14. Saffari A, Brösse I, Wiemer-Kruel A, et al. Safety and efficacy of mTOR inhibitor treatment in patients with tuberous sclerosis complex under 2 years of age: a multicenter retrospective study. *Orphanet J Rare Dis* 2019; 14: 96. doi: [10.1186/s13023-019-1077-6](https://doi.org/10.1186/s13023-019-1077-6).
 15. Kessler U, Schulte F, Cholewa D, et al. Outcome in neonates with necrotizing enterocolitis and patent ductus arteriosus. *World J Pediatr WJP* 2016; 12: 55–59. doi: [10.1007/s12519-015-0059-6](https://doi.org/10.1007/s12519-015-0059-6).
 16. Aggarwal V, Dhillon GS, Penny DJ, Gowda ST, Qureshi AM. Drug-eluting stents compared with bare metal stents for stenting the ductus arteriosus in infants with ductal-dependent pulmonary blood flow. *Am J Cardiol* 2019; 124: 952–959. doi: [10.1016/j.amjcard.2019.06.014](https://doi.org/10.1016/j.amjcard.2019.06.014).
 17. Vida VL, Speggorin S, Maschietto N, et al. Cardiac operations after patent ductus arteriosus stenting in duct-dependent pulmonary circulation. *Ann Thorac Surg* 2010; 90: 605–609. doi: [10.1016/j.athoracsur.2010.04.007](https://doi.org/10.1016/j.athoracsur.2010.04.007).