

Patients with benign paroxysmal positional vertigo and cervical spine problems: is Epley's manoeuvre contraindicated, and is a proposed new manoeuvre effective and safer?

U M RASHAD

Abstract

Background: Benign paroxysmal positional vertigo is one of the commonest peripheral vestibular causes of vertigo. The particle repositioning manoeuvre (Epley's manoeuvre) has become the 'gold standard' treatment for this disorder. Benign paroxysmal positional vertigo can affect any age group but is commoner in older patients. Cervical spine problems (e.g. spondylosis and disc prolapse) are commoner in this age group. Epley's manoeuvre necessitates passive neck movements. Such movements may not be wise in patients at risk of cervical spine fracture.

Patients and methods: This study included 40 patients complaining of vertigo and diagnosed as having benign paroxysmal positional vertigo. A new particle repositioning manoeuvre was designed for these patients, as an alternative to Epley's manoeuvre.

Results: At one week review, 36 patients (90 per cent) reported total relief from vertigo. Three patients reported a major improvement in their vertigo, and their residual vertigo was relieved by performing the new manoeuvre again after two weeks. Further clinical reviews at one month, three months, six months and one year found that seven patients had suffered minor attacks of typical benign paroxysmal positional vertigo after three months. All seven were relieved of their symptoms after undergoing the new particle repositioning manoeuvre again.

Conclusion: The proposed new manoeuvre is simple, effective and safe for treating patients with benign paroxysmal positional vertigo and cervical spine problems.

Key words: Positional Vertigo; Cervical Spine; Physical Therapy

Introduction

Benign paroxysmal positional vertigo (BPPV) is one of the most common peripheral vestibular causes of vertigo. It is characterised by bouts of vertigo lasting for less than one minute, and is associated with nystagmus when the patient's head is moved in the plane of the affected semicircular canal.¹ The particle repositioning manoeuvre (or Epley's manoeuvre) has become the 'gold standard' for treatment of this disorder.² Benign paroxysmal positional vertigo can affect any age group but is commoner in older patients.^{3,4} Cervical spine problems (e.g. spondylosis and disc prolapse) are commoner in this age group.⁵ Epley's manoeuvre may fail or produce only partial improvement, and is not without complications, including arrhythmias, asystole, nausea and vomiting.⁶ Epley's manoeuvre necessitates passive movement of the neck. Such movements may not be wise in patients at risk of cervical spine fracture.

A new particle repositioning manoeuvre was designed for these patients, and is described in this report.

Patients and methods

Patients

The study included 40 patients complaining of vertigo and diagnosed as having BPPV.

Diagnosis of BPPV was based on a typical history of transient, positional vertigo when lying on the back or side. The diagnosis was confirmed by observing the typical brief, reproducible, horizontal-rotatory nystagmus when the patient's head was placed in a provocative position.^{2,4} Dix–Hallpike testing was avoided for fear of inducing cervical spine fracture.

Any features suspicious of cervical spinal problems were noted in the history and confirmed by radiology.

From the ENT Department, Assiut University, Egypt.

Accepted for publication: 1 February 2010. First published online 23 April 2010.

All patients were reviewed by the orthopaedic surgeons. Patients' known spinal problems included cervical spondylosis, disc prolapse, previous cervical spine fracture and cervical spine rheumatoid arthritis (Figure 1).

Method

The nature of BPPV was explained to every patient, as were the treatment options. All patients supplied either written or verbal consent.

The particle repositioning manoeuvre was performed in an operating theatre with the patient seated upon the operating table. A rigid neck collar was fitted so as to not cause much extension. The mild neck extension maintained by the adjustable rigid neck collar is intended to make the semicircular canal in the proper position in relation to gravity. The following steps were then followed.

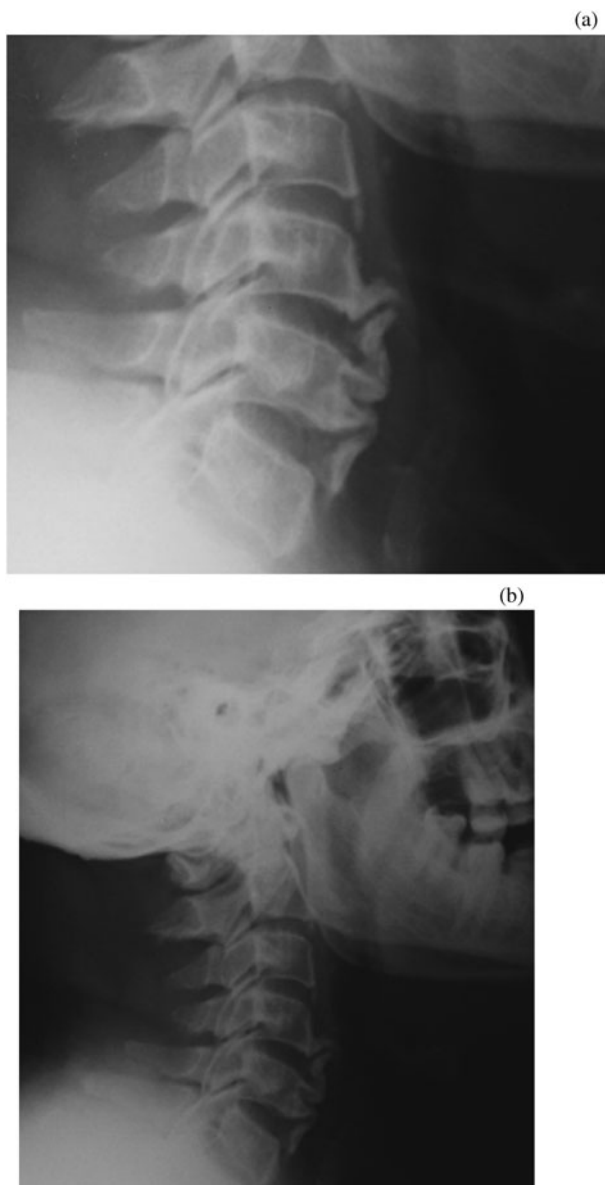


FIG. 1

Lateral cervical spine X-ray of a patient with cervical spondylosis and cervical osteophytes.

(1) The head of the operating table was lowered 30°. The patient sat on the middle of the table, so that their head would be supported by the table when lying down (this was position one; Figure 2).

(2) The patient was asked to lie rapidly on the side with vestibular pathology, without being touched (position two; Figure 3). This encouraged movement of particulate debris within the long arm of the posterior semicircular canal, away from the ampulla of the canal.

(3) The patient's body was then rotated onto the other side, without any twisting movement of the neck (position three; Figure 4). This action encouraged passage of the debris into the region of the common crus.

(4) The patient was then asked to lie face-down, maintaining the same head-neck relation (position four; Figure 5). In this position, particulate debris would be expected to pass through the common crus.

(5) The patient was then returned back to the upright position (position five; Figure 6) and the table returned to the horizontal plane. This position encouraged debris to fall into the vestibule.

(6) The rigid neck collar was then removed and the patient was asked to flex their neck in a safe fashion, avoiding any painful movements (position six; Figure 7).

(7) The patient then returned their head to a neutral position, facing forwards (position seven; Figure 8), and the rigid neck collar was replaced.

Each position was held for either two minutes, or one minute after the subsidence of any nystagmus, whichever was longer.

After the repositioning manoeuvre, patients were given the following instructions: stay still for at least two hours in a neutral position; sleep in a semi-sitting position for two nights; do not sleep on the affected side for one week; and thereafter to go about their normal lives.

Patients were reviewed after two weeks, one month, three months and six months.

Results

This study included 40 patients suffering from BPPV and cervical spine problems. Patients' ages ranged from 45 to 65 years. Nine patients were men and seven women. Table I lists patients' cervical spine problems.

At one week review, 36 patients (90 per cent) reported complete relief of their vertigo. This was

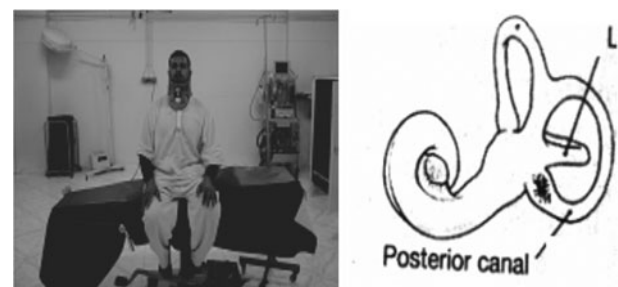

FIG. 2

Position one. L = lateral semicircular canal

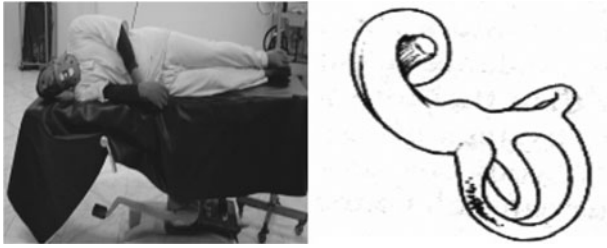

FIG. 3
Position two.

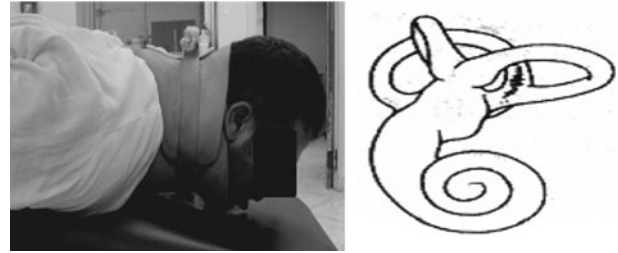


FIG. 5
Position four.

confirmed by complete absence of symptoms and negative nystagmus in the previously positive positional test. Three patients (of the unimproved four) reported a major improvement in their vertigo, while the last patient reported no improvement. All of these patients were negative for positional nystagmus. The last patient was re-evaluated and a diagnosis of cupulo-lithiasis considered; however, no other manoeuvres could be performed on this patient because of his spinal condition. The residual complaint in the previous three patients was relieved by performing the manoeuvre again after two weeks. We followed up the patients at one month, three months, six months and one year. We found that seven patients had suffered minor attacks of typical benign paroxysmal positional vertigo after three months. All the seven patients were relieved of their symptoms after undergoing the new particle repositioning manoeuvre once more.

The repositioning manoeuvre had no specific complications, apart from the mild light-headedness and nausea that commonly occur with Epley's manoeuvre.

Clinical review after one month, three months, six months and one year indicated that seven patients suffered minor attacks of typical BPPV after three months post-treatment. All seven were relieved of their symptoms upon repeated performance of the manoeuvre.

Discussion

Benign paroxysmal positional vertigo is the most common cause of vertigo, including vestibular, central and systemic and results from migration of otoconia into the semicircular canals.⁴ About 20 per

cent of all dizziness is due to BPPV. The older the patient, the more likely their dizziness is to be due to BPPV; about 50 per cent of all dizziness in older people is due to BPPV. In older people, the most common cause of BPPV is degeneration of the vestibular system of the inner ear; BPPV becomes much more common with advancing age.^{7,8}

Cervical spine problems are also commoner in the elderly.^{5,9} Thus, the coincidence of cervical spine problems and vertigo does occur in some patients. Vertigo due to BPPV must be differentiated from cervicogenic vertigo, which can be elicited by hyperactivity of spinovestibular afferents or, much more rarely, by episodic reduction of blood flow in the vertebral artery. Cervicogenic vertigo is usually induced by neck tilt and persists for minutes.⁸ Such patients were excluded from the current study.

Lea *et al.* reported that BPPV characteristics and treatment effectiveness, as measured by a negative Dix-Hallpike manoeuvre, are not age-dependent, and there is no need for any special approach or cautiousness when determining prognosis in older patients.¹

- Benign paroxysmal positional vertigo is commoner in elderly patients
- Cervical spine disease is also more common in the elderly
- This paper describes a new particle repositioning manoeuvre designed to minimise the possibility of damage to the cervical spine

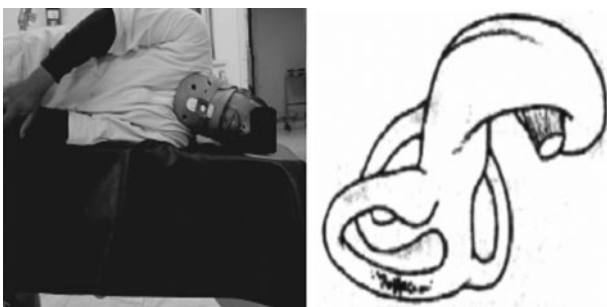

FIG. 4
Position three.

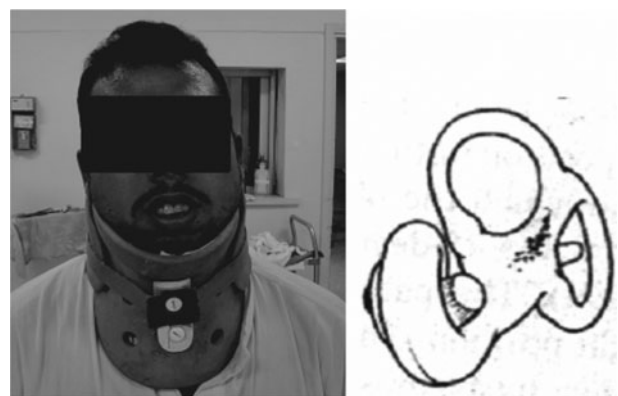

FIG. 6
Position five.

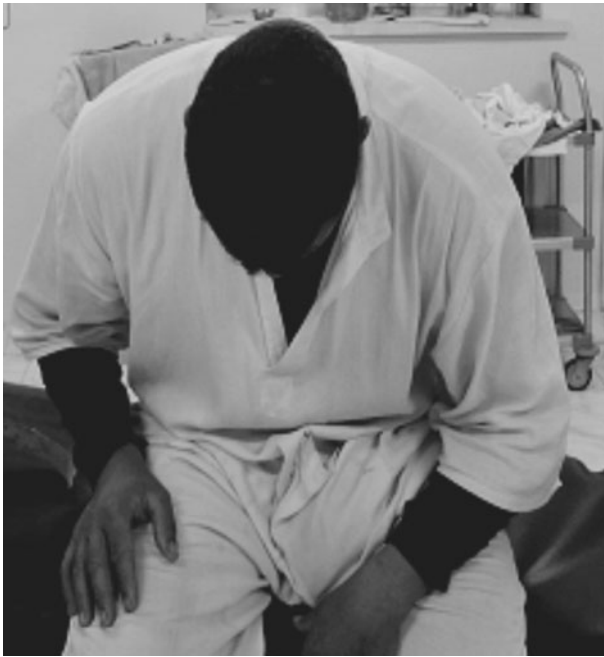

FIG. 7
Position six.

Epley reported that his manoeuvre for treating BPPV was contraindicated in patients with cervical spine problems.² Other authors have supported this view.¹⁰ This is logical, as this manoeuvre requires manipulation of the neck which may be harmful for

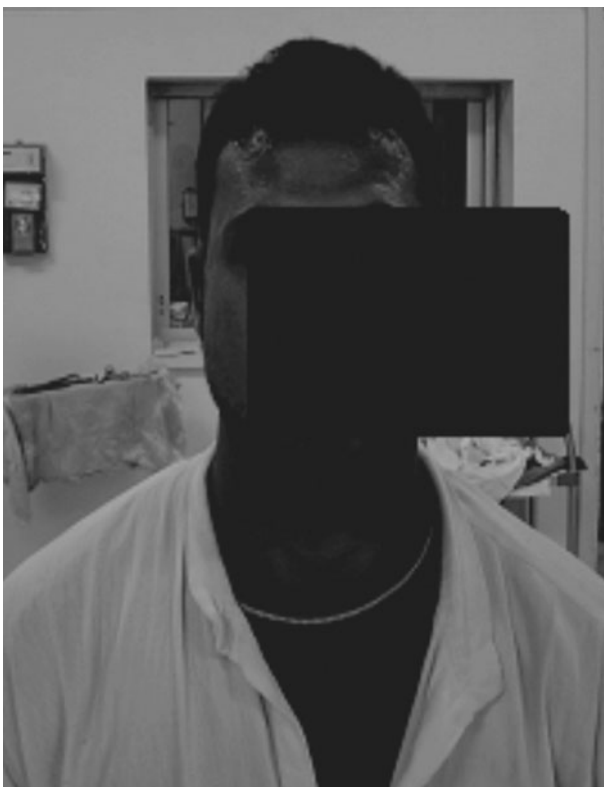

FIG. 8
Position seven.

TABLE I

PATIENTS' CERVICAL SPINE PROBLEMS

Problem	Pts (n)
Cervical spondylosis	31
Previous disc prolapse	7
Previous cervical spine fracture	1
Rheumatoid arthritis	1

Pts = patients

patients with spinal conditions, and may even lead to atlantoaxial dislocation. In an attempt to help such patients, the described, new manoeuvre was designed to avoid neck manipulation and the application of pressure to the cervical spine. The manoeuvre depends on gravity to effect movement of endolymphatic particles within the semicircular canal system. The angulations needed to direct these particles along the semicircular canal system were achieved with the help of an adjustable operating table. Clinical follow up showed that this new technique was as effective as the traditional Epley's manoeuvre, with a success rate of 90 per cent after one manoeuvre, which rose to 97.5 per cent after repetition. In comparison, Epley reported an 80 per cent success rate at one week review,² Parnes and Price-Jones a 79 per cent success rate at 3–4 week review,¹¹ and Herdman *et al.*¹² a 90 per cent success rate at 2 week review.¹² However, larger patient numbers are needed to enable better assessment of the current manoeuvre's results.

The effect of postural restrictions after the performance of Epley's manoeuvre is controversial. Most authors^{4,13–16} have indicated that post-manoevr restrictions do not improve treatment efficacy. However, Massoud and Ireland¹⁷ have suggested that such restrictions are beneficial. The current author believes that these restrictions may be of value, especially in the group of patients described.

Conclusion

The described, new particle repositioning manoeuvre is simple, effective and safe for treating patients with BPPV and cervical spine problems.

References

- 1 Lea P, Kushnir M, Shpirer Y, Zomer Y, Flecher S. Approach to benign paroxysmal positional vertigo in old age. *Isr Med Assoc* 2005;**7**:447–50
- 2 Epley JM. The canalith repositioning procedure: for treatment of benign paroxysmal positional vertigo. *Otolaryngol Head Neck Surg* 1992;**107**:399–404
- 3 Von-Brevern M, Radtke A, Lezius F. Epidemiology of benign paroxysmal positional vertigo. A population-based study. *J Neurol Neurosurg Psychiatry* 2007;**78**:710–15
- 4 Froehling DA, Silverstein MD, Mohr DN. Benign positional vertigo: incidence and prognosis in a population-based study in Olmsted County, Minnesota. *Mayo Clinic Proc* 1991;**66**:596–601
- 5 Hamilton JD, Johnston RA, Madhok R, Capell HA. Factors predictive of subsequent deterioration in rheumatoid cervical myelopathy. *Rheumatology* 2001;**40**:811–15

- 6 Sridhar S, Panda N. Particle repositioning manoeuvre in benign paroxysmal positional vertigo: is it really safe? *J Otolaryngol* 2005;**34**:41–5
- 7 Oghalai JS. Unrecognized benign paroxysmal positional vertigo in elderly patients. *Otolaryngol Head Neck Surg* 2000;**122**:630–4
- 8 Scherer H. Neck-induced vertigo. *Arch Otorhinolaryngol Suppl* 1985;**2**:107–24
- 9 Magarey ME, Rebbeck T, Coughlan B, Grimmer K, Rivett DA, Refshauge K. Pre-manipulative testing of the cervical spine review, revision and new clinical guidelines. *Man Ther* 2004;**9**:95–108
- 10 Furman JM, Cass SP. Benign paroxysmal positional vertigo. *N Engl J Med* 1999;**341**:1590–6
- 11 Parnes LS, Price-Jones RG. Particle repositioning maneuver for benign paroxysmal positional vertigo. *Ann Otorhinolaryngol* 1993;**102**:325–31
- 12 Herdman SJ, Tusa RJ, Zee DS, Proctor LR, Mattox DE. Single treatment approaches to benign paroxysmal positional vertigo. *Arch Otolaryngol Head Neck Surg* 1993;**119**:450–4
- 13 Marciano E, Marcelli V. Postural restrictions in labyrintholithiasis. *Eur Arch Otorhinolaryngol* 2002;**259**:262–5
- 14 Roberts RA, Gans RE, DeBoodt JL, Lister JJ. Treatment of benign paroxysmal positional vertigo: necessity of post-maneuver patient restrictions. *J Am Acad Audiol* 2005;**16**:357–66
- 15 Lopez EJ, Gonzalez-Sanchez M, Salinero J. Meta-analysis of the treatment of benign paroxysmal positional vertigo by Epley and Semont maneuvers [in Spanish]. *Acta Otorrinolaringol Esp* 1999;**50**:366–70
- 16 Fyrmpas G, Rachovitsas D, Haidich AB, Constantinidis J, Triaridis S, Vital V *et al.* Are postural restrictions after an Epley maneuver unnecessary? First results of a controlled study and review of the literature. *Auris Nasus Larynx* 2009;**6**:637–43
- 17 Massoud EAS, Ireland PJ. Post treatment instructions in the nonsurgical management of benign paroxysmal positional vertigo. *J Otolaryngol* 1996;**25**:121–5

Address for correspondence:

Dr Usama M Rashad,
ENT Department,
Faculty of Medicine,
Assuit University,
Assuit, Egypt.

E-mail: urashad2008@yahoo.com

Dr U M Rashad takes responsibility for the integrity of the content of the paper.

Competing interests: None declared
