

Dual congenital transmission of *Toxoplasma gondii* and *Sarcocystis neurona* in a late-term aborted pup from a chronically infected southern sea otter (*Enhydra lutris nereis*)

KAREN SHAPIRO^{1,2*}, MELISSA A. MILLER^{2,3}, ANDREA E. PACKHAM¹, BEATRIZ AGUILAR¹, PATRICIA A. CONRAD^{1,2}, ELIZABETH VANWORMER² and MICHAEL J. MURRAY⁴

¹ Pathology, Microbiology, and Immunology, School of Veterinary Medicine, University of California Davis, One Shields Ave, Davis California 95616, USA

² One Health Institute, University of California Davis, One Shields Ave, Davis California 95616, USA

³ California Department of Fish and Wildlife, Marine Wildlife Veterinary Care and Research Center, 1451 Shaffer Road, Santa Cruz California 95060, USA

⁴ Monterey Bay Aquarium, 886 Cannery Row, Monterey California 93940, USA

(Received 27 July 2015; revised 14 September 2015; accepted 24 September 2015; first published online 23 October 2015)

SUMMARY

Toxoplasma gondii and *Sarcocystis neurona* are protozoan parasites with terrestrial definitive hosts, and both pathogens can cause fatal disease in a wide range of marine animals. Close monitoring of threatened southern sea otters (*Enhydra lutris nereis*) in California allowed for the diagnosis of dual transplacental transmission of *T. gondii* and *S. neurona* in a wild female otter that was chronically infected with both parasites. Congenital infection resulted in late-term abortion due to disseminated toxoplasmosis. *Toxoplasma gondii* and *S. neurona* DNA was amplified from placental tissue culture, as well as from fetal lung tissue. Molecular characterization of *T. gondii* revealed a Type X genotype in isolates derived from placenta and fetal brain, as well as in all tested fetal organs (brain, lung, spleen, liver and thymus). This report provides the first evidence for transplacental transmission of *T. gondii* in a chronically infected wild sea otter, and the first molecular and immunohistochemical confirmation of concurrent transplacental transmission of *T. gondii* and *S. neurona* in any species. Repeated fetal and/or neonatal losses in the sea otter dam also suggested that *T. gondii* has the potential to reduce fecundity in chronically infected marine mammals through parasite recrudescence and repeated fetal infection.

Key words: *Toxoplasma gondii*, *Sarcocystis neurona*, sea otter, congenital transmission, transmammary transmission, abortion.

INTRODUCTION

While *Toxoplasma gondii* infections have been reported in numerous marine mammal species worldwide (Dubey *et al.* 2003; Miller, 2008), unanswered questions remain regarding transmission of this terrestrial parasite in aquatic fauna. Felids, both wild and domestic, are the only known definitive hosts for *T. gondii*, with sexual reproduction of the parasite resulting in fecal shedding of hundreds of millions of oocysts following initial infection (Hutchison *et al.* 1969; Dubey and Frenkel, 1972). Virtually all warm-blooded vertebrates are susceptible to *T. gondii* infection, including humans (Tenter *et al.* 2000). The majority of infections in people and animals are subclinical. However, the parasite can cause systemic disease and death in congenitally-infected fetuses and neonates, as well as in

patients who are immunosuppressed. Transmission of this zoonotic protozoan parasite to susceptible animals and humans can occur via horizontal transmission through ingestion of (i) environmentally robust oocysts in contaminated prey, soil or water; (ii) bradyzoite tissue cysts in undercooked or raw meat; or (iii) vertical transmission of tachyzoites that can infect fetuses and neonates via the placenta, or rarely via transmammary transmission (Tenter *et al.* 2000). In utero infections are often severe, and can result in fetal resorption, abortion, ocular disease and blindness, damage to the central nervous system, congenital malformations and death (Jones *et al.* 2003).

Epidemiological investigations have suggested that most *T. gondii* infections in marine mammals are acquired horizontally, as age is a significant risk factor for parasite exposure in southern sea otters (*Enhydra lutris nereis*) (Miller *et al.* 2002a) and sea lions (*Zalophus californianus*) (Carlson-Bremer *et al.* 2015). Ingestion of oocysts delivered to coastal habitats through surface runoff may play a critical role in transmission of *T. gondii* to sea

* Corresponding author: Pathology, Microbiology, and Immunology, School of Veterinary Medicine, University of California Davis, 4206 VM3A, One Shields Ave, Davis California 95616, USA. E-mail: kshapiro@ucdavis.edu

otters, a marine mammal that does not prey on typical intermediate hosts such as rodents and birds (Miller *et al.* 2002a). Few reports have documented congenital transmission of *T. gondii* in marine mammals (Jardine and Dubey, 2002; Resendes *et al.* 2002; Carlson-Bremer *et al.* 2015), including one prior report from a southern sea otter pup (Miller *et al.* 2008).

Human congenital transmission of *T. gondii* is thought to occur when previously un-infected women are exposed for the first time during pregnancy. Circumstances governing *T. gondii* congenital transmission dynamics in domestic animals and wildlife are more difficult to elucidate, given that historical data on past exposure is not usually available. However, limited scientific evidence suggests that the *T. gondii*-host relationship in some species can be more complex, resulting in recurrent fetal-placental infection and impacting multiple consecutive pregnancies. Sequential transplacental *T. gondii* transmission has been reported from chronically infected sheep (Hide *et al.* 2009), rodents (Rejmanek *et al.* 2010b) and dogs (Bresciani *et al.* 2009). Repeated vertical transmission in absence of re-exposure to oocysts or tissue cysts could significantly influence the epidemiology of toxoplasmosis in animal populations, as it implies a continuous source of infection in the absence of the parasite's definitive host (cats) and potential detrimental impacts on reproductive health.

Like *T. gondii*, *Sarcocystis neurona* is an apicomplexan parasite with a single terrestrial definitive host in North America, the Virginia opossum (*Didelphis virginiana*). Despite limited contact with known definitive or intermediate hosts, *S. neurona* infection is relatively common in marine mammals, including southern sea otters (Kreuder *et al.* 2003; Miller *et al.* 2010; Dubey *et al.* 2015) and phocids (Lapointe *et al.* 1998; Barbosa *et al.* 2015). However, congenital transmission of *S. neurona* is much less commonly reported, with only one prior report in marine mammals (Barbosa *et al.* 2015).

Unique circumstances in California provide resources and personnel to closely monitor individual radio-tagged, wild sea otters, and compile life-long data on their life history, reproduction and pathogen exposure status. The current study combines detailed antemortem and postmortem research findings to describe congenital transmission of *T. gondii* in a chronically infected sea otter dam with a history of recurrent reproductive failure and death of near term or neonatal pups. Evidence from culture isolation, histopathology, immunohistochemistry, serology and molecular characterization revealed that chronic *T. gondii* infection caused late-term abortion due to systemic toxoplasmosis of the fetus with a Type X isolate. Molecular confirmation of *S. neurona* in the placenta and fetus also provides putative evidence for dual

transplacental transmission of these parasites in a sea otter.

MATERIALS AND METHODS

Study materials and history

On February 9 2009, a female California sea otter pup (ID# 457-09) estimated to be approximately 1 week of age was found stranded at Carmel Point, Carmel Bay, Monterey County, California (Fig. 1). The otter was transported to the Monterey Bay Aquarium (MBA) for rehabilitation, which lasted until May 12 2010, at which time the otter was released in Elkhorn Slough (located within Monterey Bay, California). The female otter re-stranded with severe nasal pad wound (commensurate with breeding) on February 20, 2012 (Fig. 1). This stranding coincided with an anticipated pup birth resulting from breeding activities noted in late August/early September 2011; no pup or evidence of pregnancy were detected. After a second rehabilitation period at MBA, this same otter was released (April 27, 2012) and remained free-living until a third stranding event on July 30, 2013. At that time, she presented with non-specific clinical signs (dehydration and depression) and lack of a flight response. She received supportive care at the MBA and was scheduled for release until a routine radiograph (October 2 2013) revealed a partially ossified fetus. The dam subsequently aborted a late-term pup on November 7, 2013. Fresh sections of the placenta and aborted fetal brain tissue were transported to UC Davis within 24 h for protozoal isolation in tissue culture. A complete necropsy was also performed on the aborted pup and samples taken for molecular analysis and histopathological examination of tissues including brain, liver, spleen, lung and thymus.

The day following delivery of the aborted pup, an approximately 8-week old orphaned pup was introduced to the dam. The surrogate dam and pup displayed appropriate bonding behaviour and were jointly released on January 30 2014. Serum samples for protozoal antibody titres were obtained from the female sea otter dam at each stranding event and at several dates prior to and post-delivery of the stillborn fetus (Table 1). Serum was also obtained from the surrogate pup before and after introduction to the dam, as well as from the stillborn fetus.

Subsequent to the delivery of the aborted pup in November of 2013, this female otter was observed with a dead pup on October 19 2014, approximately 6 months after it was observed consorting with a male in mid-April 2014. The sea otter dam abandoned the carcass of the dead pup before it could be recovered. The otter was re-captured on October 21 2014, but no placenta was recovered for diagnostic testing.

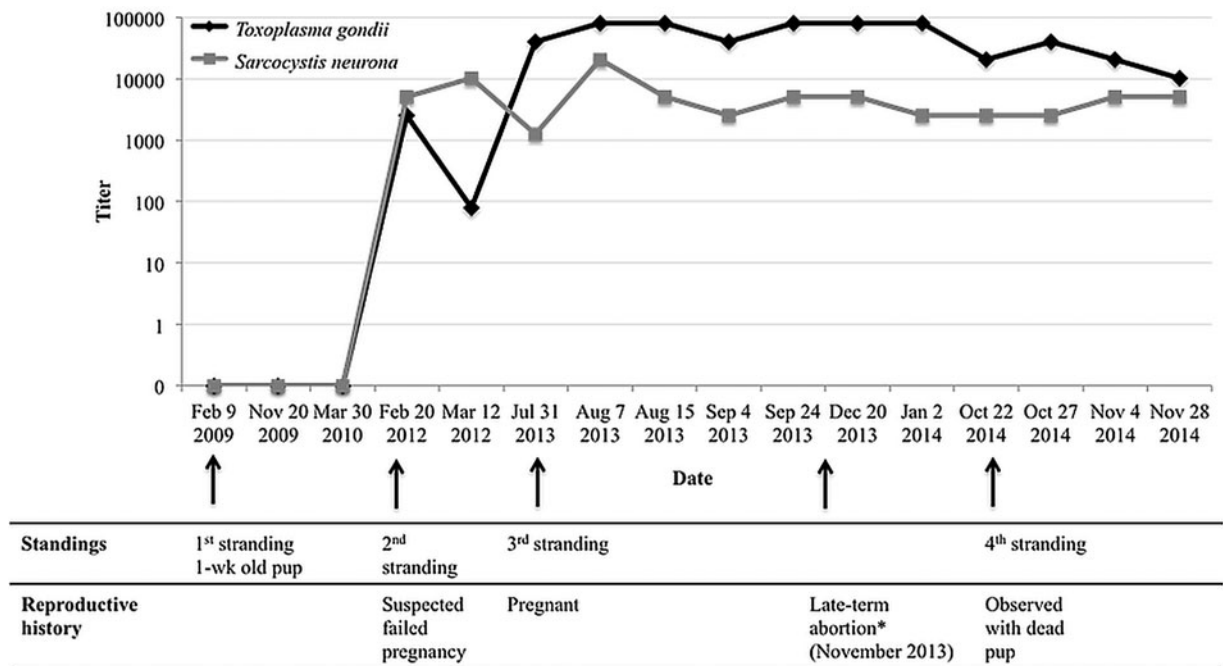


Fig. 1. Timeline of stranding events, reproductive history, and indirect fluorescent antibody titres to *Toxoplasma gondii* and *Sarcocystis neurona* in a female California sea otter that initially stranded as a pup in 2009. Following release as a young adult in 2010, the otter stranded three more times with subsequent rehabilitation at the Monterey Bay Aquarium – in February 2012, July 2013 and October 2014. During her third course of rehabilitation, the dam had a late-term abortion in November 2013(*). Initial seroconversion to both parasites was detected when the otter presented at her second stranding event in February 2012.

Table 1. Reciprocal antibody titres to *Toxoplasma gondii* and *Sarcocystis neurona* in breast milk collected from the sea otter dam, the aborted fetus and an orphaned pup that was introduced as a surrogate after the dam aborted. Antibody titres were determined on serum samples (surrogate pup) or pleural fluid (aborted fetus)

Source/specimen	Collection date	Parasite		Comments
		<i>T. gondii</i>	<i>S. neurona</i>	
Dam/milk	12/10/13	1280	160	
	12/20/13	8,1 920+	2560	
	1/2/14	8,1 920+	2560	
Aborted fetus/fluid	12/10/13	40	5	
Surrogate pup/serum	11/4/13	160	40	Pre-introduction to surrogate dam (11/8/13)
	11/15/13	IgG 40 IgM ^a 80	<40	First nursing observed 11/13/13
	12/20/13	IgG 640 IgM 1280	<40	
	1/2/14	IgG 320 IgM 320	40	

^a Antibody titres were determined by indirect fluorescent antibody testing for IgG except for samples from the surrogate pup, where both IgG and IgM antibody titres were determined to evaluate possible transmammary infection.

Tissue culture

Fresh sections (4–8 grams) of fetal brain and placenta were placed in antibiotic saline (5 mL) and stored at 4 °C for up to 24 h before being homogenized. Antibiotic saline (UC Davis Biological Media Services) contained Penicillin (16 000 units mL⁻¹), Streptomycin (0.8 mg mL⁻¹), Amphotericin B (0.2 µg mL⁻¹), and saline (pH 7.0). Homogenate of 1 mL was then added to 10 mL Trypsin-EDTA (ethylenediaminetetraacetic acid) (0.25%), phenol red (Life

Technologies, Grand Island, NY) and incubated in a water bath at 37 °C for 1 h. Samples were centrifuged at 3000 rpm for 10 min (Sorval RT 6000D, Kendro Laboratory Products Inc., Asheville, NC). Excess trypsin was removed, and the remaining 1 mL tissue pellet was added to MA-104 (monkey kidney) feeder layer cells (ATCC, Manassas, VA) within a T-25 flask (Corning Inc., Corning, NY) and incubated for 2 h at 37 °C and 5% CO₂. After incubation, the media (Delbecco’s Modified Eagle Medium, Life Technologies, Grand Island, NY) and tissue were

removed and discarded. Fresh Delbecco's medium supplemented with 10% fetal bovine serum (JR Scientific, Inc., Woodland, CA) was added to the flask. Cultures were returned to the incubator at 37 °C (Sanyo Electric Co., Ltd., Japan) and observed daily for evidence of parasite growth. Once parasites were observed, supernatant liquid was pelleted and frozen at -20 °C for molecular analysis as described below. Host cells containing parasites from culture were also harvested for cryopreservation.

Serology

Serum from the sea otter dam and surrogate pup, pleural fluid from the aborted fetus, and breast milk from the dam were tested for antibodies to *T. gondii*, *S. neurona* and *Neospora caninum* using antigen slides prepared in-house for an immunofluorescent antibody test (IFAT). Fluids were added in serial double dilutions (starting at 1:40 and ending at 1:81 920) to wells on antigen slides, incubated at 37 °C for 1 h, and washed three times (5 min each) in phosphate buffered saline (PBS, pH 7.4) (Diamedix Corp., Miami, FL). A secondary antibody (anti-ferret IgG, Bethyl Laboratories, Inc., Montgomery, TX or anti-ferret IgM, Rockland Immunochemicals Inc., Limerick, PA) conjugated to fluorescein isothiocyanate (FITC) and diluted 1:50 was then added to each well and incubated for another hour at 37 °C. The slides were washed as described previously and allowed to dry. Slides were visually inspected using an epifluorescent microscope (FITC filter set, Zeiss Axioskop, West Germany), and the last dilution to show a positive reaction (bright apple-green fluorescence of tachyzoite walls) was determined as the titre of the sample. A validation study has demonstrated that a cutoff titre of 1:320 for establishing positive exposure of sea otters to *T. gondii* maximized performance of the IFAT assay at 96.4% sensitivity and 67.3% specificity (Miller *et al.* 2002b). Furthermore, no cross-reactivity between *T. gondii* and *S. neurona* is known to occur using this method.

Histopathology and immunohistochemistry

All formalin-fixed fetal tissues were trimmed, paraffin-embedded and 5 µm thick sections were cut and stained with hematoxylin and eosin (H&E) at the UC Davis Veterinary Medical Teaching Hospital. Additional 5 µm sections were stained at the California Animal Health and Food Safety Laboratory, Davis, CA using polyclonal antiserum to both *T. gondii* and *S. neurona* as previously described (Miller *et al.* 2008, 2010). All tissue sections were reviewed under a light microscope for the presence of parasites, inflammation and tissue necrosis. Additional cryopreserved lung tissue was later formalin-fixed and *T. gondii* and *S. neurona* immunohistochemical stains were prepared and reviewed as described.

Molecular analysis – DNA extraction

Nucleic acids were extracted using the DNeasy Blood and Tissue Kit (Qiagen, Valencia, CA). For fetal tissue, approximately 20 µg of frozen specimen was used. Tissue culture-derived tachyzoites and breast milk from the sea otter dam were each centrifuged at 14 000 rpm for 5 min at 4 °C (Eppendorf 5417C, Hauppauge, NY) and the pellets were retained for extraction. The pellets were incubated with 180 µL ATL buffer and 30 µL proteinase K and incubated at 56 °C overnight. The remainder of the extraction process was carried out following manufacturer's instructions.

Screening molecular assays – polymerase chain reaction (PCR)

Initial screening of tissue culture-derived tachyzoites, fetal organs, and breast milk aliquots for *T. gondii* was conducted by applying nested primer sets targeting the internal transcribed spacer 1 (ITS1) (Rejmanek *et al.* 2009) and B1 (Grigg and Boothroyd, 2001) loci. The B1 gene dually served for screening as well as genotyping. The same samples were also tested for *S. neurona* DNA using the ITS1₅₀₀ primer set (Miller *et al.* 2009). All PCR assays were nested in design, and reaction mixtures (50 µL total) included 5 µL of 10× PCR buffer containing 15 mM MgCl₂, 1 µL of 10 mM dNTP mixture, 25 pmol forward primer, 25 pmol reverse primer, 1.5 U Taq polymerase, 2 µL DNA template for external reactions and 1 µL DNA for internal reactions.

Genotyping molecular assays: multiplexed nested polymerase chain reaction (Mn PCR) and restriction fragment length polymorphism (RFLP)

Extracted DNA was amplified for 12 polymorphic loci of *T. gondii* using a Mn PCR method that was previously described (Su *et al.* 2010). Briefly, the first amplification consisted of 50 µL final volume reactions containing 10× PCR buffer with MgCl₂ (final concentration 1X) 1.5 mM, dNTP mix 10 mM (final concentration 200 µM), AmpliTaq 5U/µL (final concentration 1.5U) as well as the forward and reverse external primer sets (25 pmol) for loci including SAG1, 3'-SAG2, alt. SAG2, SAG3, BTUB, GRA6, C22-8, C29-2, L358, protein kinase 1 (PK1), and Apico (external primers were not included for 5'-SAG2 because the alt. SAG2 primer set targets both loci). DNA template of 2 µL were added for the first amplification round, which employed the following thermocycler conditions: Pre PCR elongation 94 °C (3 min), denature at 95 °C (40 s), annealing at 58 °C (40 s), extension at 72 °C (90 s), and post PCR 72 °C (4 min). Amplification of internal primer set

products was performed using the conditions described above with the following exceptions: internal primer set for 5'-SAG2 was included, 1 μ L of product from the first external amplification was used as template DNA, and the thermocycler conditions were as follows: Pre PCR 95 °C (3 min), denature 94 °C (30 s), annealing at 60 °C for (30 s), extension at 72 °C (45 s), and post PCR incubation at 72 °C (10 min). Positive and negative controls were included with all reactions, and consisted of tissue culture-derived *T. gondii* and *S. neurona* DNA, and PCR-grade sterile water, respectively.

Internal amplification products were further analysed using RFLP to genotype the *T. gondii* isolate present in the aborted sea otter fetus and placenta. Digestion patterns were compared with well-characterized isolates including Types I (RH), II (ME49), III (CTG, cat *Toxoplasma gondii* strain), and X (DNA sequence from a tachyzoite-infected cell culture of brain tissue from a Type X-infected bobcat (number 4) identified by VanWormer *et al.* 2014). The restriction enzymes and digestion conditions for each locus were performed as described by Su *et al.* (2010). For the B1 locus, RFLP methods were conducted as described by Grigg and Boothroyd (2001). Following incubation of DNA with restriction enzymes, the digested products were visualized via electrophoresis using a 2.5 or 3% (Apico product only) agarose gel. Digestion products were stained with ethidium bromide and subjected to 90 V for 60 min; except for the C22-8 digestion product that was run at 70 V for 105 min for improved band separation.

Further assays to genetically characterize *S. neurona* in samples that tested positive using the screening assay above were also attempted by using primer sets targeting polymorphic loci including snSAG3, snSAG4 (*S. neurona*-specific surface antigens), and the microsatellite gene, sn7 (Asmundsson and Rosenthal, 2006; Rejmanek *et al.* 2010a; Wendte *et al.* 2010). However, DNA amplification efforts at these loci were unsuccessful.

Sequence analysis

For sequence analysis, PCR products were further purified using the QIAquick Gel Extraction kit (Qiagen Inc., Chatsworth, California) following manufacturer's instructions. Samples were submitted to the UC Davis core DNA Sequencing Facility. The forward and reverse DNA sequences were aligned using a multiple sequence comparison by log-expectation method via Geneious software (Biomatters, Auckland, New Zealand), ends trimmed, and the consensus sequence compared with GenBank reference sequences for *T. gondii* using Basic Local Alignment Search Tool (BLAST) (<http://blast.ncbi.nlm.nih.gov/Blast.cgi>) as well as with well characterized strain (Types I, II, III and

X) controls described above. Sequences from the different sea otter fetal tissues and the tissue culture-derived tachyzoites were also aligned with each other to evaluate whether all sequences were identical or whether a mixed infection (with multiple *T. gondii* genotypes) was present.

RESULTS

Tissue culture and serology

Ten days after monolayer cell cultures were inoculated with placenta and fetal brain tissue, free tachyzoites morphologically consistent with *T. gondii* were visualized. Larger characteristic clusters of zoites started to form by post-inoculation day 15. Tachyzoite pellets were collected and further characterized using PCR as described below. No visual evidence of *Sarcocystis neurona* growth was observed in either culture flask. Results of antibody titres to *T. gondii* and *S. neurona* in serum samples from the female sea otter dam are described in Fig. 1 and serological results for milk samples from the dam, serum from the aborted pup and fluid from the surrogate pup are summarized in Table 1. At her initial stranding as a one-week-old pup, the female sea otter was serologically negative to both *T. gondii* and *S. neurona*. However at her first re-stranding event 3 years later in February 2012, elevated antibody titres to both parasites were present (Table 1, Fig. 1). One month later (March 2012), prior to her release from the MBA, her reciprocal titres to *T. gondii* had declined to 80 (previously 2560), but in all subsequent samples collected over the next 2 years, *T. gondii* antibody titres remained very high ($\geq 40\ 960$; Fig. 1). At the time of her third stranding 15 months later and throughout the subsequent hospitalization at the MBA while pregnant, her *T. gondii* titres ranged from 40 960 to $> 81\ 920$. Titres to *S. neurona* ranged from 1280 to 20 480 during the same period (Fig. 1). Serum obtained from the sea otter dam during its fourth stranding event (9.5 months later, subsequent to another neonatal pup death) also indicated persistently high titres for *T. gondii* (20 480–40 960) and *S. neurona* (2560–5120).

Pleural fluid obtained from the stillborn pup had a positive reciprocal antibody to *T. gondii* of 40 and to *S. neurona* of 5. Elevated antibody titres to *T. gondii* and *S. neurona* ($> 81\ 920$ and 2560, respectively) were also present in breast milk samples obtained from the sea otter dam post-abortion. The initial evaluation of the surrogate pup showed low antibody titres to *T. gondii* (160 on 11/4/13) prior to its introduction to the dam (11/8/13); however, elevated titres (IgG 640; IgM 1280) were apparent 42 days post-introduction, indicative of either transmammary infection or passive transfer of antibodies. To compare IgM levels in the female dam and the

surrogate pup, one serum sample from the dam prior to her introduction to the surrogate pup (11/8/13) was also tested for IgM to *T. gondii*. A positive reciprocal IgM titre of 40 960 was present in this sample. The first evidence of nursing by the surrogate pup was observed on 11/13/13. The surrogate pup remained seronegative to *S. neurona* throughout the monitoring period. Antibody titres against *N. caninum* were negative in all samples tested.

Histopathology

Light microscopic examination was completed for H&E-stained placenta, plus fetal brain, lung, liver, kidney, umbilicus, skin, thymus, heart, tongue, spleen, pancreas and peripancreatic lymph node. Placental villi were moderately and multi-focally expanded by vascular congestion, haemorrhage, fibrin exudation, intravascular fibrin thrombi and a mixed inflammatory infiltrate composed of neutrophils, eosinophils, lymphocytes and monocytes (Fig. 2A). In several areas, intravascular fibrin thrombi completely obstructed vascular luminae. Extensive bands of villous coagulation necrosis were accompanied by more discrete regions of single cell necrosis, apoptosis and sloughing of endothelium and fetal trophoblastic cells lining individual villi. Most free protozoal zoites were short (6–8 μM long) and stout, with small, deeply basophilic nuclei and pale eosinophilic cytoplasm (Fig. 2A). Individual zoites and rare small ($\sim 50 \mu\text{M}$ diameter) round to oval intracytoplasmic tissue cysts with a thin, smooth cyst wall were scattered throughout affected villi, especially along inflamed vascular and luminal surfaces. Parasite density and distribution was difficult to assess in H&E-stained placenta due to high tissue cellularity and abundant cellular debris, so immunohistochemistry was employed to optimize visualization. Extensive *T. gondii* immunostaining was observed in placenta (Fig. 2B), with parasite distribution corresponding spatially with areas of severe tissue inflammation and necrosis.

The cerebral neuropil was mildly and multi-focally expanded by lymphoplasmacytic inflammation and malacia and adjacent capillary profiles were ectatic and blood-filled. Rare neurons located near these inflammatory foci contained small ($\sim 50 \mu\text{M}$ diameter) protozoal tissue cysts (Fig. 2C) similar to those described above. Skeletal muscle, tongue and cardiac myofibers were mild to moderately and multifocally separate by lymphocytes and monocytes. In the heart, numerous small foci of myofiber and stromal cell necrosis were noted, but no protozoal parasites were observed in tissues other than brain and placenta on H&E-stained tissue sections.

Immunohistochemical staining demonstrated a lower density of *T. gondii*-positive parasite profiles in the brain (Fig. 2D), heart, peripancreatic lymph

node, thymus, skeletal muscle, tongue and spleen. In addition, a small portion of placenta was immunopositive for *S. neurona* on both facing sections, supportive of co-infection by *S. neurona* (Figs 2E and F). However, *S. neurona* immunopositivity was not detected in fetal tissues.

Molecular testing

Screening PCR assays for *T. gondii* and *S. neurona* successfully amplified DNA of both parasites from tachyzoites derived from placental tissue culture, as well as from the fetal lung tissue. *Toxoplasma gondii* DNA was also amplified from tachyzoites propagated in tissue culture inoculated with fetal brain tissue, and from fetal organs including brain, lung, spleen, liver and thymus. Multi-locus RFLP genotyping of the *T. gondii* strain isolated from the fetal brain tissue revealed amplicon digestion patterns that were consistent with a Type X genotype across the 13-targeted loci (the 12 loci described by Su *et al.* (2010) and the B1 locus) (Table 2). Sequence analysis of amplification products from the different fetal organs yielded higher resolution molecular data for evaluating if a mixed infection was present. All sequences were identical with the exception of a single nucleotide polymorphism (SNP) present in the PK1 locus amplified from *T. gondii* in fetal liver tissue (Table 3). Compared with a previously described Type X isolate that served as a positive control, sequence analysis also showed identical sequences across all amplified loci with the exception of PK1, where three SNPs were present in the isolate derived from the placenta and aborted fetus (Table 3). Molecular detection via PCR for *T. gondii* and *S. neurona* was also attempted on aliquots of breast milk from the sea otter dam; however, parasite amplification from this matrix was unsuccessful.

DISCUSSION

The current case provides new insight on transplacental transmission of terrestrially derived protozoal pathogens in infected marine mammals. Comprehensive clinical and serological examination of the dam and postmortem diagnostic evaluation of the aborted pup support a diagnosis of congenital toxoplasmosis, providing the first compelling evidence for transplacental transmission of this zoonotic parasite in a chronically infected marine mammal. These data raise the question of whether recurrent reproductive losses due to chronic, sublethal toxoplasmosis may be more prevalent in sea otters than previously considered. In addition, molecular and immunohistochemical evidence for *S. neurona* in the placenta and fetal lung provide the first evidence for concurrent placental transmission of *T. gondii* and *S. neurona* in any species.

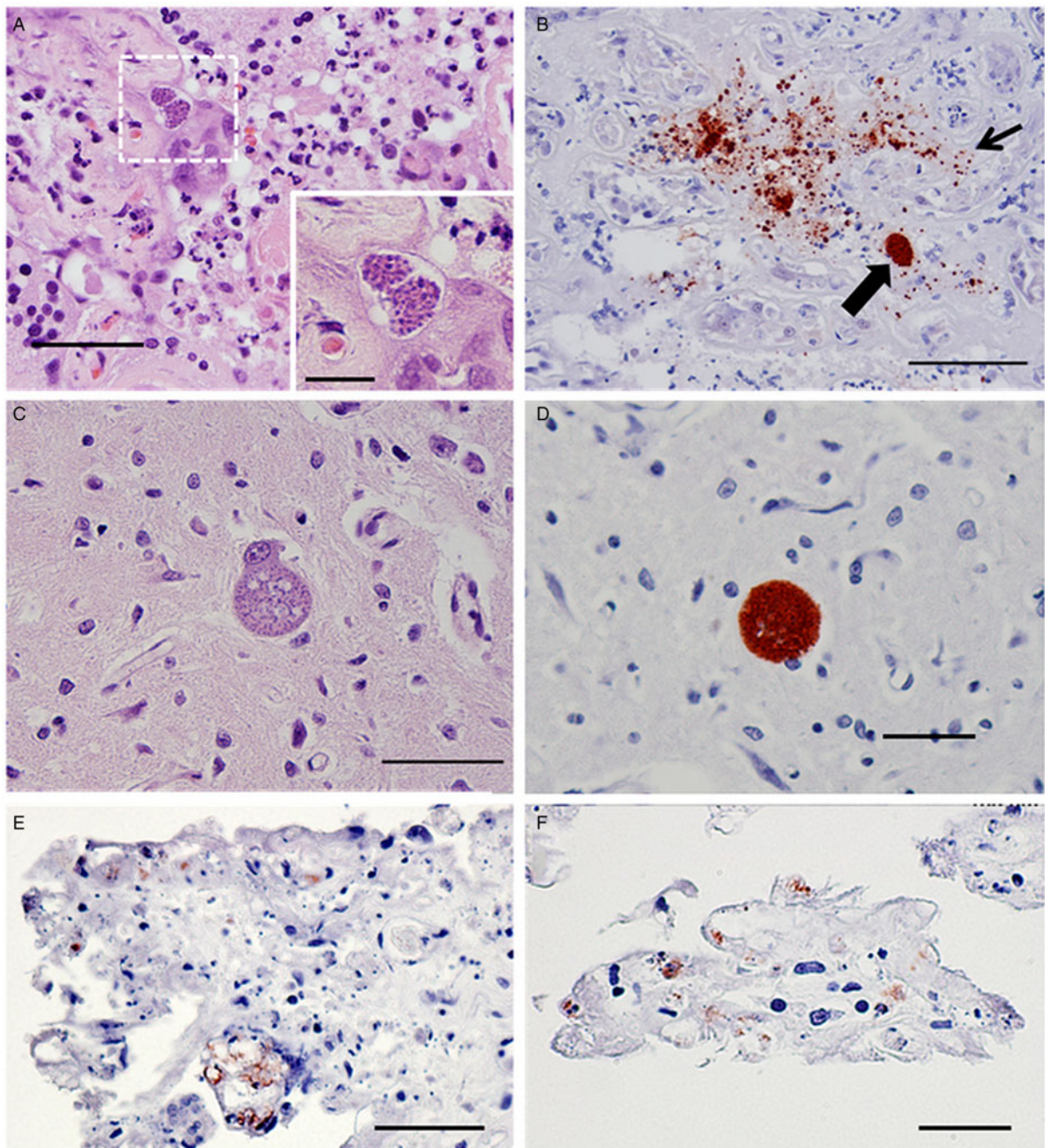


Fig. 2. Findings from placental and fetal histopathology and immunohistochemistry: (A) high magnification view of sea otter placenta showing marked tissue expansion by variably degenerate mixed inflammatory cells, fibrin and necrotic cell debris. Two discrete, intracytoplasmic *Toxoplasma gondii* tissue cysts (presumptive) are visible at the centre of the white box composed of dashed lines at top left. A higher magnification view (inset, lower right) of this same area reveals discrete clusters of tightly packed protozoal zoites within each developing tissue cyst. Individual zoites have small, centrally-placed basophilic nuclei and abundant, pale eosinophilic cytoplasm (H&E stain) (main figure bar = 100 μm ; inset bar = 30 μm); (B) the same placenta immunostained with antibodies to *T. gondii*. A large number of round to oval, positively-stained protozoal zoites are apparent throughout (small arrow), along with a single tissue cyst (large arrow) (bar = 200 μm); (C) fetal cerebrum: A single large neuron exhibits an eccentrically-placed nucleus containing two prominent nucleoli. There is marked, asymmetrical neuronal cytoplasmic distension due to a developing protozoal tissue cyst containing myriad *T. gondii* (presumptive) zoites (H&E stain) (bar = 100 μm); (D) fetal cerebrum: A single discrete, round, protozoal tissue cyst is characterized by strong-positive immunostaining for *T. gondii* (bar = 75 μm); (E) and (F) high magnification views of the same placenta as above, showing sparse, localized immunostaining for *S. neurona* on both facing sections, suggestive of placental co-infection by *T. gondii* and *S. neurona* (bar = 100 μm figure E; 50 μm figure (F)).

Table 2. Restriction fragment length polymorphism (RFLP) assays performed on amplified DNA from *Toxoplasma gondii* tachyzoites derived from tissue culture inoculated with fetal brain tissue. The cleaving patterns on the 13 loci that were analysed were consistent with alleles belonging to a Type X genotype

Locus	Allele
SAG1	X ^a
5'SAG2	I ^b /II ^c /X
3'SAG2	II/X
alt. SAg2	II/X
SAG3	II/X
BTUB	II/X
GRA6	II/X
C22-8	II/X
C29-2	II/X
L358	I/X
PK1	II/X
Apico	I/III ^d /X
B1	X

^a Reference strain used for Type X was previously described as Bobcat #4 identified by VanWormer *et al.* 2014.

^b Reference strain used for Type I was RH.

^c Reference strain used for Type II was ME49.

^d Reference strain used for Type III was CTG.

Based on findings from histopathology and immunohistochemistry, fetal death was due to disseminated toxoplasmosis due to transplacental infection. Histopathology revealed both protozoal-mediated necrosis of placental trophoblasts and endothelium, and obstruction of blood flow by resulting cell debris and fibrin thrombi, causing coagulation necrosis. The presence of small tissue cysts in brain, tongue, heart and skeletal muscle suggest that fetal infection had been present for some time (estimated at 10 days to several weeks). Fetal tissues appeared to be more autolyzed than placenta, supportive of fetal death resulting in abortion. Immunohistochemistry revealed high numbers of *T. gondii* parasites in the placenta, providing an important reminder of the potential human health risks from handling placental tissues and fetal fluids, including those from marine mammals.

Compared with prior reports of transplacental transmission of *T. gondii* in marine mammals, the current case study provides the most comprehensive molecular characterization to date. The sequence analysis and RFLP data on 13 distinct polymorphic loci confirmed infection with a Type X genotype (also designated Type 12, haplogroup 12 and ToxoDB Genotype #5) in all fetal organs and placenta. The same genotype was also implicated in a prior report of transplacental *T. gondii* transmission in a neonatal otter pup; however, only the B1 locus was characterized in that study (Miller *et al.* 2008). In their report, Miller *et al.* (2008) diagnosed transplacental transmission of *T. gondii* at necropsy in a

live-stranded neonatal pup. In contrast, Type X *T. gondii* infection in the current case resulted in late-term abortion. Other studies have documented the occurrence of congenital *T. gondii* transmission in Risso's dolphin (*Grampus griseus*) (Resendes *et al.* 2002) and an Indo-Pacific bottlenose dolphin (*Tursiops aduncus*) (Jardine and Dubey, 2002); however, molecular characterization of the implicated strains was not reported in either investigation.

Immunohistochemical confirmation of *S. neurona* zoites in placenta, and molecular confirmation of *S. neurona* DNA in placenta and fetal lung tissue provides the first confirmation of transplacental transmission of *S. neurona* in sea otters. Low concentrations of *S. neurona* parasites appeared to be present in placental tissue in comparison with *T. gondii*, as demonstrated by immunohistochemical stains and the failure of *S. neurona* to be isolated in tissue culture. Barbosa *et al.* (2015) recently documented congenital transmission of *S. neurona* in northern Pacific coastal marine mammals with fetal infections in a harbor porpoise (*Phocoena phocoena*), a Steller Sea Lion (*Eumatopias jubatus*), a pygmy sperm whale (*Kogia breviceps*), and harbor seals (*Phoca vitulina*). In horses in the USA, congenital transmission of *S. neurona* has been proposed to occur only rarely (Duarte *et al.* 2004; Pusterla *et al.* 2014), though higher occurrence was hypothesized in horses from Brazil (Pivot *et al.* 2014). However, transplacental parasite transmission was evaluated in these equine studies based solely on serologic data. One case of fatal disease due to congenital transmission of *S. neurona* has also been reported in a dog, with the diagnosis based on serological and histopathological findings (Dubey *et al.* 2014).

The current study is also the first report to provide molecular evidence of concurrent transplacental transmission of *T. gondii* and *S. neurona* in any animal. Deaths of post-natal sea otters due to dual *T. gondii* and *S. neurona* infections have been reported (Lindsay *et al.* 2001; Thomas *et al.* 2007; Miller *et al.* 2010; Shapiro *et al.* 2012), but the mode of transmission of these parasites was presumed to be horizontal. The only other prior report suggesting dual congenital transmission of *T. gondii* and *S. neurona* in any animal was a study in horses where transmission was determined based on serological testing of neonatal foals (Pivot *et al.* 2014).

Congenital transmission of *T. gondii* has been well documented in animals and humans; however, the majority of such infections were traditionally believed to occur in previously unexposed females who become acutely infected for the first time immediately prior to or during pregnancy (Remington *et al.* 2006). A few cases have been reported in people with exceptions to this general dogma. Congenital transmission in babies born to mothers who were chronically infected with *T. gondii* has been reported in immunocompromised women

Table 3. Sequence analysis at the *Toxoplasma gondii* PK1 gene amplified from control strains and brain and liver tissues from the aborted sea otter pup. The isolate derived from the pup's brain tissue demonstrated three single nucleotide polymorphisms (SNPs) (in bold font) as compared with a reference Type X isolate derived from a bobcat (VanWormer *et al.* 2014). The placenta and all other fetal tissues examined had the same SNPs as the fetal brain, while the PK1 gene amplified from fetal liver tissue included an additional SNP at position 334. These SNPs were present in nucleotide positions not subjected to enzyme digestion sites in the restriction fragment length polymorphism (RFLP) assay (178 and 669), thus yielding an identical cleaving pattern as the Type X control

Sequence source	Type	Nucleotide position														
		65	90	107	178 ^a	198	283	334	359	384	471	622	669 ^b	705	798	815
Controls	I (RH)	A	C	A	A ^c	C	C	T	C	G	A	C	G ^c	G	T	G
	II (ME49)	G	C	G	G ^d	C	A	T	C	G	A	C	T ^d	G	C	C
	III (CTG)	G	A	A	G ^d	C	A	T	T	A	T	–	G ^c	G	C	G
	X ^{e,f}	G	C	A	G ^d	T	A	T	C	G	A	C	T ^d	A	C	G
Aborted sea otter																
Brain	X ^g	G	C	G	G ^d	C	A	T	C	G	A	C	T ^d	G	C	G
Liver	X ^h	G	C	G	G ^d	C	A	C	C	G	A	C	T ^d	G	C	G

^a RsaI restriction enzyme site.

^b AvaI restriction enzyme site.

^c Not cleaved.

^d Cleaved.

^e DNA sequence from a tachyzoite-infected cell culture of brain tissue from Type X-infected Bobcat 4 identified by VanWormer *et al.* 2014.

^f GenBank accession number KT250562.

^g GenBank accession number KT250563.

^h GenBank accession number KT250564.

with AIDS (Minkoff *et al.* 1997; Lopes de Azevedo *et al.* 2010). One case report described congenital infection with *T. gondii* in a newborn from a chronically infected, immunocompetent mother who suffered reactivation of chorioretinitis during pregnancy (Andrade *et al.* 2010). Several cases have also been described in immunocompetent mothers who were likely reinfected with a different (and potentially more virulent) *T. gondii* strain during pregnancy, either through contact with kittens who were hypothesized to be shedding oocysts at the time (Gavinet *et al.* 1997), or through consumption of contaminated, undercooked meat (Elbez-Rubinstein *et al.* 2009; Valdes *et al.* 2011).

The repeated reproductive failures in the sea otter dam described in this study, and the observation that it suffered late-term abortion due to *T. gondii* despite evidence of prior exposure, suggest that chronic *T. gondii* infections may have detrimental impacts on wildlife population health that were not previously recognized. In the specific case described here, it is difficult to establish whether reproductive failure was due to infection with *T. gondii* alone or due to co-infection with *S. neurona*. The female otter experienced aborted fetuses or neonatal pup deaths at least three times during the observation period encompassing this study (Fig. 1). Additionally, based on serological diagnostic results using an IFAT that was previously validated for detection of *T. gondii* infection in sea otters (Miller *et al.* 2002b), initial infection of the dam occurred at least 18 months prior to transplacental transmission, but still resulted in fatal, systemic toxoplasmosis in the fetus (Fig. 1). Extensive PCR evaluation of placenta and fetal tissues using pan-specific primers did not reveal co-infection by more than one *T. gondii* strain. While a single isolate was recovered *in vitro* from the fetus, it is possible that the dam was initially infected with a different strain, followed by *de novo* infection with the present Type X isolate that infected the placenta and fetus. Definitive identification of a mixed infection in the dam would require rigorous parasite characterization in multiple organs, which is not feasible from a live wild otter. Collectively these data suggest that sequential reproductive failure due to *T. gondii* may be more prevalent in wildlife than was previously considered.

Successive vertical transmission of a related apicomplexan, *Neospora caninum*, is well described in cattle. Sequential transmission of *N. caninum* to the calves of chronically-infected cows is thought to occur due to immunomodulation that can occur during pregnancy, resulting in reactivation of dormant bradyzoites, forming rapidly replicating tachyzoites that can cross the placenta (Innes, 2007). Hide *et al.* (2009) proposed that vertical transmission might play a larger role than previously recognized in maintaining *T. gondii* in some animal and human populations. In certain sheep flocks

suffering from endemic *T. gondii* infections, congenital transmission can occur in up to 66% of pregnancies. Vertical transmission rates of *T. gondii* in wild mice (*Mus domesticus*) were also reported to be very high, occurring in 75% of naturally occurring pregnancies (Hide *et al.* 2009). While many studies report relatively low rates of congenitally transmitted *T. gondii* cases in humans (1 in 1000–10 000 based on serology testing of infants (Dubey and Jones, 2008)), a study in Libya reported nearly 20% of babies ($n = 121$) tested positive for *T. gondii* at birth, as determined by PCR testing of umbilical tissue (Hide *et al.* 2009). Some studies have questioned the validity of serological assays for determining *T. gondii* infections in congenitally infected animals, suggesting that antigenic tolerance can result in lack of detectable antibodies in animals where infection was confirmed via molecular or histological assays (Owen and Trees, 1998; Rejmanek *et al.* 2010b). Studies in rodents further demonstrated that vertical transmission could occur over multiple generations. For example, congenitally infected deer mice (*Peromyscus maniculatus*) can transmit the parasite to their F2 progeny, further supporting a potentially important, but often overlooked role for vertical transmission in the epidemiology of *T. gondii* (Rejmanek *et al.* 2010b).

While the specific factor(s) that may have induced sequential transplacental transmission of *T. gondii* in the sea otter dam reported here could not be definitively identified, both host and pathogen-specific factors may be relevant. Assays discerning competency of immune system function in marine mammals are not readily available, and none have been validated in sea otters. Reinfection with different strains of *T. gondii* is possible in California sea otters, as several genotypes have been described in this species (Sundar *et al.* 2008). A recent surveillance study further demonstrated that at a single site, multiple *T. gondii* genotypes can contaminate marine invertebrates in coastal California (Shapiro *et al.* 2014b), further supporting the possibility that sea otters may become exposed (through consumption of prey) to more than one *T. gondii* genotype over their lifetime. PCR analysis in the present case suggests that reactivation of *T. gondii* due to mixed infection was unlikely, as the only polymorphism detected among parasite DNA detected in different fetal organs was a single SNP in the PK1 locus amplified from liver tissue (Table 3). Interestingly, sequence analysis also revealed that across the 13 loci evaluated in this study, the only differences between the implicated strain characterized here and a prior Type X strain isolated from a California bobcat was also in the PK1 locus, with three distinct nucleotide differences present (Table 3).

Pairing of the sea otter dam with a surrogate pup immediately following the abortion event provided an opportunity to monitor for the possibility of

transmammary *T. gondii* transmission, a mode of parasite transmission that thus far has only been documented in domestic and laboratory animals (Tenter *et al.* 2000). Compared with titre levels prior to its introduction to the surrogate dam, higher *T. gondii* titres (IgG and IgM) in the surrogate pup were observed in serum samples collected 6 and 8 weeks after their pairing. The presence of IgM several weeks after nursing has begun (11/13/13) suggests that the pup may have been infected via tachyzoites present in the dam's breast milk, as mustelids do not have detectable levels of IgM in breast milk (Coe and Race, 1978). Amplification of *T. gondii* DNA in several aliquots of the sea otter's breast milk was attempted, but was not successful. While it is possible that passive transfer of antibodies may have contributed to the apparent rise in antibody titres in the pup, it is noteworthy that antibody titres in the dam were consistently high (1:81 960) during the entire period the dam-pup pair were monitored. Thus, passive transfer of antibodies would be expected to trigger a rise in serum antibodies in the pup soon after nursing, which was not the case (Table 1). Additionally, *S. neurona* titres remained low in the surrogate pup, while the dam had consistently high titres (though lower than *T. gondii*) through the monitoring period. Experimental infections have demonstrated that transmammary *T. gondii* transmission can occur in several species, including in cows, goats, sheep, cats and mice (Tenter *et al.* 2000; Powell *et al.* 2001). Ingestion of tachyzoites in unpasteurized animal milk has been identified as a rare route of exposure in people who consumed raw goat milk (Riemann *et al.* 1975; Sacks *et al.* 1982). One probable case of transmammary infection of a baby through human breast milk has also been reported (Bonametti *et al.* 1997).

In wildlife populations, vertical transmission of *T. gondii* in chronically infected female animals highlights a potential means for parasite persistence in remote regions that are devoid of the felid definitive host. For aquatic animals, this mode of transmission may also partially explain how the parasite can persist in populations that inhabit waters distant from sites receiving overland runoff that can deliver the environmentally resistant oocysts (Miller *et al.* 2002a). For example, *T. gondii* infections have been reported in some pelagic species such as striped (Domingo *et al.* 1992) and Risso's (Resendes *et al.* 2002) dolphins, while the route of infection to these mammals has remained unclear. Although recent evidence suggests that *T. gondii* oocysts can become incorporated into marine food webs that might reach deep sea-dwelling hosts (Shapiro *et al.* 2014a), the possible significance of congenital transmission in chronically infected animals as a means for perpetuating the presence of *T. gondii* in remote populations should be further

investigated. Repeated reproductive losses due to terrestrially derived pathogens may also hinder population growth in threatened species such as southern sea otters.

ACKNOWLEDGEMENTS

Findings from this research were made possible by dedicated staff and volunteers at the Monterey Bay Aquarium Sea Otter Research & Conservation program. Marissa Young (RVT) is acknowledged for her assistance with sea otter treatment and management. Erin Dodd and Francesca Batac (The California Department of Fish & Game) provided valuable assistance with preparation of sea otter tissue specimens for histopathological examination.

FINANCIAL SUPPORT

Funding support was provided through the Monterey Bay Aquarium (Mike Murray), and by the National Science Foundation (NSF) Ecology of Infectious Disease program (OCE-1065990) (Karen Shapiro and Patricia Conrad).

REFERENCES

- Andrade, G. M. Q., Vasconcelos-Santos, D. V., Carellos, E. V. M., Romanelli, R. M. C., Vitor, R. W. A., Carneiro, A. and Januario, J. N. (2010). Congenital toxoplasmosis from a chronically infected woman with reactivation of retinochoroiditis during pregnancy. *Jornal De Pediatria* **86**, 85–88.
- Asmundsson, I. M. and Rosenthal, B. M. (2006). Isolation and characterization of microsatellite markers from *Sarcocystis neurona*, a causative agent of equine protozoal myeloencephalitis. *Molecular Ecology Notes* **6**, 8–10.
- Barbosa, L., Johnson, C. K., Lambourn, D. M., Gibson, A. K., Haman, K. H., Huggins, J., Sweeny, A. R., Sundar, N., Raverty, S. J. and Grigg, M. E. (2015). A novel *Sarcocystis neurona* genotype XIII is associated with severe encephalitis in an unexpectedly broad range of marine mammals from the northeastern Pacific ocean. *International Journal for Parasitology* **45**, 595–603.
- Bonametti, A. M., Passo, J. N., daSilva, E. M. K. and Macedo, Z. S. (1997). Probable transmission of acute toxoplasmosis through breast feeding. *Journal of Tropical Pediatrics* **43**, 116–116.
- Bresciani, K. D. S., Costa, A. J., Toniollo, G. H., Luvizzoto, M. C. R., Kanamura, C. T., Moraes, F. R., Perri, S. H. V. and Gennari, S. M. (2009). Transplacental transmission of *Toxoplasma gondii* in reinfected pregnant female canines. *Parasitology Research* **104**, 1213–1217.
- Carlson-Bremer, D., Colegrove, K. M., Gulland, F. M. D., Conrad, P. A., Mazet, J. A. K. and Johnson, C. K. (2015). Epidemiology and pathology of *Toxoplasma gondii* in free-ranging California sea lions (*Zalophus californianus*). *Journal of Wildlife Diseases* **51**, 362–373.
- Coe, J. E. and Race, R. E. (1978). Ontogeny of mink IgG and IgM. *Proceedings of the Society for Experimental Biology and Medicine* **157**, 289–292.
- Domingo, M., Visa, J., Pumarola, M., Marco, A. J., Ferrer, L., Rabanal, R. and Kennedy, S. (1992). Pathological and immunocytochemical studies of Morbillivirus infection in Striped Dolphins (*Stenella coeruleoalba*). *Veterinary Pathology* **29**, 1–10.
- Duarte, P. C., Conrad, P. A., Barr, B. C., Wilson, W. D., Ferraro, G. L., Packham, A. E., Carpenter, T. E. and Gardner, I. A. (2004). Risk of transplacental transmission of *Sarcocystis neurona* and *Neospora hughesi* in California horses. *Journal of Parasitology* **90**, 1345–1351.
- Dubey, J. P. and Frenkel, J. K. (1972). Cyst-induced toxoplasmosis in cats. *Journal of Protozoology* **19**, 155–177.
- Dubey, J. P. and Jones, J. L. (2008). *Toxoplasma gondii* infection in humans and animals in the United States. *International Journal of Parasitology* **38**, 1257–1278.
- Dubey, J. P., Zarnke, R., Thomas, N. J., Wong, S. K., Van Bonn, W., Briggs, M., Davis, J. W., Ewing, R., Mense, M., Kwok, O. C., Romand, S. and Thulliez, P. (2003). *Toxoplasma gondii*, *Neospora caninum*, *Sarcocystis neurona*, and *Sarcocystis canis*-like infections in marine mammals. *Veterinary Parasitology* **116**, 275–296.

- Dubey, J. P., Black, S. S., Verma, S. K., Calero-Bernal, R., Morris, E., Hanson, M. A. and Cooley, A. J. (2014). *Sarcocystis neurona* schizonts-associated encephalitis, chorioretinitis, and myositis in a two-month-old dog simulating toxoplasmosis, and presence of mature sarcocysts in muscles. *Veterinary Parasitology* **202**, 194–200.
- Dubey, J. P., Howe, D. K., Furr, M., Saville, W. J., Marsh, A. E., Reed, S. M. and Grigg, M. E. (2015). An update on *Sarcocystis neurona* infections in animals and Equine Protozoal Myeloencephalitis (EPM). *Veterinary Parasitology* **209**, 1–42.
- Elbez-Rubinstein, A., Ajzenberg, D., Darde, M.-L., Cohen, R., Dumetre, A., Yera, H., Gondon, E., Janaud, J.-C. and Thulliez, P. (2009). Congenital toxoplasmosis and reinfection during pregnancy: case report, strain characterization, experimental model of reinfection, and review. *Journal of Infectious Diseases* **199**, 280–285.
- Gavinet, M. F., Robert, F., Firtion, G., Delouvrier, E., Hennequin, C., Maurin, J. R., TourteSchaefer, C. and DupouyCamet, J. (1997). Congenital toxoplasmosis due to maternal reinfection during pregnancy. *Journal of Clinical Microbiology* **35**, 1276–1277.
- Grigg, M. E. and Boothroyd, J. C. (2001). Rapid identification of virulent type I strains of the protozoan pathogen *Toxoplasma gondii* by PCR-restriction fragment length polymorphism analysis at the B1 gene. *Journal of Clinical Microbiology* **39**, 398–400.
- Hide, G., Morley, E. K., Hughes, J. M., Gerwash, O., Elmahaishi, M. S., Elmahaishi, K. H., Thomasson, D., Wright, E. A., Williams, R. H., Murphy, R. G. and Smith, J. E. (2009). Evidence for high levels of vertical transmission in *Toxoplasma gondii*. *Parasitology* **136**, 1877–1885.
- Hutchison, W. M., Dunachie, J. F., Siim, J. C. and Work, K. (1969). Life cycle of *Toxoplasma gondii*. *British Medical Journal* **4**, 806–806.
- Innes, E. A. (2007). The host-parasite relationship in pregnant cattle infected with *Neospora caninum*. *Parasitology* **134**, 1903–1910.
- Jardine, J. E. and Dubey, J. P. (2002). Congenital toxoplasmosis in a Indo-Pacific bottlenose dolphin (*Tursiops aduncus*). *Journal of Parasitology* **88**, 197–199.
- Jones, J., Lopez, A. and Wilson, M. (2003). Congenital toxoplasmosis. *American Family Physician* **67**, 2131–2138.
- Kreuder, C., Miller, M. A., Jessup, D. A., Lowenstine, L. J., Harris, M. D., Ames, J. A., Carpenter, T. E., Conrad, P. A. and Mazet, J. A. (2003). Patterns of mortality in southern sea otters (*Enhydra lutris nereis*) from 1998–2001. *Journal of Wildlife Diseases* **39**, 495–509.
- Lapointe, J. M., Duignan, P. J., Marsh, A. E., Gulland, F. M., Barr, B. C., Naydan, D. K., King, D. P., Farman, C. A., Huntingdon, K. A. B. and Lowenstine, L. J. (1998). Meningoencephalitis due to a *Sarcocystis neurona*-like protozoan in Pacific harbor seals (*Phoca vitulina richardsi*). *Journal of Parasitology* **84**, 1184–1189.
- Lindsay, D. S., Thomas, N. J., Rosypal, A. C. and Dubey, J. P. (2001). Dual *Sarcocystis neurona* and *Toxoplasma gondii* infection in a Northern sea otter from Washington state, USA. *Veterinary Parasitology* **97**, 319–327.
- Lopes de Azevedo, K. M., Setubal, S., Silami Lopes, V. G., Bastos Camacho, L. A. and de Oliveira, S. A. (2010). Congenital toxoplasmosis transmitted by human immunodeficiency-virus infected women. *Brazilian Journal of Infectious Diseases* **14**, 186–189.
- Miller, M., Conrad, P., James, E. R., Packham, A., Toy-Choutka, S., Murray, M. J., Jessup, D. and Grigg, M. E. (2008). Transplacental toxoplasmosis in a wild southern sea otter (*Enhydra lutris nereis*). *Veterinary Parasitology* **153**, 12–18.
- Miller, M. A. (2008). Tissue cyst-forming coccidia of marine mammals. In *Zoo and Wild Animal Medicine* Vol. 6 (ed. Fowler, M. and Miller, R.), pp. 319–340. Saunders Elsevier, St. Louis.
- Miller, M. A., Gardner, I. A., Kreuder, C., Paradies, D. M., Worcester, K. R., Jessup, D. A., Dodd, E., Harris, M. D., Ames, J. A., Packham, A. E. and Conrad, P. A. (2002a). Coastal freshwater runoff is a risk factor for *Toxoplasma gondii* infection of southern sea otters (*Enhydra lutris nereis*). *International Journal of Parasitology* **32**, 997–1006.
- Miller, M. A., Gardner, I. A., Packham, A., Mazet, J. K., Hanni, K. D., Jessup, D., Estes, J., Jameson, R., Dodd, E., Barr, B. C., Lowenstine, L. J., Gulland, F. M. and Conrad, P. A. (2002b). Evaluation of an indirect fluorescent antibody test (IFAT) for demonstration of antibodies to *Toxoplasma gondii* in the sea otter (*Enhydra lutris*). *Journal of Parasitology* **88**, 594–599.
- Miller, M. A., Barr, B. C., Nordhausen, R., James, E. R., Magargal, S. L., Murray, M., Conrad, P. A., Toy-Choutka, S., Jessup, D. A. and Grigg, M. E. (2009). Ultrastructural and molecular confirmation of the development of *Sarcocystis neurona* tissue cysts in the central nervous system of southern sea otters (*Enhydra lutris nereis*). *International Journal of Parasitology* **39**, 1363–1372.
- Miller, M. A., Conrad, P. A., Harris, M., Hatfield, B., Langlois, G., Jessup, D. A., Magargal, S. L., Packham, A. E., Toy-Choutka, S., Melli, A. C., Murray, M. A., Gulland, F. M. and Grigg, M. E. (2010). A protozoal-associated epizootic impacting marine wildlife: mass-mortality of southern sea otters (*Enhydra lutris nereis*) due to *Sarcocystis neurona* infection. *Veterinary Parasitology* **172**, 183–194.
- Minkoff, H., Remington, J. S., Holman, S., Ramirez, R., Goodwin, S. and Landesman, S. (1997). Vertical transmission of toxoplasma by human immunodeficiency virus-infected women. *American Journal of Obstetrics and Gynecology* **176**, 555–559.
- Owen, M. R. and Trees, A. J. (1998). Vertical transmission of *Toxoplasma gondii* from chronically infected house (*Mus musculus*) and field (*Apodemus sylvaticus*) mice determined by polymerase chain reaction. *Parasitology* **116**, 299–304.
- Pivot, F. L., de Macedo, A. G., da Silva, M. V., Ferreira, F. B., Silva, D. A. O., Pompermayer, E., Sangioni, L. A., Mine, T. W. P. and Vogel, F. S. F. (2014). Serological status of mares in parturition and the levels of antibodies (IgG) against protozoan family Sarcocystidae from their pre colostral foals. *Veterinary Parasitology* **199**, 107–111.
- Powell, C. C., Brewer, M. and Lappin, M. R. (2001). Detection of *Toxoplasma gondii* in the milk of experimentally infected lactating cats. *Veterinary Parasitology* **102**, 29–33.
- Pusterla, N., Mackie, S., Packham, A. and Conrad, P. A. (2014). Serological investigation of transplacental infection with *Neospora hughesi* and *Sarcocystis neurona* in broodmares. *Veterinary journal (London, England: 1997)* **202**, 649–650.
- Rejmanek, D., Vanwormer, E., Miller, M. A., Mazet, J. A. K., Nichelason, A. E., Melli, A. C., Packham, A. E., Jessup, D. A. and Conrad, P. A. (2009). Prevalence and risk factors associated with *Sarcocystis neurona* infections in opossums (*Didelphis virginiana*) from central California. *Veterinary Parasitology* **166**, 8–14.
- Rejmanek, D., Miller, M. A., Grigg, M. E., Crosbie, P. R. and Conrad, P. A. (2010a). Molecular characterization of *Sarcocystis neurona* strains from opossums (*Didelphis virginiana*) and intermediate hosts from central California. *Veterinary Parasitology* **170**, 20–29.
- Rejmanek, D., Vanwormer, E., Mazet, J. A. K., Packham, A. E., Aguilar, B. and Conrad, P. A. (2010b). Congenital transmission of *Toxoplasma gondii* in Deer Mice (*Peromyscus maniculatus*) after oral oocyst infection. *Journal of Parasitology* **96**, 516–520.
- Remington, J. S., McLeod, R., Thulliez, P. and Desmonts, G. (2006). Toxoplasmosis. In *Infectious Diseases of the Fetus and Neonborn Infant* (ed. Remington, J. S., McLeod, R., Thulliez, P. and Desmonts, G.), pp. 947–1091. Elsevier Saunders, Philadelphia.
- Resendes, A. R., Almeria, S., Dubey, J. P., Obon, E., Juan-Salles, C., Degollada, E., Alegre, F., Cabezon, O., Pont, S. and Domingo, M. (2002). Disseminated toxoplasmosis in a Mediterranean pregnant Risso's dolphin (*Grampus griseus*) with transplacental fetal infection. *Journal of Parasitology* **88**, 1029–1032.
- Riemann, H. P., Meyer, M. E., Theis, J. H., Kelso, G. and Behymer, D. E. (1975). Toxoplasmosis in an infant fed unpasteurized goat milk. *Journal of Pediatrics* **87**, 573–576.
- Sacks, J. J., Roberto, R. R. and Brooks, N. F. (1982). Toxoplasmosis infection associated with raw goats milk. *Jama-Journal of the American Medical Association* **248**, 1728–1732.
- Shapiro, K., Miller, M. and Mazet, J. (2012). Temporal association between land-based runoff events and California sea otter (*Enhydra lutris nereis*) protozoal mortalities. *Journal of Wildlife Diseases* **48**, 394–404.
- Shapiro, K., Krusor, C., Mazzillo, F., Conrad, P. A., Largier, J. L., Mazet, J. A. K. and Silver, M. W. (2014a). Aquatic polymers can drive pathogen transmission in coastal ecosystems. *Proceedings of the Royal Society B* **281**, 20141287.
- Shapiro, K., VanWormer, E., Aguilar, B. and Conrad, P. A. (2014b). Surveillance for *Toxoplasma gondii* in California mussels (*Mytilus californianus*) reveals transmission of atypical genotypes from land to sea. *Environmental Microbiology*. doi:10.1111/1462-2920.12685 [Epub ahead of print].
- Su, C., Shwab, E. K., Zhou, P., Zhu, X. Q. and Dubey, J. P. (2010). Moving towards an integrated approach to molecular detection and identification of *Toxoplasma gondii*. *Parasitology* **137**, 1–11.
- Sundar, N., Cole, R. A., Thomas, N. J., Majumdar, D., Dubey, J. P. and Su, C. (2008). Genetic diversity among sea otter isolates of *Toxoplasma gondii*. *Veterinary Parasitology* **151**, 125–132.
- Tenter, A. M., Heckeroth, A. R. and Weiss, L. M. (2000). *Toxoplasma gondii*: from animals to humans. *International Journal of Parasitology* **30**, 1217–1258.
- Thomas, N. J., Dubey, J. P., Lindsay, D. S., Cole, R. A. and Meteyer, C. U. (2007). Protozoal meningoencephalitis in sea otters (*Enhydra lutris*): a histopathological and immunohistochemical

study of naturally occurring cases. *Journal of Comparative Pathology* **137**, 102–121.

Valdes, V., Legagneur, H., Watrin, V., Paris, L. and Hascoet, J. M. (2011). Congenital toxoplasmosis due to maternal reinfection during pregnancy. *Archives De Pediatrie* **18**, 761–763.

VanWormer, E., Miller, M., Conrad, P., Grigg, M., Rejmanek, D., Carpenter, T. and Mazet, J. (2014). Using molecular epidemiology to

track *Toxoplasma gondii* from terrestrial carnivores to marine hosts: implications for public health and conservation. *PLoS Neglected Tropical Diseases* **8**, e2852.

Wendte, J. M., Miller, M. A., Nandra, A. K., Peat, S. M., Crosbie, P. R., Conrad, P. A. and Grigg, M. E. (2010). Limited genetic diversity among *Sarcocystis neurona* strains infecting southern sea otters precludes distinction between marine and terrestrial isolates. *Veterinary Parasitology* **169**, 37–44.