

An alternative use of video-telescopic guidance for insertion of myringotomy tube

FEI-PENG LEE, MD

Abstract

The insertion of a myringotomy tube is a common ENT procedure. Traditionally, this procedure is performed under otomicroscopic view. In this paper I describe a technique using rigid endoscopy with the Hopkins rod and a video monitor as a visual aid for the insertion of myringotomy tube in older children and adults. The technique is safe and effective; it allows demonstration of the entire tympanic membrane during surgery and also enables better teaching of the procedure than does the otomicroscope.

Key words: Ear, Middle; Otitis Media With Effusion; Surgical Procedures, Operative; Endoscopy

Introduction

Insertion of a myringotomy tube is a common ENT procedure. Traditionally, this procedure is performed under otomicroscopic view. In this paper I describe a technique using rigid endoscopy with the Hopkins rod and a video monitor as a visual aid for the insertion of myringotomy tube in older children and adults. I also discuss the relative merits of this technique compared with the traditional otomicroscope method.

Materials and methods

From December 2001 to February 2003, 26 cases (37 ears) of chronic otitis media with effusion were treated with myringotomy tube insertion under video-telescopic guidance. Patients' ages ranged from six to 73 years with an average of 32 years. The gender distribution was 13 males and 13 females. Nineteen right ears were involved and 18 left ears. Ten of these 26 patients were older children with ages ranging from six to 13 years. Five of the treated ears had a history of one to three previous myringotomy tube insertions. In children myringotomy tube insertion was performed under general anaesthesia. In adult patients the operation was performed under local anaesthesia with 2 per cent xylocaine solution containing 1:10 000 adrenaline.

The video-otoscope set included a Hopkins 4 mm, 0-degree telescope (Karl Storz), a compact three-chip Charged-Coupled Device (CCD) video camera (Karl Storz CCD telecam Dx ntsc 20232120), a Karl Storz Xenon light source and a Trinitron video monitor (Sony). This video-telescopic set was originally used for functional endoscopic sinus surgery.

The patient was placed in a supine position with head turned to the contra-lateral side of the operated ear. After appropriate draping the endoscope was adapted with a compact, three-chip CCD and covered with a sterile plastic bag (Figure 1). The endoscope shaft was held with the left hand and the endoscope lens tip was dipped into hot sterile saline and dried with gauze. The

endoscope was then carefully introduced into the external ear canal without inadvertent contact with the external ear canal skin to prevent pain and bleeding. Under direct vision projected on the video monitor (Figure 2), a radial incision was made in the antero-inferior or antero-superior quadrant of the ear drum with a myringotomy knife (Figure 3). This opening was sufficiently large to readily admit the myringotomy tube. The middle-ear effusion was then sucked out and the myringotomy tube placed at the edge of the tympanic membrane incision wound. Finally, the myringotomy tube was inserted (Figure 4) and adjusted to the correct position with the aid of a pick or forceps (Figures 5 and 6). In this study I used two kinds of myringotomy tube, the Sheehy collar button without wire (Micromedics Inc, St. Paul, Minnesota, USA) in 28 ears and the Bevel Bobbin (Atos Medical AB, Hörby, Sweden) in nine ears. If there was no active bleeding from the tympanic membrane fenestration or external ear canal wall, the procedure was usually finished in a short time period. However, if bleeding from external ear canal skin or tympanic membrane occurred, fogging of the lens during operation was a problem; this was rectified by withdrawing the endoscope and cleaning the tip with hot saline solution before re-insertion.

Results

The operation time for each ear ranged from four to 13 minutes, with an average of seven minutes. All patients had an uneventful recovery after operation with tubes in place and functional, except in three ears in which acute post-operative otorrhoea was successfully treated with antibiotics and ear drops.

Discussion

Endoscopes are commonly used in the office for inspecting the tympanic membrane and the medial external ear canal and also for photographic documentation.¹

Recently, rigid endoscopes have been used as an adjunct to standard otologic and neuro-otologic

From the Department of Otolaryngology, Taipei Medical University Hospital, Taipei Medical University, Taipei, Taiwan.




FIG. 1

A Hopkins 4 mm, 0-degree telescope was adapted with a compact three-chip charged-coupled device (CCD) video camera. The telescope and video camera were covered with a sterile plastic bag.

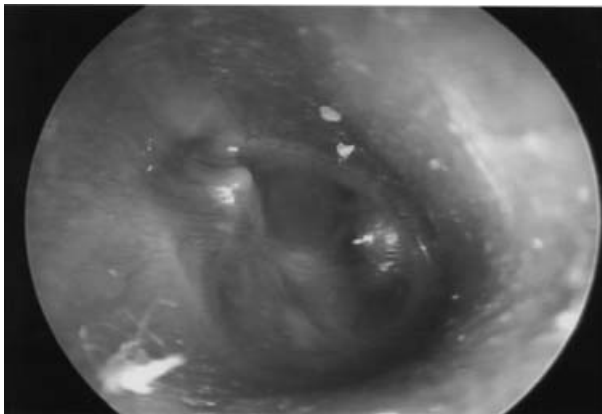


FIG. 2

Video-telescopic view of the ear drum. The tympanic membrane can be fully seen.

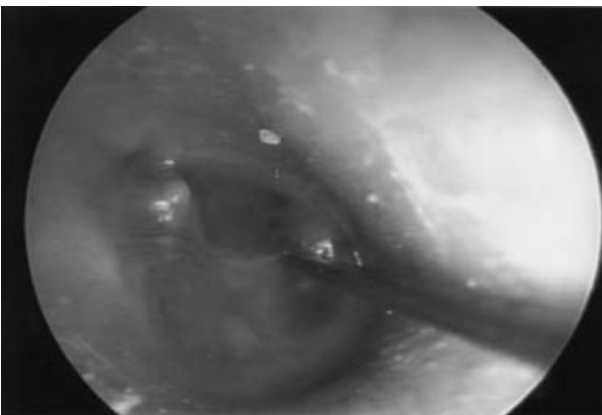


FIG. 3

A radial incision was made at the antero-inferior quadrant of the ear drum with a myringotomy knife under video-telescopic guidance.

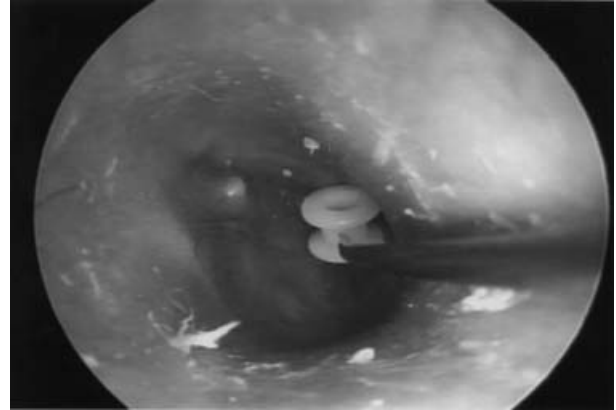

FIG. 4

The myringotomy tube was placed at the edge of the tympanic membrane incision wound under video-telescopic guidance.

procedures including myringoplasty,^{2,3} cholesteatoma surgery,⁴ identification of perilymph fistula⁵ and cerebello-pontine angle surgery.⁶⁻⁸

In 1990 Takahashi *et al.*⁹ used a fine, rigid endoscope to examine middle-ear structure in patients with otitis media with effusion through a myringotomy incision. The use of an otoendoscope for myringotomy and grommet insertion was first reported by Thomassin in 1998¹⁰ but did not become popular because the operating microscope had the major advantage of providing binocular vision.

Although the operating microscope is the instrument of choice for middle-ear surgery, my results demonstrate that the use of video-telescopic (instead of otomicroscopic) guidance in the insertion of myringotomy tubes is a safe and effective method in properly selected cases. In this study I selected patients older than six years so that the diameter of the external ear canal would be adequate.

The advantages of myringotomy tube insertion under video-telescopic guidance are as follows.

(1) Resolution of the surgical field is superior to that obtained through the operating microscope.¹¹

(2) The entire tympanic membrane can be viewed by assistants, nurses and medical students during the operation. Although for residents, teaching via this technique may not be any better than via a surgical microscope, for

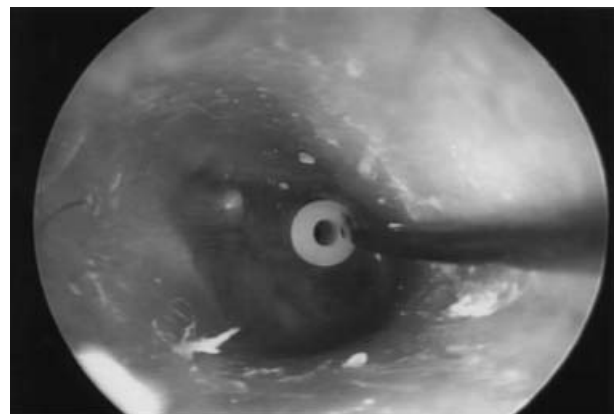


FIG. 5

The myringotomy tube was adjusted to the correct position with the aid of a pick under video-telescopic guidance.

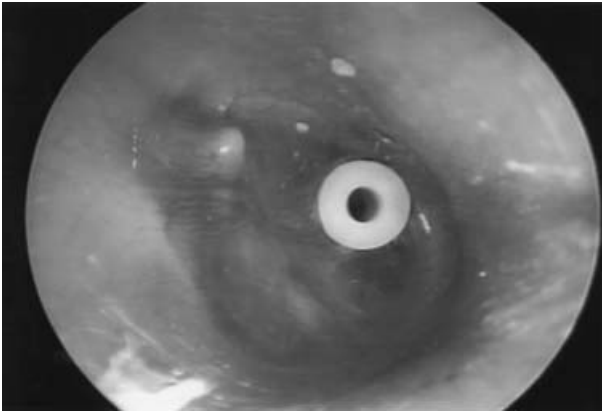


FIG. 6

Video-telescopic view of the ear drum after insertion of the myringotomy tube.

medical students and nurses it is definitely better in our experience.

(3) The operation can also be finished in a short time period compared with that required for the traditional otomicroscopic procedure, and the results are acceptable.

The disadvantages of myringotomy tube insertion under video-telescopic guidance are as follows.

(1) The method is a one-handed technique (during the insertion of the myringotomy tube) requiring special training.

(2) Fogging of the scope is a frequent problem during surgery. Bleeding from the incision edge or external ear canal wall obscures the endoscope tip, requiring frequent removal and cleaning. If persistent, troublesome bleeding occurs tube placement is difficult and one may need to revert to the otomicroscope.

(3) In those with smaller external ear canals (younger children and also some adults), the 4 mm rigid telescope is difficult to insert; a smaller sized telescope (e.g. 2.7 mm or 1.9 mm) may be necessary to accomplish the procedure.

Conclusion

Compared with otomicroscopic guidance, video-telescopic guidance for insertion of myringotomy tubes is a safe and effective technique in properly selected patients. This

technique allows demonstration of the entire tympanic membrane during surgery enabling better teaching for medical students and nurses.

References

- 1 Hawke M. Telescopic otoscopy and photography of the tympanic membrane. *J Otolaryngol* 1982;**11**:35–9
- 2 Karhuketo TS, Puhakka HJ. Technique of endoscope-aided myringoplasty. *Otol Neurotol* 2002;**23**:129–31
- 3 Ayache S, Braccini F, Facon F, Thomassin JM. Adipose graft: an original option in myringoplasty. *Otol Neurotol* 2003;**24**:158–64
- 4 Tarabichi M. Endoscopic management of cholesteatoma: long-term results. *Otolaryngol Head Neck Surg* 2000;**122**:874–81
- 5 Poe DS, Bottrill ID. Comparison of endoscopic and surgical explorations for perilymphatic fistulas. *Am J Otol* 1994;**15**:735–8
- 6 Rosenberg SI, Silverstein H, Willcox TO, Gordon MA. Endoscopy in otology and neurootology. *Am J Otol* 1994;**15**:168–72
- 7 Bottrill ID, Poe DS. Endoscope-assisted ear surgery. *Am J Otol* 1995;**16**:158–63
- 8 Poe DS. Endoscope-assisted middle ear surgery. In: Glasscock III GE, Gulya AJ, eds. *Surgery of the Ear*, 5th edn. Hamilton, Ontario: BC Decker, 2003:325–34
- 9 Takahashi H, Honjo I, Fujita A, Kurata K. Transtympanic endoscopic findings in patients with otitis media with effusion. *Arch Otolaryngol Head Neck Surg* 1990;**116**:1186–8
- 10 Thomassin JM. *Endoscopically Assisted Diagnostics and Surgery in Otology. Volume 1: Technique, Equipment and Indications*. Tuttlingen: Endo-Press, 1998
- 11 Yanagisawa E. The use of video in ENT endoscopy: its value in teaching. *Ear Nose Throat J* 1994;**73**:754–63

Address for correspondence:

Fei-Peng Lee, MD,
ENT Department,
Taipei Medical University Hospital,
252, Wu-Hsing Street,
Taipei, 110, Taiwan.

Fax: 011 886 2 27372189

E-mail: fplee@tmu.edu.tw

Dr Fei-Peng Lee takes responsibility for the integrity of the content of the paper.

Competing interests: None declared
