



Can we diagnose aortic arch obstruction in a fetus with an atrioventricular septal defect?

Original Article

Cite this article: Akam-Venkata J, Thankavel PP, Hussain T, Sharma K, Balakrishnan PL, and Ikemba CM (2024) Can we diagnose aortic arch obstruction in a fetus with an atrioventricular septal defect? *Cardiology in the Young* 34: 2182–2188. doi: [10.1017/S1047951124025642](https://doi.org/10.1017/S1047951124025642)


Received: 3 February 2024
Revised: 6 May 2024
Accepted: 4 July 2024
First published online: 16 December 2024

Keywords:

fetal echocardiography; atrioventricular septal defect; coarctation of aorta; congenital heart disease

Corresponding author:

Jyothisna Akam-Venkata;
Email: jyothisnaav@gmail.com

Jyothisna Akam-Venkata^{1,2} , Poonam P. Thankavel³, Tarique Hussain¹, Kavita Sharma¹, Preetha L. Balakrishnan⁴ and Catherine M. Ikemba¹

¹Department of Pediatrics, Division of Pediatric Cardiology, UT Southwestern Medical Center, Dallas, TX, USA; ²The Heart Institute, Joe Dimaggio Children's Hospital, Hollywood, FL, USA; ³Department of Pediatrics, Division of Pediatric Cardiology, Medical City Children's Hospital, Dallas, TX, USA and ⁴Department of Pediatrics, Division of Pediatric Cardiology, Children's Hospital of Michigan, Central Michigan University, Detroit, MI, USA

Abstract

Background: Aortic arch obstruction and/or coarctation of aorta is uncommon (5–20%) in balanced atrioventricular septal defects. Although technically challenging, prenatal diagnosis of aortic arch obstruction in atrioventricular septal defect is critical for delivery planning and improves prenatal counselling regarding the timing of cardiac surgery. We sought to identify prenatal predictors of coarctation of aorta in atrioventricular septal defect. **Methods:** Retrospective review of patients prenatally diagnosed with atrioventricular septal defect at two institutions. **Results:** Ninety-five fetuses with atrioventricular septal defect were identified and sufficient outcome data and diagnostic acoustic windows were available in 62. Six patients (10%) had coarctation of aorta after birth. Among the 38 patients with Trisomy 21, four (11%) had coarctation of aorta. On multivariable analysis, the proximal transverse aortic arch z score and ratio of left:right atrioventricular valve were independent predictors of coarctation of aorta with good interobserver reproducibility. Either proximal transverse aortic arch z score < -2, or ratio of left:right atrioventricular valve < 0.7, predicted aortic arch obstruction with 100% sensitivity and 89% specificity. **Conclusion:** Proximal transverse aortic arch z score and lower ratio of left:right atrioventricular valve diameter are independent predictors of postnatal coarctation of aorta in fetal patients with atrioventricular septal defect. The next step is the prospective application of these parameters to create an algorithm directing fetal counselling in terms of delivery location, and expected timing of surgical interventions.

Introduction

Atrioventricular septal defect represents 5% of all congenital heart disease and is commonly diagnosed on a four-chamber cardiac view on routine obstetric ultrasound.¹ Surgical repair of isolated atrioventricular septal defect is generally recommended at 3 to 6 months of age and involves patch closure of the septal defects and the creation of two atrioventricular valve orifices from the common atrioventricular valve.² While the incidence of isolated coarctation of the aorta is only 5–8% of all cardiac defects,^{3–5} aortic arch hypoplasia or coarctation of aorta is reported as an associated heart lesion in 5–20% of patients with atrioventricular septal defect.^{6–10} Even in fetuses with structurally normal hearts, the diagnosis of coarctation of aorta is challenging and often missed.^{3,11,12} Due to normal right ventricular dominant fetal physiology, where the ductus arteriosus provides the majority of cardiac output and only 10 to 15% courses through the aortic isthmus, prenatal diagnosis of aortic arch obstruction is challenging and has a high false-positive rate.^{4,17–19} Multiple studies have been devoted to the prenatal diagnosis of coarctation of aorta in otherwise structurally normal hearts; however, there is currently no published literature on the fetal predictors of aortic arch obstruction in atrioventricular septal defect patients.^{11,18}

Prenatal diagnosis of associated aortic arch obstruction in patients with atrioventricular septal defect alters prenatal counselling regarding delivery location secondary to ductal dependent circulation and the need for earlier surgical intervention. A fetus with isolated atrioventricular septal defect may deliver at a low-risk centre or local hospital. In contrast, when there is an obstruction to systemic outflow, such as coarctation of aorta, recommendations are for delivery at a hospital comfortable with critically ill neonates and cardiology consultation available.^{13–15}

We sought to identify whether prenatal markers of coarctation of aorta in structurally normal hearts apply to a fetus with atrioventricular septal defect. We hypothesised that left and right heart size and Doppler findings could predict postnatal aortic obstruction. We also report associated cardiac features and genetic abnormalities noted in our cohort of prenatally diagnosed atrioventricular septal defect patients.

© The Author(s), 2024. Published by Cambridge University Press. This is an Open Access article, distributed under the terms of the Creative Commons Attribution licence (<https://creativecommons.org/licenses/by/4.0/>), which permits unrestricted re-use, distribution and reproduction, provided the original article is properly cited.

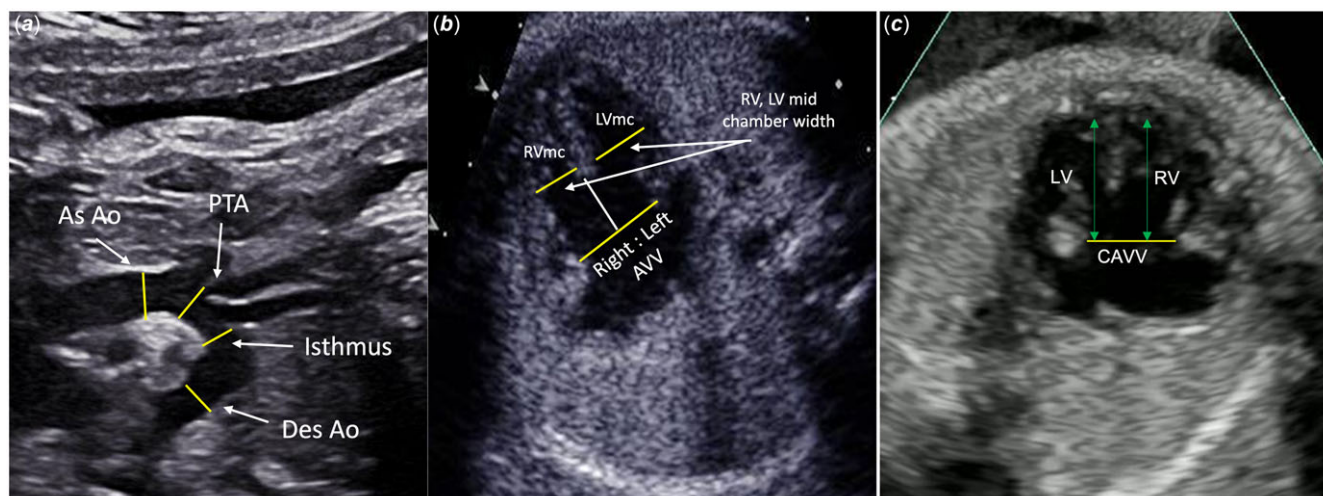


Figure 1. Fetal echocardiographic measurements in atrioventricular septal defect. 1A: aortic arch measurements: as. Ao = ascending aorta, PTA = proximal transverse aortic arch. 1B: intracardiac measurements: rvmc = right ventricle mid-chamber width, lvmc = left ventricle mid-chamber width. Right: left AVV = right and left diameter of the common atrioventricular valve. 1C: intracardiac measurements: LV = left ventricular length, RV = right ventricular length, CAVV = common atrioventricular valve.

Methods

Fetal atrioventricular septal defect patients were identified from the cardiology databases at the University of Texas Southwestern and Wayne State University between January 1, 2010 and September 30, 2019. Exclusion criteria included: prenatally diagnosed heterotaxy syndrome, unbalanced atrioventricular septal defect requiring single ventricle palliation, other associated congenital heart diseases (such as Tetralogy of Fallot or double outlet right ventricle), non-diagnostic fetal echocardiograms due to poor acoustic windows, and patients without postnatal follow-up. The institutional review boards from both universities approved this study.

Fetal echocardiograms were performed per the standard guidelines of the American Society of Echocardiography.^{13,21} The first fetal echocardiogram was reviewed in the majority of cases. If the initial echocardiogram had inadequate images, a follow-up echocardiogram was selected for analysis. Atrioventricular septal defect included complete, transitional, and partial forms. Complete atrioventricular septal defect was defined as presence of a common atrioventricular valve, primum atrial septal defect, and inlet ventricular septal defect. Transitional atrioventricular septal defect was defined as presence of two separate atrioventricular valve orifices, primum atrial septal defect, and inlet ventricular septal defect. Partial or incomplete atrioventricular septal defect was defined as presence of two separate atrioventricular valve orifices with a primum atrial septal defect but no ventricular septal defect.²² Measurements were performed on the optimal image from various frames three times, and an average was recorded by a single reader (JA) blinded to postnatal diagnosis, minimizing intra-observer variability. To assess interobserver variability, measurements were repeated by a second reader (CI) in 10 randomly selected echocardiograms blinded to the clips and frames chosen by the first reader.

Fetal measurements included aortic valve annulus, ascending aorta, proximal transverse aortic arch, aortic isthmus, pulmonary valve annulus, main pulmonary artery, and ductus arteriosus in systole. The proximal transverse arch was measured between the innominate and left common carotid arteries. The aortic isthmus was measured distal to the origin of the left subclavian artery and proximal to the insertion of the ductus arteriosus. Presence or

absence of a posterior shelf at the aortic arch isthmus was noted. The left and right-sided measurements of the common atrioventricular valve were obtained by drawing a line spanning the atrioventricular valve diameter at end-diastole, which was bisected by a perpendicular line drawn from the crest of the interventricular septum to the plane of the common atrioventricular valve in a four-chamber view (Figure 1).¹⁰ The same view was utilised to obtain the left and right ventricular lengths and the left and right ventricular mid-cavitary widths (Figure 1).¹⁸ The corresponding *z* scores were calculated based on the gestational age utilising Boston fetal echo *z* score calculator.²⁴

Colour and pulsed wave Doppler were utilised to determine the direction and timing of flow across the atrial septum, aortic arch, and ductus arteriosus. The presence of antegrade diastolic flow at the aortic isthmus was also noted, although this can be a normal finding.²⁵ Peak velocity (m/sec), as well as velocity time integral (m), were measured across the aortic valve, pulmonary valve, ductus arteriosus, and transverse aortic arch.

Based on postnatal echo reports, patients were divided into two groups: atrioventricular septal defect with versus without coarctation of aorta/arch hypoplasia. The group with arch obstruction included patients with both discrete posterior shelf and long-segment arch hypoplasia. Patient electronic medical records including echo reports were reviewed for bicuspid aortic valve, left atrioventricular valve morphology, left-sided superior vena cava, number of papillary muscles, use of prostaglandin, additional cardiac and non-cardiac anomalies, Trisomy 21, and other chromosomal abnormalities or syndromes.

Statistical analysis

Kolmogorov-Smirnov test was performed to determine the normality. Mann-Whitney non-parametric test was used to compare the fetal echo measurements and ratios between patients with and without coarctation of aorta. Multivariable analyses were performed to identify independent predictors of coarctation of aorta. Continuous variables were reported as median and standard deviation. The variables that were not normally distributed were reported as median and 25th and 75th percentile interquartile range. The intraclass correlation coefficient was calculated to assess

Table 1. Comparison of fetal echo parameters in atrioventricular septal defect patients with and without post natal coarctation of aorta/arch hypoplasia

Parameter	Coarctation (n = 6)	Normal Aortic Arch (n = 56)	p value (* < 0.05)	N
Gestational age at fetal echo weeks, days (median IQR 25 th to 75 th %)	28.0 (23.1 to 32.1)	29.9 (26.2 to 32.3)	NA	62
PTA mean (SD)	0.31 (0.09)	0.46 (0.09)	<0.001*	52
PTA arch z score mean (SD)	-2.37 (0.95)	-0.13 (1.48)	0.001*	52
Isthmus mean (SD)	0.28 (0.1)	0.38 (0.08)	0.006*	47
Isthmus z score mean (SD)	-2.03 (1.39)	-0.3 (1.59)	0.015*	47
Left:right AV valve ratio (median IQR 25 th to 75 th %)	0.64 (0.54 to 0.92)	0.91 (0.81 to 1.06)	0.018*	61
Left:right ventricle mid 4 chamber width ratio (median IQR 25 th to 75 th %)	0.75 (0.59 to 0.88)	0.95 (0.82 to 1.16)	0.025*	60
Left:right ventricle length ratio (median IQR 25 th to 75 th %)	1.05 (0.94 to 1.16)	1.07 (1.01 to 1.17)	0.639	60
AoV: PV ratio (median IQR 25 th to 75 th %)	0.81 (0.69 to 0.85)	0.81 (0.77 to 0.91)	0.427	61
Asc aorta:MPA dia ratio (median IQR 25 th to 75 th %)	0.76 (0.56 to 0.89)	0.88 (0.6 to 1.03)	0.111	57

IQR = interquartile range, PTA = proximal transverse arch measured in cm, Isthmus measured in cm, AV = atrioventricular, AoV = aortic valve, PV = pulmonary valve, Asc = ascending aorta, MPA = main pulmonary artery.

interobserver variability in the measurements performed by two readers. All the statistical analyses were performed using IBM SPSS version 2 software.

Results

A total of 95 fetal atrioventricular septal defect patients were identified from the cardiology databases. Thirty-three patients were excluded per study protocol. The final cohort included 62 patients, 55 complete atrioventricular septal defect and 7 incomplete (partial/transitional) atrioventricular septal defect. The incidence of postnatally confirmed coarctation of aorta based on echocardiography in our cohort of atrioventricular septal defect patients was 10% (6/62). All of the patients in the coarctation of aorta group received prostaglandin infusion after birth. Four of the patients with coarctation of aorta had Trisomy 21. Thus the incidence of coarctation of aorta in the subset of atrioventricular septal defect patients with Trisomy 21 was 11% (4/38). The median gestational age at the initial prenatal diagnosis was 29 weeks and 4 days (range 20 to 35 weeks). Exclusionary associated congenital heart disease was found in 13 [Tetralogy of Fallot with atrioventricular septal defect (5), double outlet right ventricle with pulmonary atresia/stenosis (4), heterotaxy syndrome (3), and variant of hypoplastic left heart syndrome (1)]. Non-diagnostic acoustic windows (8), fetal demise (6), lack of postnatal follow-up (4), and a patient with Trisomy 18 receiving palliative care (2) were also excluded.

Comparison of the ratios of left and right-sided structures and aortic arch measurements with z scores in patients with coarctation of aorta versus no coarctation of aorta is depicted in Table 1. Among the echo measures analysed, proximal transverse aortic arch and isthmus size, left: right atrioventricular valve ratio, and left: right ventricle mid-cavity width were lower in the coarctation group compared to the group with a normal arch. The ratio of aortic:pulmonary valve and ascending aorta:main pulmonary artery diameter was similar in both groups.

On multivariable analysis, the independent predictors of postnatal coarctation of aorta were proximal transverse aortic arch z score and ratio of left:right atrioventricular valve. Retrospectively utilising a combination of proximal transverse aortic arch z score of less than -2 or ratio of left:right atrioventricular valve <0.7, postnatal coarctation of aorta was predicted with 100% sensitivity [95% confidence interval (54 to 100%)] and 89 % specificity [95% CI (78 to 96%)] in our cohort. The positive predictive value was 50% [95% CI 32 to 68%], and the negative predictive value was 100%. The interobserver reproducibility, measured by intraclass correlation, was very good for proximal transverse aortic arch (95%), aortic:pulmonary valve ratio (88%), and left:right atrioventricular valve ratio (81%); fair for left:right ventricle length (78%); and poor for left:right ventricular mid-chamber width (61%) and aortic isthmus (58%) measurements (Table 2). Ductal diameter measurements could not be reliably reproduced.

The peak velocity across the ductus arteriosus, aortic, and pulmonary valves was similar between the two groups. The pulse wave Doppler-derived velocity time integral ratio of flow between the various left and right heart structures (aortic:pulmonary, isthmus:ductus arteriosus) was also similar (Appendix A). There was, however, a negative correlation between pulmonary valve velocity time integral and isthmus z score ($r = 0.35$, $p = 0.03$). Diastolic forward flow in the aortic arch was present in 4 patients in the coarctation of aorta group (66%) and 18 in the normal aortic arch group (32%) (Table 3). The ratio of diastolic:systolic velocity time integral in the aortic arch was similar between patients with coarctation of aorta and normal aortic arch (Appendix A).

Two-dimensional echo features of coarctation of aorta including posterior shelf (3) and subjective displacement of the left subclavian artery (4) were noted in some patients with coarctation of aorta but in none with unobstructed aortic arch (Table 3). Most patients with atrioventricular septal defect did not have significant atrioventricular valve insufficiency; among 54 patients with quantifiable atrioventricular valve insufficiency, four

Table 2. Intraclass correlation coefficient for interobserver variability

Parameter	Intraclass Correlation	95% Confidence Interval		p value
		Lower Bound	Upper Bound	
Proximal transverse aortic arch	0.95	0.803	0.998	0.001
Isthmus	0.58	NA	NA	0.367
Left:right atrioventricular valve ratio	0.81	0.31	0.95	0.007
Aortic: pulmonary valve annulus ratio	0.88	0.54	0.97	0.001
Left:right ventricular length	0.78	0.14	0.95	0.016
Left: right ventricular mid-chamber width	-0.61	NA	NA	0.755
Ascending aorta: Main pulmonary artery	-0.24	NA	NA	0.589

Table 3. Associated cardiac and genetic features in prenatally diagnosed atrioventricular septal defect patients

Parameter	Coarctation (n = 6)	Normal Aortic Arch (n = 56)
Trisomy 21*	4	34
Duodenal atresia*		1
Noonan syndrome PTPN11 gene mutation*	0	1
Ch2q24.3-q33.3 deletion* (multiple skeletal anomalies)	1	0
Common AV valve insufficiency ^	6	48
mild or less	3	45
mild- moderate	2	0
moderate	0	3
moderate-severe	1	0
LSVC to CS		6
Displaced LSCA	4	0
Posterior shelf	3	0
Diastolic flow arch	4	18
Bicuspid aortic valve*	0	3
Left arch aberrant right SCA*	0	6
LSVC to LA*	0	1
Partial/transitional AVSD*	1	6
Parachute Mitral valve*	2	0

*post natal diagnosis.

^ unable to quantify atrioventricular valve insufficiency in eight patients on fetal echocardiogram.

AV = Atrioventricular, LSVC = left superior vena cava, Cs = coronary sinus, LSCA = left subclavian artery, LA = left atrium, AVSD = atrioventricular septal defect.

demonstrated moderate or more (Table 3). Only one patient with moderate or more atrioventricular valve insufficiency had coarctation of aorta. All patients demonstrated appropriate right-to-left shunting across the foramen ovale. There were no fetal arrhythmias. The umbilical artery, umbilical venous, and ductus venosus Doppler patterns were normal except for one patient with a normal aortic arch who had absent diastolic flow in the umbilical artery. Fetal hydrops was noted in one patient with Trisomy 21, who was noted to have right-sided chylous pleural effusion, jaundice, and thrombocytopenia after birth. The infant recovered and successfully underwent atrioventricular septal defect repair. Other associated genetic and cardiac findings are

depicted in Table 3. Amongst all the fetal complete atrioventricular septal defect patients, seven were described after birth as partial or transitional atrioventricular septal defect (atrial septal defect physiology); one of these had an associated coarctation of aorta.

Based on fetal echo reports, coarctation of aorta was suspected in 13 patients prenatally. The fetal cardiologist suspected aortic arch obstruction or noted left:right ventricular size discrepancy on the first echocardiogram in four of the six coarctation of aorta patients. Arch obstruction was noted on a follow-up fetal echocardiogram at 27 weeks gestation in one. Coarctation of aorta was not suspected in one fetus seen at 33 weeks gestation; however, retrospectively applying the criteria of proximal transverse aortic arch z score of less than -2, coarctation of aorta would have been identified in both of these patients on their first fetal echocardiogram at the tertiary centre. Among the 56 patients without coarctation of aorta, eight fetal echo reports noted either suspect coarctation of aorta or left:right ventricular size discrepancy on their first echocardiogram representing a false-positive diagnosis. Among the eight patients with a false-positive prenatal diagnosis of coarctation of aorta, only two had a proximal transverse aortic arch z score of less than -2, and none had a left:right atrioventricular valve ratio <0.7. In our cohort of fetal atrioventricular septal defect patients, retrospectively applying the criteria of either proximal transverse aortic arch z score < -2 or left:right atrioventricular valve <0.7 predicted coarctation of aorta with a sensitivity of 100% (95% CI, 54 to 100%) and specificity of 89% (95% CI, 78 to 96%). The positive predictive value was 50% (95% CI 32 to 68%), and the negative predictive value was 100%.

Discussion

The incidence of coarctation of aorta in atrioventricular septal defect in our cohort (n = 62) was 10%, within the range of previously reported literature of 5–20%. However, in patients with Trisomy 21 and atrioventricular septal defect, we found a higher incidence of coarctation of aorta (11%) compared to a previous report by Weijerman et al. (1%).²⁹ Isolated aortic arch obstruction is even less common in Trisomy 21 patients (0.3 to 7%) with otherwise normal intracardiac anatomy.^{26–28}

Our study attempts to identify prenatal predictors of coarctation of aorta in patients with atrioventricular septal defect, which is vital to facilitate appropriate fetal counselling and delivery planning, including delivery location, as well as, timing and number of expected cardiac surgeries. Prenatal diagnosis of congenital heart disease increases maternal anxiety.^{31,32} Uncertainty has been shown to generate more anxiety in prenatal

counselling than the severity of the abnormality, which emphasises the importance of meticulous, detailed prenatal diagnosis.³³ When the aortic arch is unobstructed, an infant with atrioventricular septal defect is typically discharged from the nursery with cardiology follow-up and referral for surgical repair at 3–6 months of life. However, when aortic arch obstruction is present, repair of coarctation of aorta with or without a pulmonary artery band versus a single-stage complete repair of the atrioventricular septal defect and coarctation of aorta must be considered in the neonatal period.¹⁶

The ideal timing of fetal echocardiography to diagnose coarctation of aorta has yet to be determined. Our study reflects a cohort of patients referred to tertiary referral centres with a median gestational age of 29 weeks. Serial echocardiograms have been demonstrated to improve the accuracy of prenatal diagnosis.³⁴ Our experience supports this as one patient's arch obstruction was not evident until 27 weeks gestation on a follow-up study.

Quartermain *et al.* stressed the importance of serial fetal echo assessment with an evaluation of left:right heart ratios and aortic measurements after 30 weeks gestation to diagnose coarctation of aorta in structurally normal hearts.¹⁸ However, in our cohort, the one patient with coarctation of aorta that was missed had non-diagnostic images at 32 weeks gestation.

Multiple studies have been devoted to the prenatal diagnosis of coarctation of aorta in otherwise structurally normal hearts. Many have utilised direct measurements of the aortic arch, including proximal transverse aortic arch diameter, distal transverse aortic arch diameter, isthmus diameter, isthmus:duct ratio, and distal transverse arch:ductal ratios.^{4,11,17,20,35} Similar to patients with normal intracardiac anatomy, where proximal transverse aortic arch <3 mm was reported to be the most sensitive (94% sensitivity) predictor of coarctation of aorta;¹⁸ proximal transverse aortic arch *z* score was an independent predictor of postnatal coarctation of aorta in our cohort of atrioventricular septal defect patients with excellent reproducibility. Several studies have reported the utility of isthmus measurement in the prenatal diagnosis of coarctation of aorta.^{4,17,20} We also noted smaller isthmus diameter and *z* score in atrioventricular septal defect patients with aortic arch obstruction; however, isthmus diameter could be measured only in 47 of 62 patients retrospectively, and the interobserver reproducibility was poor (Table 2). Due to the insertion of the ductus arteriosus, measurement of the aortic isthmus is technically challenging in any fetus.

A meta-analysis of twelve articles devoted to prenatally predicting coarctation of aorta in otherwise structurally normal hearts demonstrated significant differences in the size of the left versus right heart structures; however, the threshold utilised ranged from 0.6 to 0.7 for the ratios of the various valves, arteries, and chamber measurements.⁴ Previous studies predicting arch obstruction in patients without associated structural abnormalities noted an aortic: pulmonary valve <0.6 and ascending aorta: pulmonary artery <0.65 are predictive of coarctation of aorta.^{4,11,18} In our cohort of atrioventricular septal defect patients, these ratios were not significantly different. The aortic valve and ascending aorta may not be smaller in coarctation patients with a ventricular septal defect. In structurally normal hearts, Quartermain *et al.* found a left:right ventricular mid-chamber ratio of less than 0.6 to be highly sensitive (95%) for the prediction of coarctation of aorta.¹⁸ We also found that ratio of left:right ventricular mid-chamber width was significantly lower in atrioventricular septal defect patients with aortic arch obstruction compared to those with normal aortic arch; however, there was poor interobserver reproducibility. This measurement is challenging to obtain in

the presence of an inlet VSD. In our cohort, the left:right ventricular length ratios were not significantly different, suggesting the left:right atrioventricular valve ratio may be a better tool to assess ventricular size discrepancy in atrioventricular septal defect.

In our cohort of atrioventricular septal defect patients, lower left:right atrioventricular valve ratio (0.64 vs. 0.91, *p* 0.018) was an independent predictor of coarctation of aorta similar to fetal patients with otherwise normal intracardiac anatomy referred for right ventricular to left ventricular size discrepancy, where lower mitral:tricuspid valve ratios (0.55 vs. 0.72, *p* 0.001) were noted in patients with postnatal critical arch obstruction.¹⁸ In a study of repair and outcomes in prenatally diagnosed atrioventricular septal defect, associated left-sided obstructive lesions, such as sub-aortic stenosis, aortic valve hypoplasia with or without coarctation of the aorta, were present in about 30% of right dominant atrioventricular septal defect patients, defined as ratio of left:right atrioventricular valve less than 0.85.¹⁰ Also of interest, the smallest left:right atrioventricular valve ratio to undergo biventricular repair in their report was 0.64.¹⁰ Our study takes this concept a step further, demonstrating that a left:right atrioventricular valve <0.7 predicted coarctation of aorta with good interobserver reproducibility (table 2).

Wang *et al.* reported that the ratio of the aortic isthmus velocity time integral flow during diastole to flow during systole (>0.56) enhances the accuracy using the diagnosis coarctation of aorta in an otherwise structurally normal heart.¹² In our cohort, the presence of diastolic forward flow was seen in four of six (67%) fetuses with coarctation of aorta and 18 of 56 (32%) without coarctation of aorta. The ratio of diastolic to systolic flow (velocity time integral) was similar in both groups; however, we did not have sufficient numbers to determine if this would be a reliable screening tool in patients with atrioventricular septal defect. Persistent diastolic flow in the isthmus has been reported to be a marker of lower resistance in the placental circulation compared to that of the cerebral circulation.³⁰ Hence, this is unlikely to be a useful marker for postnatal arch obstruction. We did observe a negative correlation between pulmonary valve velocity time integral and isthmus *z* score (*r*-0.35, *p*-0.031), which is logical as there is more flow through the pulmonary valve in the setting of aortic arch obstruction. Velocity time integral may be a valuable parameter to study in a larger sample. We did not identify any reported literature using velocity time integral as an associated feature of coarctation of aorta in the fetus. Studies have reported the abnormal direction of atrial shunting as the most specific measure to predict the need for neonatal aortic arch intervention in otherwise structurally normal hearts.¹⁸ None of our fetal atrioventricular septal defect patients with coarctation demonstrated an abnormal direction of atrial shunting; thus, this was not a valuable marker for coarctation of aorta in atrioventricular septal defect patients.

We report the presence of either proximal transverse aortic arch *z* score < -2 or left:right atrioventricular valve <0.7 prenatally predicts coarctation of aorta with a sensitivity of 100% and specificity of 89%. This combination tool with a high sensitivity and specificity for coarctation of aorta may guide delivery location planning in patients with atrioventricular septal defect identifying the 10% with critical arch obstruction in which case delivery in a tertiary centre is recommended.

Study limitations

A relatively smaller sample size limits our study despite inclusion of patients from two institutions. The retrospective nature of the analysis is limited by relying on the quality of the echo images, given that ultrasound techniques have undergone tremendous

improvement in the last decade. Eight patients were excluded from our cohort due to poor acoustic windows, and we could not measure the proximal transverse arch in four of the included patients. Thus when acoustic windows permit, measurement of the proximal transverse arch is reassuring, but this is not always possible. Conducting the study at tertiary referral centres, the time of the initial echocardiogram was dependent on the time of referral. Referrals were later in our cohort than the ideal timing of fetal echo screening (22–24 weeks) and often did not allow serial studies. In addition, postnatal follow-up was not always available. We noted significant variability in the measurement of the ductus arteriosus due to the variable shape of this structure, the lack of standardisation of the measurement site, and the challenge of retrospectively reviewed images. Hence, we were not able to reliably estimate the isthmus: ductus arteriosus ratio. Other classic features of coarctation of aorta, such as diastolic forward flow at the isthmus and posterior shelf, were not reliably present in our patients with coarctation of aorta and atrioventricular septal defect. In addition, we attempted to use the ratio of aortic:pulmonary valve velocity time integral and ascending aorta:main pulmonary artery velocity time integral to evaluate if a flow discrepancy across these structures could predict arch obstruction. However, the flow in aortic and pulmonary outflow tracts appears to be more reflective of differences in downstream resistance in the placental and cerebral circulation than an arch obstruction in our small cohort.

Conclusion

Prenatal diagnosis of coarctation of aorta with or without associated defects remains a challenge in fetal cardiology. However, accurate prenatal diagnosis is essential for effective prenatal counselling in terms of delivery location and timing of surgical interventions. The incidence of coarctation of aorta in our cohort of prenatally diagnosed atrioventricular septal defect patients was 10%. In Trisomy 21 and atrioventricular septal defect, the incidence of coarctation of aorta was 11%. In atrioventricular septal defect, a proximal transverse aortic arch z score < -2 or a left:right atrioventricular valve < 0.7 predicted coarctation of aorta in our retrospective study with high sensitivity, specificity, and negative predictive value. A prospective multicentre study is needed to validate this predictive tool for the prenatal detection of coarctation of aorta in atrioventricular septal defect.

Acknowledgements. We would like to thank our fetal nurse co-ordinators Ms. Cheryl Butler and Ms. Stacey Bryant, and our fetal cardiac sonographers Mr. Barry Gabbert, RDCS, and Mr. Keith Dixon, RDCS, for their contribution with co-ordination of care and excellent imaging essential for prenatal diagnosis.

Financial support. This research received no specific grant from any funding agency, commercial, or not-for-profit sectors.

Competing interests. None.

References

1. Samaanek M. Prevalence at birth, “natural” risk and survival with atrioventricular septal defect. *Cardiol Young* 1991; 1: 285–289.
2. Xie O, Brizard CP, d’Udekem Y, et al. Outcomes of repair of complete atrioventricular septal defect in the current era. *Eur J Cardiothorac Surg* 2014; 45: 610–617.
3. Buysens A, Gyselaers W, Coumans A, et al. Difficult prenatal diagnosis: fetal coarctation. *Facts Views Vis Obgyn* 2012; 4: 230–236.
4. Familiari A, Morlando M, Khalil A, et al. Risk factors for coarctation of the aorta on prenatal ultrasound: a systematic review and meta-analysis. *Circulation* 2017; 135: 772–785.
5. Rosenthal E. Coarctation of the aorta from fetus to adult: curable condition or life long disease process? *Heart* 2005; 91: 1495–1502.
6. Reddy VM, McElhinney DB, Brook MM, Parry AJ, Hanley FL. Atrioventricular valve function after single patch repair of complete atrioventricular septal defect in infancy: how early should repair be attempted? *J Thorac Cardiovasc Surg* 1998; 115: 1032–1040.
7. Redmond JM, Silove ED, De Giovanni JV, et al. Complete atrioventricular septal defects: the influence of associated cardiac anomalies on surgical management and outcome. *Eur J Cardiothorac Surg* 1996; 10: 991–995.
8. Prifti E, Bonacchi M, Bernabei M, et al. Repair of complete atrioventricular septal defects in patients weighing less than 5 kg. *Ann Thorac Surg* 2004; 77: 1717–1726.
9. Suzuki T, Bove EL, Devaney EJ, et al. Results of definitive repair of complete atrioventricular septal defect in neonates and infants. *Ann Thorac Surg* 2008; 86: 596–602.
10. Beaton AZ, Pike JJ, Stallings C, Donofrio MT. Predictors of repair and outcome in prenatally diagnosed atrioventricular septal defects. *J Am Soc Echocardiogr* 2013; 26: 208–216.
11. Beattie M, Peyvandi S, Ganesan S, Moon-Grady A. Toward improving the fetal diagnosis of coarctation of the aorta. *Pediatr Cardiol* 2017; 38: 344–352.
12. Wang H, Lei W, Liu J, Yang B, Li H, Huang D. The diastolic and systolic velocity-time integral ratio of the aortic isthmus Is a sensitive indicator of aortic coarctation in fetuses. *J Am Soc Echocardiogr* 2019; 32: 1470–1476.
13. Donofrio MT, Moon-Grady AJ, Hornberger LK, et al. Diagnosis and treatment of fetal cardiac disease: a scientific statement from the American heart association. *Circulation* 2014; 129: 2183–2242.
14. Sanapo L, Pruetz JD, Slodki M, Goens MB, Moon-Grady AJ, Donofrio MT. Fetal echocardiography for planning perinatal and delivery room care of neonates with congenital heart disease. *Echocardiography* 2017; 34: 1804–1821.
15. Donofrio MT. Predicting the future: delivery room planning of congenital heart disease diagnosed by fetal echocardiography. *Am J Perinatol* 2018; 35: 549–552.
16. Shuhaiber J, Shin AY, Gossett JG, et al. Surgical management of neonatal atrioventricular septal defect with aortic arch obstruction. *Ann Thorac Surg* 2013; 95: 2071–2077.
17. Matsui H, Mellander M, Roughton M, Jicinska H, Gardiner HM. Morphological and physiological predictors of fetal aortic coarctation. *Circulation* 2008; 118: 1793–1801.
18. Quartermain MD, Cohen MS, Dominguez TE, Tian Z, Donaghue DD, Rychik J. Left ventricle to right ventricle size discrepancy in the fetus: the presence of critical congenital heart disease can be reliably predicted. *J Am Soc Echocardiogr* 2009; 22: 1296–1301.
19. Rudolph AM. Distribution and regulation of blood flow in the fetal and neonatal lamb. *Circ Res* 1985; 57: 811–821.
20. Hornberger LK, Weintraub RG, Pesonen E, et al. Echocardiographic study of the morphology and growth of the aortic arch in the human fetus. observations related to the prenatal diagnosis of coarctation. *Circulation* 1992; 86: 741–747.
21. Rychik J, Ayres N, Cuneo B, et al. American society of echocardiography guidelines and standards for performance of the fetal echocardiogram. *J Am Soc Echocardiogr* 2004; 17: 803–810.
22. Anderson RH, Wessels A, Vettukattil JJ. Morphology and morphogenesis of atrioventricular septal defect with common atrioventricular junction. *World J Pediatr Congenit Heart Surg*. 2010; 1: 59–67.
23. Cetta Frank, Dongngan Truong LLuann, Minich etal, Defects Atrioventricular Septal. Moss and Adams’ Heart Disease in Infants, Children, and Adolescents. Ninth edn. Lippincott Williams & Wilkins, Pennsylvania, 2016, 758
24. Center BCsHH. Z-score calculator. Available at: <https://zscore.chboston.org/>.
25. Degenhardt K. Embryology of the Cardiovascular System. Fetal Cardiovascular Imaging: A Disease-Based Approach. 1st edn. Elsevier, Amsterdam, 2011.
26. Tan M, Xu C, Sim SK, Seow AL, Tan TH, Quek SC. Types and distribution of congenital heart defects associated with trisomy 21 in Singapore. *J Paediatr Child Health* 2013; 49: 223–227.
27. Stoll C, Dott B, Alembik Y, Roth MP. Associated congenital anomalies among cases with Down syndrome. *Eur J Med Genet* 2015; 58: 674–680.

28. Mikkelsen M, Poulsen H, Nielsen KG. Incidence, survival, and mortality in Down syndrome in Denmark. *Am J Med Genet Suppl* 1990; 7: 75–78†
29. Weijerman ME, van Furth AM, van der Mooren MD, et al. Prevalence of congenital heart defects and persistent pulmonary hypertension of the neonate with Down syndrome. *Eur J Pediatr* 2010; 169: 1195–1199.
30. Rychik J. The Fetal Cardiovascular Examination. *Fetal Cardiovascular Imaging: A Disease-Based Approach*. 1st edn. Elsevier, Amsterdam, 2011.
31. Sklansky M, Tang A, Levy D, et al. Maternal psychological impact of fetal echocardiography. *J Am Soc Echocardiogr* 2002; 15: 159–166.
32. Rychik J, Donaghue DD, Levy S, et al. Maternal psychological stress after prenatal diagnosis of congenital heart disease. *J Pediatr* 2013; 162: 302–7 e1.
33. Aite L, Zaccara A, Trucchi A, et al. When uncertainty generates more anxiety than severity: the prenatal experience with cystic adenomatoid malformation of the lung. *J Perinat Med* 2009; 37: 539–542.
34. Mozumdar N, Rowland J, Pan S, et al. Diagnostic accuracy of fetal echocardiography in congenital heart disease. *J Am Soc Echocardiogr* 2020; 33: 1384–1390.
35. Vigneswaran TV, Zidere V, Chivers S, et al. Impact of prospective measurement of outflow tracts in prediction of coarctation of the aorta. *Ultrasound Obstet Gynecol* 2020; 56: 850–856.

Appendix

Appendix A: Comparison of Doppler parameters in the patients with and without coarctation of aorta

Parameter	Coarctation of aorta	Normal aortic arch	<i>p</i> value
AoV: PV VTI median (IQR 25 th to 75 th %ile)	0.93 (0.65 to 1.17)	1.0 (0.76 to 1.25)	0.562
Arch: Duct VTI median (IQR 25 th to 75 th %ile)	0.67 (0.42 to 0.98)	0.76 (0.45 to 0.97)	0.803
Arch diastolic:systolic VTI median (IQR 25 th to 75 th %ile)*	0.25 (0.19 to 0.48)	0.29 (0.21 to 0.38)	0.733

AoV = aortic valve, PV = pulmonary valve, arch- aortic arch, duct-ductus arteriosus, VTI = velocity time integral. **n* = 22.