

# Vaccine-Induced Myocarditis in Two Intern Doctors in the Same Night Shift

Mustafa Emin Canakci, MD;<sup>1</sup> Omer Erdem Sevik, MD;<sup>1</sup> Gokhan Dereli, MD;<sup>1</sup> Kadir Ugur Mert, Assoc. Prof., MD;<sup>2</sup> Nurdan Acar, Prof, MD<sup>1</sup>

1. Emergency Department, Eskisehir Osmangazi University, Eskisehir, Turkey
2. Cardiology Department, Eskisehir Osmangazi University, Eskisehir, Turkey

## Correspondence:

Mustafa Emin Canakci, MD  
Emergency Department  
Eskisehir Osmangazi University School of  
Medicine  
Eskisehir, Turkey  
Prof. Dr. Nabi Avci Boulevard,  
No:4, Meselik, Odunpazari, 26040  
E-mail: [mustafaeminc@gmail.com](mailto:mustafaeminc@gmail.com)

**Conflicts of interest/funding:** The authors whose names are listed certify that they have NO affiliations with or involvement in any organization or entity with any financial interest (such as honoraria; educational grants; participation in speakers' bureaus; membership, employment, consultancies, stock ownership, or other equity interest; and expert testimony or patent-licensing arrangements), or non-financial interest (such as personal or professional relationships, affiliations, knowledge, or beliefs) in the subject matter or materials discussed in this manuscript. This research did not receive any specific grant from funding agencies in the public, commercial, or not-for-profit sectors.

**Keywords:** COVID-19; mRNA; myocarditis; vaccine

## Abbreviations:

COVID-19: coronavirus disease 2019  
ECG: electrocardiogram  
ED: emergency department  
ICU: intensive care unit  
POCUS: point-of-care ultrasonography  
SARS-CoV-2: severe acute respiratory syndrome coronavirus 2

Received: May 17, 2022

Accepted: June 16, 2022

doi:[10.1017/S1049023X22001078](https://doi.org/10.1017/S1049023X22001078)

© The Author(s), 2022. Published by Cambridge University Press on behalf of the World Association for Disaster and Emergency Medicine.

## Abstract

The coronavirus disease 2019 (COVID-19) pandemic has affected millions of people around the globe and vaccines against the disease have started to develop. Side effects of the vaccine have been reported in the literature, including myocarditis, which has a very low incidence and with a good prognosis. This case report aims to present two medical students' vaccine-induced myocarditis cases after the first doses of BNT162b2.

These patients were young males with no previous medical history and both of them had good recovery after the disease. Both of them had their vaccine very recently before the event. These cases show that myocarditis can be seen after the first dose as well.

Global vaccination is the most effective prevention method against COVID-19. Considering the fact that morbidities after the disease occur more than the side effects of the vaccine, they are still the best option against the current pandemic.

Canakci ME, Sevik OE, Dereli G, Mert KU, Acar N. Vaccine-induced myocarditis in two intern doctors in the same night shift. *Prehosp Disaster Med.* 2022;37(5):698–700.

## Introduction

Severe acute respiratory syndrome coronavirus 2 (SARS-CoV-2) is the pathogen that is responsible for coronavirus disease 2019 (COVID-19) which emerged in Wuhan, China in the year 2019. In a short while, COVID-19 became a pandemic and affected millions of people around the globe causing mortalities and various morbidities. Vaccines against the disease started to develop quickly, and on August 23, 2021,<sup>1</sup> Comirnaty, Pfizer-BioNTech's (New York USA) COVID-19 vaccine (also known as BNT162b2) was given Food and Drug Administration (FDA; Silver Spring, Maryland USA) approval for public use. While rare and most of them being mild, side effects of the vaccine have been reported in the literature, including myocarditis.<sup>2</sup> This case study aims to present two vaccine-induced myocarditis cases after administration of the first doses of BNT162b2.

Two sixth-year medical students with no known previous medical history complained about palpitations and chest pain during their night shift. They had their first dose of BNT162b2 two and four days prior.

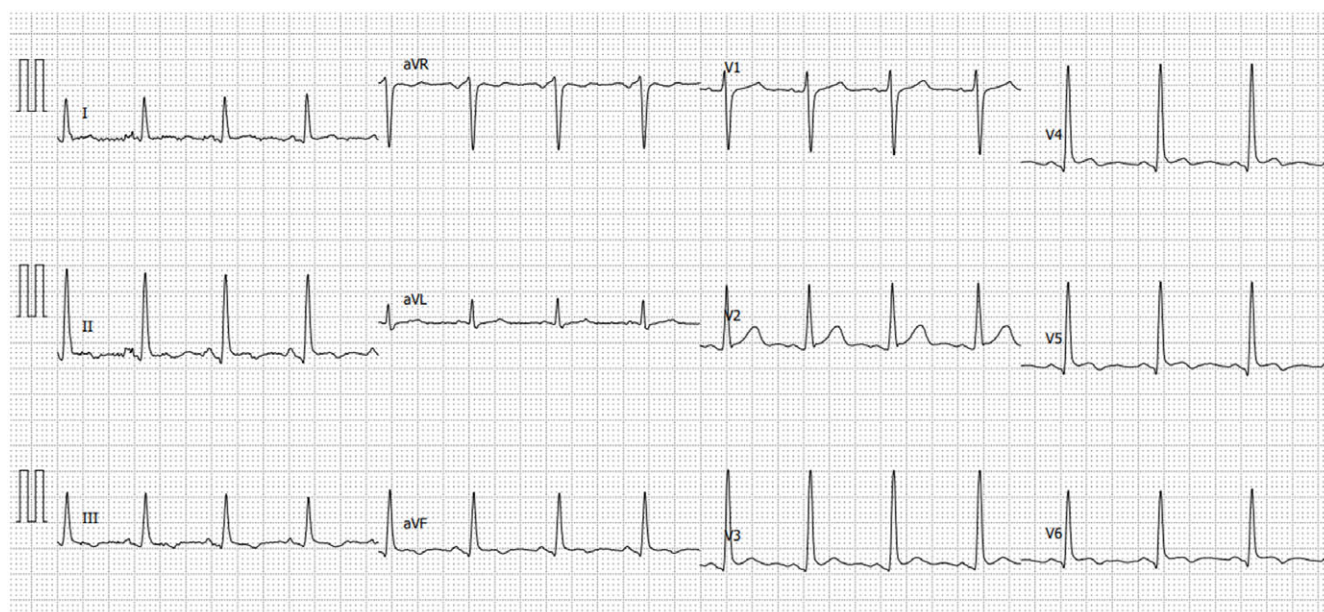
## Case Presentations

### Case 1

A previously healthy, non-smoker, 23-years-old male complaining about palpitations that were on-going for 24-hours was presented to the emergency department (ED). He explained palpitations were episodic and worse when lying down. He denied any chest pain, shortness of breath, or any other related symptoms. He had no family history of cardiac disease. The patient received his first dose of BNT162b2 48-hours prior.

Patient's vitals were as follows: arterial blood pressure: 112/80mmHg; heart rate: 112bpm; oxygen saturation: 98% on room air; and temperature: 36.6°C. Physical examination revealed no remarkable abnormalities. His electrocardiogram (ECG) showed global T-wave inversions, sinus tachycardia, and ST-segment elevations in V2-6, D1, D2, D3, and P-R segment depressions in precordial derivations (Figure 1). Point-of-care ultrasonography (POCUS) showed no pericardial fluid, no wall motion abnormalities, and no valvular defects with an ejection fraction (EF) of 60%.

His laboratory evaluation showed high-sensitive cardiac troponin T (hs-cTnT) levels elevated at 1.45ng/mL (normal range: 0.000-0.014ng/mL) and normal renal function tests. The patient was admitted to the coronary intensive care unit (ICU) for close monitoring and treatment with acute coronary syndrome and myocarditis pre-diagnoses. He was treated



Canakci © 2022 Prehospital and Disaster Medicine

**Figure 1.** Electrocardiogram of Patient 1.

with Metoprolol and Ibuprofen. Twelve hours after admission, he started to complain about sharp, stabbing-like chest pain. Serial ECGs revealed no difference from the first one.

After three days of treatment, his hs-cTnT levels were down to 0.056ng/mL. He was discharged with Ibuprofen and Metoprolol. On discharge, the patient's ECG had T-wave inversions in all precordial derivations.

#### Case 2

A previously healthy, 24-years-old male who was on the same night shift with Patient 1 and was admitted to the ED complaining about chest pain which he described as “squeezing” which was on-going for two days. His vital parameters were normal and he had no family history of cardiac disease. He received the first dose of BNT162b2 four days prior. Physical examination was normal. Patient 2's ECG showed an incomplete right bundle branch block without any significant ST-segment changes (Figure 2). His blood panel revealed relatively lower but still high hs-cTnT as 0.065ng/mL and no other significant findings. His POCUS showed no abnormalities. This patient was also admitted to the coronary ICU for observation and further testing. He was discharged with full recovery after two days of observation and symptomatic treatment. His ECG remained the same throughout his stay and his final hs-cTnT value was 0.013ng/mL.

The changes in hs-cTnT values in time are given in Figure 3.

#### Discussion

Risk of developing myocarditis after vaccination is very low. In the literature, self-limited cases with good prognoses have been reported.<sup>2</sup> The second patient was admitted four days after the vaccine, and this might explain the relatively lower hs-cTnT levels on admission. Pathophysiology is not fully known, but studies suggest that immunological reactions play a central role in myocardial damage. Vaccines are the only effective prevention method in the current pandemic. Post-vaccine adverse events, most of them being mild symptoms such as fatigue, fever, headache, and myalgia, have been reported.<sup>3</sup> The mechanism of vaccine-induced

myocarditis is also not known, but it is thought that it may be related to the mRNA sequence which codes the spike protein of SARS-CoV-2 or the systemic immune reaction against the injected material. In a study by Witberg, et al, the incidence of myocarditis after BNT162b2 vaccination has been reported as 5.49/100.000 (95% CI, 3.59-7.39) for both sexes and 10.69/100.000 (95% CI, 6.93-14.46) for males between 16 and 29 years of age.<sup>4</sup> These patients were also young males which is in line with the literature. Studies suggest that fulminant myocarditis incidences are low compared to milder cases which have a better prognosis. But still, patients who present with similar symptoms after the vaccination should be evaluated for myocarditis as well as other possible fatal diseases. Also, most of the reported cases are after the second dose of the vaccine. These cases show that myocarditis can be seen after the first dose as well.

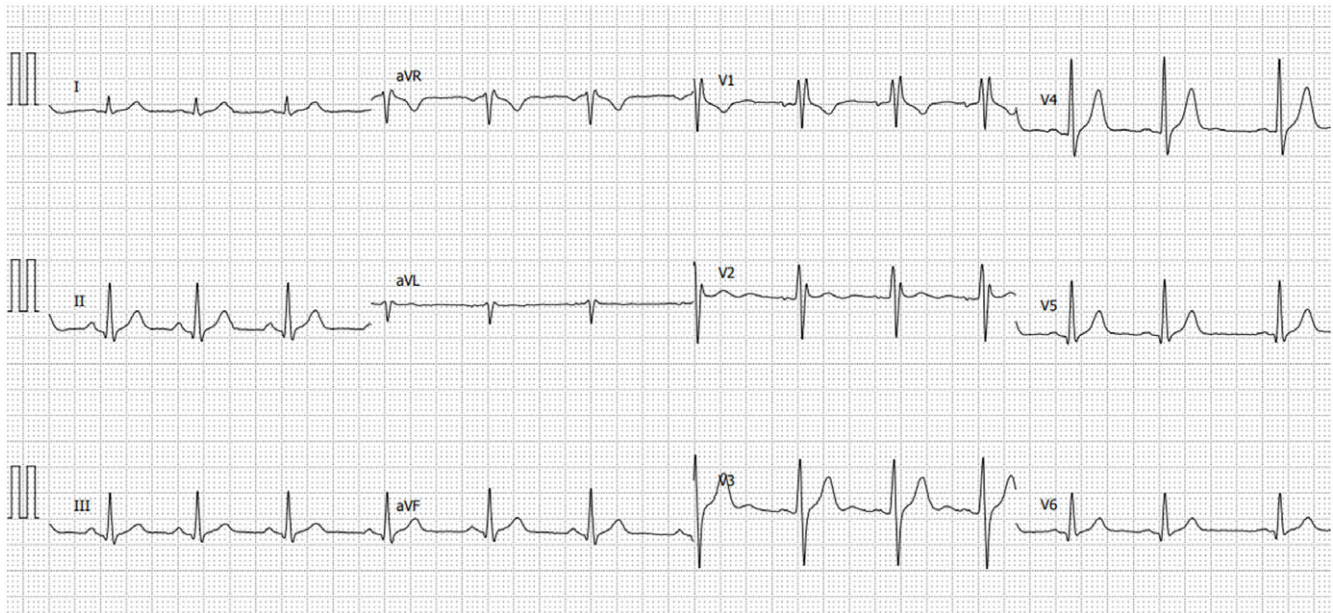
A recent meta-analysis by Ling, et al shows that vaccine-induced myocarditis case rates are similar among various vaccines, even higher in small-pox vaccines. This study also shows that mRNA vaccines for COVID-19 have higher rates of vaccine-induced myocarditis.<sup>5</sup>

Some of the latest research on animals also suggests that intravenous delivery of the vaccine might also be responsible for myocarditis. Although there are no reports that are made in the vaccine center for wrongful delivery of the BNT162b2, administrators should be careful to deliver the vaccine content directly into the muscle. The piston-pulling method could be useful to achieve the desired effect.<sup>6</sup>

#### Conclusion

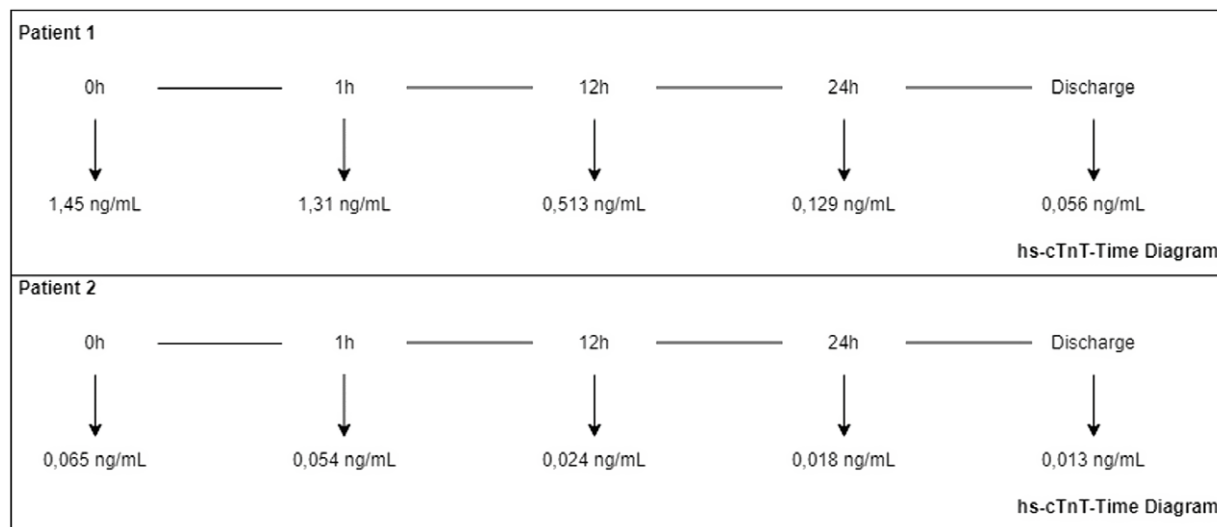
A high vaccination rate is the only solution that is available today to eradicate SARS-CoV-2 and tackle the pandemic. Most of the time, vaccine-induced myocarditis is self-limiting and has a good prognosis. These cases also did not have ventricular dysfunction or long-term effects and healed within a few days. Considering the fact that morbidities after COVID-19 occur more than after the vaccine itself, vaccines are still the best option today.





Canakci © 2022 Prehospital and Disaster Medicine

Figure 2. Electrocardiogram of Patient 2.



Canakci © 2022 Prehospital and Disaster Medicine

Figure 3. Timeline Diagram of Troponin Levels.

### References

- Food and Drug Administration. <https://www.fda.gov/emergency-preparedness-and-response/coronavirus-disease-2019-covid-19/comirnaty-and-pfizer-biontech-covid-19-vaccine>. Accessed April 23, 2022.
- Mevorach D, Anis E, Cedar N, et al. Myocarditis after BNT162b2 mRNA vaccine against COVID-19 in Israel. *N Engl J Med*. 2021;385(23):2140–2149.
- Meo SA, Bukhari IA, Akram J, Meo AS, Klonoff DC. COVID-19 vaccines: comparison of biological, pharmacological characteristics and adverse effects of Pfizer/BioNTech and Moderna vaccines. *Eur Rev Med Pharmacol Sci*. 2021;25(3):1663–1669.
- Witberg G, Barda N, Hoss S, et al. Myocarditis after COVID-19 vaccination in a large health care organization. *N Engl J Med*. 2021;385(23):2132–2139.
- Li C, Chen Y, Zhao Y, et al. Intravenous injection of coronavirus disease 2019 (COVID-19) mRNA vaccine can induce acute myopericarditis in mouse model. *Clin Infect Dis*. 2022;74(11):1933–1950.
- Ling RR, Ramanathan K, Tan FL, et al. Myopericarditis following COVID-19 vaccination and non-COVID-19 vaccination: a systematic review and meta-analysis. *Lancet Respir Med*. 2022;10(7):679–688.