

Grisel's syndrome: a rare complication of tonsillectomy

K J SIA¹, I P TANG¹, C K L KONG², A NASRIAH²

¹ORL Department, Faculty of Medicine, University of Malaya, Kuala Lumpur, Malaysia, and

²Department of Diagnostic Imaging, Sibu Hospital, Sarawak, Malaysia

Abstract

Objectives: To discuss the pathophysiology of atlanto-axial subluxation as a rare complication of tonsillectomy, and to discuss the important radiological findings for diagnosis and treatment planning.

Case report: We report a case of post-tonsillectomy atlanto-axial subluxation, also known as Grisel's syndrome, in a child. On the third day after surgery, the boy presented with torticollis with no neurological deficit. Rotatory atlanto-axial subluxation was clearly shown in computed tomography scans of the neck. Cervical traction for one week successfully reduced the subluxation, with no long-term sequelae.

Conclusion: Pre-existing cervical ligamentous laxity and post-operative infection are believed to be the main causes of Grisel's syndrome. Although it is rare, patients are advised to seek treatment early if any neck pain or fever persists. Early diagnosis is important for better treatment outcome. Initial conservative measures are advised before more invasive cervical traction is adopted.

Key words: Grisel's Syndrome; Atlanto-Axial Subluxation; Complication, Postoperative; Tonsillectomy; Torticollis

Introduction

Grisel's syndrome, also known as non-traumatic atlanto-axial rotatory subluxation, is a rare complication of head and neck surgery seen most commonly in the paediatric population. It was named after Dr P Grisel, who in 1930 first described the condition in a child with pharyngeal ulcer.¹

The pathophysiology of this rare complication is of interest. A two-part hypothesis has been proposed by Battiatia and Pazos: a pre-existing cervical ligamentous laxity with superimposed soft tissue inflammation weakens the transverse and alar ligaments of the atlanto-axial joint.² The neck manipulation involved in head and neck surgery is believed to be a contributory factor, especially in syndromic children who have ligamentous laxity.

Here, we report a case of Grisel's syndrome in a seven-year-old boy who presented with post-tonsillectomy torticollis.

Case report

A seven-year-old boy was admitted for tonsillectomy due to recurrent tonsillitis. He was otherwise healthy, with no other medical illness. Pre-operative assessment was unremarkable.

An uneventful tonsillectomy was performed. The boy was placed in the Rose position during the operation. His neck was extended and his head supported by a head ring. Modest bipolar electrocautery was used.

The patient was discharged well on the day after surgery.

One week later, the boy presented to our clinic with torticollis, with his chin tilted to the left. On the third day after surgery, he had complained of neck pain and limited neck movement, which had become progressively more disabling. He had no fever or limb weakness.

On examination, the tonsillar fossae were fairly clean with no signs of infection. Marked torticollis was seen, with tenderness on palpation.

Tonsil tissue culture showed no growth of micro-organisms.

A cervical plain radiograph (Figure 1) taken in the open-mouth view showed an obvious odonto-lateral mass interval asymmetry, with the odontoid process tilted to the left.

Urgent computed tomography of the cervical spine was performed. This showed Fielding class one atlanto-axial rotatory subluxation (with no anterior or posterior displacement of the atlas).³ The atlas was rotated to the left (Figure 2). The anterior atlanto-dental interval was 3.0 mm, which was normal. The lateral atlanto-dental interval was asymmetrical, measuring 5.4 mm on the right side and 3.5 mm on the left. The coronal view revealed an upward tilt of the left lateral mass of the atlas (Figure 3). There was no displacement of other cervical vertebrae, and no fracture was noted.

The patient was diagnosed with post-tonsillectomy Grisel's syndrome.

He was treated with a soft cervical collar, analgesics, antibiotics and a muscle relaxant. After two weeks, there was no improvement so he was hospitalised and received cervical traction for one week, followed by further six weeks with a

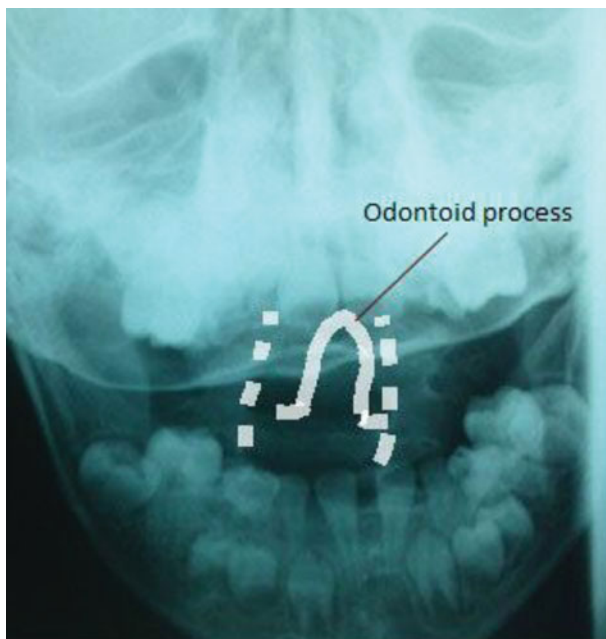


FIG. 1

Plain radiograph, open mouth odontoid view, showing asymmetry of the odonto-lateral mass intervals and tilting of the odontoid process to the left.

soft cervical collar. The torticollis gradually reduced, and the patient regained full neck movement after two months.

Repeated computed tomography after this treatment showed significant joint reduction, which correlated with the patient's marked clinical improvement.

After a year of follow up the patient had fully recovered and was discharged from care.

Discussion

Post-tonsillectomy non-traumatic atlanto-axial subluxation, also known as Grisel's syndrome, has been documented in several case reports. Grisel's syndrome is a rare clinical entity which primarily affects the paediatric population.⁴

The aetiology of this potentially catastrophic condition mainly comprises upper respiratory infections and

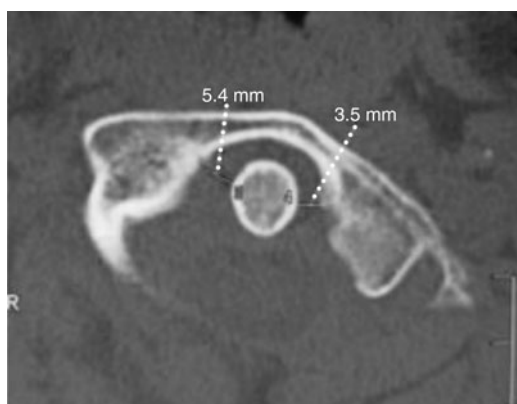


FIG. 2

axial computed tomography scan showing that the anterior atlanto-dental interval measures 3.0 mm (i.e. within the normal range). The atlas is rotated to the left. There is asymmetry of the lateral atlanto-dental intervals, which measure 5.4 mm on the right and 3.5 mm on the left.

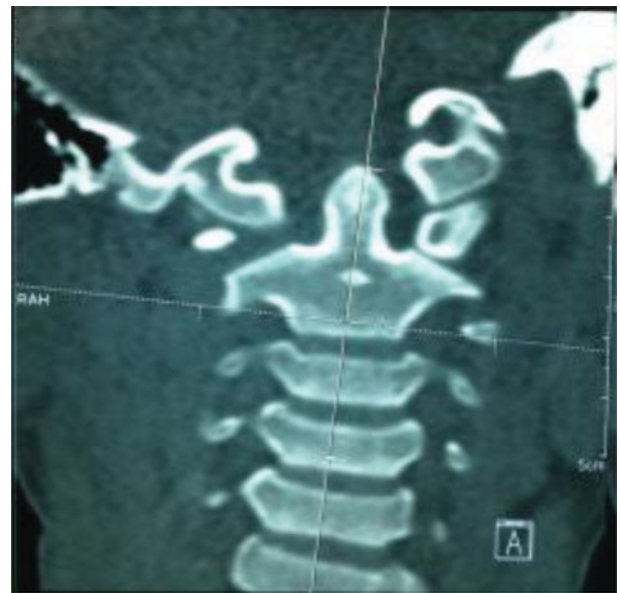


FIG. 3

Coronal computed tomography scan showing marked deviation of the odontoid process to the left, with upward tilt of the left lateral mass of the atlas.

complications of head and neck procedures.^{5,6} A historical, 1830 case report by Bell described the autopsy of a patient who suffered from atlanto-axial subluxation as a result of syphilitic pharyngeal ulcer; the autopsy revealed erosion of the transverse ligament of the axis.⁷ Other infectious processes reported in Grisel's syndrome cases include pharyngitis, tonsillitis or adenoiditis, retropharyngeal or tonsillar abscess, mastoiditis, otitis media, and cervical adenitis.⁴

The pathophysiology of Grisel's syndrome has been postulated in two hypotheses.

The first proposes that pre-existing ligamentous laxity and instability of the atlanto-axial joint predispose the patient to cervical vertebral ligamentous injury during head and neck surgery which requires prolonged neck manipulation.⁴ Trisomy 21 is a classic example of a syndrome involving ligamentous laxity which confers a high risk of atlanto-axial subluxation. In some children, the atlanto-dental interval may reach 4.0 mm, compared with 2.5–3.0 mm in adults.⁸ This condition results in hypermobility and instability of the atlanto-axial joint.

Neck extension in the Rose position during tonsillectomy is thought to carry a risk of ligamentous injury. However, our patient's head and shoulders were supported during this procedure, sparing the neck from weight-bearing. Furthermore, the operation was brief and uncomplicated. At present, there is debate over whether neck manipulation in head and neck surgery can constitute the main cause of atlanto-axial subluxation.

The second hypothesis holds that peripharyngeal infection, in the form of a septic exudate from the operative field or other sources in the upper respiratory tract, travels via the pharyngo-vertebral veins to the periodontal venous plexus.⁶ Haematogenous spread to the upper cervical spine causes hyperaemic decalcification of the first and second cervical vertebrae and weakening of ligaments, leading to pathological rotation of the atlanto-axial joint. Inflammatory mediators are carried to the cervical muscle, where they induce spasm and subsequent joint subluxation.

Our patient did not show any signs of a septic condition post-operatively. Neither his clinical condition nor his tonsillar microbial cultures showed any sign of infection. However, subtle pharyngeal infection can have a subclinical presentation which is unnoticeable.

- **Post-operative infection and pre-existing cervical ligamentous laxity predispose to atlanto-axial subluxation after tonsillectomy**
- **Vigilance is needed in cases of post-tonsillectomy torticollis**
- **Computed tomography is needed for early diagnosis, evaluation and treatment**
- **Early treatment helps to improve outcomes**

The use of bipolar diathermy is believed sometimes to cause local thermal injury and to contribute to local wound infection.⁹ We advocate post-operative prophylactic oral antibiotics for patients who have undergone tonsillectomy with extensive electrocautery. However, the rationale of routine post-operative use of antibiotics is still debatable.

Battiata and Pazos had proposed a 'two-hit' hypothesis for Grisel's syndrome.² Pre-existing cervical ligamentous laxity in the paediatric population acts as the first 'hit'. A subsequent local infectious process acts as the second hit, leading to muscular spasm, weakening of the transverse and alar ligaments, and eventually to atlanto-axial subluxation as described earlier.

Patients receiving early diagnosis and treatment have been shown to have a better prognosis than those with delayed management.^{10–12} An initial two-week trial of cervical immobilisation with a soft cervical collar, together with anti-inflammatory drugs and muscle relaxants, can be attempted. However, if there is no clinical improvement after conservative management, cervical traction and physiotherapy should be initiated.¹³ Surgery and closed reduction are recommended if these measures fail.⁵

Conclusion

Grisel's syndrome is a rare condition which should be suspected in a patient with signs of post-operative infection (e.g. fever and tonsillar fossa bleeding) and prolonged neck pain. Patients should be warned before discharge that torticollis ('wryneck') is a warning sign which should prompt them to seek medical help. In cases of torticollis, early investigation for atlanto-axial rotatory subluxation should not be delayed. An early computed tomography scan is crucial to

establish the diagnosis and to determine the best treatment modality, before the complication worsens. Although Grisel's syndrome is not common, clinicians must be aware of this potentially catastrophic complication of routine head and neck surgery.

References

- 1 Grisel P. Enucleation of the atlas and nasopharyngeal torticollis [in French]. *La Presse Med* 1930;**38**:50–3
- 2 Battiata AP, Pazos G. Grisel's syndrome: the two hits hypothesis. *Ear Nose Throat J* 2004;**83**:553–5
- 3 Fielding JW, Hawkins RJ. Atlanto-axial rotatory fixation. *J Bone Joint Surg Am* 1977;**59**:37–44
- 4 Wilson BC, Jarvis BL, Haydon RC 3rd. Nontraumatic subluxation of the atlantoaxial joint: Grisel's syndrome. *Ann Otol Rhinol Laryngol* 1987;**96**:705–8
- 5 Karkos PD, Benton J, Leong S, Mushi E, Sivaji N, Assimakopoulos D. Grisel's syndrome in otolaryngology: a systemic review. *Int J Pediatric Otorhinolaryngol* 2007;**71**:1823–7
- 6 Parke WW, Rothman RH, Brown MD. The pharyngovertebral veins: an anatomical rationale for Grisel's syndrome. *J Bone Joint Surg* 1984;**66**:568–74
- 7 Bell C. *The Nervous System of the Human Body, Embracing the Papers Delivered to the Royal Society on the Subject of the Nerves*. London: Longmans, 1830;403
- 8 Jackson H. The diagnosis of minimal atlanto-axial subluxation. *Brit J Radiol* 1950;**23**:672–4
- 9 Lakeisha RH, Thomas JG, Eric AM. Does increased electrocautery during adenoidectomy lead to neck pain? *Otolaryngol Head Neck Surg* 2005;**133**:556–61
- 10 Harma A, Firat Y. Grisel syndrome: nontraumatic atlantoaxial rotatory subluxation. *J Craniofac Surg* 2008;**19**:1119–21
- 11 Byeoknyeon K, Keiko I, Kenji S, Shogo S, Yoshiaki E, Hironaka T *et al*. Significance of prevention and early treatment of a postoperative twisted neck: atlantoaxial rotatory subluxation after head and neck surgery. *J Anesth* 2010;**24**:598–602
- 12 Martinez-Lage JF, Morales T, Fernandez Cornejo V. Atlanto-axial rotatory subluxation in children: early management. *Acta Neurochir* 2001;**143**:1223–8
- 13 Deichmueller CMC, Welkoborsky HJ. Grisel's syndrome – a rare complication following "small" operations and infections in the ENT region. *Eur Arch Otorhinolaryngol* 2010;**267**:1467–73

Address for correspondence:

Dr Kian Joo Sia,
14A, Lorong 4A, Jalan Pipit,
96000 Sibul,
Sarawak, Malaysia

Fax: +60 82419495
E-mail: kj_sia@yahoo.com

Dr K J Sia takes responsibility for the integrity of the content of the paper
Competing interests: None declared
