

# Posterior myocardial infarction with isolated ST elevations in V8 and V9: Is this an “ST elevation MI”?

Lance Brown, MD, MPH;<sup>\*†</sup> Jessica Sims, MD;<sup>†</sup> Alessandra Conforto, MD<sup>†</sup>

## ABSTRACT

We report a case of a 53-year-old man whose first manifestation of coronary artery disease was an acute isolated posterior myocardial infarction (IPMI). Acute IPMI is relatively uncommon and predominantly due to occlusion of the left circumflex coronary artery. IPMI is challenging to diagnose due to the absence of ST segment elevation on a standard 12-lead electrocardiogram (ECG) even in the setting of total coronary artery occlusion and transmural (Q-wave) infarct. We discuss the diagnostic implications of the absence of tall R waves in leads V1 and V2 on this patient's ECG. The utility of posterior leads (V7 through V9) is demonstrated. The controversy surrounding the use of thrombolytic therapy or primary angioplasty in the setting of acute IPMI without ST segment elevation on a standard 12-lead ECG is reviewed.

**Key words:** posterior myocardial infarction, posterior ECG leads, emergency department

## RÉSUMÉ

Nous présentons le cas d'un homme âgé de 53 ans dont les premières manifestations d'insuffisance coronarienne prirent la forme d'un infarctus du myocarde postérieur isolé. Ce type d'infarctus est relativement rare et est causé principalement par l'occlusion du rameau circonflexe de l'artère coronaire gauche. Le diagnostic de l'infarctus postérieur représente un défi en raison de l'absence d'une augmentation du segment ST sur un électrocardiogramme standard à 12 dérivations (ECG), même en présence d'une occlusion totale de l'artère coronaire et d'un infarctus transmural (onde Q de nécrose). Nous discutons des implications de l'absence d'ondes R longues dans les dérivations V1 et V2 sur l'ECG de ce patient. L'utilité des dérivations postérieures (V7 à V9) est démontrée. La controverse entourant le recours à la thérapie thrombolytique ou à l'angioplastie primaire en présence d'un infarctus du myocarde postérieur isolé sans élévation du segment ST sur un ECG standard à 12 dérivations est passée en revue.

## Introduction

The posterior aspect of the left ventricle is typically supplied by the left circumflex coronary artery<sup>1</sup> and is a challenging area of the heart in which to identify acute ischemia and infarction. During acute transmural myocardial infarction (MI), the characteristic ST-segment elevations seen in other areas of the heart are not seen in isolated pos-

terior myocardial infarctions (IPMI) on standard 12-lead electrocardiograms (ECGs).<sup>1,2</sup> If acute transmural IPMI were identified promptly in the emergency department (ED), these patients could be considered for thrombolytic therapy or immediate interventional cardiac catheterization.<sup>3-6</sup> A few techniques have been developed to identify IPMI, including the use of posterior leads V7, V8 and V9,<sup>3-10</sup> body surface mapping,<sup>11,12</sup> and the development of

From the \*Emergency Department, Loma Linda University Medical Center, Loma Linda, Calif.; and the †Emergency Department, Los Angeles County Medical Center/Keck School of Medicine of the University of Southern California, Los Angeles, Calif.

Received: July 17, 2002; final submission: Aug. 27, 2002; accepted: Sept. 15, 2002

*This article has been peer reviewed.*

specific 12-lead ECG criteria other than ST elevation.<sup>13–15</sup> Papers from the pre-thrombolytic era<sup>14,15</sup> and a recent consensus report from the American College of Cardiology that was endorsed by the American College of Emergency Physicians<sup>16</sup> use the presence of tall R waves (typically defined as an R/S ratio  $\geq 1$ <sup>17</sup>) in ECG leads V1 and V2 to define posterior MI. We present a case of an acute IPMI in which the ECG lacked tall R waves in leads V1 and V2. The use of posterior leads identified ST-segment elevation that changed patient management resulting in the patient going promptly to the cardiac catheterization laboratory.

## Narrative

A 53-year-old Russian-speaking man presented to the ED (accompanied by his son, who translated for him) by private auto. He had a 4½-hour history of chest pain radiating to both arms. The onset of chest pain occurred while walking and was not relieved by rest. Associated symptoms included shortness of breath, nausea and diaphoresis. The patient's only past medical history was of hypertension, for which he was taking losartan. He was taking no other medications. He had a 30 pack-year smoking history.

Initial vital signs revealed blood pressure 177/102 mm Hg, pulse 72 beats/min, respiratory rate 20 breaths/min and a normal body temperature. His initial ECG showed downsloping ST depression most prominently in leads V1 through V4 (Fig. 1) and a tall R wave in lead V3, but not in leads V1 or V2. Prompted by the ST depression and typical presentation for MI, a reading for posterior leads V7 through V9 (15-lead ECG) was immediately obtained and demonstrated ST elevations (Fig. 1). Standard management including oxygen, aspirin, morphine sulfate, intravenous nitroglycerin and heparin was initiated. A cardiology consultation was obtained, and the

patient was taken promptly to the cardiac catheterization laboratory. Troponin I and other laboratory values were pending at that time.

Cardiac catheterization revealed total occlusion of the left circumflex artery, a normal left main coronary artery, a normal right coronary artery, a 60% proximal lesion of a small branch of the circumflex artery and luminal irregularities in the left anterior descending coronary artery. The patient underwent uncomplicated stenting of the left circumflex artery. A subsequent echocardiogram identified moderate to severe posterior wall hypokinesis and was otherwise unremarkable. The patient's initial troponin I level was 1.4 ng/mL (CTNI Enzyme Immunoassay, Dade Behring, Inc., Newark, Del.; laboratory reference range 0.0–1.2 ng/mL) with a peak of 172 ng/mL 7 hours after presentation. Five hours after presentation a single CK measurement was obtained and was 3730 U/L with a CK-MB of 191 ng/mL (relative index 5.1%). The only complication identified during hospitalization was a single uncomplicated episode of hematemesis. The patient otherwise did well and was discharged home on hospital day 4.

## Discussion

Our patient presented with an acute IPMI without ST elevation on the 12-lead ECG or tall R waves in V1 or V2. ST depressions in V1 and V2 and an upright T wave in V2 were present. ST elevations were only present in leads V8 and V9. The true incidence of IPMI is unknown but has been reported as 7% (3 of 46),<sup>18</sup> 0% (0 of 13),<sup>9</sup> 12% (4 of 34),<sup>6</sup> 4% (23 of 544)<sup>13</sup> and 3% (7 of 210)<sup>7</sup> of patients with acute MI when posterior leads V7 through V9 were obtained.

Identifying patients with IPMI utilizing the standard 12-lead ECG may be challenging.<sup>1,2,10,12–14</sup> Due to the location of the myocardial injury, ST-segment elevations that would

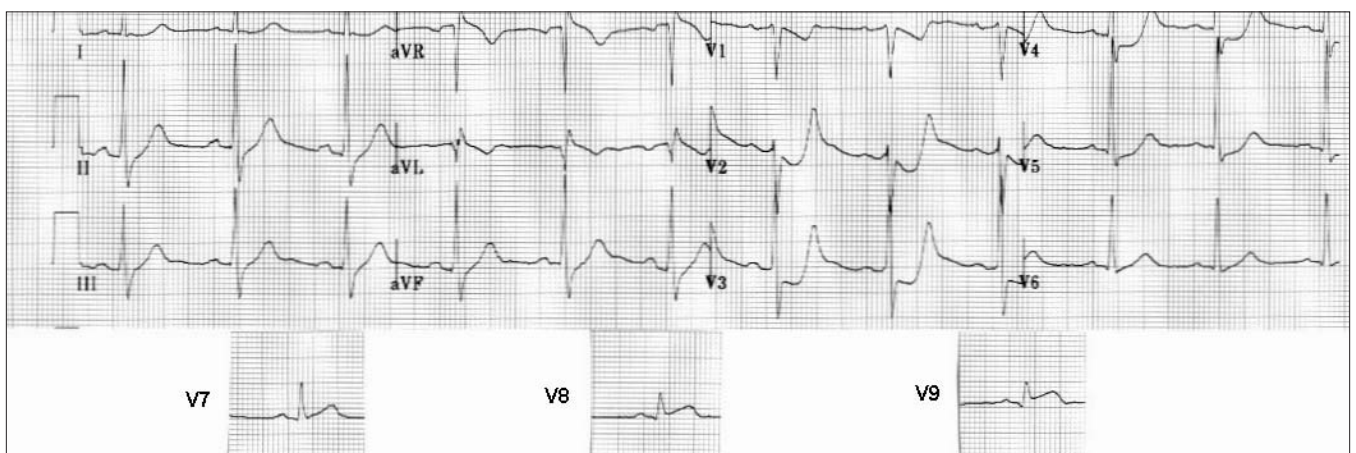


Fig. 1. ECG of a 53-year-old man with isolated posterior myocardial infarction.

typically be associated with total coronary artery occlusion and MI are directed away from the leads of the standard 12-lead ECG.<sup>1,2,14</sup> Because of this, efforts to develop criteria other than ST elevation for the identification of IPMI have been made. Some of these criteria were initially developed in the 1960s, but included few acute infarctions.<sup>14,15</sup> Current diagnostic criteria for acute IPMI include: horizontal ST-segment depression, tall R waves, and prominent upright T waves in V1, V2 and/or V3.<sup>1,2</sup> Our case demonstrated downsloping ST segments and lacked tall R waves in V1 and V2. An upright T wave in V2 and a tall R wave in V3 were present. It has been suggested that tall R waves in anterior leads (V1, V2 and V3) are simply the electrical equivalent of Q waves in the posterior leads (V7, V8 and V9).<sup>1,2</sup> If this were the case, these two findings would always occur simultaneously on a 15-lead ECG (a 12-lead ECG + posterior leads). In a study of 18 patients with isolated posterior-lead ST elevation, Agarwal and coworkers reported anterior R waves in 8 patients and posterior Q waves in 8 patients, but both findings in only 4 patients.<sup>3</sup> The correlation between anterior R waves, posterior Q waves, and the time course of their development in IPMI needs further study.

Posterior leads can display the anticipated ST-segment elevations associated with IPMI and coronary artery occlusion (predominantly the circumflex artery).<sup>3,4</sup> There is, however, limited data as to the performance of posterior leads in clinical practice with regard to false-positive and false-negative findings. Zalensky and cohorts reported on 533 patients  $\geq 35$  years of age who presented to the ED with chest pain suggestive of ischemia or infarction and who were admitted to a cardiac care unit.<sup>6</sup> All patients had standard 12-lead ECGs and 15-lead ECGs. There were 345 patients with MIs and 188 patients who were determined to not have had an MI. Although the IPMI cases were not tabulated separately, 34 of 345 (10%) of the MI patients had posterior-lead ST elevation and 3 of 188 (2%) of the patients who did not have MI had posterior-lead ST elevation. Zalensky and cohorts summarized the performance of posterior leads in appropriately identifying patients with MI: sensitivity 60%, specificity of 89%, positive predictive value 91%, negative predictive value 55%, accuracy 70%. Patients in this study were 15 to 21 times more likely to have acute MI if there were ST elevations in the posterior leads than if there were no ST elevations on any ECG. This analysis may be influenced by the definition of pathologic ST elevation (0.5 mm or 1 mm) in the posterior leads.<sup>6,19</sup> Posterior leads may also be helpful in identifying acute IPMI in patients less likely to present with chest pain or in a "typical" fashion.<sup>20,21</sup> Few physicians, however, seem to

use posterior leads in their clinical practice. In a survey of Canadian physicians, only 11% of cardiologists and 9% of emergency physicians routinely use posterior leads.<sup>22</sup>

The optimal treatment of IPMI is currently unknown. Studies of thrombolysis in acute MI typically only include 12-lead ECGs.<sup>23,24</sup> The GISSI study looked at 450 patients with suspected MI and ST depression and reported a higher mortality if these patients were treated with streptokinase than if they were treated with placebo.<sup>23</sup> Patients with suspected MI and ST depression, however, are a heterogeneous group that includes patients with non-Q wave MI, unstable angina, noncardiac chest pain and IPMI.<sup>25</sup> In contrast to the GISSI findings, Langer and colleagues reported a thrombolytic benefit for patients with non-Q wave MI (as defined on the 12-lead ECG) with  $>2$  mm ST depression and presentation  $>6$  hours after symptom onset.<sup>26</sup> Unfortunately, this study did not separately report the findings of patients with ST depression isolated to the anterior leads. The benefit demonstrated in this study may be due to inclusion of cases with total circumflex coronary artery occlusion.<sup>25</sup> Some effort has been made to differentiate IPMI from other causes of ST depression on a 12-lead ECG. Localization of the maximum ST depression in lead V2 or V3 has a reported sensitivity of 96% and specificity of 70% for identifying ischemia due to left circumflex artery occlusion.<sup>27</sup> The total mass of myocardium lost in IPMI with circumflex artery occlusion is less than in other anatomic distributions (notably anterior MI).<sup>5</sup> It would be expected that these smaller MIs would be associated with a relatively lower mortality than larger areas of infarction.<sup>5</sup> Although survival is not the only important outcome measure, it has been estimated that a study of  $>10\,000$  subjects would be needed to demonstrate a survival advantage in treating patients with IPMI with thrombolytics.<sup>5,28</sup> No study including this many IPMIs has been performed. Although still unresolved, a survey of Canadian physicians revealed that 89% of cardiologists and 78% of emergency physicians would administer thrombolytics to a patient who had isolated posterior-lead ST elevation.<sup>22</sup>

It is one of the major goals in the ED to identify patients who may benefit from thrombolysis or immediate interventional angiography. This case reveals some of the relatively subtle findings on standard 12-lead ECG that are suggestive of IPMI. This case also demonstrates the utility of posterior leads in identifying ST elevation in the setting of IPMI. Future studies may better define the role of acute reperfusion therapy in the setting of IPMI with isolated ST-segment elevations in the posterior leads.

**Competing interests:** None declared.

**Acknowledgements:** Financial support was provided by departmental funds.

## References

1. Brady WJ. Acute posterior wall myocardial infarction: electrocardiographic manifestations. *Am J Emerg Med* 1998;16:409-13.
2. Brady WJ, Erling B, Pollack M, Chan TC. Electrocardiographic manifestations: acute posterior wall myocardial infarction. *J Emerg Med* 2001;20:391-401.
3. Agarwal JB, Khaw K, Aurignac F, LoCurto A. Importance of posterior chest leads in patients with suspected myocardial infarction, but nondiagnostic, routine 12-lead electrocardiogram. *Am J Cardiol* 1999;83:323-6.
4. Matetzky S, Freimark D, Feinberg MS, Novikov I, Rath S, Rabinowitz B, et al. Acute myocardial infarction with isolated ST-segment elevation in posterior chest leads V7-9: "Hidden" ST-segment elevations revealing acute posterior infarction. *J Am Coll Cardiol* 1999;34:748-53.
5. O'Keefe JH, Sayed-Taha K, Gibson W, Christian TF, Bateman TM, Gibbons RJ. Do patients with left circumflex coronary artery-related acute myocardial infarction without ST-segment elevation benefit from reperfusion therapy? *Am J Cardiol* 1995;75:718-20.
6. Zalenski RJ, Cooke D, Rydman R, Sloan EP, Murphy DG. Assessing the diagnostic value of an ECG containing leads V4R, V8, and V9: the 15-lead ECG. *Ann Emerg Med* 1993;22:786-93.
7. Oraii S, Maleki M, Tavakolian AA, Eftekharzadeh M, Kamanfar F, Mirhaji P. Prevalence and outcome of ST-segment elevation in posterior electrocardiographic leads during acute myocardial infarction. *J Electrocardiol* 1999;32:275-8.
8. Khaw K, Moyeyra AE, Tannenbaum AK, Hosler MN, Brewer TJ, Agarwal JB. Improved detection of posterior myocardial wall ischemia with the 15-lead electrocardiogram. *Am Heart J* 1999;138:934-40.
9. Brady WJ, Hwang V, Sullivan R, Chang N, Beagle C, Carter CT, et al. A comparison of 12- and 15-lead ECGs in ED chest pain patients. Impact on diagnosis, therapy, and disposition. *Am J Emerg Med* 2000;18:239-43.
10. Rich MW, Imburgia M, King TR, Fischer KC, Kovach KL. Electrocardiographic diagnosis of remote posterior wall myocardial infarction using unipolar posterior lead V9. *Chest* 1989;96:489-93.
11. Wung SF, Lux RL, Drew BJ. Thoracic location of the lead with maximal ST-segment deviation during posterior and right ventricular ischemia: comparison of 18-lead ECG with 192 estimated body surface leads. *J Electrocardiol* 2000;33:167-74.
12. Menown IBA, Allen J, Anderson JM, Adgey AA. ST depression only on the initial 12-lead ECG: early diagnosis of acute myocardial infarction. *Eur Heart J* 2001;22:218-27.
13. Boden WE, Kleiger RE, Gibson RS, Schwartz DJ, Schechtman KB, Capone RJ, et al. Electrocardiographic evolution of posterior acute myocardial infarction: importance of early precordial ST-segment depression. *Am J Cardiol* 1987;59:782-7.
14. Perloff JK. The recognition of strictly posterior myocardial infarction by conventional scalar electrocardiography. *Circulation* 1964;30:706-18.
15. Seyal MS, Swiryn S. True posterior myocardial infarction. *Arch Intern Med* 1983;143:983-5.
16. Cannon CP, Battler A, Brindis RG, Cox JL, Ellis SG, Every NR, et al. American College of Cardiology key data elements and definitions for measuring the clinical management and outcomes of patients with acute coronary syndromes. A report of the American College of Cardiology Task Force on Clinical Data Standards (Acute Coronary Syndrome Writing Committee). *J Am Coll Cardiol* 2001;38:2114-30.
17. Mattu A, Brady WJ, Perron AD, Robinson DA. Prominent R wave in lead V1: electrocardiographic differential diagnosis. *Am J Emerg Med* 2001;19:504-13.
18. Melendez LJ, Jones DT, Salcedo JR. Usefulness of three additional electrocardiographic chest leads (V7, V8 and V9) in the diagnosis of acute myocardial infarction. *CMAJ* 1978;119:745-8.
19. Wung SF, Drew BJ. New electrocardiographic criteria for posterior wall acute myocardial ischemia validated by a percutaneous transluminal coronary angioplasty model of acute myocardial infarction. *Am J Cardiol* 2001;87:970-4.
20. Gupta M, Tabas JA, Kohn MA. Presenting complaint among patients with myocardial infarction who present to an urban, public hospital emergency department. *Ann Emerg Med* 2002;40:180-6.
21. Gibler WB, Armstrong PW, Ohman EM, Weaver WD, Stebbins AL, Gore JM, et al. Persistence of delays in presentation and treatment for patients with acute myocardial infarction: The GUSTO-I and GUSTO-III experience. *Ann Emerg Med* 2002;39:123-30.
22. Novak PG, Davies C, Gin KG. Survey of British Columbia cardiologists' and emergency physicians' practice of using nonstandard ECG leads (V4R to V6R and V7 to V9) in the diagnosis and treatment of acute myocardial infarction. *Can J Cardiol* 1999;15:967-72.
23. Gruppo Italiano per lo Studio della Streptochinasi nell'Infarto Miocardico (GISSI). Effectiveness of intravenous thrombolytic treatment in acute myocardial infarction. *Lancet* 1986;1:397-401.
24. Second International Study of Infarct Survival (ISIS-2) Collaborative Group. Randomized trial of intravenous streptokinase, oral aspirin, both, or neither among 17,187 cases of suspected acute myocardial infarction: ISIS-2. *Lancet* 1988;2:349-60.
25. Braunwald E, Cannon CP. Non-Q wave and ST segment depression myocardial infarction: Is there a role for thrombolytic therapy? [editorial]. *J Am Coll Cardiol* 1996;27:1333-4.
26. Langer A, Goodman SG, Topol EJ, Charlesworth A, Skene AM, Wilcox RG, et al. Late assessment of thrombolytic efficacy (LATE) study: prognosis in patients with non-Q wave myocardial infarction. *J Am Coll Cardiol* 1996;27:1327-32.
27. Shah A, Wagner SG, Green CL, Crater SW, Sawchak ST, Wildermann NM, et al. Electrocardiographic differentiation of the ST-segment depression of acute myocardial injury due to the left circumflex artery occlusion from that of myocardial ischemia of nonocclusive etiologies. *Am J Cardiol* 1997;80:512-3.
28. Midgette AS, O'Connor GT, Baron JA, Bell J. Effect of intravenous streptokinase on early mortality in patients with suspected acute myocardial infarction. *Ann Intern Med* 1990;113:961-8.

**Correspondence to:** Dr. Lance Brown, Department of Emergency Medicine A-108, Loma Linda University Medical Center, 11234 Anderson St., Loma Linda CA 92354 USA; 909 558-4344, fax 909 558-0121, LBrownMD@aol.com