

Grey matter correlates of minor physical anomalies in the ÆSOP first-episode psychosis study

K. DEAN, P. FEARON, K. MORGAN, G. HUTCHINSON, K. ORR, X. CHITNIS, J. SUCKLING, R. MALLETT, J. LEFF, P. B. JONES, R. M. MURRAY and P. DAZZAN

Background Minor physical anomalies are more prevalent among people with psychosis. This supports a neurodevelopmental aetiology for psychotic disorders, since these anomalies and the brain are both ectodermally derived. However, little is understood about the brain regions implicated in this association.

Aims To examine the relationship between minor physical anomalies and grey matter structure in a sample of patients with first-episode psychosis.

Method Sixty patients underwent assessment of minor physical anomalies with the Lane scale. High-resolution magnetic resonance images and voxel-based methods of image analysis were used to investigate brain structure in these patients.

Results The total anomalies score was associated with a grey matter reduction in the prefrontal cortex and precuneus and with a grey matter excess in the basal ganglia, thalamus and lingual gyrus.

Conclusions Minor physical anomalies in a sample of patients with first-episode psychosis are associated with regional grey matter changes. These regional changes may be important in the pathogenesis of psychotic disorder.

Declaration of interest None.

Minor physical anomalies are subtle defects of the head, face, hands and feet resulting from ectodermal maldevelopment during early pregnancy. Patients with schizophrenia have an excess of such anomalies (McGrath *et al*, 1995; Ismail *et al*, 2000), supporting a neurodevelopmental facet to schizophrenia because the brain, too, has an ectodermal origin. Few studies have examined the neuroanatomical correlates of minor physical anomalies (Table 1). Most use only gross brain volumetric measures, so obscuring associations with subtle structural brain changes. These studies also rely on a scale not designed for assessment of physical anomalies in psychotic disorders but instead derived from a study of behaviour in young children (Waldrop & Halverson, 1971). The Waldrop scale is also arguably limited by being restricted to only 18 items, lacking precise definitions, having low sensitivity and being subjective in nature (Lane *et al*, 1997).

We examined minor physical anomalies and cerebral grey matter in a sample of patients with first-episode psychosis, using high-resolution magnetic resonance imaging (MRI) and voxel-based image analysis to evaluate the entire brain for subtle differences at a subregional level, and a bespoke minor physical anomaly scale for schizophrenia which is procedurally exacting and defines the topography of anomalies previously reported in individuals with schizophrenia (Lane *et al*, 1997). We predicted associations between anomalies and grey matter volume in cortical and subcortical regions thought to be important in the pathogenesis of psychosis.

METHOD

Sample

Participants were recruited as part of the London arm of a large epidemiological study, the Aetiology and Ethnicity in Schizophrenia and Other Psychoses (ÆSOP)

study, which investigated the incidence of schizophrenia in three English cities (Dazzan *et al*, 2004, 2005). As part of this study, we approached all individuals aged 16–65 years resident in a defined area of south London who consecutively presented for the first time to the local psychiatric services with a functional psychotic illness (ICD-10 codes F10–19, excluding coding F1x.0 for acute intoxication; F20–29 and F30–39, psychotic codings; World Health Organization, 1992) over a 3-year period. Exclusion criteria were:

- (a) a history of head trauma resulting in loss of consciousness for over 1 h;
- (b) the presence of a disease of the central nervous system;
- (c) poor fluency in English;
- (d) transient psychotic symptoms resulting from acute intoxication (as defined by ICD-10) following the administration of alcohol or other psychoactive substance.

Of the 191 persons who participated in the study, 127 were in contact with services long enough to complete the minor physical anomaly (MPA) assessment. Of these participants, 60 also had an MRI scan. In the light of potential participation bias in our study, we compared these individuals with those who did not undergo an MRI examination. The 60 participants were younger (mean age 27.1 years, *s.d.*=7.2, *v.* 35.3 years, *s.d.*=12.9, *t*-test $P < 0.001$) and more likely to be White than African-Caribbean or African ($\chi^2 P = 0.013$), but were otherwise comparable with those not participating in the MRI assessment in terms of gender, social class, diagnosis and total MPA score. We also recruited 43 neighbourhood control participants matched for age, gender and ethnicity. This control group was mainly used for the purpose of weighting the MPA scale (see below). Ethical approval for the study was granted by the ethics committee of the Institute of Psychiatry, and the participants gave written informed consent.

Clinical and physical assessments

We interviewed patients with the Schedules for Clinical Assessment in Neuropsychiatry (SCAN; World Health Organization, 1994). We made a diagnosis according to ICD-10 criteria by consensus in meetings involving senior clinicians (R.M.M. or J.L.) in which all clinical information was presented. A total symptom score was

Table 1 Minor physical anomalies and brain imaging in schizophrenia

Reference	Sample	MPA scale	Imaging	Comments
Buckley <i>et al</i> (1994)	28 prevalent cases with schizophrenia; 20 staff volunteers	Waldrop	¹ H-MRS of the left temporal and frontal lobes	Minor physical anomalies of the head more prominent in cases with gross structural abnormalities (mainly of the ventricular system); MPAs of the head also associated with reduced frontal creatinine on MRS (similar results with total MPAs but less robust)
McGrath <i>et al</i> (1995)	157 patients with psychosis taken from the Camberwell Collaborative Psychosis Study sample	Waldrop	Axial computed tomography	Total lateral ventricular volume and maximum area of the third ventricle were not associated with MPAs
O'Callaghan <i>et al</i> (1995)	47 patients with prevalent schizophrenia; 24 controls	Waldrop	MRI	Total MPA scores were unrelated to measures of ventricular volume; marked ventricular system abnormalities on MRI were found for 4 patients who also had high total MPA scores
McNeil <i>et al</i> (2000)	22 monozygotic twin pairs discordant for schizophrenia/schizoaffective disorder	Waldrop	MRI	Signs of brain abnormality in the ill twin (small hippocampi, large ventricles) were not significantly related to MPAs
Muramatsu <i>et al</i> (2000)	74 in-patients with schizophrenia and 53 controls	Waldrop	Computed tomography	Those with schizophrenia and high MPA scores had significantly smaller brain size than those with lower MPA scores
Hata <i>et al</i> (2003)	27 patients with a diagnosis of schizophrenia made before the age of 18 years	Waldrop	MRI	Positive correlation between ventricular brain ratio on MRI and MPA scores

MPA, minor physical anomaly; MRI, magnetic resonance imaging; MRS, magnetic resonance spectroscopy.

obtained by summing the SCAN individual symptom item scores as per Wing & Sturt's (1978) procedure for the Present State Examination (PSE; Wing *et al*, 1974). The premorbid IQ was estimated with the National Adult Reading Test (NART; Nelson & Willison, 1991). Ethnicity was self-ascribed by participants at interview, and duration of untreated illness was defined as the time between first psychotic symptom and presentation to services. Neurological soft signs were assessed using the Neurological Evaluation Scale (Buchanan & Heinrichs, 1989). From clinical notes we calculated the duration of antipsychotic exposure in weeks and the daily antipsychotic doses at the time of anomaly assessment, converted into chlorpromazine equivalents (Bazire, 1998; Taylor *et al*, 1999; Bezchlibnyk-Butler & Jeffries, 2000).

We assessed the participants' minor physical anomalies as soon as possible after initial presentation with an abridged version of the Lane scale (Lane *et al*, 1997), which contains 62 qualitative measures of the head and face. The scale includes an extensive assessment of facial symmetry

and identifies a range of specific dysmorphic features such as the presence of epicanthic folds and cleft-like defects. Each individual dysmorphic feature included in the scale is operationalised as a categorical or ordinal score. All assessments for both cases and controls were performed by trained examiners. We conducted assessments of reliability between these examiners on a random subgroup of the sample and found agreement on scores for individual anomalies to be between 95% and 100%. In order to calculate an overall MPA score for each participant, weightings were derived from the control sample ($n=43$). As in previous studies using the Lane scale, the most common variant for each individual anomaly measure in the control sample was assigned a score of 0 (i.e. normal) and any other variant of the measure was assigned a score of 1 (reflecting the presence of an anomaly; McGrath *et al*, 2002). We also examined the result of this weighting procedure for each anomaly to confirm its face validity. This definition of 'anomaly' for each individual measure was then applied to the patient

group such that the most common variant of each measure in the control group was assigned a score of 0 when present among those in the patient group and any other variant was assigned a score of 1. A total MPA score for the patient group and the control group was then calculated by adding all the scores for individual anomaly measures (62 in total) on the scale. The theoretical maximum total MPA score is thus 62. We were then able to examine the relationship between brain structure on MRI and total MPA score among the 60 patients.

Statistical analysis

Analyses were performed using the Statistical Package for the Social Sciences, version 11.0 for Windows. Descriptive statistics were generated for both cases and controls. Associations between total MPA score and putative confounding factors (clinical and demographic) were assessed using *t*-tests and linear regression where appropriate. Linear regression was also employed to examine the relationship

between total MPA score and MRI volumetric measures.

Structural image acquisition

Scans were acquired with a General Electric Signa 1.5 T system (GE Medical Systems, Milwaukee, Wisconsin, USA), at the Maudsley Hospital, London. Contiguous, interleaved proton-density and T_2 -weighted images, each 3 mm thick, were acquired in the coronal plane, to provide whole brain coverage. A repetition time of 4000 ms and effective echo times of 20 ms and 85 ms were used with an eight-echo train length. The matrix size was 256×192 , collected from a rectangular field-of-view of $22 \text{ cm} \times 16.5 \text{ cm}$, giving an in-plane resolution of 0.859 mm. The total acquisition time was 10 min 12 s.

Structural image processing

The methods used for segmentation and registration of each fast spin echo data-set have been described in detail elsewhere (Bullmore *et al.*, 1999; Suckling *et al.*, 1999a,b). Briefly, extracerebral tissues were initially removed, using an automated algorithm. Manual editing of the skull-stripped images was necessary only to remove brain-stem and cerebellum from the cerebral hemispheres and diencephalon. The probability of each intracerebral voxel belonging to each of four possible tissue classes (grey matter, white matter, cerebrospinal fluid or dura/vasculature) was then estimated with a modified fuzzy clustering algorithm (Suckling *et al.*, 1999a). This type of segmentation assigns to each voxel a value in the range 0–1 indicating the fraction of the voxel represented by each tissue type (for example, a grey matter value of 0.7 means that 70% of the tissue represented by that voxel is grey matter).

A template image in the standard space of Talairach & Tournoux (1988) was constructed using a landmark procedure with the AFNI program (Cox, 1996) from six proton-density images acquired from six healthy individuals and then averaging these images. Maps of tissue distribution were then registered onto the template by first registering each proton density image using a 12-parameter affine registration, minimising the grey-level difference between images. This registration aligns all the images together, scaling them to the same gross dimensions. The derived mapping was then applied to the corresponding tissue maps.

At each voxel in standard space the total MPA score was regressed onto the estimated grey matter volume. The test statistic calculated was the regression coefficient divided by its standard deviation to generate an effect map. Permutation testing was used to assess statistical significance, and regional relationships were tested at the level of voxel clusters (Bullmore *et al.*, 1999; Sigmundsson *et al.*, 2001). Given that structural brain changes are likely to extend over a number of contiguous voxels, test statistics that incorporate spatial information, such as three-dimensional cluster mass (the sum of suprathreshold voxel statistics), are generally more powerful than other possible test statistics, which are informed only by data at a single voxel. Initially, the effect map was thresholded at $P < 0.05$ using a critical value obtained from a null distribution sample by recalculation of the test statistic after appropriate permutation of the MPA score, to simulate the conditions under the null hypothesis. Suprathreshold three-dimensional voxel cluster mass (sum of the test statistics within a cluster) was tested against the corresponding null distribution sampled by the equivalent processing of effect maps following permutation. We corrected the statistical threshold for cluster significance in all analyses so that the expected number of false positive clusters (P value times number of tests) was less than 1.

RESULTS

Socio-demographic and clinical characteristics of the sample and the global brain volumes of the patient group are shown in Table 2. The total MPA score for the 60 patients was normally distributed, with a mean of 14.58 and a standard deviation of 6.84. As expected, the control group had a much lower mean MPA score than the patient group (6.28, s.d.=2.75), with the difference being statistically significant ($P < 0.0001$, t -test). Of the 62 anomalies included in the total score, abnormalities in the patient group were most commonly noted in relation to the mouth, ears and general facial symmetry. The most frequently noted anomalies included the following: abnormal plate shape (58%), attached earlobes (67% right, 60% left), abnormality of the anterior surface of the ear (37% right, 47% left), position of ear canals not level (30% right and left),

paired facial structures not level (43%) and face asymmetrical (40%). Some anomalies were also noted in relation to eyebrows, eyes and nose with less frequency.

Anomalies score and demographic and clinical characteristics

The mean total MPA score did not vary significantly by gender, diagnostic category within psychosis, ethnic group or type of medication prescribed (Table 3). Total MPA score was positively associated with total symptom score ($P=0.05$) but not significantly associated with age, duration of untreated psychosis, years of education, IQ, neurological soft signs score or current antipsychotic dosage.

Relationship between anomalies and brain structure

With regard to global brain volume, there was no association between MPA score and total grey matter, white matter or cerebrospinal fluid volume. At a regional level, total MPA score was associated with three clusters of grey matter deficit and four clusters of grey matter excess ($P \leq 0.002$; Table 4, Fig. 1). The first grey matter deficit cluster was centred on the right superior and medial frontal gyri (Brodmann area 6); the second deficit was centred on the same region of the left frontal lobe and the third deficit was centred on the right precuneus extending on the right superiorly to the postcentral gyrus and paracentral lobule; this cluster also extended across the midline to involve similar regions in the left hemisphere and extended laterally into the left inferior parietal lobule.

Of the four clusters of grey matter excess (Table 4, Fig. 1), the first was centred on the left lentiform nucleus and the second on the same region of the right hemisphere. The third cluster was centred on the left thalamus and extended inferiorly into the pulvinar, and the fourth was centred on the right lingual gyrus (Brodmann area 18).

We explored the potential role of antipsychotic medication in explaining the association between MPA and the volume of each of the individual clusters identified. We found that adjustment for current dosage, type or duration of antipsychotic treatment did not significantly alter any of the associations between total MPA score and cluster volume. Controlling additionally for the effect of total symptom score

Table 2 Socio-demographic, clinical and gross brain morphological characteristics of the sample

Characteristic	Patients (n=60)	Controls (n=43)
Gender, n (%)		
Male	36 (60)	22 (51)
Female	24 (40)	21 (49)
Diagnosis, n (%)		
Schizophrenia, schizoaffective disorder	31 (52)	
Other psychosis	29 (48)	
Ethnicity, n (%)		
White British	24 (40)	20 (46)
African–Caribbean	27 (45)	18 (42)
Other	9 (15)	5 (12)
Age, years: mean (s.d.)	27.13 (7.24)	32.33 (10.57)
Education, years: mean (s.d.)	13.11 (2.52)	13.26 (2.74)
IQ: mean (s.d.)	99.29 (15.55)	107.92 (12.16)
Duration of untreated illness, weeks		
Mean (s.d.)	30.51 (59.18)	
Median	7.43	
Total symptom score: mean (s.d.)	31.49 (17.25)	
Total NES soft signs score: mean (s.d.)	8.56 (8.17)	4.62 (3.34)
Current antipsychotic dosage (chlorpromazine equivalents) mg: mean (s.d.)	168.58 (191.96)	
Brain volumes, cm ³ : mean (s.d.)		
White matter	467.08 (48.59)	
Grey matter	572.28 (57.8)	
CSF	154.32 (29.32)	
Total MPA score: mean (s.d.)	14.58 (6.84)	6.28 (2.75)

CSF, cerebrospinal fluid; MPA, minor physical anomaly; NES, Neurological Evaluation Scale.

did not alter these findings, despite the significant relationship found between MPA score and symptoms.

DISCUSSION

In a sample of individuals with first-episode psychosis, we have shown that total MPA score is associated with a reduction of grey matter volume in the prefrontal cortex and precuneus, and with an excess of grey matter volume in the basal ganglia, thalamus and lingual gyrus.

The main strength of our study lies in the fact that it is the first examination of the relationship between minor physical anomalies and brain structure that moves beyond gross brain volume measures. Furthermore, we have employed a scale for the assessment of anomalies which was specifically designed for use in patients with psychosis, and have evaluated a sample drawn from a population-based first-episode group. As there are only a few previous studies linking brain imaging

and minor physical anomalies, and all have used only global measures of brain structure, comparison between our results and earlier findings is limited. However, as in our study, most existing studies did not find any significant association between gross measures of total brain or ventricular volume and minor physical anomalies.

Study limitations

A potential limitation of this study is that we evaluated first-episode psychoses as a whole, without stratifying for diagnosis. However, the fact that we did not find any difference in mean total MPA score or cluster volume between diagnostic groups makes the possibility of diagnostic specificity less likely. Many previous studies have focused on schizophrenia, but our results suggest there might well be commonality between different psychosis subtypes in terms of neurodevelopmental processes. Also, our assessment of anomalies did not include any quantitative measures, some of which have been identified as important

in those with psychosis (McGrath *et al*, 2002). It may also be argued that addition of quantitative measures enhances the robustness of anomaly assessment, since such measures may be more objective than ratings of qualitative anomalies. This is particularly important given the potential bias that might arise from the difficulty inherent in masking the MPA assessor to patient status. However, it should be noted that the specific anomalies we found to be most prevalent (palatal abnormalities, deformities of the ears and asymmetries) are consistent with those reported in previous studies (Lane *et al*, 1997; McGrath *et al*, 2002) and we achieved a high degree of interrater reliability (95–100%). In addition, masking in this particular study is arguably less important because the participants included in this analysis were all patients, and those assessing their anomalies were unaware of any MRI findings at the time of assessment. We employed an additive model of MPA scoring in which the presence of different anomalies contributed equally to the total MPA score, making no assumptions about the relative importance or severity of anomalies. Such a model may not accurately represent reality, but until more is known about the relationship between minor physical anomalies and neurodevelopmental abnormality a simple pragmatic approach seems preferable. Finally, an important limitation of this study is that we did not investigate the brain correlates of minor physical anomalies in a sample of healthy individuals. Our study has provided preliminary evidence of an association between such anomalies and particular brain areas; investigating this further in healthy individuals might identify which brain areas are specifically associated with anomalies, independently of an underlying pathogenic process and of use of psychotropic medications.

Main findings

The areas highlighted by our regional analysis have previously been implicated in the pathogenesis of psychosis. The deficit clusters were located predominantly in the prefrontal cortex, an area known to have an important executive or modulatory role in behaviour and cognition (Knight *et al*, 1999). Deficits in these functions are characteristically found in psychosis (Goldberg *et al*, 1987) and a number of structural MRI studies have demonstrated a reduction

Table 3 Association with total minor physical anomalies score among patients (n=60)

	Mean total MPA score	Regression coefficient	P
Gender			
Male (n=36)	15.42		
Female (n=24)	13.33		0.25 (t=1.16)
Diagnosis			
Schizophrenia, schizoaffective disorder (n=31)	15.23		0.46 (t=0.75)
Other psychosis (n=29)	13.90		
Ethnicity			
White (n=24)	13.96		
African-Caribbean (n=27)	15.00		0.85 (F=0.16)
Other (n=9)	15.00		
Medication type			
Typical antipsychotic (n=16)	17.75		
Atypical antipsychotic (n=9)	13.22		0.20 (F=1.62)
Mixed (n=15)	13.27		
No medication (n=20)	13.65		
Age, years		-0.07	0.62
Duration of untreated psychosis, weeks		0.19	0.15
Education, years		0.03	0.80
IQ		-0.06	0.66
Total symptom score		0.26	0.05
Total NES soft signs score		-0.19	0.16
Current antipsychotic dosage (chlorpromazine equivalents), mg		0.16	0.21
Brain volumes, cm³			
White matter		0.00	0.99
Grey matter		0.01	0.93
CSF		-0.08	0.55

CSF, cerebrospinal fluid; MPA, minor physical anomalies; NES, Neurological Evaluation Scale.

in the volume of frontal lobes, particularly of the prefrontal region, in both chronic disorder and first-episode patient samples (Chua *et al*, 1995; Gur *et al*, 2000; Wright *et al*, 2000; Hirayasu *et al*, 2001). Consistent with these reports, we have

Table 4 Regional associations of grey matter with total minor physical anomalies score, $P \leq 0.002$ (controlled for age)

	Number of voxels in cluster	Location of cluster centre x, y, z
Total MPA score associated with less grey matter		
R superior and medial frontal gyrus (BA 6)	427	7.4, 12.6, 52.9
L superior and medial frontal gyrus (BA 6)	292	-6.0, 5.7, 58.5
R precuneus with extension into the paracentral lobule, precentral and postcentral gyrus, and across to the L side	1035	0.1, -48.2, 54.4
Total MPA score associated with more grey matter		
L lentiform nucleus, putamen	839	-26.8, 6.0, 2.8
R lentiform nucleus, putamen	1132	26.8, -0.3, 5.2
L thalamus	448	-3.4, -17.3, 2.3
R lingual gyrus (BA 18)	845	3.2, -80.5, -3.8

BA, Brodmann area; L, left; MPA, minor physical anomalies; R, right.

already described in this same sample a reduction of frontal volume (precentral gyrus, inferior frontal gyrus) in association with difficulties in integrating information from multiple sensory modalities (Dazzan *et al*, 2004). These findings, and the association between high MPA score and reduced prefrontal volume reported here, suggest that abnormal neurodevelopment of the frontal lobe may be occurring prior to birth in a subgroup of patients with psychosis, and that this is reflected in functional deficits such as problems in executive functioning and sensory integration. Interestingly, in a *post hoc* analysis we found MPA total score to be significantly associated with the sensory integration subscore of the Neurological Evaluation Scale ($P=0.006$).

We also found an association between total MPA score and reduced grey matter volume of the precuneus extending into the paracentral lobule and the precentral and postcentral gyrus. The precuneus, located in the medial parietal cortex, has been reported to be activated during visuo-spatial tasks (Corbetta *et al*, 1993; Ghaem *et al*, 1997) and language comprehension (Binder, 1997). Brain regions important for language and integration of stimuli may be particularly affected in schizophrenia (Shenton *et al*, 2001). Our results may provide further support for this notion.

In addition to the grey matter deficits described, we found an association between total MPA score and an increased volume of grey matter in a number of subcortical structures such as the lentiform nucleus (part of the basal ganglia) and the thalamus. Interestingly, and in agreement with other studies (Chakos *et al*, 1994, 1995; Keshavan *et al*, 1994; Gur *et al*, 1998), we have previously found in this sample that basal ganglia and thalamus enlargement was associated with use of antipsychotic medication (Dazzan *et al*, 2005). Thus, in this study we explored the possibility that the increased volume of subcortical structures could be reflecting an effect of medication. Adjustment for medication dosage, type or duration did not alter the significance of any of the primary relationships between MPA score and cluster volumes. Although this would suggest that administration of antipsychotic medication cannot fully explain our findings, it is plausible that people with an excess of minor physical anomalies are more vulnerable to the effects of antipsychotics on

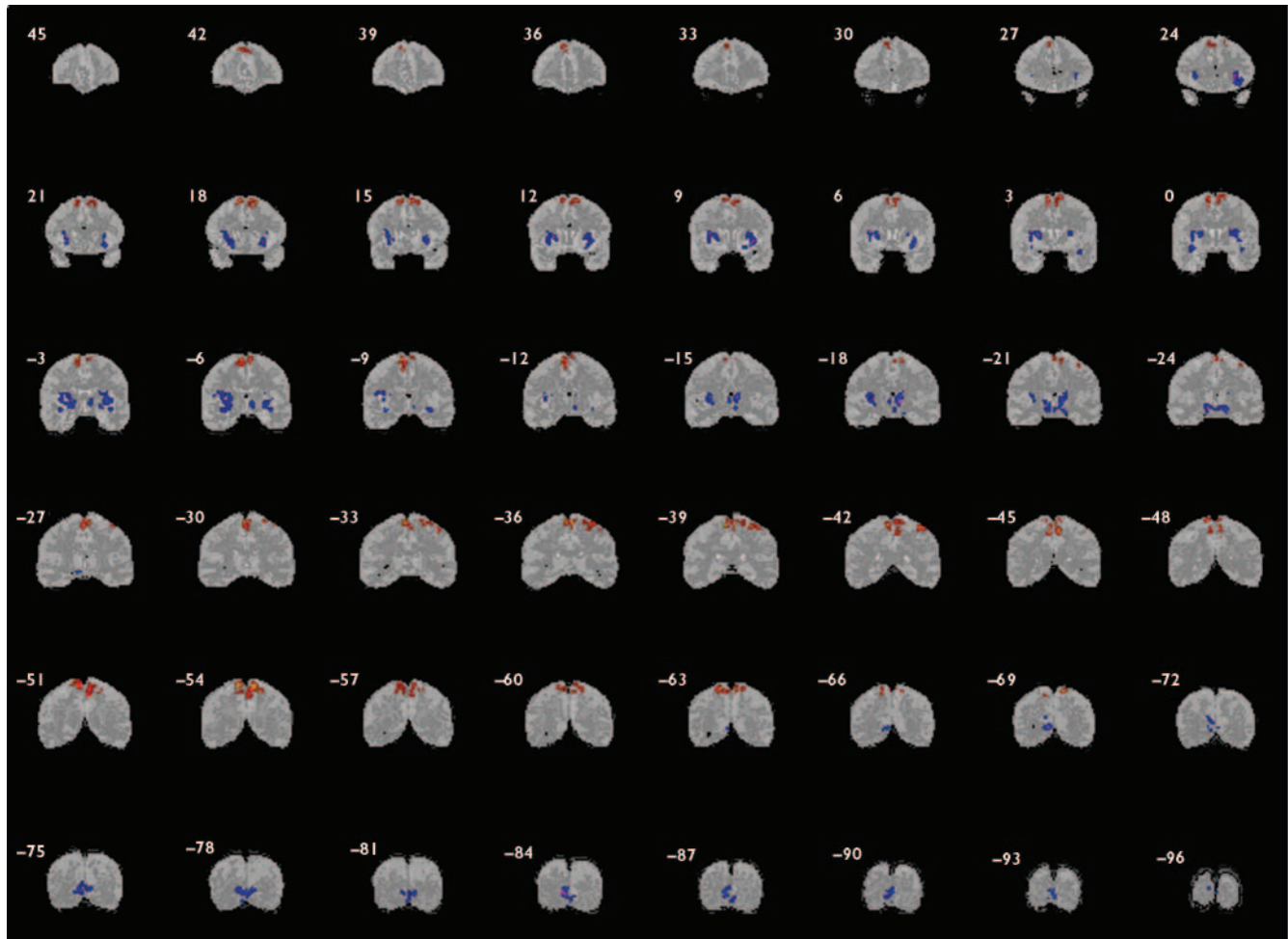


Fig. 1 Brain changes and minor physical anomalies. Regions of tissue deficit in association with higher total score are shown in red; regions of tissue excess in association with higher total minor physical anomalies score are shown in blue. Results are displayed on an averaged grey- and white-matter map. The left side of the image corresponds to the right side of the brain. Numbers refer to the approximate y coordinates in the standard space of Talairach and Tournoux.

subcortical structures. Also, our previous finding of a reduction of basal ganglia and thalamus volume in participants with more soft neurological abnormalities, independent of medication, suggest that these regions are areas of vulnerability for psychosis (Dazzan *et al*, 2004). However, it is important to consider that measures of medication exposure in non-randomised studies are likely to be intrinsically inaccurate. Therefore, it is possible that participants with an excess of minor physical anomalies, who were also experiencing more severe symptoms, were more likely to receive antipsychotic medication, and this was then reflected in their larger basal ganglia. This possibility is further supported by our finding that MPA score was associated with total symptom score, although controlling for total symptom

score did not significantly alter the associations found between individual cluster volumes and MPA score.

Finally, we found a cluster of volume excess associated with total MPA score which was centred on the lingual gyrus, an area of visual association cortex particularly concerned with visual attention. The lingual gyrus has previously been reported to be abnormal in psychosis (Franck *et al*, 2002; Shapleske *et al*, 2002) and our previous data on this sample also suggest an association between this area and an excess of sensory integrative deficits (Dazzan *et al*, 2004). Abnormalities in this region among those with an excess of minor physical anomalies may be reflected in the presence of perceptual symptoms, particularly if visual in nature. Although we did not look at specific symptoms in our study,

we did find an association between MPA score and symptom severity.

Possible aetiological mechanisms

Linking minor physical anomalies to structural brain abnormalities may help to define the temporal origin of the latter. Minor physical anomalies are known to arise in pregnancy and thus cerebral anomalies associated with the presence of an excess of such anomalies are likely also to have their origins during this antenatal period, therefore having a neurodevelopmental origin. Waddington *et al* (1999a,b) have developed a model of cerebrocraniofacial dysmorphogenesis to explain the neurodevelopmental basis of schizophrenia. They argue that embryological development of midline craniofacial

structures such as the palate occurs over weeks 9–10 to 14–15 of gestation, and that the important process occurring during this period is one of narrowing and elongation of the mid-face. Aetiological factors, whether environmental or genetic, acting during the first trimester may affect this process of midline development of both the face and the brain, with structures such as the medial temporal lobe, thalamus and midline anterior cortex (prefrontal to temporoparietal areas) being particularly impaired in their development as a result. Disruption of midline embryonic craniofacial growth was confirmed in a recent study conducted by the same group employing three-dimensional morphometric measurement (Hennessy *et al*, 2004). This model is, at least in part, consistent with our findings, particularly regarding reduced volumes in the prefrontal cortex. Others have identified a range of potential environmental factors which might act during the first trimester of pregnancy, including maternal malnutrition (Susser *et al*, 1996); influenza infection (O'Callaghan *et al*, 1991; Brown *et al*, 2004); rubella infection (Brown *et al*, 2001); cortisol exposure, such as might occur in association with maternal stress or depression (Modi *et al*, 2001; Diego *et al*, 2004); and obstetric complications, which although occurring later in pregnancy might be precipitated by dysmorphogenesis occurring much earlier (Smith *et al*, 1998). In addition, candidate genes involved in craniofacial development have been proposed (Waddington *et al*, 1999b). Samples selected for their genetic liability to psychosis in the absence of disorder have been reported to have elevated rates of morphological abnormality compared with healthy controls (Gourion *et al*, 2004). However, the presence of minor physical anomalies in such high-risk groups may well reflect non-specific neurodevelopmental abnormality rather than being specifically linked to schizophrenia genes (Lawrie *et al*, 2001).

In conclusion, total MPA score is positively associated with reduced prefrontal volume and enlarged basal ganglia volumes in a sample of patients with first-episode psychosis. This provides further evidence to support the importance of risk operating during the antenatal period. The findings also point to particular brain regions in which abnormalities are likely to have been present prior to birth and which may well be important areas involved in the pathogenesis of psychosis. Further investigation,

K. DEAN, MRCPsych, P. FEARON, MRCPsych, K. MORGAN, PhD, Division of Psychological Medicine, Institute of Psychiatry, King's College London, UK; G. HUTCHINSON, MRCPsych, Department of Psychiatry, University of West Indies, Trinidad, Trinidad & Tobago; K. ORR, FRANZCP, Department of Psychiatry, Sir Charles Gairdner Hospital, Perth, Australia; X. CHITNIS, MSc, Department of Neurology, Institute of Psychiatry, King's College London; J. SUCKLING, PhD, Department of Psychiatry, University of Cambridge, Addenbrooke's Hospital, Cambridge; R. MALLETT, PhD, J. LEFF, FRCPsych, Division of Psychological Medicine, Institute of Psychiatry, King's College London; P. B. JONES, FRCPsych, Department of Psychiatry, University of Cambridge, Addenbrooke's Hospital, Cambridge; R. M. MURRAY, FRCPsych, P. DAZZAN, MRCPsych, Division of Psychological Medicine, Institute of Psychiatry, King's College London, UK

Correspondence: Dr Kimberlie Dean, Department of Forensic Mental Health Science, PO Box 23, Institute of Psychiatry, De Crespigny Park, London SE5 8AF, UK. Tel: +44 (0)20 7848 0771; fax: +44 (0)20 7848 0754; email: k.dean@iop.kcl.ac.uk

(First received 17 August 2005, final revision 5 December 2005, accepted 3 March 2006)

particularly in healthy control individuals, must be considered before conclusions can be drawn about the specificity of our findings for the pathogenesis of psychosis.

ACKNOWLEDGEMENTS

The Aetiology and Ethnicity in Schizophrenia and Other Psychoses (ÆSOP) study was funded by the Medical Research Council (UK). We thank the Stanley Medical Research Institute for their support. We thank Dr A. Lane (St John of God Hospital, Dublin) for advice regarding the use of her scale and the analysis of data derived from it. We wish to thank the ÆSOP researchers who helped with the data collection and the patients who took part in the study.

REFERENCES

- Bazire, S. (1998)** *Psychotropic Drug Directory: The Professionals' Pocket Handbook and Aide Memoire*. Salisbury: Quay Books.
- Bezchlibnyk-Butler, K. & Jeffries, J. (2000)** *Clinical Handbook of Psychotropic Drugs* (10th edn). Seattle, WA: Hogrefe & Huber.
- Binder, J. (1997)** Functional magnetic resonance imaging. Language mapping. *Neurosurgery Clinics of North America*, **8**, 383–392.
- Brown, A. S., Cohen, P., Harkavy-Friedman, J., et al (2001)** A. E. Bennett Research Award. Prenatal rubella, premorbid abnormalities, and adult schizophrenia. *Biological Psychiatry*, **49**, 473–486.
- Brown, A. S., Begg, M. D., Gravenstein, S., et al (2004)** Serologic evidence of prenatal influenza in the etiology of schizophrenia. *Archives of General Psychiatry*, **61**, 774–780.
- Buchanan, R. W. & Heinrichs, D. W. (1989)** The Neurological Evaluation Scale (NES): a structured instrument for the assessment of neurological signs in schizophrenia. *Psychiatry Research*, **27**, 335–350.
- Buckley, P. F., Moore, C., Long, H., et al (1994)** IH-magnetic resonance spectroscopy of the left temporal and frontal lobes in schizophrenia: clinical, neurodevelopmental, and cognitive correlates. *Biological Psychiatry*, **36**, 792–800.
- Bullmore, E. T., Suckling, J., Overmeyer, S., et al (1999)** Global voxel, and cluster tests, by theory and permutation, for a difference between two groups of structural MR images of the brain. *IEEE Transactions on Medical Imaging*, **18**, 32–42.
- Chakos, M. H., Lieberman, J. A., Bilder, R. M., et al (1994)** Increase in caudate nuclei volumes of first-episode schizophrenic patients taking antipsychotic drugs. *American Journal of Psychiatry*, **151**, 1430–1436.
- Chakos, M. H., Lieberman, J. A., Alvir, J., et al (1995)** Caudate nuclei volumes in schizophrenic patients treated with typical antipsychotics or clozapine. *Lancet*, **345**, 456–457.
- Chua, S. E. & McKenna, P. J. (1995)** Schizophrenia – a brain disease? A critical review of structural and functional cerebral abnormality in the disorder. *British Journal of Psychiatry*, **166**, 563–582.
- Corbetta, M., Miezin, F. M., Shulman, G. L., et al (1993)** A PET study of visuospatial attention. *Journal of Neuroscience*, **13**, 1202–1226.
- Cox, R. W. (1996)** AFNI: software for analysis and visualization of functional magnetic resonance neuroimages. *Computers and Biomedical Research*, **29**, 162–173.
- Dazzan, P., Morgan, K. D., Orr, K. G., et al (2004)** The structural brain correlates of neurological soft signs in ÆSOP first-episode psychoses study. *Brain*, **127**, 143–153.
- Dazzan, P., Morgan, K. D., Orr, K., et al (2005)** Different effects of typical and atypical antipsychotics on grey matter in first episode psychosis: the ÆSOP study. *Neuropsychopharmacology*, **30**, 765–774.
- Diego, M. A., Field, T., Hernandez-Reif, M., et al (2004)** Prepartum, postpartum and chronic depression effects on newborns. *Psychiatry*, **67**, 63–80.
- Franck, N., O'Leary, D. S., Flaum, M., et al (2002)** Cerebral blood flow changes associated with Schneiderian first-rank symptoms in schizophrenia. *Journal of Neuropsychiatry and Clinical Neuroscience*, **14**, 277–282.
- Ghaem, O., Mellet, E., Crivello, F., et al (1997)** Mental navigation along memorized routes activates the hippocampus, precuneus, and insula. *NeuroReport*, **8**, 739–744.
- Goldberg, T. E., Weinberger, D. R., Berman, K. F., et al (1987)** Further evidence for dementia of the prefrontal type in schizophrenia? A controlled study of teaching the Wisconsin Card Sorting Test. *Archives of General Psychiatry*, **44**, 1008–1014.
- Gourion, D., Goldberger, C., Olie, J. P., et al (2004)** Neurological and morphological anomalies and the genetic liability to schizophrenia: a composite phenotype. *Schizophrenia Research*, **67**, 23–31.

- Gur, R. E., Maany, V., Mozley, P. D., et al (1998)** Subcortical MRI volumes in neuroleptic-naive and treated patients with schizophrenia. *American Journal of Psychiatry*, **155**, 1711–1717.
- Gur, R. E., Cowell, P. E., Latshaw, A., et al (2000)** Reduced dorsal and orbital prefrontal gray matter volumes in schizophrenia. *Archives of General Psychiatry*, **57**, 761–768.
- Hata, K., Iida, J., Iwasaka, H., et al (2003)** Association between minor physical anomalies and lateral ventricular enlargement in childhood and adolescent onset schizophrenia. *Acta Psychiatrica Scandinavica*, **108**, 147–151.
- Hennessy, R. J., Lane, A., Kinsella, A., et al (2004)** 3D morphometrics of craniofacial dysmorphology reveals sex-specific asymmetries in schizophrenia. *Schizophrenia Research*, **67**, 261–268.
- Hirayasu, Y., Tanaka, S., Shenton, M. E., et al (2001)** Prefrontal gray matter volume reduction in first episode schizophrenia. *Cerebral Cortex*, **11**, 374–381.
- Ismail, B., Cantor-Graae, E. & McNeil, T. F. (2000)** Minor physical anomalies in schizophrenia: cognitive, neurological and other clinical correlates. *Journal of Psychiatric Research*, **34**, 45–56.
- Keshavan, M. S., Bagwell, W. W., Haas, G. L., et al (1994)** Changes in caudate volume with neuroleptic treatment. *Lancet*, **344**, 1434.
- Knight, R. T., Staines, W. R., Swick, D., et al (1999)** Prefrontal cortex regulates inhibition and excitation in distributed neural networks. *Acta Psychologica*, **101**, 159–178.
- Lane, A., Kinsella, A., Murphy, P., et al (1997)** The anthropometric assessment of dysmorphic features in schizophrenia as an index of its developmental origins. *Psychological Medicine*, **27**, 1155–1164.
- Lawrie, S. M., Byrne, M., Miller, P., et al (2001)** Neurodevelopmental indices and the development of psychotic symptoms in subjects at high risk of schizophrenia. *British Journal of Psychiatry*, **178**, 524–530.
- McGrath, J. J., van Os, J., Hoyos, C., et al (1995)** Minor physical anomalies in psychoses: associations with clinical and putative aetiological variables. *Schizophrenia Research*, **18**, 9–20.
- McGrath, J., El-Saadi, O., Grim, V., et al (2002)** Minor physical anomalies and quantitative measures of the head and face in patients with psychosis. *Archives of General Psychiatry*, **59**, 458–464.
- McNeil, T. F., Cantor-Graae, E. & Weinberger, D. R. (2000)** Relationship of obstetric complications and differences in size of brain structures in monozygotic twin pairs discordant for schizophrenia. *American Journal of Psychiatry*, **157**, 203–212.
- Modi, N., Lewis, H., Al-Naqeeb, N., et al (2001)** The effects of repeated antenatal glucocorticoid therapy on the developing brain. *Paediatric Research*, **50**, 581–585.
- Muramatsu, D., Isono, H., Okajima, Y., et al (2000)** Minor physical anomaly in schizophrenia (Japanese). *Seishin Igaku (Clinical Psychiatry)*, **42**, 689–695.
- Nelson, H. E. & Willison, J. R. (1991)** *National Adult Reading Test* (2nd edn). Windsor: nferNelson.
- O'Callaghan, E., Sham, P., Takei, N., et al (1991)** Schizophrenia after prenatal exposure to 1957 A2 influenza epidemic. *Lancet*, **337**, 1248–1250.
- O'Callaghan, E., Buckley, P., Madigan, C., et al (1995)** The relationship of minor physical anomalies and other putative indices of developmental disturbance in schizophrenia to abnormalities of cerebral structure on magnetic resonance imaging. *Biological Psychiatry*, **38**, 516–524.
- Shapleske, J., Rossell, S. L., Chitnis, X. A., et al (2002)** A computational morphometric MRI study of schizophrenia: effects of hallucinations. *Cerebral Cortex*, **12**, 1331–1341.
- Shenton, M. E., Dickey, C. C., Frumin, M., et al (2001)** A review of MRI findings in schizophrenia. *Schizophrenia Research*, **49**, 1–52.
- Sigmundsson, T., Suckling, J., Maier, M., et al (2001)** Structural abnormalities in frontal, temporal, and limbic regions and interconnecting white matter tracts in schizophrenic patients with prominent negative symptoms. *American Journal of Psychiatry*, **158**, 234–243.
- Smith, G. C., Smith, M. F., McNay, M. B., et al (1998)** First-trimester growth and the risk of low birth weight. *New England Journal of Medicine*, **339**, 1817–1822.
- Suckling, J., Brammer, M. J., Lingford-Hughes, A., et al (1999a)** Removal of extracerebral tissues in dual-echo magnetic resonance images via linear scale-space features. *Magnetic Resonance Imaging*, **17**, 247–256.
- Suckling, J., Sigmundsson, T., Greenwood, K., et al (1999b)** A modified fuzzy clustering algorithm for operator independent brain tissue classification of dual echo MR images. *Magnetic Resonance Imaging*, **17**, 1065–1076.
- Susser, E., Neugebauer, R., Hoek, H. W., et al (1996)** Schizophrenia after prenatal famine. Further evidence. *Archives of General Psychiatry*, **53**, 25–31.
- Talairach, J. & Tournoux, P. (1988)** *Co-Planar Stereotaxic Atlas of the Human Brain*. New York: Thieme.
- Taylor, D., McConnell, D., McConnell, H., et al (1999)** *The Bethlem and Maudsley NHS Trust Prescribing Guidelines*. London: Martin Dunitz.
- Waddington, J. L., Lane, A., Larkin, C., et al (1999a)** The neurodevelopmental basis of schizophrenia: clinical clues from cerebro-craniofacial dysmorphogenesis, and the roots of a lifetime trajectory of disease. *Biological Psychiatry*, **46**, 31–39.
- Waddington, J. L., Lane, A., Scully, P., et al (1999b)** Early cerebro-craniofacial dysmorphogenesis in schizophrenia: a lifetime trajectory model from neurodevelopmental basis to 'neuroprogressive' process. *Journal of Psychiatric Research*, **33**, 477–489.
- Waldrop, M. F. & Halverson, C. F. (1971)** Minor physical anomalies and hyperactive behavior in young children. In *Exceptional Infant* (ed. J. Hellmuth), pp. 343–381. New York: Brunner/Mazel.
- Wing, J. K. & Sturt, E. (1978)** *The PSE-ID-CATEGO System. Supplementary Manual*. London: Medical Research Council.
- Wing, J. K., Cooper, J. E. & Sartorius, N. (1974)** *The Measurement and Classification of Psychiatric Symptoms*. Cambridge: Cambridge University Press.
- World Health Organization (1992)** *The ICD-10 Classification of Mental and Behavioural Disorders: Clinical Descriptions and Diagnostic Guidelines*. Geneva: WHO.
- World Health Organization (1994)** *Schedules for Clinical Assessment in Neuropsychiatry (SCAN) – Version 2.0*. Geneva: WHO.
- Wright, I. C., Rabe-Hesketh, S., Woodruff, P. W., et al (2000)** Meta-analysis of regional brain volumes in schizophrenia. *American Journal of Psychiatry*, **157**, 16–25.