

Efficacy of endoscopic sinus surgery for paranasal sinus mucocele including modified endoscopic Lothrop procedure for frontal sinus mucocele

JWU JIN KHONG, M.B.B.S., RAMAN MALHOTRA, M.B. CH.B., F.R.C.OPHTH., DINESH SELVA, M.B.B.S., F.R.A.C.S., F.R.A.N.Z.C.O., PETER JOHN WORMALD*, M.D. F.R.A.C.S., F.R.C.S., F.C.S. (SA)

Abstract

This study evaluated the efficacy of the modified endoscopic Lothrop procedure (MELP) for complicated frontal mucoceles and endoscopic marsupialization for other paranasal sinus mucoceles.

It was a retrospective, consecutive case review of sinus mucoceles treated endoscopically by a single surgeon over a four-year period (1998–2002).

There were 41 mucoceles in 28 patients, including 24 frontal, eight frontoethmoidal, three ethmoidal, five maxillary and one frontal mucocele. Twenty-one patients underwent the modified Lothrop procedure for frontal mucoceles, and seven underwent simple drainage and marsupialization for frontoethmoidal, ethmoidal and maxillary mucoceles. At median follow-up of 16 months, all patients had a patent mucocele opening. Patients treated by drainage and marsupialization did not have any complications or mucocele recurrence. All patients treated by the modified endoscopic Lothrop procedure had improvement in symptoms and signs. Four patients had minor complications including epistaxis and adhesions and five required further surgery. The average hospital in-patient stay was 2 ± 1.4 days.

Endoscopic techniques, including MELP are effective in the short term for the management of complex and simple paranasal sinus mucoceles. MELP has a useful place in the management of mucoceles with a significant bony partition from an adjacent sinus or nasal cavity. It is also indicated when the mucocele is associated with loss of lateral support in the sinus with risk of medial-wall collapse of the orbital contents obstructing drainage.

Key words: Mucocele; Frontal sinus; Endoscopy; Surgical Procedures, Operative; Paranasal Sinus Disease

Introduction

Over the past decade, intranasal drainage and marsupialization of mucoceles using endoscopic sinus surgery has emerged as definitive management, with minimal morbidity and a low recurrence rate.^{1–8} Two clinical situations remain a challenge. The first is where there is significant bony separation between the mucocele and the rest of the sinuses or nasal cavity and the mucocele is not bulging into an adjacent sinus or nasal cavity. After marsupialization a circumferential raw area of bone will remain between the mucocele and the sinus or nasal cavity. Due to the circumferential nature of the injury, the opening tends to stenose and the mucocele may recur. The second problem is when the mucocele erodes the floor and/or posterior wall of the frontal sinus. In this situation the mucocele lining is adherent to the orbital periosteum or the dura. Removal of the lining may be difficult if obliteration of the mucocele is intended and recurrences may occur.

The aim of this paper is to evaluate the efficacy of endoscopic sinus surgery for performing drainage and marsupialization for paranasal sinus mucocele and the efficacy of the modified endoscopic Lothrop procedure (MELP) for complicated frontal sinus mucoceles that have a significant bony separation from the nasal cavity and sinuses, and for those mucoceles that have eroded the bone of the orbit or dura.

Materials and methods

This was a retrospective, consecutive case series of all paranasal sinus mucoceles undergoing endoscopic sinus surgery at the Department of Surgery- Otolaryngology and Ophthalmology, Adelaide and Flinders Universities, over a four-year period between 1998 and 2002. A single surgeon (PJW) performed all surgery. Surgical procedures included endoscopic sinus surgery drainage and marsupialization for

From the Oculoplastic and Orbital Unit, Department of Ophthalmology, Royal Adelaide Hospital, University of Adelaide, and the Department of Surgery-Otolaryngology, Head and Neck Surgery*, Adelaide and Flinders Universities, Adelaide, Australia.
Accepted for publication: 14 February 2004.

uncomplicated paranasal sinus mucoceles ($n = 7$) and MELP for complicated frontal sinus mucoceles ($n = 21$). Intra-operative image guidance (Landmarx, Medtronic Xomed, Jacksonville, FL, USA) was used in all the MELP procedures and for two of the endoscopic sinus surgery cases.

A mucocele was defined as an expansion of an existing sinus with associated erosion of septations within the sinus and the walls of the sinus. Only patients who fulfilled this criterion were included.

Patient profile data consisted of demographic details, past history of sinus surgery, concurrent naso-laryngopharyngeal comorbidities, the mucocele site and pre-operative findings on computerized tomography (CT) and in some patients magnetic resonance imaging (MRI).

All patients underwent a clinical evaluation. Pre- and post-operative features including ocular and nasal symptoms were chartered. The initial management and follow-up was also recorded. Outcome measures included change in symptoms and signs, patency of the mucocele opening, mucocele recurrence, complications, additional surgery required and duration of hospital stay.

Data were recorded on an Excel® spreadsheet. Continuous data were analysed using the *t*-test and described as mean and standard deviation (mean \pm SD).

Results and analysis

Twenty-eight patients (17 males and 11 females) with 41 paranasal sinus mucoceles underwent endoscopic sinus surgery. The mean age was 52 ± 16.6 (range 15–83) years. The median follow-up was 16 (mean 18, range 1–42) months.

Sites included frontal (61 per cent), frontoethmoidal (20 per cent), ethmoidal (seven per cent) and maxillary (12 per cent) sinuses. Eight (29 per cent) of patients had multiple mucoceles. Twenty-one (75 per cent) of cases were managed with MELP while seven (25 per cent) of cases required only endoscopic sinus surgery for the management of their mucoceles. Of the 21 cases that underwent MELP, four required concurrent endoscopic sinus surgery. The technique of MELP is described elsewhere.⁹

Patients' symptoms and signs were summarized and categorized, according to the procedure they underwent, into the endoscopic sinus surgery and

MELP subgroups (Table I). Frontal pain (57.1 per cent), nasal obstruction (57.1 per cent) and rhinorrhoea (42.9 per cent) were the main presenting symptoms in the endoscopic sinus surgery subgroup as compared to frontal pain (71.4 per cent), headache (52.4 per cent), nasal obstruction (38.1 per cent) and posterior nasal drip (38.1 per cent) in the MELP subgroup. Two patients from the endoscopic sinus surgery subgroup and one from the MELP subgroup had a palpable mass on presentation. Medial canthus masses were correlated with the presence of frontoethmoidal mucoceles and gingivobuccal sulcus swelling was associated with a left maxillary mucocele. One case with a frontal mucopyocele presented with progressive reduction of vision to 6/18, ptosis and periorbital swelling as a result of orbital cellulitis complicated by preseptal abscess. His visual acuity returned to 6/6 within two weeks of the MELP procedure.

In the endoscopic sinus surgery patient group, none had significant separation of their mucoceles from the nasal cavity or the sinuses on imaging. Most patients had extension of the mucocele into the orbit (71 per cent) and nearly half (43 per cent) had globe displacement. Two patients had erosion of the medial orbital wall and the orbital roof. In the MELP patient group, 10 (48 per cent) had orbital extension and eight (38 per cent) had globe displacement. Eleven (52 per cent) patients had a thick bony wall separating the mucocele from the sinuses and the nasal cavity. Two of the frontal sinus mucoceles were located laterally (Figure 1(a)) and two were located superiorly in the frontal sinus. Erosion of the orbital wall and skull base was present in 10 (48 per cent) patients (Figure 1(b) and 1(c)). These included four patients with dehiscence of the posterior table of the frontal sinus, six with orbital roof erosion, two with erosion of the medial orbital wall, one with erosion of the lamina papyracea and three with intracranial extension (Table II).

Prior ENT history and co-morbidities are summarized in Table III.

Treatment outcome

All patients treated by endoscopic sinus surgery alone had a patent sinus ostia. None required additional surgery. One had minor epistaxis after the procedure.

TABLE I
PRESENTING SYMPTOMS AND SIGNS

Symptoms	ESS group (n) n = 7	MELP group (n) n = 21	Signs	ESS group (n) n = 7	MELP group (n) n = 21
Diplopia	2 (28.6%)	5 (23.8%)	Visual loss	0	1 (4.8%)
Epiphora	1 (14.3%)	1 (4.8%)	Non-axial proptosis	2 (28.6%)	3 (14.3%)
Frontal pain	4 (57.1%)	15 (71.4%)	Globe displacement	3 (42.9%)	8 (38.1%)
Headache	2 (28.6%)	11 (52.4%)	Lid swelling	2 (28.6%)	7 (33.3%)
Rhinorrhoea	3 (42.9%)	7 (33.3%)	Vitreochoroidal fold	0	1 (4.8%)
Nasal obstruction	4 (57.1%)	8 (38.1%)	Palpable mass-medial canthus (2), gingivobuccal sulcus (1)	2 (28.6%)	1 (4.8%)
Post nasal drip	2 (28.6%)	8 (38.1%)	Subcutaneous air	0	1 (4.8%)
Anosmia	2 (28.6%)	1 (4.8%)	Ptosis	0	1 (4.8%)

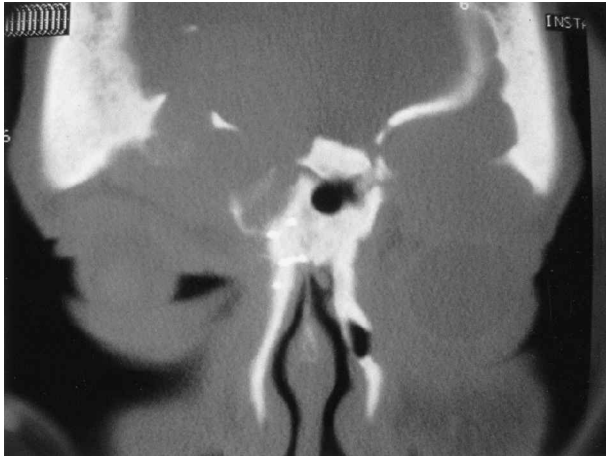


FIG. 1(a)

Coronal computerized tomographic image showing bilateral frontal mucoceles. The left frontal mucocele is located laterally and separate from the nasal cavity.

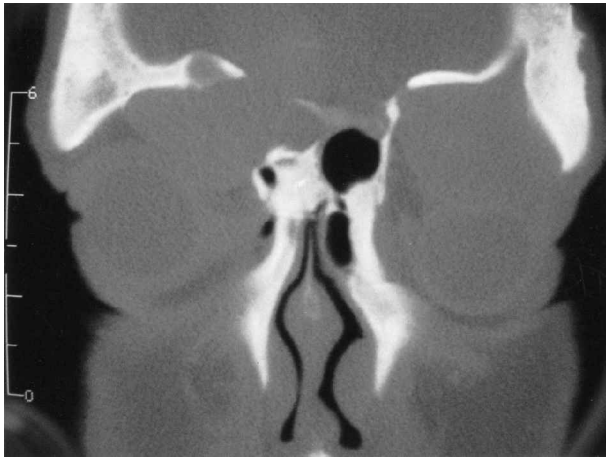


FIG. 1(b)

Coronal image demonstrates bilateral orbital roof destruction and intraorbital extension, which resulted in right lateral globe displacement and left inferior globe displacement.

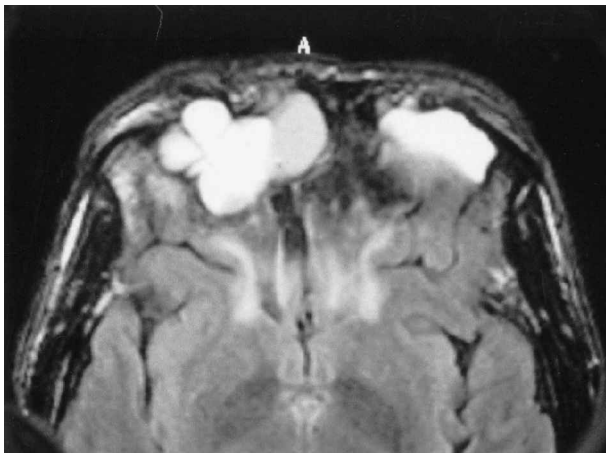


FIG. 1(c)

Axial image showing anterior and posterior frontal sinus table destruction and intracranial extension bilaterally.

In the MELP group, two patients had stenosis of their frontal ostium requiring revision surgery to re-establish a widely patent frontal ostium. These frontal ostia have subsequently remained patent and the patients asymptomatic. One patient needed toileting of the frontal ostium at one month to clear crusts and debris from the marsupialized mucocele ostium. Self-limiting complications were recorded in three cases in the MELP patient group. These were minor epistaxis, adhesions between the middle turbinate and lateral nasal wall and adhesions between the middle turbinate and septum.

Nine patients, (five from the MELP group and four from the endoscopic sinus surgery group) had incomplete resolution of symptoms. Their nasal symptoms were attributable to ongoing nasal and sinuses pathology including chronic fungal sinusitis and recurrent nasal polyposis. Residual symptoms include headache, rhinorrhoea, nasal obstructions, frontal pain and posterior nasal drip.

The median duration of in-patient stay was two (mean 2 ± 1.4 , range one to six) days. Twelve patients were managed as day cases and six patients stayed overnight after the procedure. Those that remained as in-patients for longer did so for non-medical reasons (patients lived too far for immediate out-patient follow up).

Discussion

Mucoceles are expansile masses originating in the sinuses usually presenting with frontal headache, nasal obstruction and eye signs such as globe displacement, diplopia, proptosis, lid swelling, palpable mass and at times reduced vision and ptosis.^{10,11}

Scarring of the sinus opening is the most common cause for mucocele formation. The frontal and ethmoidal sinuses were the most commonly involved, which reflects the predisposition for their small sinus openings to be damaged during sinus surgery or trauma, or by repeated infections with subsequent obstruction and mucocele formation. Most patients (93 per cent) in our series had prior sinus surgery (86 per cent), chronic sinusitis (79 per cent) or trauma (seven per cent).

Endoscopic management of mucoceles protruding into the other sinuses or nasal cavity has been the accepted treatment for years.¹⁻⁸ Our results confirm the success of treating uncomplicated mucoceles with standard endoscopic sinus surgery techniques. However, mucoceles presenting with a significant bony separation from the other sinuses or nasal cavity are more complex and difficult to manage. This bony divide needs to be removed by a drill so that a large enough opening is created into the mucocele that will stay patent in the long term. In this series MELP provided short-term successful management of these complex patients.

The alternative to drilling away this bone is to approach the mucocele via external incisions, remove its entire lining and obliterate it with fat. A survey of contemporary practices in the United Kingdom showed that while many surgeons routinely performed endoscopic sinus surgery, 54 per cent

TABLE II
PRE-OPERATIVE IMAGING FINDINGS

CT findings	ESS group (n) n = 7	MELP group (n) n = 21
Intra-orbital extension	5 (71.4%)	10 (47.6%)
Globe displacement	3 (42.9%)	8 (38.1%)
Separation of mucocele from sinuses and nasal cavity	0	11 (52.4%)
Erosion of the orbital wall and/or skull base	2 (28.6%)	10 (47.6%)

of surgeons would still rely on the external approach for frontal sinus mucocele and pyocele.¹² However, if the mucocele has eroded the orbital roof or skull base and there is extensive apposition of mucocele mucosa on the orbital periosteum or dura, complete removal of the mucosa is very difficult. If mucosa remains and the sinus is obliterated then recurrence of the mucocele is likely.⁷ The follow up of an obliterated sinus can also be unreliable as imaging may not be able to distinguish an obliterated sinus from a recurrent mucocele.^{1,7} In addition, it has been shown that the mucosa of a mucocele do not lose normal respiratory epithelium^{13,14} and follow-up endoscopic examination has also found well-mucosalized cavities after mucocele marsupialization.⁴ These findings suggest that there is no added benefit in attempting to remove the mucocele lining if it is closely applied to either the orbital periosteum or dura.

MELP provides the largest possible access to the frontal sinuses^{9,15} and allows mucoceles based in the lateral regions of the frontal sinus to be accessed and opened as widely as possible. This wide access improves the potential success rate of maintaining a patent opening into the mucocele.

This study showed that MELP was used successfully to open 11 mucoceles separated from the nasal cavity and sinuses and 10 mucoceles with significant erosion of either the orbital roof or skull base. Two patients required revisions due to mucocele recurrences but all currently have patent ostia. While the authors acknowledge that the follow-up period is still relatively short, MELP has proved to be a reliable alternative for the management of difficult and complex mucoceles of the frontal sinuses. MELP has a useful place in the management of mucoceles

- This paper evaluates the outcome from a modified endoscopic Lothrop procedure for frontal sinus and marsupialization for other paranasal sinus mucoceles in 28 patients
- At 16 months follow up all patients had adequate drainage of their mucoceles
- Four patients, all of whom had Lothrop procedures, had minor complications
- The paper concludes that endoscopic procedures for paranasal sinus mucoceles are effective in the short to medium term

separated from the nasal and sinus cavity by a thick bony divide. In addition MELP is also indicated when the mucocele is associated with loss of lateral support in the sinus with risk of medial-wall collapse of the orbital contents obstructing drainage. These recommendations augment those of previous authors that most paranasal sinus mucoceles can be successfully managed by endoscopic marsupialization into the nasal cavity.^{16,17}

This study adds to the number of publications advocating endoscopic sinus surgery as a safe and effective approach for mucocele management.^{8,16,17} Har *et al.*⁸ reported the largest series of 103 patients (108 mucoceles) with a median follow-up of 4.7 years and a recurrence rate of 0.9 per cent. This also represents the longest follow up for endoscopically managed mucoceles. However, significantly longer follow up is necessary to fully evaluate outcomes. Recurrence of mucocele after osteoplastic and obliteration procedures was 19 per cent (nine out

TABLE III
PRIOR ENT HISTORY AND CO-MORBIDITIES

Prior ENT history and co-morbidities	SM group Number of patients (n)	MELP group Number of patients (n)
Chronic sinusitis	6 (85.7%)	16 (76.1%)
Fungal sinusitis	0	7 (33.3%)
Nasal polyposis	0	8 (38.1%)
Previous endoscopic sinus surgery	4 (57.1%)	7 (33.3%)
Previous sinus surgery external approach	3 (42.9%)	14 (66.7%)
Facial trauma-facial fracture, anterior and posterior table frontal sinus fracture	0	2 (9.5%)
Prior neurosurgery – temporal craniectomy for trigeminal rhizotomy (1), craniotomy with infected bone flaps (1), frontal meningeoma excision (1), bilateral cranialization (1)	0	4 (19.0%)
Paranasal obstructive lesion-osteoma (1), inverting papilloma (1), large midline frontal cell (1)	1 (14.3%)	2 (9.52%)
Asthma	1 (14.3%)	5 (23.8%)
Pyomucocele	0	1 (4.8%)

of 47 patients) in a retrospective study¹⁸ whereas in two endoscopic series,^{1,5} the recurrence rate was zero per cent with minimal complications. It is important to note that in the latter two studies, patients thought not suitable for an entirely endoscopic approach due to complex sinus anatomy were managed with an external approach or a combined endoscopic and external approach. However, despite the addition of an external incision, the principle of mucocoele marsupialization into the nasal cavity was maintained and obliteration was rarely performed.

In conclusion, MELP should be considered as an alternative to external obliteration for the treatment of complex frontal mucocoeles. Endoscopic marsupialization should be considered the first line treatment for simple paranasal sinus mucocoeles.

References

- Kennedy DW, Josephson JS, Zinreich SJ, Mattox DE, Goldsmith MM. Endoscopic sinus surgery for mucocoeles: a viable alternative. *Laryngoscope* 1989;**99**:885–95
- Schaefer SD, Close LG. Endoscopic management of frontal sinus disease. *Laryngoscope* 1990;**100**:155–60
- Benninger MS, Marks S. The endoscopic management of sphenoid and ethmoid mucocoeles with orbital and intranasal extension. *Rhinology* 1995;**33**:157–61
- Har-El G, Balwally AN, Lucente FE. Sinus mucocoeles: is marsupialization enough? *Otolaryngol Head Neck Surg* 1997;**117**:63–40
- Lund VJ. Endoscopic management of paranasal sinus mucocoeles. *J Laryngol Otol* 1998;**112**:36–40
- Ikeda K, Takahashi C, Oshima T, Suzuki H, Satake M, Hidaka H *et al*. Endonasal endoscopic marsupialization of paranasal sinus mucocoeles. *Am J Rhinol* 2000;**14**:107–11
- Har-El G. Transnasal endoscopic management of frontal mucocoeles. *Otolaryngol Clin North Am* 2001;**34**:243–51
- Har-El G. Endoscopic management of 108 sinus mucocoeles. *Laryngoscope* 2001;**111**:2131–4
- Wormald PJ. Salvage frontal sinus surgery: the endoscopic modified Lothrop procedure. *Laryngoscope* 2003;**113**:276–83
- Rootman J, Allen L. Structural lesions. In: Rootman J, ed. *Diseases of the Orbit*, 2nd edn, Philadelphia: Lippincott Williams & Wilkins, 2003;425–31
- Haik BG, Amedee RG. Ophthalmic manifestations of mucocoeles. In: Bosniak S, ed. *Principles and Practice of Ophthalmic Plastic and Reconstructive Surgery*. Philadelphia: WB Saunders, 1996;1014–22
- Molony NC, Ah-See K, Rachmanidou A, Draf W. A survey of contemporary management of frontal sinus disease in the United Kingdom. *Eur Arch Otorhinolaryngol* 2000;**257**:247–50
- Lund VJ. Fronto-ethmoidal mucocoeles: A histopathological analysis. *J Laryngol Otol* 1991;**105**:921–23
- Har-El G, DiMaio T. Histologic and physiologic studies of marsupialized sinus mucocoeles. *J Otolaryngol* 2000;**29**:195–98
- Gross CW, Harrison SE. The modified Lothrop procedure: indications, results, and complications. (Review) *Otolaryngol Clin North Am* 2001;**34**:133–7
- Beasley NJ, Jones NS. Paranasal sinus mucocoeles: modern management. *Am J Rhinol* 1995;**9**:251–6
- Conboy PJ, Jones NS. The place of endoscopic sinus surgery in the treatment of paranasal sinus mucocoeles. *Clin Otolaryngol* 2003;**28**:207–10
- Bordley JE, Bosley WR. Mucocoeles of the frontal sinus: causes and treatment. *Ann Otol Rhinol Laryngol* 1973;**82**:696–702

Address for correspondence:

Professor Peter John Wormald,
Department of Surgery – Otolaryngology Head and Neck Surgery,
Queen Elizabeth Hospital,
28 Woodville Road, Woodville South,
Adelaide, SA 5011, Australia.

Fax: + 61 8 8222 7419

E-mail: peterjwormald@adelaide.edu.au

Professor P. J. Wormald takes responsibility for the integrity of the content of the paper.

Competing interests: None declared
