

Aggravation of pathogenesis mediated by ochratoxin A in mice infected with *Trypanosoma brucei rhodesiense*

J. K. KIBUGU^{1,2*}, J. J. N. NGERANWA², J. N. MAKUMI², J. K. GATHUMBI³,
J. M. KAGIRA¹, J. N. MWANGI⁴, M. W. MUCHIRI¹ and R. E. MDACHI¹

¹Kenya Agricultural Research Institute, Trypanosomiasis Research Centre, P. O. Box 362, Kikuyu, Kenya

²Kenyatta University, Department of Biochemistry and Biotechnology, P. O. Box 43844, Nairobi, Kenya

³University of Nairobi, Department of Veterinary Pathology, Microbiology and Parasitology, P. O. Box 29053, Nairobi, Kenya

⁴Kenya Agricultural Research Institute, Social Economics and Biometrics Division, P. O. Box 00200-57811, Nairobi, Kenya

(Received 12 August 2008; revised 21 September and 28 October 2008; accepted 29 October 2008; first published online 21 January 2009)

SUMMARY

Mice fed 1.5 mg ochratoxin A (OTA) per kg body weight and infected with *Trypanosoma brucei rhodesiense* were compared with trypanosome-infected placebo-fed and uninfected OTA-fed controls. Uninfected OTA-fed mice showed fever, lethargy, facial and eyelid oedemas, mild hepatitis and nephritis, and high survival. Infected placebo-fed controls had mean pre-patent period (PPP) of 3.26 days, lethargy, dyspnoea, fever, facial and scrotal oedema, survival of 33–65 days, reduced red cell counts (RCC: $10.96\text{--}6.87 \times 10^6$ cells/ μl of blood), packed cell volume (PCV: 43.19–26.36%), haemoglobin levels (Hb: 13.37–7.92 g/dL) and mean corpuscular volume (MCV) of 37.96–41.31 fL, hepatosplenomegaly, generalized oedemas, heart congestion, hepatitis and nephritis. Compared to infected placebo-fed controls, infected OTA-fed mice had significantly ($P < 0.05$) shorter mean PPP (2.58 days), reduced survival (6–47 days), more pronounced fever and dyspnoea. The latter had significantly ($P < 0.05$) reduced RCC ($10.74\text{--}4.56 \times 10^6$ cells/ μl of blood), PCV (43.90–20.78%), Hb (13.06–5.74 g/dL), increased MCV (39.10–43.97 fL), severe generalized oedemas, haemorrhages, congestion, hepatic haemosiderosis, hepatitis, nephritis, endocarditis, pericarditis and exclusively, splenic macrophage and giant cell hyperplasia, expanded red pulp and splenic erythrophagocytosis. It was concluded that OTA aggravated the pathogenesis of *T. b. rhodesiense* infection in mice, and should therefore be taken into consideration during trypanosomiasis control programmes.

Key words: Ochratoxin A, *Trypanosoma brucei rhodesiense*, pathogenesis, mice.

INTRODUCTION

Sleeping sickness is of great medical concern in sub-Saharan Africa where more than 66 million people are at risk (WHO, 2004). The disease, which is caused by *T. b. gambiense* and *T. b. rhodesiense*, and transmitted by tsetse flies, is endemic in areas where other diseases such as HIV-AIDS, parasitic diseases, food-borne diseases (FBD) occur, and whose interaction could lead to serious implications on animal and human health. Mycotoxicosis is an important FBD caused by ingestion of mycotoxins produced by a variety of toxigenic fungi that contaminate food and animal feeds (FAO/UNEP, 1977; Azziz-Baumgartner *et al.* 2005). The most common mycotoxins are aflatoxins, ochratoxins, trichothecenes and zearalenone (Smith and Moss, 1985) and are stable to normal cooking and food processing procedures (Al-Anati and Petzinger, 2006). Through suppression of the immune and haemopoietic systems (Cukrova *et al.* 1991; Williams *et al.* 2004),

interference with functions of essential nutrients like vitamins (Anyanwu *et al.* 2004) and toxicity effects on vital organs (Pier and McLoughlin, 1985), mycotoxins influence the course of many diseases. Thus the most common syndromes caused by ingestion of moderate to high levels of mycotoxins range from acute mortality (Azziz-Baumgartner *et al.* 2005), slow growth and reduced reproductive efficiency (Oswald *et al.* 2005) while lesser amounts may result in impaired immunity and decreased resistance to infections (Pier and McLoughlin, 1985).

One of the most potent and frequently encountered mycotoxin is ochratoxin A (OTA) (Kimathi and Siboe, 1994; Bondy and Pestka, 2000) which is a pentaketide secondary metabolite produced by the fungal species *Penicillium cyclopium* (Smith and Moss, 1985) and *Aspergillus ochraceus* (El-Arab *et al.* 2006). Due to its many adverse effects such as immunotoxicity (Bondy and Pestka, 2000; Assaf *et al.* 2004; Al-Anati and Petzinger, 2006), nephrotoxicity and hepatotoxicity (Smith and Moss, 1985; JECFA 47, 2001), OTA is likely to alter the pathogenesis of trypanosome infections in the field. Also, through its potent nephrotoxicity, this mycotoxin could affect the production of renal-produced erythropoietin

* Corresponding author: Kenya Agricultural Research Institute, Trypanosomiasis Research Centre, P. O. Box 362, Kikuyu, Kenya. E-mail: jkkibugu@yahoo.com

Table 1. Groups of mice used in the study

Mice group	No. of mice	Treatment
Group A	12	<i>T. b. rhodesiense</i> -infected and fed on OTA
Group B	12	<i>T. b. rhodesiense</i> -infected placebo-fed controls
Group C	12	Uninfected OTA-fed controls
Group D	6	<i>T. b. rhodesiense</i> -infected naïve controls
Group E	6	Uninfected naïve controls (clean)

leading to aggravation of trypanosome-induced anaemia. Despite the endemicity of both trypanosomiasis and mycotoxicosis in the sub-Saharan Africa, the interaction of the two diseases has not been investigated. Therefore, the purpose of the present study was to assess the effects of OTA on the pathogenesis of human infective *T. b. rhodesiense* infection in the murine model.

MATERIALS AND METHODS

Ethics

All protocols and procedures used in this study were reviewed and approved by the KARI-TRC Institutional Animal Care and Use Committee. The detoxification of mycotoxic waste and safety precautions were carried out as described elsewhere (Scott, 1995). In addition, the droppings and waste bedding material of the OTA-exposed animals were put in a labelled heavy duty plastic container, drenched in diesel and incinerated.

Materials

Forty-two days old male inbred adult Swiss White mice from KARI-TRC colony were maintained on mice pellets (Unga Feeds Ltd, Kenya) and water *ad libitum* at a temperature of 21–25 °C. These mice were acclimatized for 7 days before the experiment commenced. Wood-chippings were provided as bedding material. A cryo-preserved *T. b. rhodesiense* clone, KETRI 3741, a derivative of KETRI 2537 which was previously isolated from a human host in Uganda in 1972 (Fink and Schmidt, 1980) was used to infect the mice in this study. Purified extracts of OTA (187.5 µg/ml) and a placebo (obtained from Bora Biotech Ltd, Cooper Centre, Nairobi, Kenya) were separately constituted in vegetable oil as described by El-Arab *et al.* (2006).

Experimental design

Five groups of mice (aged 49 days) were used in this study as shown in Table 1. Group A mice were fed

Table 2. Number of experimental mice present at different time-intervals

Number at different weeks post-mycotoxin exposure (p.m.e.) (Inf=infection time between 1 and 2 weeks p.m.e.: ⁱ=number of mice during infection, Eu=euthanasia between weeks 4 and 5, ^s=number sacrificed.)

Mice groups	0	1	Inf	2	3	4	Eu	5	6	7	8	9
Group A	12	11	11 ⁱ	11	8	7	2 ^s	5	3	2	1	1
Group B	12	12	12 ⁱ	12	12	12	2 ^s	10	9	9	5	3
Group C	12	10	9 ⁱ	9	9	9	2 ^s	7	7	7	7	7
Group D	6	6	6 ⁱ	6	6	6	2 ^s	4	3	1	1	0
Group E	6	6	6 ⁱ	6	6	6	2 ^s	4	4	4	4	4

on OTA extract for 7 days and then infected with *T. b. rhodesiense*. After infection, the feeding on OTA was continued up to the 30th day. Group B was fed on placebo extract and then infected as in Group A. Group C had the same ochratoxin treatment as in Group A but was not infected with trypanosomes. Groups D and E did not receive the OTA or placebo treatment but the former was infected with *T. b. rhodesiense* while the latter was not. In groups A and C mice, OTA was administered orally through a gavage needle for 30 days at a daily dose of 1.50 mg OTA/kg body weight. Group B mice received the equivalent volume of the placebo. Since higher mortality was expected in groups A, B and C than in D and E, a higher number of mice was assigned to the former. To infect mice, cryo-preserved trypanosome stabilates were first expanded in donor mice that were euthanized at peak parasitaemia and blood harvested as described earlier (Kagira *et al.* 2007a). Groups A, B and D mice were injected intraperitoneally (i.p.) with 10⁴ trypanosomes per mouse (Gichuki and Brun, 1999; Kagira *et al.* 2007a) on day 7 post-commencement of ochratoxin administration.

Monitoring of parasitaemia and clinical changes

Body weight of mice was determined weekly as described by El-Arab *et al.* (2006) using an electronic balance (Mettler PM34, DeltaRange[®]), commencing week 0 pre-mycotoxin exposure (1 week pre-infection) for 7 weeks post-commencement of OTA feeding (6 weeks post-infection duration). All mice as detailed in Table 2 at different intervals were weighed and then bled. Blood (20 µl) from mouse tail snip method was examined daily for parasites from the 2nd day post-infection for the first 2 weeks, every second day for the next 4 weeks and twice weekly for further 4 weeks. The matching technique of Herbert and Lumsden (1976) was used to assess parasitaemia levels. Fifty microlitres of tail blood was collected once a week, analysed by automated Coulter Counter (Beckman Coulter[®] A^C-T diffTM) and a full haemogram of each of the experimental mouse obtained. Thin blood smears were prepared, fixed and stained

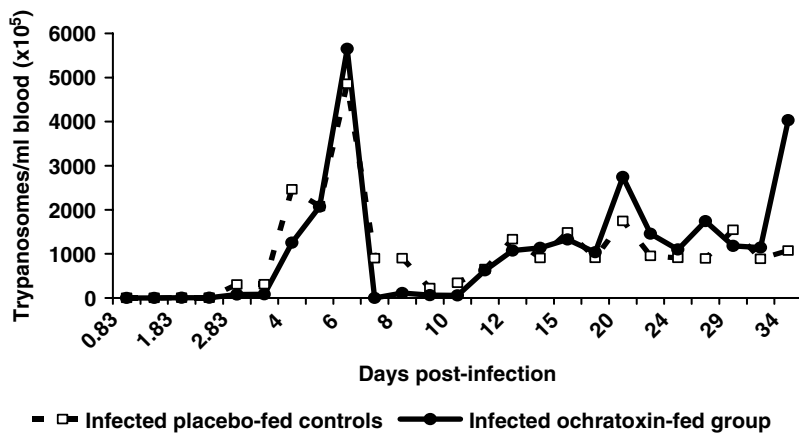


Fig. 1. Parasitaemia pattern in mice fed ochratoxin and infected with *Trypanosoma b. rhodesiense*.

with Giemsa stain for differential cell counts (DCC) (Bain and Bates, 2001; Baker *et al.* 2001).

The pre-patent period (PPP), i.e. the time between infection and appearance of trypanosomes in the blood, for each mouse was determined and recorded. The survival times for each animal i.e. time the animal took to succumb to disease in the absence of chemotherapy, were monitored for 67 days post-trypanosome infection. This time was based on maximum survival time of 54 days observed in *T. b. rhodesiense*-infected mice (Fink and Schmidt, 1979), to which 2 weeks was added to make sure that time to death event for all mice was observed since the KETRI 3741 clone used in the present study was not well characterized. For animals surviving beyond this period, the survival time was recorded as 67 days and categorized as censored data. The clinical picture was determined daily as described by Gichuki and Brun (1999). Two animals per group were randomly selected, sacrificed on the last day of OTA exposure (30 day post-commencement of ochratoxin administration, i.e. 23 days post-infection), and the spleen weight: body weight ratio recorded. The gross pathology and histopathology of mice were also determined. After euthanasia, autopsy was conducted, major organs were harvested, stored in formalin, and histologically processed and slides stained with Haematoxylin and Eosin (Drury and Wallington, 1980). The prepared slides were then examined under the microscope.

Statistical analysis

Parasitaemia, PPP and spleen weight data were subjected to analysis of variance and mean separation using SAS (SAS Institute Inc., Cary NC, USA, 1999–2001) and StatView (SAS Institute, Version 5.0.1) statistical packages. Skewed haematological data were first subjected to the square root transformation, $\sqrt{x+1}$, and then subjected to repeated measures analysis. Due to the unbalanced nature of the data, least square means were calculated.

Survival data analysis was carried out using the Kaplan-Meier method for determination of survival distribution function. Rank tests of homogeneity were used to determine the effect of treatment on early (during early phase of infection) and longer (during late phase of infection) survival times respectively (Everitt and Der, 1998).

RESULTS

Parasitaemia development

The PPP of the *T. b. rhodesiense*-infected OTA-fed mice (Gp. A) was 2.58 ± 0.2 mean days which was significantly ($P < 0.05$) shorter than the *T. b. rhodesiense*-infected placebo-fed controls (Gp. B; 3.26 ± 0.1 mean days). The pattern of parasitaemia is shown in Fig. 1, and was characterized by 2 prominent peaks; the first occurring in the first week of infection followed by a smaller wave that persisted until death. Although there was no significant difference ($P > 0.05$) in the level of parasitaemia in the second peak between the groups, the infected ochratoxin-fed mice (Gp. A) showed a higher second peak than the infected placebo-fed controls (Gp. B).

Clinical changes and survival

The clinical signs of all the *T. b. rhodesiense*-infected mice (Gps A, B and D) included lethargy, dyspnoea, raised hair coat, facial and scrotal oedema. These signs were more pronounced in the infected OTA-fed mice (Gp. A) than in the infected placebo-fed controls (Gp. B), especially dyspnoea. The clinical signs became more severe starting 24 days post-infection and were more pronounced compared to raised hair coat, poor body condition, lethargy, facial and eyelid oedemas observed in the uninfected OTA-fed mice (Gp. C). Fig. 2 shows the body weights of the experimental mice. While weight gain was observed in groups A, C and E, the uninfected naïve controls (Gp. E) maintained higher body

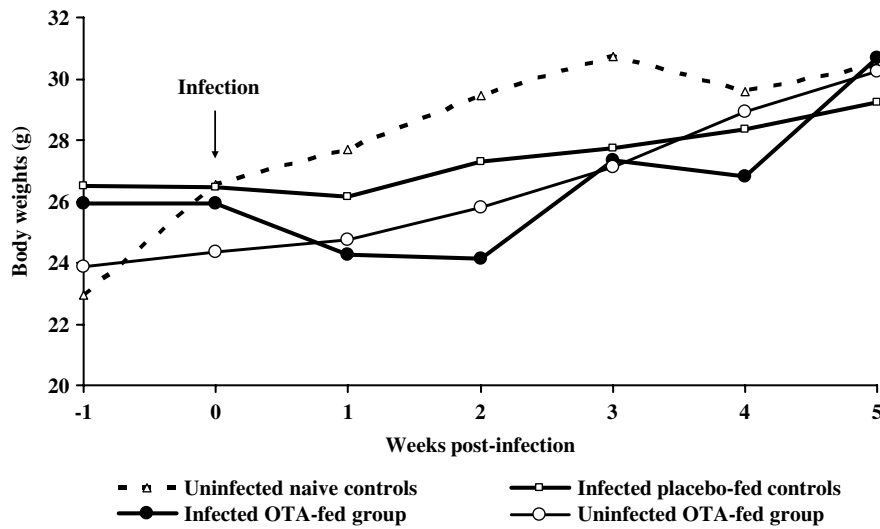


Fig. 2. Body weights of mice fed ochratoxin and infected with *Trypanosoma b. rhodesiense* at different time intervals.

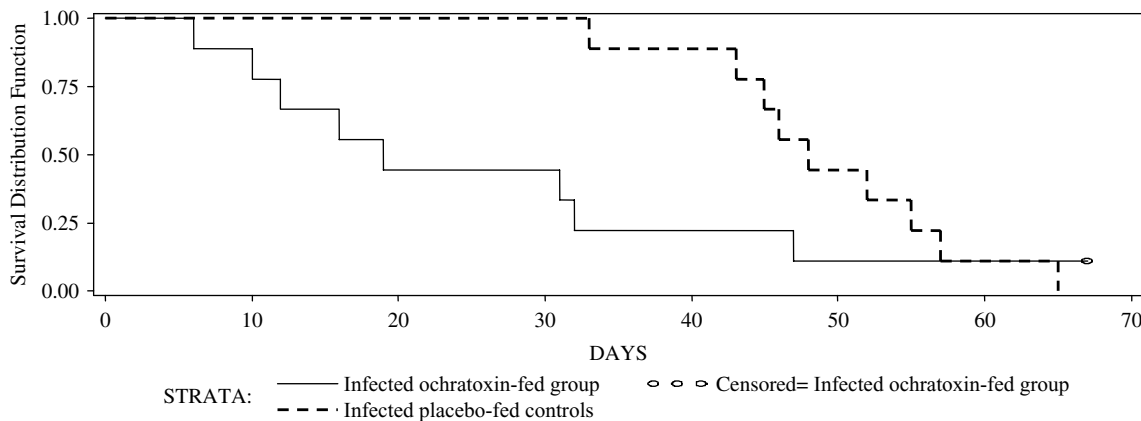


Fig. 3. Survival distribution function of mice fed ochratoxin A and infected with *Trypanosoma b. rhodesiense*.

weights throughout the experiment compared to the infected groups, with the infected OTA-fed mice (Gp. A) having the least values. However, the changes in body weights were not significantly different ($P < 0.05$) between the infected groups (Gps A and B) or between uninfected OTA-fed mice (Gp. C) and uninfected naïve controls (Gp. E).

Fig. 3 shows the survival distribution functions for the trypanosome-infected OTA-fed mice (Gp. A) and the trypanosome-infected placebo-fed controls (Gp. B). The survival for the *T. b. rhodesiense*-infected mice ranged from 6 to 47 days for the OTA-fed group (Gp. A) compared to 33 to 65 days for the infected placebo-fed controls (Gp. B). The OTA-fed group experienced more deaths during the early phase of the disease with the first death occurring on day 8 post-infection (p.i.) compared to day 33 p.i. in the controls. The rank tests of homogeneity showed that the Wilcoxon test P -value (0.01) was both significant ($P < 0.05$) and less than that of the Log Rank test (0.15). This indicated that the two groups differed primarily at early survival times with significantly ($P < 0.05$) shorter early survival times in the

OTA-fed group (Gp. A) compared to the placebo-fed controls (Gp. B).

Table 2 shows the number of mice sampled at various time-intervals. Groups A, B, C, D, E had 11, 12, 9, 6, 6 mice respectively during infection, and 8, 12, 9, 6 mice respectively at 3 weeks post-mycotoxin exposure (p.m.e.), 5, 10, 7, 4, 4 mice in that order at 5 weeks p.m.e., while 1, 3, 7, 0, 4 mice were left respectively at 9 weeks p.m.e.

Clinical pathological changes

There was no difference in pathological changes between the infected placebo-fed (Gp. B) and infected naïve control (Gp. D) groups. Red cell counts (RCC) (Fig. 4), packed cell volume (PCV) (Fig. 5) and haemoglobin levels (Hb) (Fig. 6) dropped while mean corpuscular volume (MCV) increased (Fig. 7) in all *T. b. rhodesiense*-infected mice (Gps A and B) from second week post-infection compared to the uninfected naïve controls (Gp. E). Mild reduction in RCC, PCV and Hb with normal MCV was observed in uninfected OTA-fed mice (Figs 4–7). These

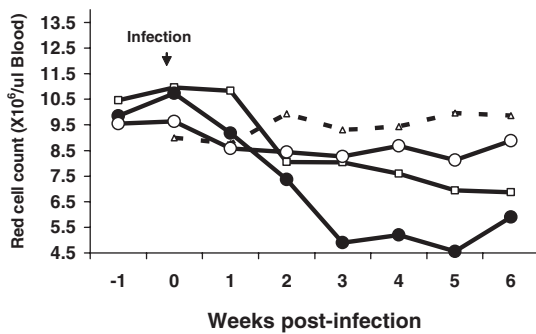


Fig. 4. RCC

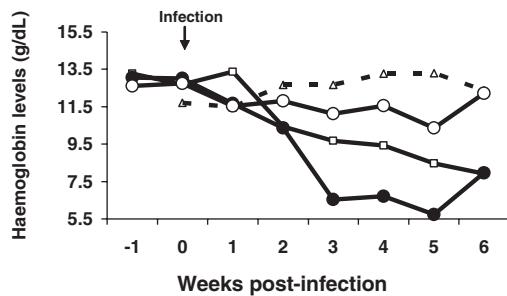


Fig. 6. Hb

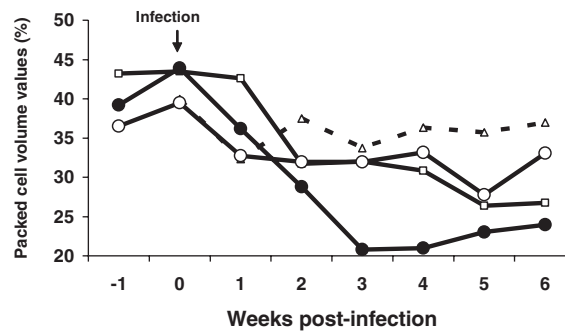


Fig. 5. PCV

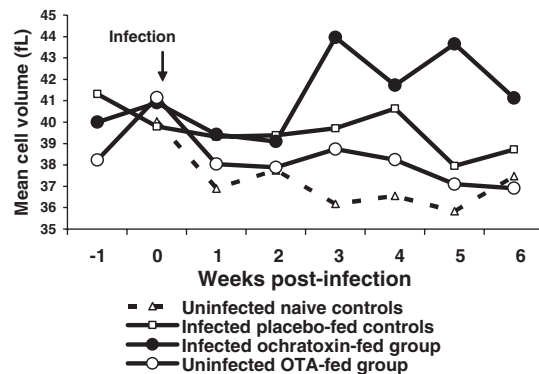


Fig. 7. MCV

Figs 4–7. Haematological changes at different time-intervals in mice fed ochratoxin and infected with *Trypanosoma b. rhodesiense*.

changes were more pronounced in the infected ochratoxin-fed group (Gp. A). The RCC, PCV and Hb were significantly lower ($P < 0.05$) while the mean corpuscular volume (MCV) was significantly ($P < 0.05$) higher in the infected ochratoxin-fed mice (Gp. A) than in the infected placebo-fed controls (Gp. B).

Grossly, the infected placebo-fed (Gp. B) and infected naïve (Gp. D) control mice had similar pathology which included emaciation, hepatosplenomegaly, ascites, liver and kidney capsular haemorrhages, heart congestion, cerebral oedema and hydrothorax. Histologically, there was perivascular inflammatory cell infiltration in the liver, heart and kidneys. The kidneys also showed fatty degeneration and necrosis of tubular cells. The gross lesions in the uninfected OTA-fed group (Gp. C) were liver jaundice, ulcerative gastritis and petechiae haemorrhage of kidney capsule. There was histological evidence of minimal inflammatory cell infiltrations, congestion, interstitial oedema, minimal hepatocellular fatty degeneration and coagulative necrosis in the liver of group C mice (Fig. 8). Also in this group, the kidneys had haemorrhages, congestion, tubular degeneration, necrosis and casts within tubular lumen and scanty inflammatory cell infiltrations (Fig. 9).

Mice in the infected OTA-fed group (Gp. A) had similar but more severe lesions than the infected

placebo-fed (Gp. B), infected naïve (Gp. D) and uninfected OTA-fed (Gp. C) controls. These were mainly mild hepatosplenomegaly, hydrothorax, hydropericardium, congested liver and pale kidney with white pin-point areas. There was congestion, haemorrhages, fatty changes and massive perivascular infiltration with inflammatory cells (mainly lymphocytes and eosinophils) in the liver (Fig. 10) and kidney (Fig. 11). The liver had haemosiderosis and degeneration of hepatocytes while the kidneys showed degeneration of tubular cells, collapsed tubules, pinkish exudate within the tubules and interstitial oedema. There was endocarditis, pericarditis, perivascular cuffing, necrosis and fibrosis in the heart. The spleen showed macrophage and giant cell hyperplasia, expanded red pulp, and erythrophagocytosis. In addition, the infected OTA-fed mice (Gp. A) had significantly ($P < 0.05$) smaller spleen size than the infected placebo-fed controls (Gp. B) as shown in Table 3.

DISCUSSION

The results in this study showed an aggravation of clinical and pathological lesions in *T. b. rhodesiense*-infected ochratoxin-fed mice, indicating that ochratoxicosis synergizes the pathogenesis of the murine trypanosomiasis. Increased mean corpuscular volume (indicating macrocytosis), dyspnoea, splenic

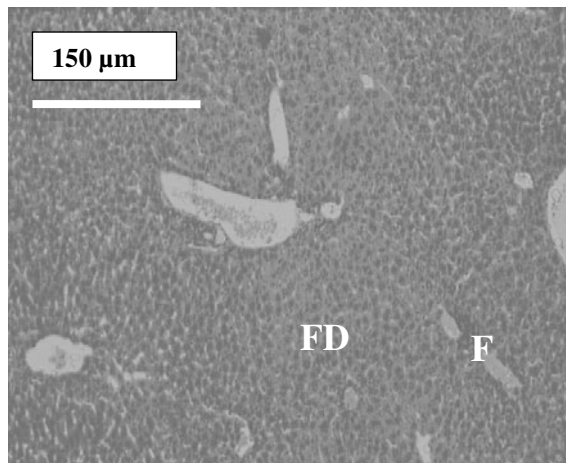


Fig. 8

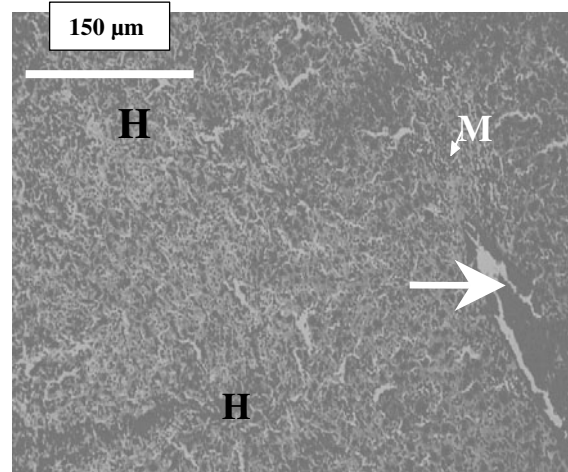


Fig. 10

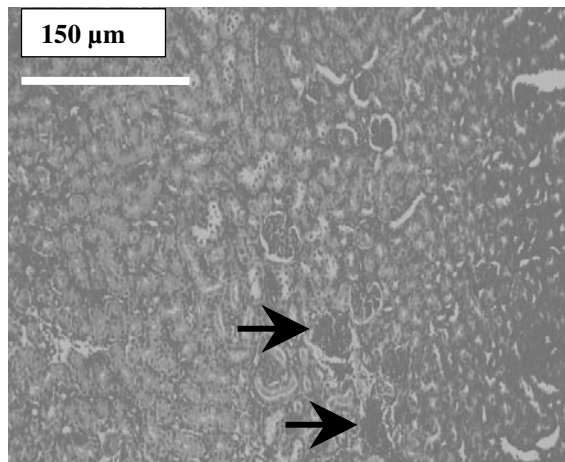


Fig. 9

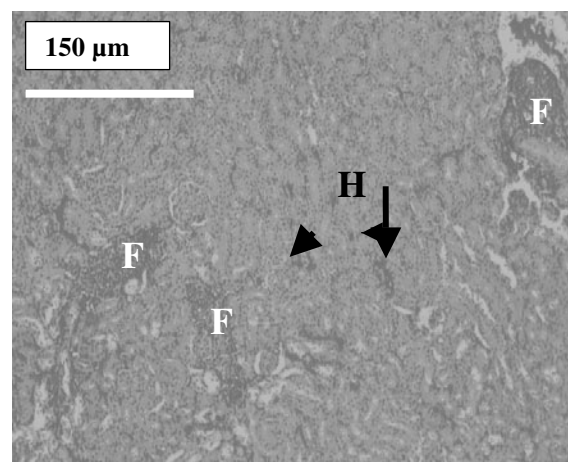


Fig. 11

Figs 8–11. Histopathological changes in the experimental mice. Hepatocellular fatty degeneration (FD) and scanty inflammatory cells (F) in the liver of uninfected OTA-fed mice (Fig. 8) and hepatitis in the liver of infected OTA-fed mice characterized by severe haemorrhages (H), congested vessel (arrow) and massive infiltration with mononuclear cells (M) (Fig. 10). Congestion (arrows) and few inflammatory cells in the kidneys of uninfected OTA-fed mice (Fig. 9) and perivascular inflammatory cell infiltration (F), haemorrhages (H, arrows) and pinkish exudate in renal tubules in the kidneys of infected OTA-fed mice (Fig. 11) (Haematoxylin and Eosin).

Table 3. Mean spleen size of mice fed ochratoxin and infected with *Trypanosoma b. rhodesiense*

Mice group	Mean spleen weight: body weight ratio (g/kg)
Uninfected naïve controls (clean)	0.007
Uninfected ochratoxin-fed	0.024*
Infected placebo-fed controls	0.070*
Infected ochratoxin-fed	0.029 ^{a*}

^a Significant difference in spleen sizes, between infected ochratoxin-fed mice and infected placebo-fed controls.

* Significant difference in spleen sizes, between all treated groups and uninfected naïve controls.

macrophage and giant cell hyperplasia, and erythrophagocytosis in these mice suggested severe erythropoietic crises. Aggravated anaemia observed in the

trypanosome-infected ochratoxin-fed animals was expected since anaemia in trypanosomosis and ochratoxicosis is well documented in various animal species. However, anaemia is attenuated by the anti-inflammatory drugs dexamethasone and hydrocortisone in *T. brucei*-infected mice (Balber, 1974; Halliwell and Gorman, 1989). This shows that while these corticosteroids influence anaemia through immunosuppression (Balber, 1974), a different pathway could be at play for the ochratoxin-mediated exacerbation of anaemia in the present study. The mechanism(s) by which OTA aggravated pathogenesis of anaemia in the present study could involve down-regulation of erythropoietin activity (Naessens *et al.* 2005) by ochratoxin A. Indeed severe nephritis was observed in the infected ochratoxin-fed mice. Hepatic haemosiderosis and severe haemorrhages in infected OTA-fed mice could also have exacerbated anaemia. This is not surprising since defects in red

blood cells have been reported in ochratoxicosis (Gupta *et al.* 1983; Albassam *et al.* 1987) and trypanosomosis (Kagira *et al.* 2007b).

Histopathological evidence suggested exacerbation of inflammation in the trypanosome-infected OTA-fed mice in this study. Ochratoxicosis aggravated the inflammation observed in the kidney, liver and heart. The observed lesions have been reported before in trypanosomosis (Stephen, 1986; Maina *et al.* 2003) and ochratoxicosis (Albassam *et al.* 1987; JECFA 47, 2001; Carlson and Ensley, 2003; El-Arab *et al.* 2006). OTA is a potent hepatotoxic and nephrotoxic (Smith and Moss, 1985) and could have promoted the degeneration of parenchymal cells in this study as has been observed by other workers (El-Arab *et al.* 2006). The severe inflammatory cell infiltration in the infected OTA-fed mice could have resulted from the increased number of necrotic cells (Anderson, 1985). The observed inflammatory eosinophils in the liver and kidney (Stephen, 1986) could suggest type I hypersensitivity reactions (Anderson, 1985) which has been reported during trypanosomosis (Ben-Rashed *et al.* 2003). Aggravation of renal, facial and scrotal and generalized oedemas, and hydropericardium in the OTA-fed mice was probably secondary to the observed acute renal tubular cell injury.

Ochratoxin A rendered the host more susceptible to infection by significantly reducing the PPP and inducing a more virulent infection. This agrees with findings by Sacks *et al.* (1980) who found a correlation between PPP and virulence of trypanosomes. The shortened PPP by OTA in the present study may be attributed to its immunosuppressive effects leading to increased host susceptibility. Antibody response, an important defence mechanism against trypanosome invasion (Njiru *et al.* 2000; Lejon *et al.* 2003), has been shown to be depressed by OTA in various animals (Dwivedi and Burns, 1984; Bondy and Pestka, 2000; Al-Anati and Petzinger, 2006). Primarily, IgM production (Dwivedi and Burns, 1984; Bondy and Pestka, 2000) is reduced by blocking protein synthesis through inhibition of phenylalanyl t-RNA synthetase (Pier and McLoughlin, 1985). Indeed OTA could have affected the influence of *T. b. rhodesiense* on the spleen similar to the low degree of splenomegaly reported in cyclophosphamide-injected *T. lewesi*-infected rats (Budovsky *et al.* 2006). Further, splenic atrophy in OTA-exposed mice (Gupta *et al.* 1983) was suggested to be due to induced suppression of splenic antibody response (Dwivedi and Burn, 1984; Pier and McLoughlin, 1985) and may lead to the increased host susceptibility to trypanosome infection.

The survival time of *T. b. rhodesiense*-infected mice has been estimated between 6 and 9 weeks (Fink and Schmidt, 1979) and between 3 and 12 weeks for KETRI 3741 (Kagira *et al.* 2007a), consistent with survival time of between 3 and 7 weeks in the infected

placebo-fed control mice in the present study. However, ochratoxicosis significantly reduced the host survival times with higher death rates in the early phase of the infection in the OTA-fed mice causing a more acute disease. This differed with results of similar studies on malarial parasites where, in *Plasmodium berghei*-infected mice, mycotoxicosis increased the host survival time, an effect that was attributed to direct toxicity of aflatoxin B₁ on the parasite (Hendrickse *et al.* 1986; Young *et al.* 1988). This difference in the observations may be due to differences in the parasite species and the mycotoxin used. In the present study, ochratoxicosis and trypanosomosis could have worked in synergy to exacerbate the pathological lesions. Budovsky *et al.* (2006) reported similar cyclophosphamide-mediated aggravation of pathological lesions in *T. lewesi*-infected rats, while Sandhu *et al.* (1998) observed OTA-mediated exacerbation of anaemia and biochemical changes in chicks infected with inclusion body hepatitis virus. Kumar *et al.* (2003) also observed increased mortality and severity of *Escherichia coli* infection in OTA-fed poultry. The mild retarded growth rate observed in the infected OTA-fed mice was expected since ochratoxin A and trypanosomosis are known to impede growth in animals (Stephen, 1986; Smith and Moss, 1985).

In conclusion, the study has shown that continuous dosing of mice with OTA aggravated the clinical and pathological aspects of *T. b. rhodesiense* (KETRI 3741) infection in mice. This aggravation may have some implications on the clinical progression and outcome of sleeping sickness and animal trypanosomosis cases in Africa where the two conditions occur concurrently. Indeed, global climatic changes which could result in favourable conditions for mycotoxin production, and the significance of interaction of mycotoxicoses with various infectious agents that may lead to emergence of new disease patterns has already been recognized (Minakshi, 2005). It is therefore important to consider the effects of ochratoxicosis during control programmes of trypanosomosis and other tropical parasitic diseases in the field. Further, future studies should evaluate the biological mechanisms involved in the exacerbation of pathogenesis of trypanosomosis by ochratoxin A.

Mr R. S. I. Karuku is highly acknowledged posthumously for inspiring the first author to the world of food poisoning, which is the main drive in this communication. We thank the Director, Kenya Agricultural Research Institute (KARI) and the Centre Director, KARI-Trypanosomiasis Research Centre for granting permission to publish this paper. We are particularly grateful to the following KARI-TRC staff: Messrs G. Kimure, B. Wanyonyi, Peter Githiri, A. Mageto, Ms J. Kagendo, Ms. S. Kairuthi, Ms S. Nabisino, Ms C. Kahi, who assisted in data collection and Mr P. Kahuria and Ms T. Kamau who provided the experimental animals. Drs Leonard Munga and John Thuita corrected the manuscript and optimized electronic cell

counting procedures respectively. This work was funded by Kenya Agricultural Productivity Programme (KAPP) through KARI.

REFERENCES

- Al-Anati, L. and Petzinger, E.** (2006). Immunotoxicity of ochratoxin A. *Journal of Veterinary Pharmacology and Therapeutics* **29**, 79–90.
- Albassam, M. A., Yong, S. I., Bhatnagar, R., Sharma, A. K. and Prior, M. G.** (1987). Histopathologic and electron microscopic studies on the acute toxicity of ochratoxin A in rats. *Veterinary Pathology* **24**, 427–435.
- Anderson, J. R.** (1985). *Muir's Textbook of Pathology*, 12th Edn. Edward Arnold, London, New York, Melbourne, Auckland.
- Anyanwu, E. C., Morad, M and Campbell, A. W.** (2004). Metabolism of mycotoxins, intracellular functions of vitamin B12 and neurological manifestations in patients with chronic toxigenic mold exposures: A Review. *The Scientific World Journal* **4**, 736–745.
- Assaf, H., Azouri, H. and Pallardy, M.** (2004). Ochratoxin A induces apoptosis in human lymphocytes through down regulation of Bcl-x_L. *Toxicological Sciences* **79**, 335–344.
- Azziz-Baumgartner, E., Lindblade, K., Giesecker, K., Rogers, H. S., Kieszak, S., Njapau, H., Schleicher, R., McCoy, L. F., Misore, A., DeCock, K., Rubin, C., Slutsker, L. and the Aflatoxin Investigative Group** (2005). Case-control study of an acute aflatoxicosis outbreak, Kenya, 2004. *Environmental Health Perspectives* **113**, 1779–1783.
- Bain, B. J. and Bates, I.** (2001). Basic haematological techniques. In *Dacie and Lewis Practical Haematology*, 9th Edn. (ed. Lewis, E. M., Bain, B. J. and Bates, I.), pp. 19–46. Churchill Livingstone, London, UK.
- Baker, F. J., Silverton, R. E. and Pallister, C. J.** (2001). *Introduction to Medical Laboratory Technology*, 7th Edn. Oxford University Press, London, New York, New Delhi.
- Balber, A. E.** (1974). *Trypanosoma brucei*: Attenuation by corticosteroids of anaemia of infected mice. *Experimental Parasitology* **35**, 209–218.
- Ben-Rashed, M., Ingram, G. A. and Pentreath, V. W.** (2003). Mast cells, histamine and the pathogenesis of intestinal damage in experimental *Trypanosoma brucei* infections. *Annals of Tropical Medicine and Parasitology* **97**, 803–809.
- Bondy, G. S. and Pestka, J. J.** (2000). Immunomodulation by fungal toxins. *Journal of Toxicology and Environmental Health* **3**, 109–143.
- Budovsky, A., Prinsloo, I. and El-On, J.** (2006). Pathological developments mediated by cyclophosphamide in rats infected with *Trypanosoma lewesi*. *Parasitology International* **55**, 237–242.
- Carlson, M. P. and Ensley, S. M.** (2003). Understanding fungal (mold) toxins (mycotoxins). NebGuide published <http://www.fda.gov/cvm/>.
- Cukrova, V., Longrova, E. and Akao, M.** (1991). Effects of aflatoxin B1 on myelopoiesis *in vivo*. *Toxicology* **70**, 203–211.
- Drury, R. A. B. and Wallington, E. A.** (1980). *Carleton's Histological Technique*, 5th Edn. Oxford University Press, Oxford New York Toronto.
- Dwivedi, P. and Burns, R. B.** (1984). Effects of ochratoxin A on immunoglobulin in broiler chicks. *Research in Veterinary Science* **36**, 117–121.
- El-Arab, A. M. E., Girgis, S. M., Hegazy, E. M. and El-Khalek, A. B. A.** (2006). Effect of dietary honey on intestinal microflora and toxicity of mycotoxins in mice. *BMC Complementary and Alternative Medicine* **6**, 1–13.
- Everitt, B. S. and Der, G.** (1998). *A Handbook of Statistical Analysis Using SAS*. Boca Raton, London, New York, Washington D. C.
- FAO/UNEP** (1977). Recommended practices for the prevention of mycotoxins in food, feed and their products. *Draft of a Document for the Joint FAO/WHO/UNEP Conference on Mycotoxins*, Nairobi, 19–27 September, 1977.
- Fink, E. and Schmidt, H.** (1979). Meningoencephalitis in chronic *Trypanosoma brucei rhodesiense* infection of the white mouse. *Tropenmedizin und Parasitologie* **30**, 206–211.
- Fink, E. and Schmidt, H.** (1980). Preclinical testing of potential trypanocidal drugs in primates: preliminary investigation of an experimental diamidine in vervets. In *Recent Developments in Medical Research in East Africa* (ed. Njogu, A. R., Tukei, P.M and Roberts, J. M. D.), pp. 173–182. KETRI/KEMRI, Nairobi, Kenya.
- Gichuki, C. and Brun, R.** (1999). Animal models of CNS (second-stage) sleeping sickness. In *Handbook of Animal Models of Infection*, (ed. Zak, O and Sande, M.), pp. 795–800. Academic Press, London, UK.
- Gupta, M., Sasmal, D., Bandyopadhyay, S., Bagchi, G., Chatterjee, T. and Dey, S.** (1983). Hematological changes produced in mice by ochratoxin A and citrinin. *Toxicology* **26**, 55–62.
- Halliwell, R. E. W. and Gorman, N. T.** (1989). Anti-inflammatory drugs, immuno-suppressive agents and immuno-modulators. In *Veterinary Clinical Immunology* 9th Edn. (ed. Pedersen, D.), pp. 493–507. W.B. Saunders Company: Philadelphia, PA, USA.
- Hendrickse, R. G., Lamplugh, S. M. and Maegraith, B. G.** (1986). Influence of aflatoxin on nutrition and malaria in mice. *Transactions of the Royal Society of Tropical Medicine and Hygiene* **80**, 846–847.
- Herbert, W. J. and Lumsden, W. H. R.** (1976). *Trypanosoma brucei*: a rapid “Matching” method for estimating the host's parasitaemia. *Experimental Parasitology* **40**, 427–431.
- JECFA**, **47** (2001). Evaluation of certain mycotoxins. WHO Food Additives Series No. 47/FAO Food and Nutrition Paper 74, 2001 nos. 1011–1020 Inchem.
- Kagira, J. M., Ngotho, M. and Thuita, J.** (2007 a). Development of a rodent model for late stage rhodesian sleeping sickness. *Journal of Protozoology Research* **17**, 48–56.
- Kagira, J. M., Thuita, J. K., Ngotho, J. M., Mdachi, R. E., Mwangangi, D. M. and Ndung'u, J. M.** (2007 b). Haematology of experimental *Trypanosoma brucei rhodesiense* infection in Vervet Monkeys. *African Journal of Health Sciences* **13**, 59–65. Available at Bionline International 1989–2007, last up-dated on 23/02/07.
- Kimathi, G. M. and Siboe, G. M.** (1994). Maize flour contaminated with toxigenic fungi and mycotoxins.

- Proceedings of the 15th Annual African Health Science Congress*, KEMRI HQ, Nairobi, 7–11 February, 1994. KETRI/KEMRI, Nairobi, Kenya.
- Kumar, A., Jindal, N., Shukla, C. L., Pal, Y., Ledoux, D. R. and Rottinghaus, G. E.** (2003). Effect of ochratoxin A on *Escherichia coli*-challenged broiler chicks. *Avian Diseases* **47**, 415–424.
- Lejon, V., Sindic, C. J. M., Van Antwerpen, M. P., Doua, F., Dje, N., Solano, P., Jamonneau, V. and Buscher, P.** (2003). Human African trypanosomiasis: quantitative and qualitative assessment of intrathecal immune response. *European Journal of Neurology* **10**, 711–719.
- Maina, N., Ngotho, J. M., Njiru, Z. K., Karanja, W. M., Gem, C. O., Karanja, S. M., Kibugu, J. K. and Ndung'u, J. M.** (2003). Efficacy of Trypan[®] (Diminazene Di-aceturate) in camels infected with *Trypanosoma evansi*. *Journal of Camel Practice and Research* **10**, 51–55.
- Minakshi, D.** (2005). Pathological techniques in diagnosis of animal, bird and fish disease. *Current Science* **89**, 605.
- Naessens, J., Kitani, H., Nakamura, Y., Yagi, Y., Sekikawa, K. and Iraqi, F.** (2005). TNF- α mediates the development of anaemia in a murine *Trypanosoma brucei rhodesiense* infection, but not the anaemia associated with a murine *Trypanosoma congolense* infection. *Clinical and Experimental Immunology* **139**, 405–410.
- Njiru, Z. K., Olaho-Mukani, W., Khaemba, B. M., Ochieng, R. S. and Ndung'u, J. M.** (2000). Haematological and serological changes during acute *Trypanosoma evansi* infection in dromedary camels (*Camelus dromedarius*). *Journal of Camel Practice and Research* **7**, 113–116.
- Oswald, I. P., Bouhet, S., Marin, D. E., Pinton, P. and Taranu, I.** (2005). Mycotoxin effects on the pig immune system. <http://www.engormix.com>.
- Pier, A. C. and McLoughlin, M. E.** (1985). Mycotoxic suppression of immunity. In *Trichothecenes and other mycotoxins: Proceedings of the International Mycotoxin Symposium, Sydney, Australia, 1984* (ed. Lacey, J.), pp. 507–519. John Wiley and Sons, New York, USA.
- Sacks, D. L., Selkirk, M., Ogilvie, B. M. and Askonas, B. A.** (1980). Intrinsic immunosuppression activity of different trypanosome strains varies with parasite virulence. *Nature, London* **283**, 476–478.
- Sandhu, B. S., Singh, B. and Brar, R. S.** (1998). Haematological and biochemical studies in broiler chicks fed ochratoxin A and inoculated with inclusion body hepatitis virus, singly and in concurrence. *Veterinary Research Communications* **22**, 335–346.
- Scott, P. M.** (1995). Natural toxins: subchapter 1 -Mycotoxins. In *Official Methods of Analysis* (ed. Cunniff, P.), pp. 1–53 Health Protection Branch, Canada. AOAC International.
- Smith, J. E. and Moss, M. O.** (1985). *Mycotoxins: Formation, Analysis and Significance*. John Wiley and Sons, New York, USA.
- Stephen, L. E.** (1986). *Trypanosomiasis: a Veterinary Perspective*. 1st Edn. Pergamon Press, Oxford, New York, Beijing, Frankfurt Sao Paulo, Sydney, Tokyo, Toronto.
- World Health Organization** (2004). *Trypanosomiasis*. WHO Division of Control of Tropical Diseases. Internet Homepage updated 29 October, 2004. URL:<http://www.med.sc.edu.85/trypanosomiasis.htm>. World Health Organization, Geneva, Switzerland.
- Williams, J. H., Phillips, T. D., Jolly, P. E., Stiles, J. K., Jolly, C. M. and Aggarwal, D.** (2004). Human aflatoxicosis in developing countries: a review of toxicology, exposure, potential health consequences and interventions. *American Journal of Clinical Nutrition* **80**, 1106–1122.
- Young, R. H., Hendrickse, R. G., Maxwell, S. M. and Maegraith, B. G.** (1988). Influence of aflatoxin on malarial infection in mice. *Transactions of the Royal Society of Tropical Medicine and Hygiene* **82**, 559–560.