

Morphological and molecular characterization of *Plasmodium cathemerium* (lineage PADOM02) from the sparrow *Passer domesticus* with complete sporogony in *Culex pipiens* complex

Research Article

Cite this article: Aly MZY, Mohamed III, Sebak SI, Vanstreels RET, El gendy AM (2020). Morphological and molecular characterization of *Plasmodium cathemerium* (lineage PADOM02) from the sparrow *Passer domesticus* with complete sporogony in *Culex pipiens* complex. *Parasitology* **147**, 985–993. <https://doi.org/10.1017/S0031182020000566>

Received: 23 December 2019

Revised: 14 March 2020

Accepted: 23 March 2020



First published online: 27 April 2020

Key words:

Avian malaria; Culicidae; cytochrome b; Haemosporida; light microscopy; PCR; sporogony; vector-borne pathogen

Author for correspondence:

Azza M. El gendy,
E-mail: aelgendy@sci.cu.edu.eg

Mohamed Z. Y. Aly¹, Ibrahem I. I. Mohamed¹, Salwa I. Sebak¹,
Ralph E. T. Vanstreels^{2,3}  and Azza M. El gendy⁴ 

¹Faculty of Science, Department of Zoology, South Valley University, Qena, Egypt; ²Marine Apex Predator Research Units (MAPRU), Institute for Coastal and Marine Research, Nelson Mandela University, South Africa; ³Department of Zoology, DST-NRF Centre of Excellence at the Fitz Patrick Institute for African Ornithology, Nelson Mandela University, South Africa and ⁴Faculty of Science, Department of Entomology, Cairo University, Giza, PO Box 12613, Egypt

Abstract

Avian malaria is a mosquito-borne disease caused by *Plasmodium* spp. protozoa. Although these parasites have been extensively studied in North America and Eurasia, knowledge on the diversity of *Plasmodium*, its vectors and avian hosts in Africa is scarce. In this study, we report on natural malarial infections in free-ranging sparrows (*Passer domesticus*) sampled at Giza Governorate, Egypt. Parasites were morphologically characterized as *Plasmodium cathemerium* based on the examination of thin blood smears from the avian host. Sequencing a fragment of the mitochondrial cytochrome *b* gene showed that the parasite corresponded to lineage PADOM02. Phylogenetic analysis showed that this parasite is closely related to the lineages SERAU01 and PADOM09, both of which are attributed to *P. cathemerium*. Experimental infection of *Culex pipiens* complex was successful, with ookinetes first detected at 1-day post infection (dpi), oocysts at 4 dpi and sporozoites at 6 dpi. The massive infection of the salivary glands by sporozoites corroborates that *Cx. pipiens* complex is a competent vector of PADOM02. Our findings confirm that *Plasmodium* lineage PADOM02 infects sparrows in urban areas along the Nile River, Egypt, and corroborate that *Cx. pipiens* complex is a highly competent vector for these parasites. Furthermore, our results demonstrate that this lineage corresponds to the morphospecies *P. cathemerium* and not *P. relictum* as previously believed.

Introduction

Climate change may lead to the increased transmission of, and shift the spatial distribution of infectious diseases (Patz *et al.*, 1996). In combination with other anthropogenic factors such as increased housing, settlements, and environmental pollution, extensive tropical urbanization, colonization, and changing lifestyle patterns, these changes have produced new breeding areas for vectors of many diseases, with significant implications for human and animal health (Weaver and Reisen, 2010; Hongoh *et al.*, 2012; Carvalho *et al.*, 2017). Mosquitoes are a major public health concern, as they play a vital role in transmitting human and animal diseases (Tandina *et al.*, 2018). *Culex pipiens* L. (Culicidae: Diptera) is a cosmopolitan mosquito causing nuisance and transmitting several significant pathogens such as West Nile virus, St. Louis encephalitis virus, Zika virus, Sindbis/Sindbis-like viruses, *Usutu* flavivirus, avian malaria (*Plasmodium* spp.) and filarial worms (Farajollahi *et al.*, 2011).

Research on avian malarial parasites has been heavily focused towards detection and understanding avian host–parasite relationships. In contrast, few studies have been carried out on vector–parasite relationships, due to lack of available colonies of many vector mosquito species and because cultures of avian *Plasmodium* species and lineages are not easily available (Valkiūnas, 2011). The investigation of vector–parasite relationship requires a source of infective avian blood, which is not available for many of the >55 morphospecies of avian plasmodium species described to date (Valkiūnas and Iezhova, 2018).

As is the case for most of the African continent (Valkiūnas, 2005), few studies have examined the blood parasites of birds in Egypt. More than 150 species of migratory birds visit Egypt annually, in addition to 350 resident species of birds (Ibrahim, 2011). Despite this, most studies on avian malarial parasites in Egypt were conducted more than five decades ago (Haiba, 1948; Mohammed, 1958a, b; Guindy *et al.*, 1965). Only one study that detected the *Plasmodium* lineages PADOM02, PADOM16 and SGS1 in sparrows (*Passer domesticus*) sampled at Luxor (Marzal *et al.*, 2011) has been conducted since the development of molecular methods to study avian malaria. More detailed studies on avian malaria are important, as the migratory birds might carry parasites across international boundaries and potentially lead to

significant health impacts and mortality of both wild and domestic birds (Žiegytė *et al.*, 2014; Valkiūnas *et al.*, 2015, 2017; Schoener *et al.*, 2019).

To investigate vector–parasite relationships of avian *Plasmodium* spp., mosquito infectivity, laboratory experiments must be conducted with parasites obtained from natural infections. Polymerase chain reaction (PCR) is a highly sensitive tool to detect DNA from parasites in both avian hosts and mosquito vectors, but microscopic detection of sporozoites remains necessary to verify sporogony and to identify competent vectors (Valkiūnas, 2011). However, the morphology of life stages within the vector (oocysts and sporozoites) does not vary sufficiently across *Plasmodium* species to allow for the identification of parasite species or lineage by microscopy (Santiago-Alarcon *et al.*, 2012), and therefore a combination of morphological and PCR studies is necessary (Valkiūnas, 2011). When possible, the morphology of the parasite within erythrocytes (trophozoites, meronts and gametocytes) following experimental infection of an avian host is valuable in order to confirm the parasite morphospecies (Valkiūnas and Iezhova, 2018). This combined approach has been adopted in studies of human malaria parasites and has been increasingly employed to study avian malarial parasites (Kim and Tsuda, 2010; Kazlauskienė *et al.*, 2013; Žiegytė *et al.*, 2014; Valkiūnas *et al.*, 2015).

In this study, we characterize *Plasmodium* lineage PADOM02 from naturally infected free-ranging sparrows (*P. domesticus*) in Giza, Egypt, including (i) morphological characterization of erythrocytic stages in the natural host, (ii) morphological characterization of the complete sporogony in *Cx. pipiens* and (iii) molecular characterization and phylogenetic analysis of the cytochrome *b* gene.

Material and methods

Detection and characterization of natural infection in sparrows

Ethics approval was obtained from the Institutional Animal Care and Use Committee of the University of Cairo for holding, transportation and laboratory maintenance of wild sparrows (CU-IF 89-19). Two hundred house sparrows (*P. domesticus*) were captured from Elsaf city, Giza Governorate, with traps and nets. The sparrows were brought to the laboratory alive and identified. A drop of blood was collected from the brachial vein of each bird to prepare blood smears, which were air-dried, fixed with methanol and stained with Giemsa. Approximately 100–150 fields were examined at low magnification (400X), and then at least 100 fields were studied at high magnification (1,000X), corresponding to a minimum 5×10^5 erythrocytes. Infection intensity, as a percentage, was estimated by counting the number of parasites per 1000 erythrocytes or per 10 000 erythrocytes if infections were very light (Godfrey *et al.*, 1987). Malaria parasites were identified following the keys provided by Valkiūnas (2005) and Valkiūnas and Iezhova (2018). Birds with mixed infections were excluded.

Experimental infection and sporogony characterization in *Cx. pipiens* complex

Mosquito larvae were obtained from breeding habitats in Giza Governorate, Egypt. Larvae were reared in the insectaries of the Department of Entomology, Faculty of Science, Cairo University, to obtain adults for morphological identification based on keys provided by Harbach (1985). A stock colony of adult *Cx. pipiens* complex was maintained at $27 \pm 2^\circ\text{C}$ and 60–70% relative humidity (RH), following methods described by Adham *et al.* (2003).

Approximately 50 unfed *Cx. pipiens* complex adult females were sexed and separated in experimental cages ($25 \times 25 \times 25 \text{ cm}^3$).

These females were deprived of a sugar solution and then were allowed to feed fully on sparrows with single natural infection of *Plasmodium* PADOM02, whose blood contained mature gametocytes (0.1–0.2 parasite per erythrocyte), as described by Valkiūnas *et al.* (2015). Single infected sparrow has been used for each replicate. Non-infected sparrows (as determined through blood smears) were used as controls. Fully fed female mosquitoes were separated in small cages with an aspirator and kept at 28°C for sporogony. A subset of control and infected females were removed and dissected as described by Valkiūnas (2005), at various intervals [(12 h, 1 day, 2 days, 3 days, 4 days, 5 days, 6 days, 7 days, 8 days, 9 days and 10 days post infection (dpi)] to investigate parasite development. Infected and control *Culex* midgut contents were stained by Giemsa stain, in the same way as blood smear (Valkiūnas, 2005), for ookinete visualization. Midgut permanent preparations were checked under binocular at 20X magnification for oocysts presence, while ookinetes and sporozoites have been examined at higher magnification. Histological preparations of midgut were prepared from infected and control females at the same time intervals then stained by hematoxylin and eosin to observe oocysts maturation. Finally, salivary glands and the residuals of the whole body (carcasses) were squashed on a slide to prepare a thick film then air-dried, fixed with methanol and stained by Giemsa (Valkiūnas *et al.*, 2013).

DNA extraction, PCR and sequencing

Plasmodium parasites were identified within 24 h by microscopic examination for sparrow blood smears and all the positive ones were used for genomic DNA extraction and PCR amplification as follows: approximately 50 μL whole blood of the infected sparrows were drawn from the brachial vein into heparinized microcapillaries and stored in SET-buffer (0.015 M NaCl, 0.05 M Tris, 0.25 M EDTA, pH 8.0) and stored at -20°C for molecular analysis (Hellgren *et al.*, 2007). The standard ammonium-acetate protocol was used for genomic DNA extraction from avian blood and *Culex* whole body after 4 and 6 days of infection (Sambrook *et al.*, 1989). Total DNA was quantified by BioPhotometer 6131 (Eppendorf, Hamburg, Germany) and analyzed on a 1% denatured agarose gel to ensure its integrity; the 260/280 and 260/230 absorbance ratios were evaluated for protein and solvent contamination. A nested-PCR protocol was used to amplify a 480-bp fragment of the mitochondrial cytochrome *b* (*cyt-b*) gene of *Haemoproteus* and *Plasmodium*, with primers HaemNF and HaemNR2 followed by primers HaemF and HaemR2 (Waldenström *et al.*, 2004). Amplifications were conducted with a 25 μL volume, with 2 μL of the first amplification product as a template for the second reaction. Amplification products were visualized on a 1% agarose gel stained with Ethidium bromide and photographed with a high-resolution gel documentation system. Uninfected house sparrow, which proved to be parasite free by microscopic examination, was used as a negative control.

Partial sequencing of cytochrome *b* gene and phylogenetic analysis

Amplification bands were excised from agarose gel and purified by Wizard SV Gel and PCR Clean-Up System kit (Promega, Madison, USA). Sanger sequencing was performed with HaemF and HaemR2 primers, with BigDye Terminator v3.1 and ABI PRISM 3100 (Applied Biosystems, Austin, USA). Resulting sequences were aligned and edited with BioEdit (Hall, 1999), and deposited in Genbank (accession code MK018109).

Phylogenetic analysis of the *cyt-b* gene sequences was conducted to compare sequences obtained in this study to publicly available sequences of avian haemosporidians from public

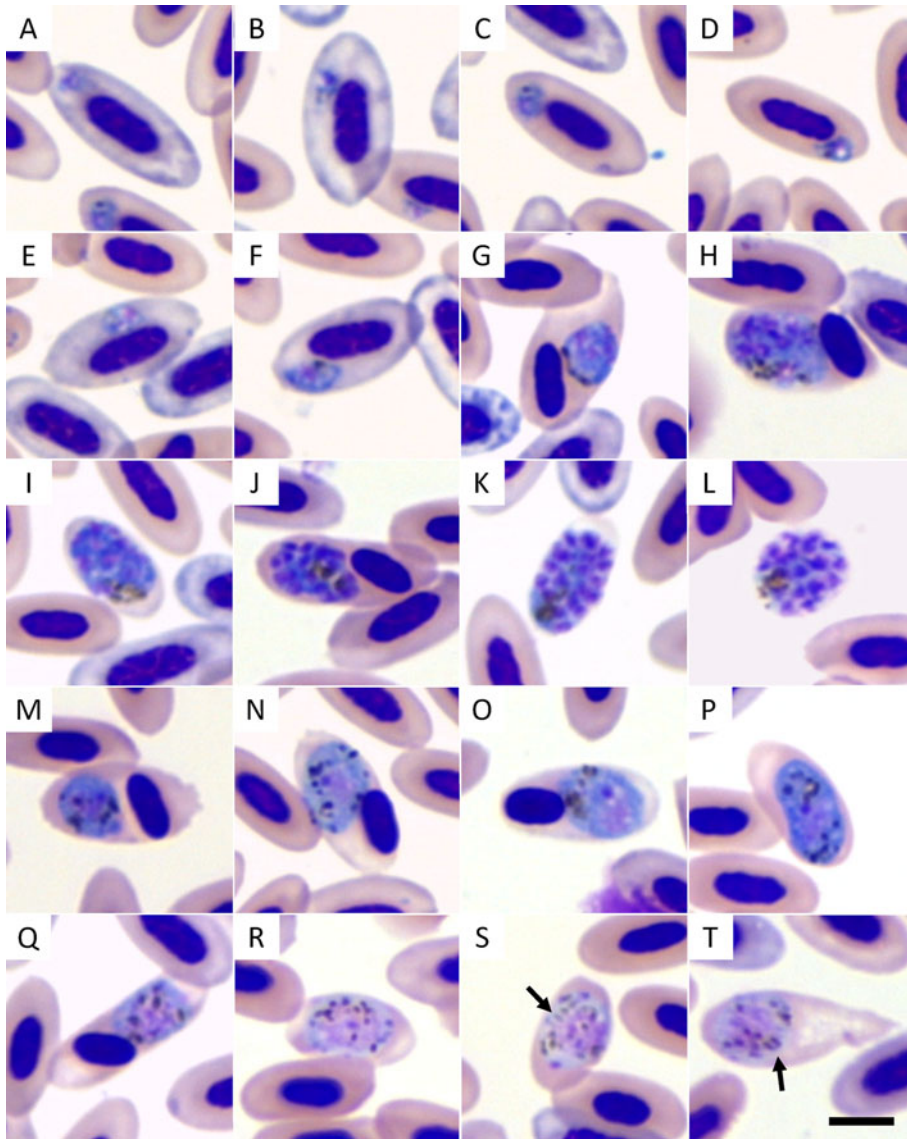


Fig. 1. *Plasmodium cathemerium* lineage PADOM02 a Giemsa-stained blood smears of a naturally infected sparrow (*Passer domesticus*). Legend: (A–F) trophozoites; (G–L) erythrocytic meronts; (M–P) macrogametocytes; (Q–T) microgametocytes. Arrows indicate rod-like pigmented granules. Scale bar = 5 μm .

databases (Table S1). Only the 479 bp segment was used in this analysis, as standardized in the MalAvi database (Bensch *et al.*, 2009). Sequences were aligned by ClustalW (Thompson *et al.*, 2002), as implemented in MEGA 6.06 (Tamura *et al.*, 2013). Bayesian phylogenetic trees were produced with MrBayes 3.2.6 (Ronquist and Huelsenbeck, 2003), based on the GTR + I + G model of nucleotide evolution recommended by jModelTest 2.1.10 (Darriba *et al.*, 2012). Two Markov chains for 10 million generations with sampling every 1000 generations; the first 2500 trees (25%) were discarded as a burn-in step and the remaining trees were used to calculate the posterior probabilities. Pairwise estimates of evolutionary distance were produced with MEGA 6.06 based on a maximum composite likelihood model, with a gamma distribution (shape parameter = 1), including transitions and transversions, and excluding ambiguous positions for each sequence pair.

Results

Morphological identification of *Plasmodium* in the avian host

Plasmodium parasite has been identified from 53 house sparrow blood smears ($n = 200$) with an overall prevalence of 26.5%. Only 3 mixed infections have been detected (1.5%) and have been excluded. The ones used in the transfection experiments

were identified as *Plasmodium* (*Haemamoeba*) *cathemerium* based on the morphological characteristics seen in blood smears from the avian host (Fig. 1) and later confirmed by PCR reaction and sequencing of Cyt b fragment. Trophozoites are present in polychromatic (Fig. 1A and B) and mature erythrocytes (Fig. 1C and D). They have an irregular shape and uneven outline, seldom touch the host cell nucleus and do not displace or only slightly displace it (Fig. 1E and F). Erythrocytic meronts are large (but do not exceed 10 μm in length) and usually roundish with abundant cytoplasm, markedly distorting the host cell and displacing the host cell nucleus (Fig. 1G, H and J) or occasionally enucleating (Fig. 1I and K) or rupturing the host cell (Fig. 1L). Pigmented granules in erythrocytic meronts are usually clumped into a spot, often near the margin of the parasite, and the number of merozoites ranges from 9 to 18 (most frequently, between 11 and 14). Macrogametocytes (Fig. 1M–P) and microgametocytes (Fig. 1Q–T) are generally roundish, markedly exceed the host cell nucleus, but neither surpass 10 μm in length nor occupy the entire cytoplasm of the host cell. Gametocytes, especially microgametocytes, frequently enucleate the host cell (Fig. 1P and R–T). Pigmented granules are randomly scattered in the cytoplasm of gametocytes; however, rod-like pigmented granules with pointed ends are occasionally present in microgametocytes (Fig. 1S and T). Large vacuoles or residual bodies are absent in all parasites, and no meronts were observed outside of the blood cells.

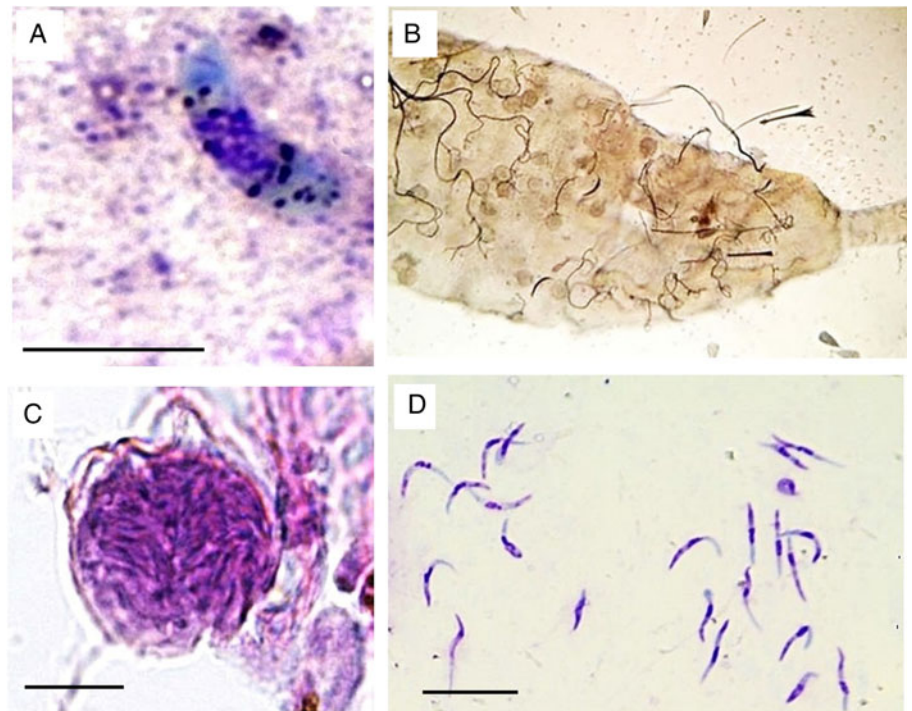


Fig. 2. *Plasmodium cathemerium* lineage PADOM02 in the tissues of experimentally-infected *Culex pipiens* complex: (A) mature ookinete in Giemsa-stained midgut contents preparation obtained 1 day post infection (dpi) (B) mosquito midgut inundated by oocyst as observed under light microscope (20X) (C) mature oocysts in hematoxylin and eosin-stained midgut histological preparations obtained 4 dpi (D) mature sporozoites in Giemsa-stained salivary gland preparations obtained 5 dpi. Scale bar = 10 μm .

Table 1. Morphometry of *Plasmodium cathemerium* lineage PADOM02 in *Culex pipiens* complex

Life stage	Mean \pm s.d. (Minimum–Maximum)
Ookinete ($n = 7$) ^a	
Length (μm)	12.23 \pm 0.79 (11.29–13.68)
Width (μm)	3.37 \pm 0.43 (2.55–3.80)
Area (μm^2)	28.90 \pm 0.58 (25.50–30.80)
Oocyst ($n = 12$) ^b	
Minimum diameter (μm)	22.42 \pm 4.23 (14.33–26.52)
Maximum diameter (μm)	25.79 \pm 3.72 (19.00–29.62)
Area (μm^2)	80.43 \pm 5.60 (53.7–88.10)
Sporozoite ($n = 21$) ^c	
Length (μm)	10.64 \pm 0.80 (9.24–12.46)
Width (μm)	1.25 \pm 0.18 (1.00–1.60)
Area (μm^2)	21.58 \pm 0.64 (18.5–27.6)

^aMethanol-fixed preparations at 1 day post infection (dpi).

^bFormalin-fixed preparations of mature parasites at 4 dpi.

^cMethanol-fixed preparations at 5 dpi.

Parasite development in *Cx. pipiens* complex

Culex pipiens complex mosquitoes were susceptible to experimental infection after being allowed to feed on sparrows with a parasitemia of 0.1 to 0.2 parasites per erythrocyte and gave positive PCR results. Ookinetes were seen in the midgut of *Cx. pipiens* complex as early as 24 h after exposure; these structures were large curved-elongated bodies (Fig. 2A, Table 1). The nuclei of ookinetes had an irregular outline and were positioned slightly laterally, and numerous dark granules were scattered in the deep-blue cytoplasm (Fig. 2A). The number of ookinetes decreased rapidly, and only very few ookinetes were seen in the midgut of mosquitoes examined 2 dpi.

Oocysts developed rapidly but asynchronously and were seen in large numbers (≥ 54) in the midgut of mosquitoes examined

as early as 4 dpi (Fig. 2B). Maturing oocysts varied considerably in size (Table 1), containing 9 to 19 pigment granules scattered in their cytoplasm as well as a prominent vacuole (Fig. 2C). Development continued, leading to the formation of sporoblasts and the release of sporozoites. The fusiform sporozoites were first seen in salivary glands 6 dpi and continued to be present until the end of the experiment (10 dpi). Thousands of sporozoites were seen in preparations of salivary glands, indicating successful sporogony. The sporozoites were curved-bodied, with blunt ends and possessed centrally located nuclei (Fig. 2D, Table 1).

PCR, sequencing and phylogenetic analysis

Sequencing of the cytochrome b amplified fragments from both donor sparrow blood and infected female mosquitoes in 4 and 6 days after infection (when mature oocysts and sporozoites stages morphologically detected) produced a 480 bp partial sequence that was 100% identical to several published sequences (Genbank accession codes AB474380, AB474381, AB542062, DQ659543, DQ838991, HF543659 and KJ488599). When only the sequence trimmed as standardized by MalAvi (479 bp) was evaluated, the parasite was identical to lineage PADOM02 (Bensch, 2019). Phylogenetic analysis revealed that the *cyt-b* gene sequence of PADOM02 clusters with lineages SEIAUR01 and PADOM09, both of which have been attributed to the morphospecies *Plasmodium cathemerium*. The evolutionary distance of the *cyt-b* gene sequence of PADOM02 was smaller in relation to other lineages attributed to *P. cathemerium* (0.63% – 1.50% expected base substitutions per site) than to lineages attributed to other species of the *Haemamoeba* subgenus (3.08–5.74%) (Fig. 3 Table 2)

Discussion

Although Africa has a remarkable avian diversity, with ~2700 species (*Avibase* – The World Bird Database <https://avibase.bsc-eoc.org/avibase.jsp?lang=EN>), the diversity of avian malarial parasites in this continent has been considerably understudied (Valikiunas,

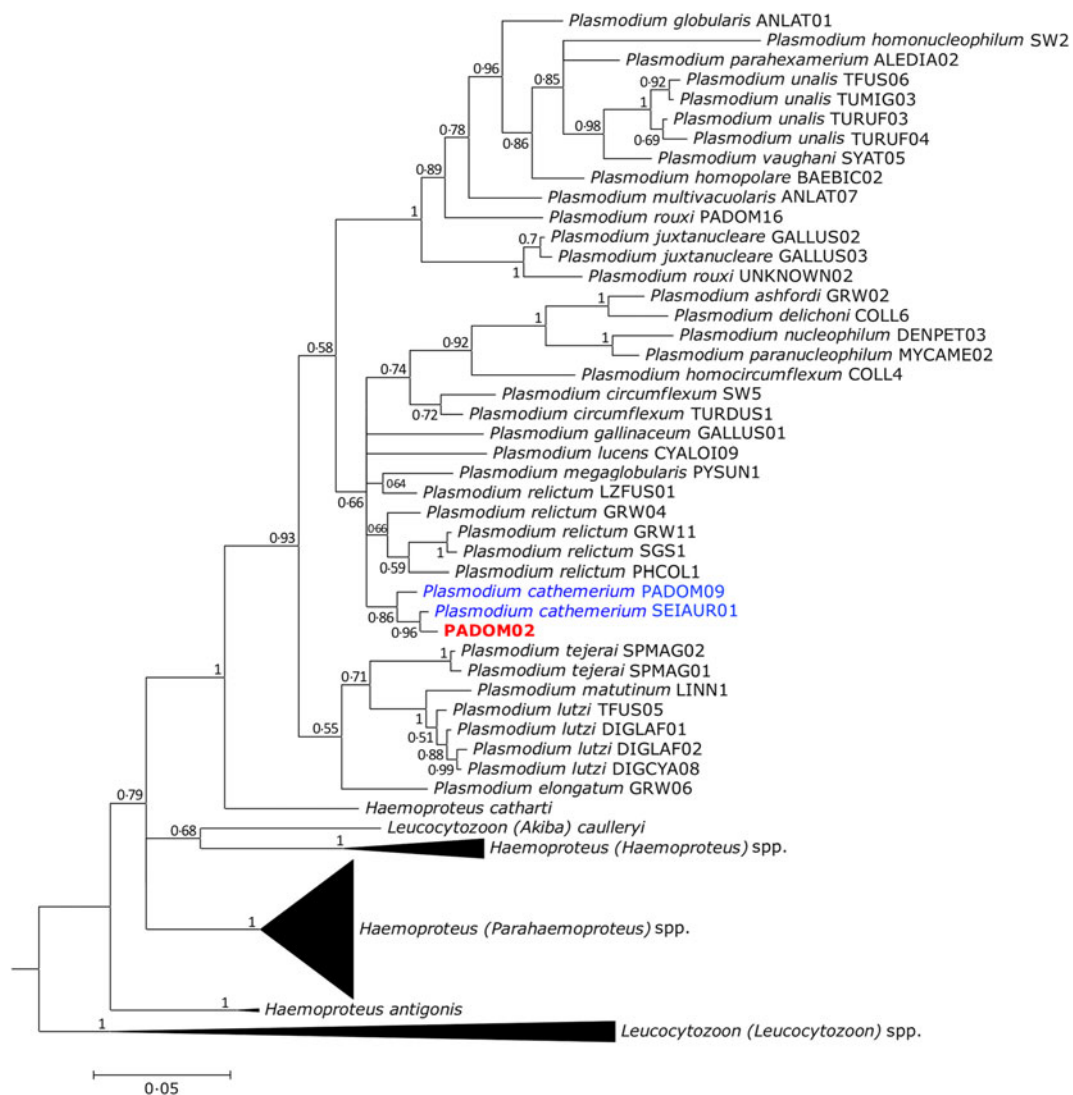


Fig. 3. Bayesian phylogenetic tree of the mitochondrial cytochrome *b* gene sequences (480 bp) of the studied haemosporidian lineage. MalAvi or GenBank accession codes for each lineage are indicated within brackets. Branch lengths are drawn proportionally to evolutionary distance. Values adjacent to nodes correspond to posterior probabilities.

2005). Many wild bird species, especially migratory birds, are susceptible to various malarial infections (Clark *et al.*, 2014). Only a few studies have evaluated the occurrence of *Plasmodium* spp. in Egyptian birds (Haiba, 1948; Mohammed, 1958*a, b*; Guindy *et al.*, 1965; Wiersch *et al.*, 2005); however, no study has been done on their vectors. The study of Marzal *et al.* (2011) has detected 3 *Plasmodium* lineages PADOM02, PADOM16 and SGS1 in house sparrows from Luxor (south part of Egypt) with 85.3% prevalence and 2.9% mixed infection. The current study record a less prevalence per cent, 26.5% in *P. domesticus* captured from Giza Governorate, Egypt with 1.5% mixed infection. The data recorded in Giza is lower than previously detected in Luxor suggested the effect of urbanization on both bird and vector (Martínez-De la Puente *et al.*, 2016; Carbo-Ramirez *et al.*, 2017). Additionally, we morphologically characterized the erythrocytic stages inside the erythrocytes of the avian host and the sporogonic cycle in the vector, combined with a phylogenetic analysis of mitochondrial *cyt-b* gene. The lineage PADOM02 has been detected in a number of avian hosts and mosquito vectors worldwide (Table 1). Most studies reporting this lineage have detected it solely through molecular methods, and therefore there is limited information on its morphology. Beadell *et al.* (2006) originally attributed this lineage to the morphospecies

Plasmodium (Haemamoeba) relictum. However, this classification must be considered with caution, because that study did not provide details on the morphological criteria that were used. Furthermore, later studies have found that another sequence attributed to *P. relictum* in the study of Beadell *et al.* (2006) corresponded to *Plasmodium (Huffia) elongatum* (Valkiūnas *et al.*, 2008; Vanstreels *et al.*, 2014). When D'Amico and Baker (2010) examined the blood smear of a red knot (*Calidris canutus*) infected with this lineage, they concluded that it corresponded to *P. relictum* based on the classification that had been proposed by Beadell *et al.* (2006). D'Amico and Baker (2010) did not provide a detailed morphological description, however, the basic text description and the photographs provided in their study are generally consistent with several species of the subgenus *Haemamoeba*.

The parasites in our study have roundish gametocytes that are markedly larger than the host cell nucleus, which unequivocally places them in the subgenus *Haemamoeba*, with 11 known species (Valkiūnas, 2005; Valkiūnas and Iezhova, 2018). The absence of large vacuoles or residuals bodies in the trophozoites and erythrocytic meronts provides the basis for the elimination of *P. giovanolai*, *P. matutinum*, *P. tejerai* and *P. griffithsi* (Valkiūnas, 2005; Valkiūnas and Iezhova, 2018). Because the erythrocytic meronts do not cause a marked enlargement of the host cell, do not

Table 2. Estimates of evolutionary distance (% expected base substitutions per site) of mitochondrial cytochrome *b* gene sequences of *Plasmodium* PADOM02 in relation to lineages attributed to the *Haemamoeba* subgenus

Morphospecies and lineage	2	3	4	5	6	7	8	9	10	11	12	13	14
1. PADOM02	1.50	0.63	4.94	5.21	5.46	5.72	5.21	5.73	3.09	3.08	3.29	3.31	6.60
2. <i>Plasmodium cathemerium</i> PADOM09		1.28	4.51	5.53	5.78	6.04	5.53	6.05	3.10	3.55	2.84	3.78	6.39
3. <i>Plasmodium cathemerium</i> SEIAUR01			4.73	5.00	5.25	5.50	5.00	5.51	2.87	3.32	2.61	3.55	6.89
4. <i>Plasmodium gallinaceum</i> GALLUS01				6.71	6.96	7.24	6.71	7.25	5.43	6.41	5.96	6.65	7.09
5. <i>Plasmodium lutzi</i> DIGLAF01					0.21	0.42	0.42	1.72	5.74	6.21	6.23	6.45	4.38
6. <i>Plasmodium lutzi</i> DIGCYA08						0.21	0.63	1.94	6.00	6.46	6.49	6.71	4.63
7. <i>Plasmodium lutzi</i> DIGLAF02							0.85	2.17	6.26	6.20	6.22	6.44	4.63
8. <i>Plasmodium lutzi</i> TFUS05								1.72	5.74	6.21	6.23	6.45	4.38
9. <i>Plasmodium matutinum</i> LINN1									6.08	6.55	6.28	6.80	4.42
10. <i>Plasmodium relictum</i> GRW04										2.16	2.41	2.38	6.36
11. <i>Plasmodium relictum</i> GRW11											2.82	0.21	7.10
12. <i>Plasmodium relictum</i> LZFUS01												3.05	6.11
13. <i>Plasmodium relictum</i> SGS1													7.36
14. <i>Plasmodium tejeraei</i> SPMAG01													

possess a centrally located residual cytoplasm, and their nuclei are not located in the periphery, *P. caloti* and *P. parvulum* can be excluded (Valkiūnas and Iezhova, 2018). Because fully grown gametocytes neither exceed 10 µm in length nor occupy the entire cytoplasm of the host cell, and the gametocyte pigmented granules are not clumped into a spot, it is also possible to exclude *P. gallinaceum*, *Plasmodium coturnixi*, and *P. lutzi* (Valkiūnas, 2005; Valkiūnas and Iezhova, 2018). There are thus three morphospecies within the subgenus *Haemamoeba* to be further considered: *P. cathemerium*, *P. relictum* and *P. subpraecox*. Of these, we consider our parasite to be morphologically most consistent with *P. cathemerium* based on the following characteristics: (a) presence of elongated rod-like pigmented granules, with pointed ends in the microgametocytes (a characteristic thought to be unique to *P. cathemerium*); (b) when a single trophozoite is present, the host cell nucleus is only occasionally and slightly displaced (unlike the high frequency and marked nuclear displacement that is usually associated with *P. relictum*); (c) 9–18 merozoites per erythrocytic meronts is consistent with the interval of 6–24 merozoites described for *P. cathemerium* (whereas *P. subpraecox* usually has 5–12 merozoites); (d) the infection was detected in a house sparrow (whereas previous studies have shown this species to be refractory to *P. subpraecox*) (Valkiūnas, 2005; Valkiūnas and Iezhova, 2018). We, therefore, conclude that the original assignment of the lineage PADOM02 to the morphospecies *P. relictum* was in error and that this lineage is instead most consistent with *P. cathemerium*. This interpretation is corroborated by our phylogenetic analysis, which places PADOM02 amidst other lineages attributed to *P. cathemerium*.

Culex pipiens is the most common vector of avian malaria (Valkiūnas, 2005; Santiago-Alarcon *et al.*, 2012). Huff (1927, 1932) found that the following mosquitoes are susceptible to *P. cathemerium* (unknown *cyt-b* lineage): *Cx. pipiens*, *Cx. salinarius*, *Cx. territans*, *Cx. quinquefasciatus*, *Cx. tarsalis* and *Aedes aegypti*. However, Huff (1927) has reported the transfer from birds to mosquitoes and from mosquitoes back to birds with *P. cathemerium* with only two species of the studied mosquitoes. A recent study with morphological and molecular methods to detect *Plasmodium* spp. in *Cx. pipiens* from Austria has identified three lineages: *P. vaughani* SYAT05, *P. elongatum* GRW6 and *P. relictum* SGS1 (Schoener *et al.*, 2019). In this study, we found

that *Cx. pipiens* complex (adults derived from larvae collected in Egypt) were susceptible to *P. cathemerium* PADOM02. The sporogonic process and the morphology of sporogonic stages of *P. cathemerium* PADOM02 in *Cx. pipiens* complex were generally comparable to those of *P. relictum* GRW4 in *Cx. pipiens pipiens* (Valkiūnas *et al.*, 2015), and it seems unlikely that the vector stages of these parasites could be differentiated on a morphological basis. The massive infection of the salivary glands suggests that a substantial number of sporozoites would be inoculated through blood-sucking, corroborating that *Cx. pipiens* complex is a competent vector of PADOM02. In contrast with Valkiūnas *et al.* (2015), however, we observed a much faster developmental rate, with oocysts developing in 4 dpi and sporozoites in 5 dpi (*cf.* 13 dpi for oocysts and 16 dpi for sporozoites in Valkiūnas *et al.*, 2015). This is likely related to the higher ambient temperatures used to rear mosquitoes in this study (27 ± 2°C, compared to 20 ± 1°C in Valkiūnas *et al.*, 2015) as temperature effects on the *Plasmodium* extrinsic incubation period (the interval of plasmodium development inside the vector from blood meal acquisition to salivary gland infection). The complete incubation period lasts 5–16 days, is inversely dependent on temperature and ultimately restricts the altitudinal distribution of infectious mosquitoes and disease transmission (LaPointe *et al.*, 2010, 2012; Carvalho *et al.*, 2017).

The only other study employing molecular methods to identify the *Plasmodium* lineages in Egyptian birds was conducted by Marzal *et al.* (2011). Interestingly, in that study, *Plasmodium* lineage PADOM02 was also detected in free-ranging sparrows despite a relatively small sample size (34 individuals). The fact that we detected the same parasite in sparrows captured ~500 km north from the study site of Marzal *et al.* (2011) suggests that this is a common parasite in free-ranging sparrows along the Nile river. This is not unexpected considering the broad distribution of this lineage, which suggests this is a relatively common parasite of birds in the Holarctic region (see Table 3). Considering that the Nile river is an important stop-over site for migratory birds along the Black Sea-Mediterranean and East Africa-West Asia fly ways (Davidson and Stroud, 2006; Abdelwhab and Hafez, 2011), this raises interesting questions on the potential host of sparrows as a reservoir of infection for the transmission of these parasites to other birds passing through

Table 3. Summary of the known host–parasite associations of *Plasmodium* lineage PADOM02

Host	Location	Reference
Charadriiformes		
<i>Calidris canutus rufa</i>	USA	D'Amico and Baker (2010)
Galliformes		
<i>Phasianus colchicus</i>	South Korea	Ishtiaq <i>et al.</i> (2007)
Passeriformes		
<i>Anthus hodgsoni</i>	South Korea	Beadell <i>et al.</i> (2006); Ishtiaq <i>et al.</i> (2007)
<i>Carpodacus erythrinus</i>	Czech Republic	Synek <i>et al.</i> (2013)
<i>Carpodacus erythrinus</i>	Russia	Palinauskas <i>et al.</i> (2013)
<i>Corvus corone</i>	Japan	Beadell <i>et al.</i> (2006)
<i>Emberiza citronella</i>	New Zealand	Bonneaud <i>et al.</i> (2006); Ewen <i>et al.</i> (2012)
<i>Emberiza godlewskii</i>	China	Liu <i>et al.</i> (2019)
<i>Luscinia svecica</i>	Norway	Beadell <i>et al.</i> (2006)
<i>Motacilla cinerea</i>	Armenia or Azerbaijan	Drovetski <i>et al.</i> (2014)
<i>Motacilla flava</i>	Spain	Hellgren <i>et al.</i> (2007)
<i>Passer domesticus</i>	Egypt	Marzal <i>et al.</i> (2011); This study
<i>Passer domesticus</i>	France	Bonneaud <i>et al.</i> (2006); Loiseau <i>et al.</i> (2010); Marzal <i>et al.</i> (2011)
<i>Passer domesticus</i>	Romania	Marzal <i>et al.</i> (2011)
<i>Passer domesticus</i>	Spain	Marzal <i>et al.</i> (2011); Ferraguti <i>et al.</i> (2018); Garcia-Longoria <i>et al.</i> (2019)
<i>Passer domesticus</i>	Turkey	Marzal <i>et al.</i> (2011)
<i>Passer montanus</i>	Japan	Inumaru <i>et al.</i> (2017)
Culicidae		
<i>Culex vorax</i>	Japan	Ejiri <i>et al.</i> (2009)
<i>Culex pipiens pallens</i> ^a	Japan	Ejiri <i>et al.</i> (2009, 2011); Kim <i>et al.</i> (2009); Kim and Tsuda (2010)
<i>Culex pipiens</i>	Switzerland	Glaizot <i>et al.</i> (2012)
<i>Culex pipiens</i> ^b	Egypt	This study

^a = Blood meal analyses revealed that the mosquitoes had recently fed on *Corvus macrorhynchos*, *Passer montanus* and *Parus major* (Kim *et al.*, 2009) or on *Ardea cinerea*, *Strix uralensis* and *Bos taurus* (Ejiri *et al.*, 2011).

^b = Experimental infection from naturally infected *Passer domesticus*.

the area. It is also worth noting that the records of PADOM02 in yellowhammers (*Emberiza citronella*) in New Zealand (Bonneaud *et al.*, 2006; Ewen *et al.*, 2012) suggest that this parasite was introduced together with its host since yellowhammers are not native to New Zealand and were brought from Europe (Duncan, 1997).

Although there are records of PADOM02 infecting Galliformes (Ishtiaq *et al.*, 2007) and Charadriiformes (D'Amico and Baker, 2010), most records of this lineage thus far have been obtained from Passeriformes (see Table 3), suggesting these are the main hosts for this parasite. Lineages PADOM09 and SEIAUR01, which are also attributed to *P. cathemerium*, thus far have been predominantly reported in Passeriformes, with PADOM09 restricted to the Americas whereas SEIAUR01 appears to be restricted to North America and the Caribbean (Bensch, 2019). Further studies on the geographic and host distribution of avian malarial parasites at the lineage level will, therefore, provide valuable insight into the ecological dynamics of these parasites and their interactions with avian host. Molecular identification and evolutionary study provide a level of insight that could not be obtained exclusively by morphological studies since these parasites appear to be otherwise undistinguishable.

In conclusion, our findings confirm that *Plasmodium* lineage PADOM02 infects sparrows in urban areas along the Nile River, Egypt and corroborate that *Cx. pipiens* complex is a highly competent vector for these parasites. Furthermore, we

demonstrate that this lineage corresponds to the morphospecies *P. cathemerium* and not *P. relictum* as previously believed.

Supplementary material. The supplementary material for this article can be found at <https://doi.org/10.1017/S0031182020000566>.

Acknowledgements. We thank Prof. James Nation, Institute of Food and Agricultural Sciences, Entomology and Nematology Department, University of Florida, USA for his comments, valuable suggestions and English language editing. This work has been supported by Faculty of Science Research Sector in Cairo and South Valley Universities.

Financial support. This study was supported by research grand from Faculty of Science, Cairo University.

Conflict of interest. The authors have declared that they have no conflict of interest.

Ethical standards. This work was carried out with approval of Cairo University Institutional Animal Care and Use Committee (CU-IACUC), approval number CU-IF 89-19.

References

Abdelwhab EM and Hafez HM (2011) An overview of the epidemic of highly pathogenic H5N1 avian influenza virus in Egypt: epidemiology and control challenges. *Epidemiology & Infection* **139**, 647–657.

- Adham FK, Gabre RM, Ayaad TH and Galal FH (2003) The effects of laboratory *Hepatozoon gracilis* infection on the fecundity, mortality and longevity of *Culex pipiens* Linnaeus (Diptera: Culicidae). *Egyptian Journal of Parasitology* **33**, 353–360.
- Beadell JS, Ishtiaq F, Covas R, Melo M, Warren BH, Atkinson CT, Bensch S, Graves GR, Jhala YV, Peirce MA, Rahmani AR, Fonseca DM and Fleischer RC (2006) Global phylogeographic limits of Hawaii's avian malaria. *Proceedings of the Royal Society of London B: Biological Sciences* **273**, 2935–2944.
- Bensch S (2019) MalAvi: A database for avian haemosporidian parasites. <http://130.235.244.92/Malavi/index.html> (access on 07 November 2019).
- Bensch S, Hellgren O and Pérez-Tris J (2009) Malavi: a public database of malaria parasites and related haemosporidians in avian hosts based on mitochondrial cytochrome b lineages. *Molecular Ecology Resources* **9**, 1353–1358.
- Bonneaud C, Pérez-Tris J, Federici P, Chastel O and Sorci G (2006) Major histocompatibility alleles associated with local resistance to malaria in a passerine. *Evolution* **60**, 383–389.
- Carbo-Ramirez P, Zuria I, Schaefer HM and Santiago-Alarcon D (2017) Avian haemosporidians at three environmentally contrasting urban green-spaces. *Journal of Urban Ecology* **3**, 1–11.
- Carvalho BM, Rangel EF and Vale MM (2017) Evaluation of the impacts of climate change on disease vectors through ecological niche modelling. *Bulletin Entomological Research* **107**, 419–430.
- Clark JN, Clegg MS and Lima RM (2014) A review of global diversity in avian haemosporidians (*Plasmodium* and *Haemoproteus*: Haemosporida): new insights from molecular data. *International Journal of Parasitology* **44**, 329–338.
- D'Amico VL and Baker AJ (2010) A rare case of *Plasmodium* (*Haemamoeba*) *relictum* Infection in a free-living Red Knot (*Calidris Canutus rufa*, Scolopacidae). *Journal of Ornithology* **151**, 951–954.
- Darriba D, Taboada GL, Doallo R and Posada D (2012) Jmodeltest 2: more models, new heuristics and parallel computing. *Nature Methods* **9**, 772.
- Davidson NC and Stroud DA (2006) African–Western Eurasian Flyways: current knowledge, population status and future challenges. In Boere GC, Galbraith CA and Stroud DA (eds), *Waterbirds Around the World*. Edinburgh, UK: The Stationery Office, pp. 63–73.
- Drovetski SV, Aghayan SA, Mata VA, Lopes RJ, Mode NA, Harvey JA and Voelker G (2014) Does the niche breadth or trade-off hypothesis explain the abundance–occupancy relationship in avian Haemosporidia? *Molecular Ecology* **23**, 3322–3329.
- Duncan RP (1997) The role of competition and introduction effort in the success of passeriform birds introduced to New Zealand. *The American Naturalist* **149**, 903–915.
- Ejiri H, Sato Y, Sawai R, Sasaki E, Matsumoto R, Ueda M, Higa Y, Tsuda Y, Omori S, Murata K and Yukawa M (2009) Prevalence of avian malaria parasite in mosquitoes collected at a zoological garden in Japan. *Parasitology Research* **105**, 629–633.
- Ejiri H, Sato Y, Kim KS, Hara T, Tsuda Y, Imura T, Murata K and Yukawa M (2011) Entomological study on transmission of avian malaria parasites in a zoological garden in Japan: bloodmeal identification and detection of avian malaria parasite DNA from blood-fed mosquitoes. *Journal of Medical Entomology* **48**, 600–607.
- Ewen JG, Bensch S, Blackburn TM, Bonneaud C, Brown R, Cassey P, Clarke RH and Pérez-Tris J (2012) Establishment of exotic parasites: the origins and characteristics of an avian malaria community in an isolated island avifauna. *Ecology Letters* **15**, 1112–1119.
- Farajollahi A, Fonseca DM, Kramer LD and Marm Kilpatrick A (2011) “Bird biting” mosquitoes and human disease: a review of the role of *Culex pipiens* complex mosquitoes in epidemiology. *Infection, Genetics and Evolution* **11**, 1577–1585.
- Ferraguti M, Martínez-de la Puente J, Bensch S, Roiz D, Ruiz S, Viana DS, Sorriquer RC and Figuerola J (2018) Ecological determinants of avian malaria infections: an integrative analysis at landscape, mosquito and vertebrate community levels. *Journal of Animal Ecology* **87**, 727–740.
- García-Longoria L, Marzal A, De Lope F and Garamszegi L (2019) Host-parasite interaction explains variation in the prevalence of avian haemosporidians at the community level. *PLoS One* **14**, 1–17.
- Glaizot O, Fumagalli L, Iritano K, Lalubin F, Van Rooyen J and Christe P (2012) High prevalence and lineage diversity of avian malaria in wild populations of great tits (*Parus major*) and mosquitoes (*Culex pipiens*). *PLoS One* **7**, e34964.
- Godfrey RD Jr., Fedynich AM and Pence DB (1987) Quantification of hematozoa in blood smears. *Journal of Wildlife Diseases* **23**, 558–565.
- Guindy E, Hoogstraal H and Mohammed AH (1965) *Plasmodium gurnhami* sp. nov. from the Egyptian hoopoe (*Upupa epops major brehm*). *Transactions of the Royal Society of Tropical Medicine and Hygiene* **59**, 280–282.
- Haiba MH (1948) Plasmodia of common Egyptian birds. *Journal of Comparative Pathology and Therapeutics* **58**, 81–93.
- Hall TA (1999) Bioedit: a user-friendly biological sequence alignment editor and analysis program for windows 95/98/NT. *Nucleic Acid Symposium Series No. 41*, 95–98.
- Harbach RE (1985) Pictorial keys to the genera of mosquitoes, subgenera of *Culex* and the species of *Culex* (*Culex*) occurring in southwestern Asia and Egypt, with a note on the subgeneric placement of *Culex deserticola* (Diptera: Culicidae). *Mosquito Systematics* **17**, 83–107.
- Hellgren O, Waldenström J, Pérez-Tris J, Ösi ES, Hasselquist D, Krizanauskienė A, Ottosson U and Bensch S (2007) Detecting shifts of transmission areas in avian blood parasites—a phylogenetic approach. *Molecular Ecology* **16**, 1281–1290.
- Hongoh V, Berrang-Ford L, Scott ME and Lindsay R (2012) Expanding geographical distribution of the mosquito, *Culex pipiens*, in Canada under climate change. *Applied Geography* **33**, 53–62.
- Huff CG (1927) Studies on the infectivity of Plasmodia of birds for mosquitoes, with special reference to the problem of immunity in the mosquito. *American Journal of Hygiene* **7**, 706–734.
- Huff CG (1932) Further infectivity experiments with mosquitoes and bird malaria. *American Journal of Hygiene* **15**, 751–754.
- Ibrahim WAL (2011) An overview of bird migration studies in Egypt. *The Ring* **33**, 1–2.
- Inumaru M, Murata K and Sato Y (2017) Prevalence of avian haemosporidia among injured wild birds in Tokyo and environs, Japan. *International Journal for Parasitology: Parasites and Wildlife* **6**, 299–309.
- Ishtiaq F, Gering E, Rappole JH, Rahmani AR, Jhala YV, Dove CJ, Milensky C, Olson SL, Peirce MA and Fleischer RC (2007) Prevalence and diversity of avian hematozoan parasites in Asia: a regional survey. *Journal of Wildlife Diseases* **43**, 382–398.
- Kazlauskienė R, Bernotienė R, Palinauskas V, Iezhova TA and Valkiūnas G (2013) *Plasmodium relictum* (lineages pSGS1 and pGRW11): complete synchronous sporogony in mosquitoes *Culex pipiens pipiens*. *Experimental Parasitology* **133**, 454–461.
- Kim KS and Tsuda Y (2010) Seasonal changes in the feeding pattern of *Culex pipiens pallens* govern the transmission dynamics of multiple lineages of avian malaria parasites in Japanese wild bird community. *Molecular Ecology* **19**, 5545–5554.
- Kim KS, Tsuda Y, Yamada A and Yamada A (2009) Bloodmeal identification and detection of avian malaria parasite from mosquitoes (Diptera: Culicidae) inhabiting coastal areas of Tokyo Bay, Japan. *Journal of Medical Entomology* **46**, 1230–1234.
- LaPointe DA, Goff ML and Atkinson CT (2010) Thermal constraints to the sporogonic development and altitudinal distribution of avian malaria *Plasmodium relictum* in Hawaii. *Journal of Parasitology* **96**, 318–324.
- LaPointe DA, Atkinson CT and Samuel MD (2012) Ecology and conservation biology of avian malaria. *Annals of the New York Academy of Sciences* **1249**, 211–226.
- Liu B, Deng Z, Huang W, Dong L and Zhang Y (2019) High prevalence and narrow host range of haemosporidian parasites in Godlewski's bunting (*Emberiza godlewskii*) in northern China. *Parasitology International* **69**, 121–125.
- Loiseau C, Zoorob R, Robert A, Chastel O, Julliard R and Sorci G (2010) *Plasmodium relictum* infection and MHC diversity in the house sparrow (*Passer domesticus*). *Proceedings of the Royal Society B: Biological Sciences* **278**, 1264–1272.
- Martínez-De la Puente J, Ferraguti M, Ruiz S, Roiz D, Sorriquer R and Figuerola J (2016) *Culex pipiens* forms and urbanization: effects on blood feeding sources and transmission of avian Plasmodium. *Malaria Journal* **15**, 589–597.
- Marzal A, Ricklefs RE, Valkiūnas G, Albayrak T, Arriero E, Bonneaud C, Czirájk GA, Ewen J, Hellgren O, Hořáková D, Iezhova TA, Jensen H, Krizanauskienė A, Lima MR, de Lope F, Magnussen E, Martin LB, Moller AP, Palinauskas V, Pap PL, Pérez-Tris J, Sehgal RNM, Soler M, Szöllösi E, Westerdahl H, Zetindjiev P and Bensch S (2011) Diversity, loss, and gain of malaria parasites in a globally invasive bird. *PLoS One* **6**, e21905.

- Mohammed AHH** (1958a) *Protozoal Blood Parasites of Egyptian Birds*, (Thesis), London School of Hygiene and Tropical Medicine.
- Mohammed AHH** (1958b) *Systematic and Experimental Studies on Protozoal Blood Parasites of Egyptian Birds*. Volume I&II. Cairo: Cairo University Press.
- Palinauskas V, Iezhova TA, Križanauskienė A, Markovets MY, Bensch S and Valkiūnas G** (2013) Molecular characterization and distribution of *Haemoproteus minutus* (Haemosporida, Haemoproteidae): a pathogenic avian parasite. *Parasitology International* **62**, 358–363.
- Patz JA, Epstein PR, Burke TA and Balbus JM** (1996) Global climate change and emerging infectious diseases. *Journal of the American Medical Association* **275**, 217–223.
- Ronquist F and Huelsenbeck JP** (2003) MrBayes 3: Bayesian phylogenetic inference under mixed models. *Bioinformatics (Oxford, England)* **19**, 1572–1574.
- Sambrook J, Fritsch EF and Maniatis T** (1989) *Molecular cloning: a laboratory Manual*, 2nd ed., Cold Spring Harbor Laboratory Press, Cold Spring Harbor, N.Y.
- Santiago-Alarcon D, Palinauskas V and Schaefer HH** (2012) Diptera vectors of avian Haemosporidian parasites: untangling parasite life cycles and their taxonomy. *Biological Reviews* **87**, 928–964.
- Schoener ER, Harl J, Himmel T, Fragner K, Weissenböck H and Fuehrer HP** (2019) Protozoan parasites in *Culex pipiens* mosquitoes in Vienna. *Parasitology Research* **118**, 1261–1269.
- Synek P, Muncinger P, Albrecht T and Votýpka J** (2013) Avian haemosporidians in haematophagous insects in the Czech Republic. *Parasitology Research* **112**, 839–845.
- Tamura K, Stecher G, Peterson D, Filipski A and Kumar S** (2013) MEGA6: molecular evolutionary genetics analysis version 6.0. *Molecular Biology and Evolution* **30**, 2725–2729.
- Tandina F, Doumbo O, Yaro AS, Traoré SF, Parola P and Robert V** (2018) Mosquitoes (Diptera: Culicidae) and mosquito-borne diseases in Mali, West Africa. *Parasite and Vectors* **11**, 1–12.
- Thompson JD, Gibson TJ and Higgins DG** (2002) Multiple sequence alignment using ClustalW and ClustalX. *Current Protocols Bioinformatics* **00**, 2.3.1–2.3.22.
- Valkiūnas G** (2005) *Avian Malaria Parasites and other Haemosporidia*. Boca Raton, Florida, USA: CRC Press, 932 pp.
- Valkiūnas G** (2011) Haemosporidian vector research: marriage of molecular and microscopical approaches is essential. *Molecular Ecology* **20**, 3084–3086.
- Valkiūnas G and Iezhova TA** (2018) Keys to the avian malaria parasites. *Malaria Journal* **17**, 1–24.
- Valkiūnas G, Zehtindjiev P, Dimitrov D, Križanauskienė A, Iezhova TA and Bensch S** (2008) Polymerase chain reaction-based identification of *Plasmodium (Huffia) elongatum*, with remarks on species identity of haemosporidian lineages deposited in GenBank. *Parasitology Research* **102**, 1185–1193.
- Valkiūnas G, Kazlauskienė R, Bernotienė R, Palinauskas V and Iezhova TA** (2013) Abortive long-lasting sporogony of two *Haemoproteus* species (Haemosporida, Haemoproteidae) in the mosquito *Ochlerotatus Cantans*, with perspective on haemosporidian vector research. *Parasitology Research* **112**, 2159–2169.
- Valkiūnas G, Žiegytė R, Palinauskas V, Bernotienė R, Bukauskaitė D, Ilgūnas M, Dimitrov D and Iezhova TA** (2015) Complete sporogony of *Plasmodium relictum* (lineage pGRW4) in mosquitoes *Culex pipiens pipiens*, with implications on avian malaria epidemiology. *Parasitology Research* **114**, 3075–3085.
- Valkiūnas G, Ilgūnas M, Bukauskaitė D, Palinauskas V, Bernotienė R and Iezhova TA** (2017) Molecular characterization and distribution of *Plasmodium matutinum*, a common avian malaria parasite. *Parasitology* **144**, 1726–1735.
- Vanstreels RET, Kolesnikovas CKM, Sandri S, Silveira P, Belo NO, Junior FCF, Epiphanyo S, Steindel M, Braga ÉM and Catão-Dias JL** (2014) Outbreak of avian malaria associated to multiple species of *Plasmodium* in Magellanic penguins undergoing rehabilitation in southern Brazil. *Plos One* **9**, e94994.
- Waldenström J, Bensch S, Hasselquist D and Östman Ö** (2004) A new nested polymerase chain reaction method very efficient in detecting *Plasmodium* and *Haemoproteus* infections from avian blood. *Journal of Parasitology* **90**, 191–194.
- Weaver SC and Reisen WK** (2010) Present and future arboviral threats. *Antiviral Research* **85**, 328–345.
- Wiersch SC, Maier WA and Kampen H** (2005) *Plasmodium* (Haemamoeba) *cathemerium* gene sequences for phylogenetic analysis of malaria parasites. *Parasitology Research* **96**, 90–94.
- Žiegytė R, Bernotienė R, Bukauskaitė D, Palinauskas V, Iezhova TA and Valkiūnas G** (2014) Complete sporogony of *Plasmodium relictum* (lineage pSGS1 and pGRW11) in mosquitoes *Culex pipiens* form *molestus*, with implications to avian epidemiology. *Journal of Parasitology* **100**, 878–882.