

Main Article

Prof M Birchall takes responsibility for the integrity of the content of the paper

Presented at the virtual Ehlers–Danlos Society ECHO Summit, 2–3 October 2020 (online event).

Cite this article: Lam CM, Wood G, Birchall MA. Laryngological presentations and patient-reported outcome measures in Ehlers–Danlos syndrome. *J Laryngol Otol* 2022; **136**:947–951. <https://doi.org/10.1017/S0022215121004072>

Accepted: 4 May 2021

First published online: 10 December 2021

Key words:

Ehlers–Danlos Syndrome;
Patient Reported Outcome Measures; Larynx;
Connective Tissue

Author for correspondence:

Prof Martin A Birchall, Royal National Throat, Nose and Ear Hospital, 47–49 Huntley Street, London WC1E 6DG, UK
E-mail: m.birchall@ucl.ac.uk

Abstract

Objective. This study aimed to characterise the laryngological presentations of Ehlers–Danlos syndrome and conduct a preliminary exploration of patient-reported outcome measures.

Methods. This paper describes a retrospective case series of patients with Ehlers–Danlos syndrome seen by the senior author between 2005 and 2019. A literature review was conducted to summarise the existing findings.

Results. Twenty-one patients met the inclusion criteria. All reported symptoms were grouped; this showed that swallowing, voice and hyolaryngeal skeletal complex problems were commonest. Patient-reported outcome measures were available for eight patients, which showed large variations in: the Reflux Severity Index (median = 25.5; range = 0–33), Eating Assessment Tool score (median = 21.5; range = 0–35) and Voice Handicap Index (median = 21.5; range = 0–104). Twelve studies met our literature review inclusion criteria, involving at least 91 patients with laryngological presentations of Ehlers–Danlos syndrome.

Conclusion. Ehlers–Danlos syndrome patients experience musculoskeletal issues, which in the throat manifest as hyolaryngeal skeletal complex problems. Future studies with larger patient numbers are required to validate laryngological patient-reported outcome measure tools in Ehlers–Danlos syndrome.

Introduction

Ehlers–Danlos syndrome describes a group of inheritable connective tissue disorders involving defects in collagen and connective tissue synthesis. It is typically characterised by joint laxity, skin hyperextensibility and tissue fragility. It has been classified in numerous ways, with the latest 2017 classification describing 13 subtypes.¹ The different subtypes all have their own associated genetic basis, unknown in some cases, and each subtype has major and minor clinical criteria (determined based on a criterion's diagnostic specificity).¹

Ehlers–Danlos syndrome can affect multiple organ systems, with musculoskeletal, vascular and gastrointestinal symptoms being common.^{2,3} However, there are relatively few reports of laryngological presentations of Ehlers–Danlos syndrome, and these predominantly consist of case reports and case series.

Patient-reported outcome measures are often used to characterise symptom severity and are also used to monitor treatment progress. In laryngology, tools such as the Eating Assessment Tool, Reflux Symptom Index and Voice Handicap Index are commonly used. The Eating Assessment Tool is a validated, self-administered, symptom-specific outcome questionnaire for dysphagia that is widely used in the initial assessment of dysphagia severity and subsequent monitoring of treatment effectiveness.⁴ The Reflux Symptom Index is a validated and self-administered tool for assessing the severity of laryngopharyngeal reflux.⁵ The Voice Handicap Index is used to measure the psychosocial handicapping effects of voice disorders.⁶ However, these tools have not been validated for patients with Ehlers–Danlos syndrome.

This study aimed to characterise the laryngological presentations of Ehlers–Danlos syndrome in our patient cohort and conduct a preliminary exploration of patient-reported outcome measures in this population. A literature review was performed to summarise the laryngological presentations of Ehlers–Danlos syndrome that have previously been described.

Materials and methods

Retrospective data were collected from patients with a diagnosis of Ehlers–Danlos syndrome who were seen in laryngology clinic by the senior author between 2005 and 2019. Only patients with a clinical diagnosis of Ehlers–Danlos syndrome (any subtype) prior to presentation at the laryngology clinic were included. Patients without record of laryngological presenting symptoms were excluded. Details of patient demographics, date of first presentation to the clinic, Ehlers–Danlos syndrome subtype, presenting

symptoms and patient-reported outcome measures were collected. The patient-reported outcome measures used were the Eating Assessment Tool, Reflux Symptom Index and Voice Handicap Index. Microsoft Excel® spreadsheet software was used to analyse the data collected.

The literature search was conducted on 22 October 2020, on the PubMed/Medline (from inception to 22 October 2020) and Ovid Embase databases (1974 to 22 October 2020). The following Boolean search was performed: #1 "Larynx"[Mesh]; #2 "airway obstruction"[Mesh]; #3 "larynx"[tw]; #4 "Ehlers-Danlos Syndrome"[Mesh]; #5 "EDS"[tw]; #6 "Ehlers-Danlos"[tw]; #7 "Ehler*"; #8 "Danlos"[tw]; #9 "Patient Reported Outcome Measures"[Mesh]; #10 "Patient Outcome Assessment"[Mesh]; #11 "Patient Reported Outcome Measure"[tw]; #12 "PROM"[tw]; #13 #1 OR #2 OR #3; #14 #4 OR #5 OR #6 OR #7 OR #8; #15 #9 OR #10 OR #11 OR #12; #16 #13 AND #14; #17 #13 AND #14 AND #15.

Studies describing laryngological presentations in patients with Ehlers–Danlos syndrome were included. Conference abstracts and studies without full text were excluded. Search term #16 aimed to find studies with laryngological presentations of Ehlers–Danlos syndrome and search term #17 aimed to identify studies that described patient-reported outcome measures in this population.

This study only collected de-identified anonymised data and is classed as a service evaluation. Using the National Health Service Health Research Authority and UK Research and Innovation Medical Research Council decision tool,⁷ it was determined that ethical approval was not required for this study.

Results

In total, 21 patients met the inclusion criteria for our case series: 3 males and 18 females, with a median age of 47 years (range = 16–67 years) at first presentation to the clinic. Nine patients first presented to the clinic in 2019, representing a substantial increase on previous years (Figure 1).

Twenty patients had a diagnosis of Ehlers–Danlos syndrome hypermobility; one patient had a diagnosis of Ehlers–Danlos syndrome dermatosparaxis. The commonest first presenting symptoms were globus (seven patients), choking (five patients) and hyoid subluxation (two patients) (Figure 2). All symptoms reported by patients were grouped (Table 1). This showed that symptoms related to swallowing were commonest (15 patients; 71.4 per cent), followed by voice symptoms (9 patients; 42.9 per cent), hyolaryngeal skeletal complex problems (6 patients; 28.6 per cent), respiratory symptoms (5 patients; 23.8 per cent), nasal symptoms (3 patients; 14.3 per cent), vestibulocochlear symptoms (2 patients; 9.5 per cent) and other symptoms (5 patients; 23.8 per cent) (Figure 3).

Patient-reported outcome measures data were available for eight patients (38 per cent). The results showed large variations in the Reflux Symptom Index (median = 25.5; range = 0–33), Eating Assessment Tool score (median = 21.5; range = 0–35) and Voice Handicap Index (median = 21.5; range = 0–104).

Search term #17 yielded six studies, of which only one described laryngological presentations in Ehlers–Danlos syndrome patients, but it did not have relevant patient-reported outcome measures data.⁸ Search term #16 yielded 116 studies, of which 6 instances of study duplication were identified, and a further 4 studies were identified from reference lists. In total, 12 studies met our inclusion criteria, involving at least 278

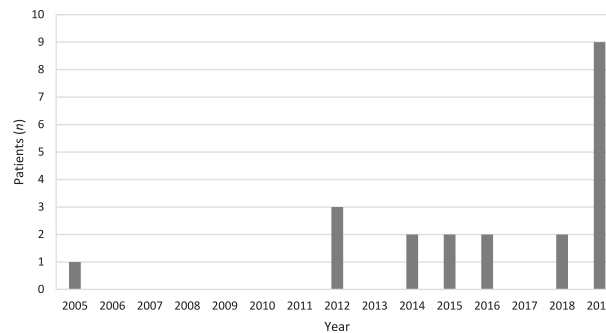


Fig. 1. Chart showing the number of patients with Ehlers–Danlos syndrome presenting to the senior author's laryngology clinic by year.

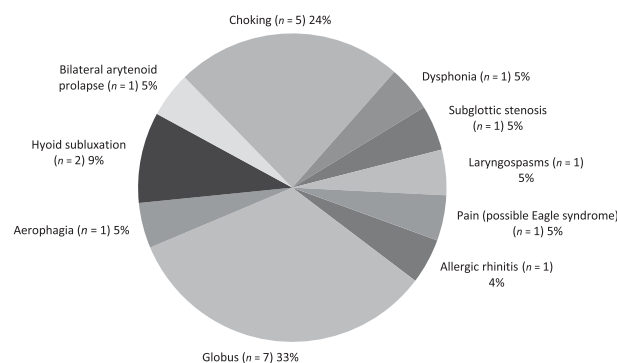


Fig. 2. Chart showing the first presenting symptom reported by patients presenting to the senior author's laryngology clinic.

patients with Ehlers–Danlos syndrome, of which at least 91 patients with laryngological presentations were reported. The results of the literature review are summarised in Table 2.^{8–20}

Discussion

Ehlers–Danlos syndrome is usually diagnosed in young adults, although clinical manifestations of the disease, including laryngological symptoms, may begin in childhood.⁹ Textbooks often report the prevalence of Ehlers–Danlos syndrome as 1 in 5000 births. A recent study in the Danish population also reported a prevalence of 1 in 5000 births.²¹ However, this incidence increases with increased awareness amongst physicians, and a 2019 study found that diagnoses of Ehlers–Danlos syndrome and joint hypermobility syndrome have been steadily increasing over the past 27 years.^{2,22} Our findings are consistent with this trend, as we report a substantial increase in the number of Ehlers–Danlos syndrome cases that presented to the laryngology clinic in 2019 compared with previous years (Figure 1).

In our case series, there was a large range in the ages of the patients presenting to the laryngology clinic, with a median age of 47 years. Of the 21 patients in our case series, 18 (85.7 per cent) were female and 3 (14.3 per cent) were male; in comparison, there were 73.9 per cent females and 26.1 per cent males in the Danish study.²¹ In our literature review, Rimmer *et al.* reported two paediatric cases of Ehlers–Danlos syndrome with reported symptoms of dysphonia within 18 months of birth; these patients first presented to the paediatric voice clinic at ages 14 years and 6 years, respectively.⁹ Hunter *et al.* reported a mean age of 45.5 years (range = 1.5–80 years) in their study which asked patients with Ehlers–Danlos

Table 1. All laryngological symptoms reported by patients

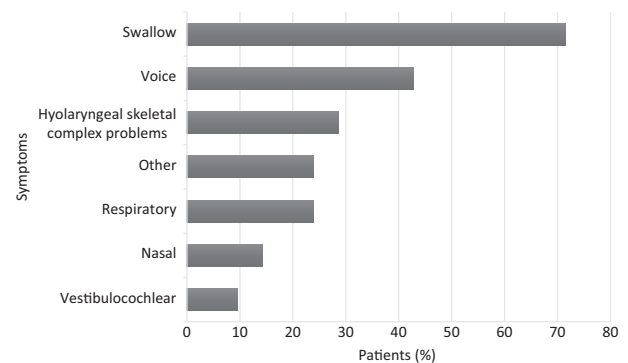
Symptoms	Patients (n)
Nasal – allergic rhinitis, sinusitis, nasal regurgitation	3
Vestibulocochlear – tinnitus, vertigo, clicking ears	2
Respiratory – obstructive sleep apnoea syndrome, coughing, dyspnoea	5
Swallow – dysphagia, globus, choking, reflux, odynophagia, aerophagia, dysmotility, hypercontractile oesophagus & cricopharyngeus	15
Voice – dysphonia, mutism	9
Hyolaryngeal skeletal complex problems – hyoid subluxation, bilateral arytenoid prolapse, subluxation arytenoids, possible subluxation, laryngospasm	6
Other – temporomandibular joint syndrome, subglottic stenosis, pain (possible Eagle syndrome), atlantoaxial subluxation spine, neck swelling, acute throat swelling (possible anaphylaxis)	5

syndrome about difficulties with their voice.¹⁰ These examples in the literature suggest that whilst Ehlers–Danlos syndrome is usually diagnosed in young adults, clinicians should be aware of early laryngological signs of Ehlers–Danlos syndrome presenting in childhood, as well as late presentations, as demonstrated by the large age range.

In our case series, swallowing and voice symptoms were reported in 71.4 per cent and 42.9 per cent of patients, respectively (Figure 3). This is higher than previous figures reported in the literature.¹⁰ The third most common group of presenting symptoms were hyolaryngeal skeletal complex problems (28.6 per cent). Ehlers–Danlos syndrome patients commonly experience musculoskeletal issues, which in the throat manifest as hyolaryngeal skeletal complex problems, as collagen defects are found throughout the body (Figure 4). The vocal folds are composed of epithelium, vocal muscle, and three layers of lamina propria consisting of different distributions of collagen, including collagen type I and type III, which are adversely affected in Ehlers–Danlos syndrome.²³ Ehlers–Danlos syndrome may also affect synovial joints in the larynx, such as the cricoarytenoid joints, which have been reported to be affected in rheumatoid arthritis.²⁴

Our literature review included case reports that also mention hyolaryngeal skeletal complex problems. Chatzoudis *et al.* reported a case of a 44-year-old woman with classical Ehlers–Danlos syndrome presenting with recurrent airway obstruction because of hypermobility of the suprahyoid suspensory soft tissues.¹¹ Ali *et al.* reported a case of a 48-year-old woman with Ehlers–Danlos syndrome type III (hypermobility type) presenting with dyspnoea and aphonia 1 day after anterior cervical discectomy.²⁵ On direct laryngoscopy, the vocal folds appeared normal, but on inspiration, the arytenoids were observed to have hyperlaxity and obstruct the airway.²⁵ However, neither of these studies reported patient-reported outcome measures data. In our case series, six patients (28.6 per cent) reported hyolaryngeal skeletal complex problems, including arytenoid prolapse, arytenoid subluxation and hyoid subluxation (Table 1). We had patient-reported outcome measures data for four of these patients, with median values of 29 (range = 0–33) on the Reflux Symptom Index, 28.5 (range = 0–35) on the Eating Assessment Tool and 21.5 (range = 0–32) on the Voice Handicap Index.

The term ‘Patient Reported Outcome Measures’ was indexed in the Ovid version of the Medline database in 2017, and was previously indexed under the term ‘Patient Outcome Assessment’. This perhaps explains the small number of studies reporting laryngological patient-reported

**Fig. 3.** Chart showing the percentage of patients experiencing each symptom by group.

outcome measures in patients with Ehlers–Danlos syndrome. In total, we had patient-reported outcome measures data for 8 of the 21 patients included in our study, showing a median Reflux Symptom Index of 25.5 (range = 0–33), median Eating Assessment Tool score of 21.5 (range = 0–35) and median Voice Handicap Index of 21.5 (range = 0–104). The large range in our patient-reported outcome measures data may suggest that our patients presented with varying degrees of symptom severity or that these symptoms had different effects on our patients’ quality of life. It could also be reflective of possible limitations of the Reflux Symptom Index, Eating Assessment Tool and Voice Handicap Index tools at assessing symptom severity in the Ehlers–Danlos syndrome population.

At present, no patient-reported outcome measure tools characterising laryngological symptoms have been validated in the Ehlers–Danlos syndrome patient cohort. This is important, as living with Ehlers–Danlos syndrome has a significant impact on a patient’s quality of life. In one study, females with Ehlers–Danlos syndrome rated their physical functional health status as being worse than those with fibromyalgia on the Sickness Impact Profile.²⁶ With the number of Ehlers–Danlos syndrome patients presenting to laryngology clinic possibly increasing (Figure 1), accurate tools to characterise symptom severity and its effects on patients’ quality of life are needed urgently.

Our study limitations include the small number of patients and the incomplete patient-reported outcome measures dataset from our patient cohort. The retrospective nature of our study does not allow us to monitor symptom progression, and future prospective studies involving patient-reported outcome measure assessments at multiple points in time are

Table 2. Summary of laryngological presentations of disease in patients with Ehlers–Danlos syndrome from our literature review

Study (year)	Study type	Ehlers–Danlos syndrome patients (n)	Ehlers–Danlos syndrome subtype	Laryngological presentations
Ayres <i>et al.</i> (1981) ¹²	Case report	1	Not stated	Recurrent inspiratory stridor & expiratory airflow obstruction. Apnoeic episodes. Pharyngeal collapse
Hunter <i>et al.</i> (1998) ¹⁰	Cross-sectional	Unclear (>200)	Types I–IV & VI	Difficulty swallowing (39%), difficulty in clearing throat (29%), tightness or lump in throat on swallowing (26%), difficulty in chewing (25%) – often due to discrepancies between lower & upper jaw alignment, difficulty shouting or sustaining voice (28%), dysphonia (27%)
Abdul-Wahab <i>et al.</i> (2003) ⁸	Case series	32	Not stated	Laryngo-tracheomalacia in 2 patients – caused significant obstructive sleep apnoea & severe hypotonia requiring non-invasive mechanical ventilation whilst asleep
Rimmer <i>et al.</i> (2008) ⁹	Case report	2	Case 1: hypermobility. Case 2: classic	Case 1: dysphonia (hoarse cry, breathy voice quality, reduced volume); left hemi-larynx weakness – immobile left hemi-larynx & absent mucosal wave. Compensatory hypertrophy of right ventricular fold which, on phonation, approximated to midline. Case 2: dysphonia (harsh, high-pitched, breathy voice); bulky right vocal fold; left cricoarytenoid joint – (1) reduced mobility, (2) failure of full apposition on adduction & (3) no visible mucosal wave. Irregular, symmetrical vocal folds. No cricoarytenoid joint fixation
Desuter <i>et al.</i> (2009) ¹³	Case report	1	Hypermobility	Frequent TMJ dislocation. Right vocal fold: haemorrhagic infiltration of Reinke's space & epithelium rupture with ligament exposure. Multiple microvascular aneurysms within laryngeal vestibule & pharyngeal walls
Castori <i>et al.</i> (2010) ¹⁴	Case series	21	Hypermobility	Dysphonia (38.1%), hypotonia &/or incoordination of vocal folds demonstrated on fibroscopy (number of cases not stated)
Harris <i>et al.</i> (2013) ¹⁵	Case series	5	Classic (cases 1 & 4), hypermobility (cases 2, 3 & 5)	Case 1 & 5: vocal fold dysfunction (probable in case 4). Case 2: vascular tracheal compression, choking, intermittent stridor. Dyspnoea (all patients), cough (cases 2–5), choking sensation (case 2), throat clearing (case 4)
Du & Tan, (2013) ¹⁶	Case report	1	Not stated	Persistent hoarseness, globus, decreased vocal range & deeper voice. Haemorrhagic polyp on right true vocal fold
Chatzoudis <i>et al.</i> (2015) ¹¹	Case report	1	Classic	Recurrent airway obstruction due to hypermobility of suprahyoid suspensory soft tissue particularly affecting right side, causing rotation of larynx to left. Led to twisting of trachea & instant complete airway obstruction
Arulanandam <i>et al.</i> (2016) ¹⁷	Case series	9	Classic (cases 5 & 9), hypermobility (cases 6–8)	Sensation of food stuck in throat (4 patients), choking when swallowing liquids (3 patients), globus (2 patients), food regurgitation (1 patient). Case 5: dysphagia, hypermobility of hyoid bone. Case 6: fluctuating hoarseness, GRBAS grade 1 voice, slight scissoring of vocal folds. Case 7: severe chronic throat pain, mild hoarseness, vocal fatigue, bilateral prolapsing arytenoids. Case 8: right vocal fold palsy, intermittent choking on fluids, limitation of effort tolerance, intermittent laryngospasm, subluxed cricoarytenoid joints & fixation of left cricoarytenoid joint. Case 9: subglottic stenosis, scar band on right vocal fold to left arytenoid, difficulty breathing
George <i>et al.</i> (2016) ¹⁸	Case report	2	Type VIII (periodontal type)	Case 1: Chronic hoarseness due to bilateral vocal fold sulci. Laryngeal mucosal hypertrophy. Case 2: chronic hoarseness due to abnormality of cricoarytenoid joint. Cricoid fibrosis. MRI showed subglottic stenosis
Safi <i>et al.</i> (2017) ¹⁹	Case series	3	Hypermobility (cases 1 & 2), classic (case 3)	Case 1: Arytenoid prolapse causing extrathoracic airway obstruction – difficulty breathing & stridor post URTI. Symptoms improved after URTI resolution. Case 2: hoarseness, chronic cough, feeling of throat closing which occurs with a URTI. Case 3: loss of voice, shortness of breath & stridor after a general anaesthetic

TMJ = temporomandibular joint; GRBAS = grade, roughness, breathiness, asthenia and strain scale;²⁰ MRI = magnetic resonance imaging; URTI = upper respiratory tract infection

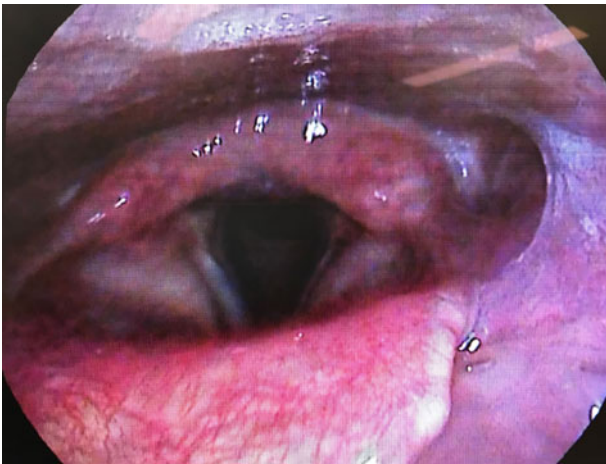


Fig. 4. Image showing wide excursion of the arytenoids on sniffing in one of the patients in our case series.

recommended. Furthermore, we used three different patient-reported outcome measure tools in our study that have not been validated in the Ehlers–Danlos syndrome patient cohort; hence, the effectiveness of these tools for characterising symptom severity is unknown.

- In our case series, swallowing symptoms were the commonest reported symptoms
- In Ehlers–Danlos syndrome, musculoskeletal issues in the throat can manifest as hyolaryngeal skeletal complex problems
- Patient-reported outcome measures are important for characterising symptom severity and its effects on quality of life
- At present, no patient-reported outcome measure tools characterising laryngological symptoms have been validated in Ehlers–Danlos syndrome patients

Conclusion

We present a case series characterising laryngological presentations of Ehlers–Danlos syndrome, with preliminary exploration of patient-reported outcome measures. We report a substantial increase in the number of Ehlers–Danlos syndrome patients seen in a laryngology clinic in 2019. Swallowing symptoms were the most common presenting complaint in our case series. Ehlers–Danlos syndrome patients commonly experience musculoskeletal issues, which in the throat manifest as hyolaryngeal skeletal complex problems, as reflected by the patients reporting such symptoms in our study and in our literature review. Future studies with larger patient numbers are required to validate the patient-reported outcome measures used in this study for Ehlers–Danlos syndrome patients.

Competing interests. None declared

References

- 1 Malfait F, Francomano C, Byers P, Belmont J, Berglund B, Black J *et al.* The 2017 international classification of the Ehlers–Danlos syndromes. *Am J Med Genet Part C Semin Med Genet* 2017;**175**:8–26
- 2 Callewaert B, Malfait F, Loeys B, De Paepe A. Ehlers–Danlos syndromes and Marfan syndrome. *Best Pract Res Clin Rheumatol* 2008;**22**:165–89
- 3 Kishore S, Backhouse L, Rook DM, Butler C, Osborne A, Fikree A *et al.* Mo1222 Gastrointestinal manifestations of Ehler–Danlos syndrome type III (hypermobility type): a paediatric cohort. *Gastroenterology* 2013;**144**:S610
- 4 Belafsky PC, Mouadeb DA, Rees CJ, Pryor JC, Postma GN, Allen J *et al.* Validity and reliability of the Eating Assessment Tool (EAT-10). *Ann Otol Rhinol Laryngol* 2008;**117**:919–24
- 5 Belafsky PC, Postma GN, Koufman JA. Validity and reliability of the Reflux Symptom Index (RSI). *J Voice* 2002;**16**:274–7
- 6 Jacobson BH, Johnson A, Grywalski C, Silbergleit A, Jacobson G, Benninger MS *et al.* The Voice Handicap Index (VHI): development and validation. *Am J Speech Lang Pathol* 1997;**6**:66–70
- 7 UKRI. Medical Research Council decision tool. In: <http://www.hra-decisiontools.org.uk/research/> [7 December 2021]
- 8 Abdul Wahab A, Janahi IA, Eltohami A, Zeid A, Faiyaz UI Haque M, Teebi AS. A new type of Ehlers–Danlos syndrome associated with tortuous systemic arteries in a large kindred from Qatar. *Acta Paediatr* 2003;**92**:456–62
- 9 Rimmer J, Giddings CEB, Cavalli L, Hartley BEJ. Dysphonia – a rare early symptom of Ehlers–Danlos syndrome? *Int J Pediatr Otorhinolaryngol* 2008;**72**:1889–92
- 10 Hunter A, Morgan AW, Bird HA. A survey of Ehlers–Danlos syndrome: hearing, voice, speech and swallowing difficulties, is there an underlying relationship? *Br J Rheumatol* 1998;**37**:803–4
- 11 Chatzoudis D, Kelly TJ, Lancaster J, Jones TM. Upper airway obstruction in a patient with Ehlers–Danlos syndrome. *Ann R Coll Surg Engl* 2015;**97**:e50–1
- 12 Ayres J, Rees J, Cochrane GM. Haemoptysis and non-organic upper airways obstruction in a patient with previously undiagnosed Ehlers–Danlos syndrome. *Br J Dis Chest* 1981;**75**:309–10
- 13 Desuter G, Gardiner Q, Dahan K. Laryngeal signs of Ehlers Danlos syndrome in an adult: the first case reported. *Otolaryngol Head Neck Surg* 2009;**141**:428–9
- 14 Castori M, Camerota F, Celletti C, Danese C, Santilli V, Saraceni VM *et al.* Natural history and manifestations of the hypermobility type Ehlers–Danlos syndrome: a pilot study on 21 patients. *Am J Med Genet A* 2010;**152A**:556–64
- 15 Harris JG, Khiani SJ, Lowe SA, Vora SS. Respiratory symptoms in children with Ehlers–Danlos syndrome. *J Allergy Clin Immunol Pract* 2013;**1**:684–6
- 16 Du E, Tan M. Successful CO₂ laser ablation of true vocal fold microaneurysm in a patient with Ehlers–Danlos syndrome. *Otolaryngol Head Neck Surg* 2013;**149**:959–60
- 17 Arulanandam S, Hakim AJ, Aziz Q, Sandhu G, Birchall MA. Laryngological presentations of Ehlers–Danlos syndrome: case series of nine patients from two London tertiary referral centres. *Clin Otolaryngol* 2016;**42**:860–3
- 18 George SM, Vandersteen A, Nigar E, Ferguson DJ, Topham E, Pope F. Two patients with Ehlers–Danlos syndrome type VIII with unexpected hoarseness. *Clin Exp Dermatol* 2016;**41**:771–4
- 19 Safi FA, Alyosif MA, Imam S, Assaly RA. Arytenoid prolapse in 3 patients with Ehler–Danlos syndrome leading to respiratory compromise. *Mayo Clin Proc* 2017;**92**:851–3
- 20 Hirano M. *Clinical Examination of Voice*. New York: Springer-Verlag, 1981
- 21 Søborg MLK, Leganger J, Mortensen LQ, Rosenberg J, Burcharth J. Establishment and baseline characteristics of a nationwide Danish cohort of patients with Ehlers–Danlos syndrome. *Rheumatology (Oxford)* 2017;**56**:763–7
- 22 Demmler JC, Atkinson MD, Reinhold EJ, Choy E, Lyons RA, Brophy ST. Diagnosed prevalence of Ehlers–Danlos syndrome and hypermobility spectrum disorder in Wales, UK: a national electronic cohort study and case-control comparison. *BMJ Open* 2019;**9**:e031365
- 23 Bühler RB, Sennes LU, Tsuji DH, Mauad T, Ferraz Da Silva L, Saldiva PN. Collagen type I, collagen type III, and versican in vocal fold lamina propria. *Arch Otolaryngol Head Neck Surg* 2011;**137**:604–8
- 24 Kamanli A, Gok U, Sahin S, Kaygusuz I, Ardicoglu O, Yalcin S. Bilateral cricoarytenoid joint involvement in rheumatoid arthritis: a case report. *Rheumatology* 2001;**40**:593–4
- 25 Ali A, Al Ahwel YA, Milad A, Rehman SU, Safi F, Assaly R. A new laryngeal signs in a patient with Ehler Danlos syndrome. *Am J Respir Crit Care Med* 2016;**193**:A3409
- 26 Berglund B, Nordström G. Symptoms and functional health status of individuals with Ehlers–Danlos syndrome (EDS). *J Clin Rheumatol* 2001;**7**:308–14