

Laryngeal manifestations of pachyonychia congenita: a clinical case and discussion on management for the otolaryngologist

A M O'KANE, C P JACKSON, M MAHADEVAN, C BARBER

Department of Paediatric Otolaryngology, Starship Children's Hospital, Auckland, New Zealand

Abstract

Background: Pachyonychia congenita is a rare keratinising disorder, which typically presents during the first three years of life and usually affects the nails and palmoplantar surfaces. It can involve the larynx and potentially result in life-threatening airway obstruction.

Methods: A case report is presented and the findings of a literature review are reported. The review involved a PubMed search using the keywords 'pachyonychia congenita' together with 'larynx', 'laryngeal involvement', 'laryngeal obstruction', 'airway obstruction', 'hoarseness' and/or 'stridor'.

Results: A five-year-old boy, with confirmed pachyonychia congenita, presented with complications of laryngeal involvement over a four-year period. He required three intubations and a tracheostomy for acute airway obstruction. Treatment with potassium titanyl phosphate laser laryngoscopy stabilised the progression of laryngeal disease.

Conclusion: Patients with pachyonychia congenita and laryngeal involvement can have a varied presentation, ranging from hoarseness to acute airway obstruction. Management can be a challenge, requiring early evaluation, regular surveillance and aggressive treatment. This paper reports our experience in managing and treating the laryngeal complications of a child with pachyonychia congenita.

Key words: Pachyonychia Congenita; Larynx; Complications; Airway Obstruction; Hoarseness; Stridor

Introduction

Pachyonychia congenita is a rare genodermatosis, first described in 1906 by Jadassohn and Lewandowsky.¹ It characteristically affects the nails and palmoplantar surfaces, with the larynx less commonly involved.² It is transmitted as an autosomal dominant trait, and is thought to affect between 5000 and 10 000 people worldwide.³

Pachyonychia congenita is caused by mutations in one of five keratin genes: KRT6A, KRT6B, KRT6C, KRT16 and KRT17. A new classification system now divides pachyonychia congenita into subtypes PC-K6a, PC-K6b, PC-K6c, PC-K16 and PC-K17, depending on the encoding genes affected.⁴ Keratins play an integral role in epidermal cell integrity and mechanical strength. Mutations in these five genes result in fragility of the epithelial cell cytoskeleton, which leads to cell cytolysis and subsequent hyperkeratosis.^{5–7}

The clinical manifestations of pachyonychia congenita normally present within the first three years of life,³ and include nail dystrophy, painful palmoplantar keratoderma, follicular hyperkeratosis and mucosal leukokeratosis.^{2,3} Involvement of the larynx is a less common clinical feature. When affected, patients usually present with hoarseness and, much more rarely, laryngeal obstruction.

Pachyonychia congenita with laryngeal involvement has an unknown prevalence. Hoarseness has been reported with varying frequency in the literature. In 1987, Benjamin

et al. found that hoarseness arose in less than 10 per cent of patients with pachyonychia congenita.⁸ When Eliason *et al.* surveyed the clinical symptoms of 254 patients with confirmed pachyonychia congenita, patients were directly questioned about voice quality. In that cohort, hoarseness was present in 28 per cent of cases.³

We present the case of a 5-year old boy with pachyonychia congenita, subtype PC-K6a, who, from the age of 10 months, had repeated presentations with laryngeal obstruction following upper respiratory tract infections (URTIs).

Case report

A five-year-old boy was diagnosed with pachyonychia congenita at four weeks of age, when he presented with thickening of his fingernails (Figure 1) and oral plaques. This diagnosis was confirmed at nine months following genetic analysis, which showed a KRT6A gene mutation. Family history revealed he was born to non-consanguineous parents, and his mother, father and sister are all unaffected.

The first symptoms of laryngeal obstruction began at 10 months of age, when he developed stridor, shortness of breath and increased work of breathing following a coryzal illness. He attended the local ENT department where he was intubated to stabilise his airway for transfer to a tertiary centre (Starship Children's Hospital, Auckland, New Zealand).

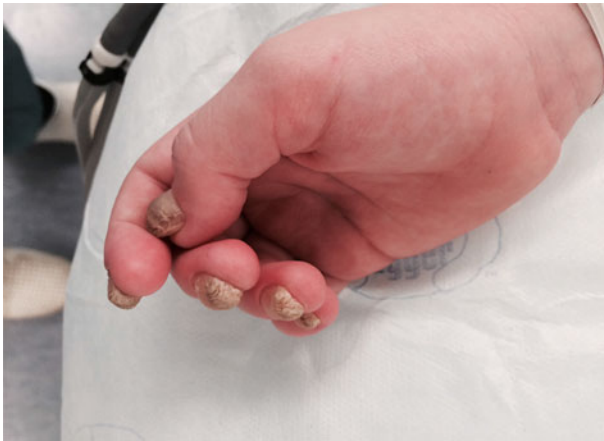

FIG. 1
Thickened fingernails.

The patient underwent laryngoscopy and bronchoscopy, which revealed laryngeal obstruction due to vocal fold oedema and keratin plaques on the true vocal folds and epiglottis (Figure 2). The keratosis was debulked. After a failed trial extubation in the operating theatre, the patient remained intubated for 7 days in the paediatric intensive care unit, receiving antibiotics and steroids. He was discharged 3 days following extubation.

Over the next year, the patient was admitted with stridor and increased work of breathing on two occasions; this was successfully managed with steroids and antibiotics. His voice was noted to remain hoarse in between attacks.

At two years of age, following a URTI, the patient presented locally with stridor and significant airway obstruction. He underwent laryngoscopy and bronchoscopy, which revealed large plaques of keratosis and oedema on both vocal folds causing near total airway occlusion. A tracheostomy was performed to secure his airway and he was transferred to Starship Children's Hospital. His tracheostomy was successfully decannulated after three weeks of treatment with antibiotics and steroids.

Over the next 18 months, the patient was admitted for two further periods of intubation for laryngeal obstruction. Both followed a URTI. After these multiple admissions, a decision was made to aggressively debulk each side sequentially in an

attempt to achieve disease control (Figures 3–5). On each of these occasions, the potassium titanyl phosphate (KTP) laser was not only used to remove all visible keratosis on the larynx but also to debulk oedematous tissue.

This intervention was successful and there have been no further emergency presentations or requirement for intubation. Serial laryngoscopies, performed at four-monthly intervals, show a more stable larynx (Figure 6). The patient has some hoarseness, but a useful and easily intelligible voice.

Discussion

Pachyonychia congenita is a rare keratinising disorder that typically affects the nails and palmoplantar skin, but can also involve the hair, oral mucosa, tongue and larynx.²

Patients with a KRT6A mutation (as in our case) are more likely to have laryngeal involvement than those with other pachyonychia congenita subtypes.^{3,9} Eliason *et al.* found that of the 71 patients who reported hoarseness, 69 per cent had KRT6A mutations, and, less frequently, KRT16 (21 per cent), KRT17 (14 per cent) and KRT6B (9 per cent).³ Shah *et al.* reported a higher proportion of their 17 patients with hoarseness having a KRT6A mutation, with a frequency of 82 per cent; 12 per cent of patients with hoarseness had a KRT17 mutation and 6 per cent had KRT16.⁹ No patients with KRT6B or KRT6C mutations reported hoarseness as a clinical symptom. This discrepancy may be accounted for by the different sample sizes.

The presence of hoarseness within the first year of life, with or without oral leukokeratosis, would suggest the diagnosis of a KRT6A mutation.^{2,3,9} This was demonstrated by Haber and Drummond, where the first presentation of hoarseness and signs of laryngeal obstruction was at nine months of age.¹⁰ Our patient presented with similar symptoms at a similar age. These are the only two reported cases of laryngeal obstruction where the diagnosis of subtype PC-K6a has been confirmed using mutational genetic tests.

Although laryngeal involvement is rare in patients with pachyonychia congenita, it has the potential to be life-threatening because of airway obstruction. There have been four other reported cases describing this complication in the literature.^{10–13} Upper respiratory tract infection appeared to be a precipitating factor in developing airway compromise

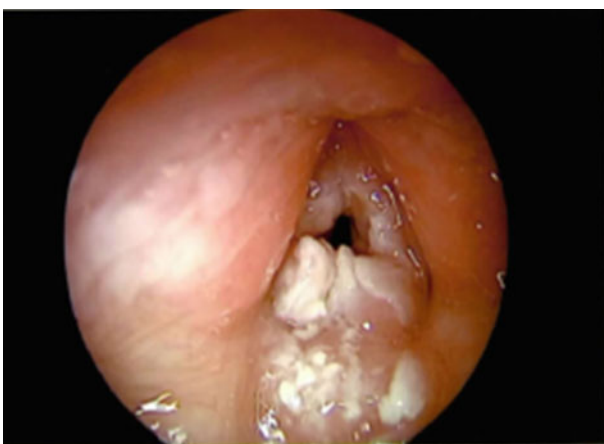

FIG. 2
Laryngoscopic view at first presentation.

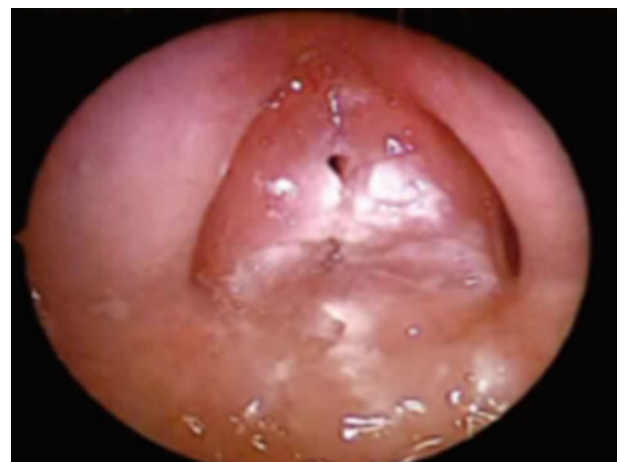

FIG. 3
Laryngoscopic view before laser debulking.

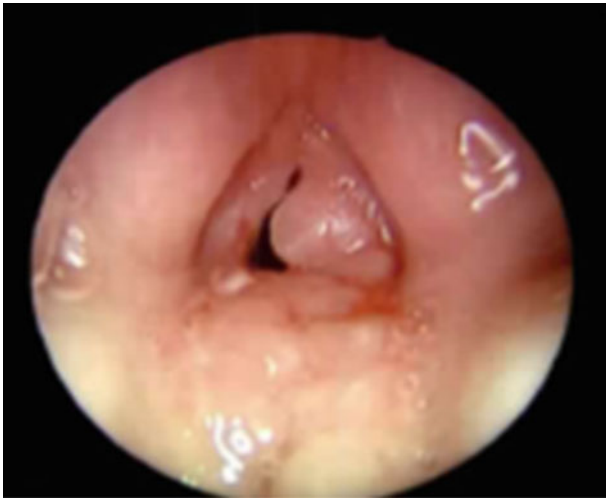

FIG. 4

Laryngoscopic view three weeks following laser to left vocal fold.

in our patient, who on each admission had preceding coryzal symptoms. This is the second report of a patient with a KRT6A mutation presenting with laryngeal obstruction following a URTI.¹⁰ Other cases of pachyonychia congenita, without genetic confirmation of subtype, have been reported by Wudy *et al.*¹³ and Cohn *et al.*,¹¹ who described worsening airway symptoms in their patients following URTIs.

Given the variability of clinical presentation, which ranges from asymptomatic to sudden and acute airway obstruction, the management and treatment of pachyonychia congenita patients with laryngeal involvement is a challenging one, requiring a multidisciplinary approach. Early endoscopic evaluation of children with hoarseness is necessary to assess the airway and monitor disease progression. This is particularly important in patients younger than three years with a smaller laryngeal aperture, where hyperkeratosis can lead more quickly to airway compromise.¹³ Flexible nasendoscopy is a quick out-patient procedure that does not require a general anaesthetic, and is a useful tool in the initial assessment and surveillance of the larynx. Identifying the genetic subtype can also be helpful in predicting the potential risk of laryngeal

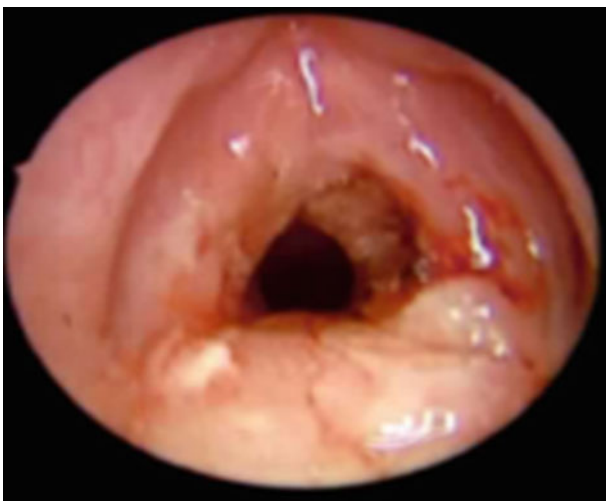

FIG. 5

Laryngoscopic view after final sequential laser debulking.

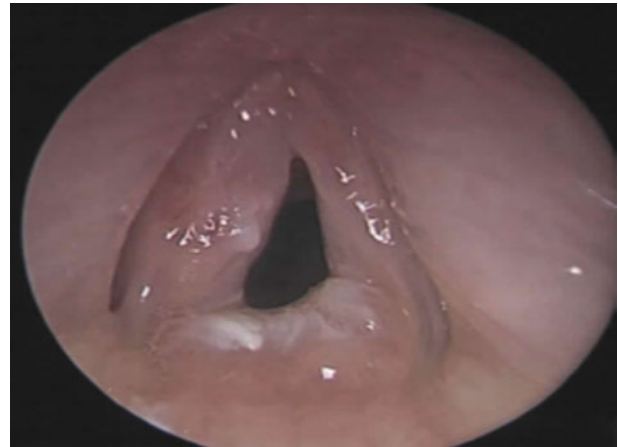


FIG. 6

Laryngoscopic view one year following laser debulking.

involvement; for instance, those with subtype PC-K6a appear to be more susceptible, particularly at a young age.^{2,3,9} As was seen in our case and in others reported in the literature,^{10,11,13} URTIs can worsen symptoms; hence a lower threshold to admit these patients for observation and treatment may be advisable.

- **Pachyonychia congenita is a rare keratinising disorder, normally affecting nails and skin**
- **Laryngeal keratosis is a less common occurrence, presenting as hoarseness or acute airway obstruction**
- **Early endoscopy is essential in diagnosis and surveillance of the disease**
- **Upper respiratory tract infections can exacerbate symptoms**
- **Laryngeal manifestations of pachyonychia congenita respond well to aggressive laser debulking of hyperkeratosis and oedema**

Conservative management is not the treatment of choice for pachyonychia congenita patients with airway obstruction; surgical intervention is needed to re-establish the airway.¹³ In earlier reports by Wudy *et al.*¹³ and Cohn *et al.*,¹¹ micro-laryngeal techniques were used to excise exophytic lesions, with good effect. More recently, Haber and Drummond described the use of carbon dioxide laser laryngoscopy on a nine-month-old girl who presented acutely with stridor and hoarseness.¹⁰ They carried out two laser treatments, one month apart, and the child remained symptom-free for just over two years. When features of laryngeal involvement returned at the age of three years, they were milder, and fewer deposits of hyperkeratosis, which were then removed by laser, were found on the larynx.¹⁰ We have found that using a KTP laser to aggressively debulk hyperkeratotic lesions and oedema of the larynx has kept our patient's symptoms and acute re-presentation under control. Prior to this, conservative management with steroids and antibiotics meant that the patient required periods of intubation on three occasions and a tracheostomy. Potassium titanyl phosphate laser laryngoscopy has been performed three times,

resulting in a more stable airway, with no further intubations required.

Conclusion

Pachyonychia congenita can cause laryngeal keratosis, which can lead to hoarseness and progress to airway obstruction. When a child with pachyonychia congenita develops hoarseness or respiratory symptoms, we recommend early endoscopy to evaluate the larynx, and genetic analysis to determine the pachyonychia congenita subtype. The symptom of hoarseness in a child with pachyonychia congenita who is younger than 12 months would suggest the presence of a KRT6A mutation. Our experience indicates that the laryngeal keratosis and oedema typical of this condition respond well to aggressive KTP laser debulking. This article will increase awareness of the laryngeal manifestations of pachyonychia congenita and provide a framework for a management strategy.

References

- Jadassohn J, Lewandowsky F. *Pachyonychia Congenita: Keratosis Disseminata Circumscripta (Folliculosis)*. *Ikonographia Dermatologica*. Berlin: Urban and Schwarzenberg, 1906
- Leachman SA, Kaspar RL, Fleckman P, Florell SR, Smith FJ, McLean WH *et al.* Clinical and pathological features of pachyonychia congenita. *J Invest Dermatol Symp Proc* 2005;**10**:3–17
- Eliason MJ, Leachman SA, Feng BJ, Schwartz ME, Hansen CD. A review of the clinical phenotype of 254 patients with genetically confirmed pachyonychia congenita. *J Am Acad Dermatol* 2012;**67**:680–6
- Wilson NJ, Leachman SA, Hansen CD, McMullan AC, Milstone LM, Schwartz ME *et al.* A large mutational study in pachyonychia congenita. *J Invest Dermatol* 2011;**131**:1018–24
- McLean WH, Hansen CD, Eliason MJ, Smith FJ. The phenotypic and molecular genetic features of pachyonychia congenita. *J Invest Dermatol* 2011;**131**:1015–17
- McLean WH, Smith FJ, Cassidy AJ. Insights into genotype-phenotype correlation in pachyonychia congenita from the human intermediate filament mutation database. *J Invest Dermatol Symp Proc* 2005;**10**:31–6
- McLean WH, Moore CB. Keratin disorders: from gene to therapy. *Hum Mol Genet* 2011;**20**:R189–97
- Benjamin B, Parsons DS, Molloy HF. Pachyonychia congenita with laryngeal involvement. *Int J Pediatr Otorhinolaryngol* 1987;**13**:205–9
- Shah S, Boen M, Kenner-Bell B, Schwartz M, Rademaker A, Paller AS. Pachyonychia congenita in paediatric patients: natural history, features, and impact. *JAMA Dermatol* 2014;**150**:146–53
- Haber RM, Drummond D. Pachyonychia congenita with laryngeal obstruction. *Paediatr Dermatol* 2011;**28**:429–32
- Cohn AM, McFarlane JR, Knox J. Pachyonychia congenita with involvement of the larynx. *Arch Otolaryngol* 1976;**102**:233–5
- Stieglitz JB, Centerwall WR. Pachyonychia congenita (Jadassohn-Lewandowsky syndrome): a seventeen-member, four-generation pedigree with unusual respiratory and dental involvement. *Am J Med Genet* 1983;**14**:21–8
- Wudy SA, Lenders H, Pirsig W, Mohr W, Teller WM. Diagnosis and management of laryngeal obstruction in childhood pachyonychia congenita. *Int J Pediatr Otorhinolaryngol* 1995;**31**:109–15

Address for correspondence:

Dr Anna M O'Kane,
27 Cleaver Avenue,
Belfast BT9 5JA,
Northern Ireland, UK

Fax: 02890 665 778

E-mail: okaneam@doctors.org.uk

Dr A M O'Kane takes responsibility for the integrity of the content of the paper

Competing interests: None declared
