



Original Article

Cite this article: Korsuize NA, Bakhuis W, van Wijk B, Grotenhuis HB, ter Heide H, Cohen de Lara M, Fejzic Z, Schoof PH, Haas F, and Steenhuis TJ (2024) Truncus arteriosus from prenatal diagnosis to clinical outcome: a single-centre experience. *Cardiology in the Young* **34**: 1921–1927. doi: [10.1017/S1047951124025071](https://doi.org/10.1017/S1047951124025071)

Received: 22 November 2023

Revised: 21 March 2024

Accepted: 14 April 2024

First published online: 13 May 2024

Keywords:


truncus arteriosus; prenatal detection; direct connection; single-centre experience

Corresponding author:

T. J. Steenhuis;

Email: tj.steenhuis-2@umcutrecht.nl

[†]Deceased

Nina A. Korsuize^{1,2} , Wouter Bakhuis^{1,2}, Bram van Wijk¹, Heynric B. Grotenhuis², Henriëtte ter Heide^{2,3}, Michelle Cohen de Lara⁴, Zina Fejzic⁵, Paul H. Schoof¹, Felix Haas^{1,†} and Trinette J. Steenhuis^{2,3}

¹Department of Pediatric Cardiothoracic Surgery, University Medical Center Utrecht/Wilhelmina Children's Hospital, Utrecht, The Netherlands; ²Department of Pediatric Cardiology, University Medical Center Utrecht/Wilhelmina Children's Hospital, Utrecht, The Netherlands; ³Department of Fetal Cardiology, University Medical Center Utrecht/Wilhelmina Children's Hospital, Utrecht, The Netherlands; ⁴Department of Gynecology and Obstetrics, University Medical Center Utrecht/Wilhelmina Children's Hospital, Utrecht, The Netherlands and ⁵Department of Pediatric Cardiology, Amalia Children's Hospital, Radboud University Medical Center, Nijmegen, The Netherlands

Abstract

Background: The aim of this study was to review our institution's experience with truncus arteriosus from prenatal diagnosis to clinical outcome. **Methods:** and results: We conducted a single-centre retrospective cohort study for the years 2005–2020. Truncus arteriosus antenatal echocardiographic diagnostic accuracy within our institution was 92.3%. After antenatal diagnosis, five parents (31%) decided to terminate the pregnancy. After inclusion from referring hospitals, 16 patients were offered surgery and were available for follow-up. Right ventricle-to-pulmonary artery continuity was preferably established without the use of a valve (direct connection), which was possible in 14 patients (88%). There was no early or late mortality. Reinterventions were performed in half of the patients at latest follow-up (median follow-up of 5.4 years). At a median age of 5.5 years, 13 out of 14 patients were still without right ventricle-to-pulmonary artery valve, which was well tolerated without signs of right heart failure. The right ventricle demonstrated preserved systolic function as expressed by tricuspid annular plane systolic excursion z-score (-1.4 ± 1.7) and fractional area change ($44 \pm 12\%$). The dimensions and function of the left ventricle were normal at latest follow-up (ejection fraction $64.4 \pm 6.2\%$, fractional shortening $34.3 \pm 4.3\%$). **Conclusions:** This study demonstrates good prenatal diagnostic accuracy of truncus arteriosus. There was no mortality and favourable clinical outcomes at mid-term follow-up, with little interventions on the right ventricle-to-pulmonary artery connection and no right ventricle deterioration. This supports the notion that current perspectives of patients with truncus arteriosus are good, in contrast to the poor historic outcome series. This insight can be used in counselling and surgical decision-making.

Common arterial trunk or truncus arteriosus is a cyanotic CHD in which the truncal root fails to divide into an aorta and pulmonary artery, which results in a single outflow tract that supplies blood to both the pulmonary and systemic circulation.¹ The incidence of truncus arteriosus is 0.6 per 10,000 live births.² The prognosis of unrepaired truncus arteriosus is generally grave, with estimated mortality rates ranging between 70 and 85% secondary to congestive heart failure in early life.³ Recent studies report operative mortality rates between 7 and 13%.^{4,5}

Prenatal echocardiographic diagnosis of CHD has improved significantly over the last decade and the current prenatal echocardiographic truncus arteriosus diagnostic accuracy is reported as high as 87%.^{6–9} Nevertheless, diagnosing truncus arteriosus on prenatal echocardiography can be challenging as it shows similarities with conditions like severe tetralogy of Fallot and pulmonary atresia with ventricular septal defect. Additional factors like fetal movement, fetal positioning, and maternal habitus also play an important role.⁷

The content of counselling for parents after prenatal diagnosis depends on the type of truncus arteriosus and the presence of other cardiac lesions and/or extracardiac anomalies. The association of truncus arteriosus with genetic disorders is discussed and prenatal genetic testing is advised (amniocentesis). When evaluation is completed, management options are discussed including continuation of pregnancy followed by delivery and comfort care or surgical intervention, and termination of pregnancy. In literature, rates of termination of pregnancy range from 22 to 90%.^{9–11} In our centre, counselling is aimed to be neutral with provision of appropriate facts about outcome and quality of life.

To avoid damage to the lungs, neonates require surgery in the first weeks of life.^{12,13} The surgical procedure can be performed as a primary reconstruction or a two-stage repair (bilateral pulmonary artery banding followed by complete repair). Primary surgical repair is the therapy of choice in most centres and preferred by some because of higher reported survival rates.¹⁴

© The Author(s), 2024. Published by Cambridge University Press. This is an Open Access article, distributed under the terms of the Creative Commons Attribution licence (<http://creativecommons.org/licenses/by/4.0/>), which permits unrestricted re-use, distribution and reproduction, provided the original article is properly cited.

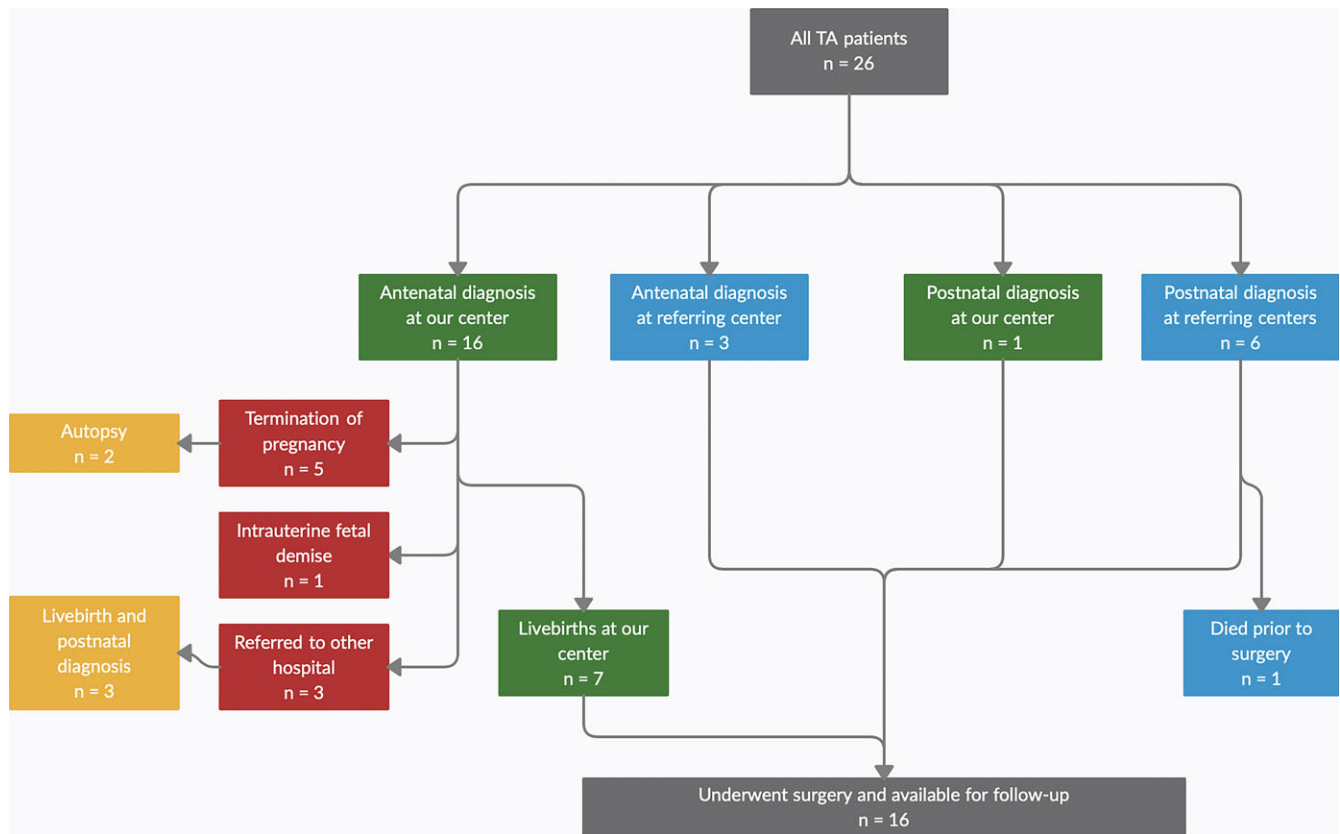


Figure 1. Flow diagram of patient inclusion. The patient selection for this retrospective cohort study is shown. Sixteen patients were antenatally diagnosed at our centre; of these, five pregnancies were terminated, one pregnancy resulted in intrauterine fetal demise, and three were referred (back) to other hospitals (2 nd opinions and 1 without therapeutic options at our centre). Postnatal validation was available for 13 patients (seven livebirths that were antenatally diagnosed, three livebirths in other hospitals, one postnatal diagnosis, and two autopsies). Three patients were antenatally diagnosed at a referring hospital. Six patients were postnatally diagnosed with TA at referring centres (of which one died prior to surgery). Sixteen patients underwent corrective surgery at our centre and were available for follow-up. TA = truncus arteriosus.

The surgical procedure mainly consists of separating the pulmonary artery from the ascending aorta, ventricular septal defect closure, and establishing a right ventricle-to-pulmonary artery connection.

The aim of this study was to review our institution's experience with truncus arteriosus from prenatal diagnosis to clinical outcome, to allow for more accurate prenatal counselling and improve clinical and surgical decision-making.

Materials and methods

The study was approved by the local institutional research ethics board and consent was obtained from all parents.¹⁵ Women carrying a child with truncus arteriosus who visited our fetal cardiology department between January 2005 and January 2020 were identified through our antenatal records and included in our study. Patients with truncus arteriosus were also identified from our surgical database. Major surgical complications were classified as mechanical circulatory support, (non-)fatal cardiac arrest, heart block needing a permanent pacemaker, reopening for bleeding/tamponade, requirement of renal replacement therapy, and/or permanent neurological deficit. Reintervention was defined as a reoperation or catheter-based intervention. Follow-up information was obtained retrospectively from the electronic medical record system. The flow diagram of patient inclusion is shown in Figure 1.

Women who were carrying a child with truncus arteriosus were identified through our antenatal records. They were referred to our centre either by a primary or secondary healthcare provider or by

another tertiary centre for a second opinion. In the Netherlands, a structural fetal screening programme was implemented in 2007, which provides a standard anomaly scan performed in primary and secondary healthcare centres (carried out by specialised sonographers or gynaecologists) between 18 and 22 weeks of gestation. If CHD is suspected, a fetal cardiologist in a tertiary centre performs a dedicated fetal cardiac echocardiogram. Echocardiography in our centre was performed using a General Electric Healthcare Voluson E8/E10 Ultrasound system with General Electric software. In addition, some truncus arteriosus patients were diagnosed postnatally, both at our centre and other referring centres in the Netherlands. The latter were referred to our centre for corrective surgery. All livebirths who underwent surgery at our institution were available for follow-up.

Primary surgical correction was performed in all patients. The heart was approached via median sternotomy and the surgery was performed with the use of cardiopulmonary bypass. The pulmonary arterial confluence was detached from the truncus. Then the truncal valve was inspected, and we found two truncal valve anomalies: one bicuspid and one quadricuspid valve. None of the patients required concomitant valve repair. The aorta was reconstructed either primarily or by using an autologous or bovine pericardium patch. The ventricular septal defect was closed with a Gore-Tex patch through a right ventriculotomy. Right ventricle-to-pulmonary artery reconstruction was preferably performed without the use of a valved conduit by direct connection of pulmonary artery confluence to the right ventricle with or without the use of autologous pericardium.

All patients had regular follow-up visits with a paediatric cardiologist that included echocardiographic evaluation. Clinical condition of the patients was obtained from the medical records and retrospectively classified according to the New York Heart Association (NYHA) classification. Echocardiography was performed using General Electric (GE Healthcare, Wauwatosa, Wisconsin, USA) ultrasound systems. All echocardiograms were retrospectively evaluated by a single cardiologist (HG). The following dimensions were recorded: left ventricular end-diastolic dimension, left ventricular end-systolic dimension, left ventricular interventricular septum thickness at diastole, and left ventricular posterior wall thickness in diastole. Z-scores were calculated for all left ventricular dimensions based on body surface area according to the Haycock Formula.¹⁶ Furthermore, heart function parameters were collected: left ventricular ejection fraction, left ventricular fractional shortening, tricuspid annular plane systolic excursion, and right ventricle fractional area change. Functions of the truncal valve and the right ventricular outflow tract were analysed for degree of truncal valve insufficiency, right ventricle-to-pulmonary artery stenosis, and right ventricle-to-pulmonary artery insufficiency.

Data were analysed using IBM SPSS Statistics version 25.0 (IBM Corp. Released 2018. IBM SPSS Statistics for Windows, Version 25.0. IBM Corp, Armonk, NY, USA). Echocardiographic parameters are shown as (z-score) mean \pm standard deviation.

Results

The total study cohort consists of 26 truncus arteriosus patients, 19 of whom were antenatally diagnosed (in our centre and referring centres). Considering pregnancy terminations (5), intrauterine fetal demise (1), patients referred to other hospitals (3), and additional postnatal diagnoses of truncus arteriosus (7), a total of 16 patients who underwent primary surgical repair at our centre were available for follow-up (Fig. 1).

Antenatal diagnosis of truncus arteriosus in our centre was made in 16 patients. Fourteen parents opted for additional genetic testing via amniocentesis. Results showed genetic anomalies in three patients: deletion of chromosome 5p, trisomy 18 and 22q11.2 deletion syndrome. Termination of the pregnancy was decided in two cases, and fetal demise occurred in one. In total five pregnancies (31%) were clinically terminated; post-mortem investigations were available in two cases; both confirmed the truncus arteriosus diagnosis. The diagnostic fetal echocardiographic accuracy could be confirmed in 13 patients, either after birth (11 patients) or death (two patients). One patient was antenatally incorrectly diagnosed as having an atrioventricular septal defect in combination with hypoplasia of the aortic arch. This was considered an inconclusive fetal ultrasound result, as imaging quality was poor due to maternal abdominoplasty. Overall diagnostic accuracy was 92.3%.

Three patients did not have follow-up appointments at our institution. Two were referred to us for a second opinion and they returned to the referring hospital for delivery and surgery. Upon inquiry, both diagnoses of truncus arteriosus were postnatally confirmed, and patients were still alive. One patient was referred to another tertiary hospital for surgical correction.

Six patients were postnatally diagnosed at referring hospitals, one of whom died prior to surgery due to severe truncal valve dysplasia and circulatory failure. Combining the seven livebirths (antenatally diagnosed) at our centre, three antenatal diagnoses in referring tertiary centres, and six postnatally diagnosed patients, a total of 16 patients were accepted for corrective surgery and were available for follow-up.

The mode of delivery was recorded for all our surgical patients (n = 16). Six patients were born after spontaneous labour, five after induced labour, and five by caesarean section. Two caesarean sections were planned because of breech presentation, two were due to fetal distress, and one was due to pre-eclampsia symptoms in the mother that were not responding well to medication. The mode of delivery was based on the gynaecological history, preference of the pregnant woman, and distance to our ward. Before surgery, patients were admitted to the paediatric ICU, where they were monitored until surgery. We conduct an electrocardiogram in the first days after admittance, as well as two echocardiograms (day 1 and day 2). Additional investigations, such as daily electrocardiograms, tropoin testing, and additional echocardiography, were only conducted if there was a medical indication. These 16 patients (62.5% female) had a mean gestational age of 38 + 5 weeks (range 36 + 1–41 + 1) with an average birthweight of 3.2 kilograms (range 1.8–4.9). The median age at latest follow-up was 5.4 years. Eleven patients (69%) were classified with truncus arteriosus type I according to the Van Praagh classification, three patients with truncus arteriosus type II, one patient with type III, and one patient with type IV (with interrupted aortic arch). Four patients had a right aortic arch as secondary cardiac diagnosis. An underlying genetic anomaly was found in 25% (n = 4) of patients; three patients were diagnosed with 22q11.2 deletion syndrome, and one patient with Coloboma, Heart defects, Atresia choanae, Growth retardation, Genital abnormalities and Ear abnormalities (CHARGE) syndrome with a CHD7 deletion.

Sixteen patients underwent surgery at a median age of 9.5 days (range 5–47) and a median weight of 3.2 kilograms (range 1.8–4.8). Primary repair was performed in all patients. Operation was delayed beyond neonatal age in one patient because of low birthweight. No pulmonary artery banding was performed in our cohort. To limit future reoperations, primary right ventricle-to-pulmonary artery connection was preferred in all patients. In two patients (12%), the distance between the right ventricle and pulmonary artery did not allow for a direct connection; a valveless Gore-Tex conduit was used in one and a valved aortic homograft in the other.

Median ICU length of stay was 9 days (range 3–20), with a median ventilation time of 5 days (range 3–15). Total hospital stay was a median of 20.5 days (range 15–33). Reoperation for bleeding was necessary in one case. Arrhythmias and pulmonary hypertension were transitory. No patient needed mechanical circulatory support, placement of a pacemaker, or renal replacement therapy. Moreover, none of the patients sustained any neurological events.

There was no early or late mortality in our cohort. At latest follow-up, all patients showed good functional capacity (class I or II of the NYHA and modified Ross Heart Failure Classification).^{17,18}

Cognitive capacity, based on daily functioning, was normal in 63% of the patients (including one patient with 22q11.2 deletion syndrome). Three patients with developmental delay required special needs education (two with 22q11.2 deletion syndrome and one with CHARGE syndrome). One patient with no underlying genetic defect had mildly impaired motor functions.

After a median follow-up of 5.4 years (range 0.01–12.5), eight patients were free from any reintervention, seven patients with direct right ventricle-to-pulmonary artery connection, and one patient with a Gore-Tex conduit (Fig. 2). Two patients (13%) required surgical reintervention, five patients (31%) required one or more catheter-based reinterventions, and one patient required both. If reoperation was necessary, it was performed in the first year after index surgery (median 4.5 months (range 1.1–76.6)). The median interval for catheterisation after primary procedure was

Table 1. Echocardiographic parameters at latest follow-up

Variable		Mean ± SD
LVEDD z-score		-0.2 ± 1.2
LVESD z-score		0.4 ± 1.1
LVISD z-score		-0.2 ± 1.0
LVPWD z-score		0.5 ± 1.0
TAPSE z-score		-1.4 ± 1.7
LV EF (%)		64.4 ± 6.2
LV FS (%)		34.3 ± 4.3
FAC (%)		44.4 ± 12.0
Heart valve function		
Truncal valve		
Insufficiency	No	9
	Mild	5
	Moderate	2
	Severe	0
RV-PA connection		
Insufficiency	No	0
	Mild	0
	Moderate	0
	Severe	16
Stenosis	No	15
	Mild	1
	Moderate	0
	Severe	0

LVEDD = left ventricular end-diastolic dimension; LVESD = left ventricular end-systolic dimension; LVISD = left ventricular internal systolic dimension; LVPWD = left ventricular posterior wall thickness in diastole; TAPSE = tricuspid annular plane systolic excursion; LV = left ventricular; EF = ejection fraction; FS = fractional shortening; FAC = fractional area change; and RV-PA = right ventricle to pulmonary artery.

Dimensions and function at latest echocardiographic follow-up. Mean age at latest follow-up: 4.7 years ± 3.4 years.

valveless surgical repair resulted in good mid-term clinical outcomes, with no mortality and good functional capacity at latest follow-up. Finally, a favourable clinical outcome can be anticipated in most non-syndromic live-born truncus arteriosus patients.

In our centre, prenatal diagnostic accuracy of truncus arteriosus was 92.3%, compared to the wide range reported in literature.^{6,8} Our accuracy rates could not be extrapolated to all patients because of incomplete information about prenatal screening in the referring centres and missing information on CHD diagnosis after termination of pregnancy without post-mortem exam (diagnosis could not be confirmed). The diagnostic accuracy of CHD is dependent on the type of cardiac anomaly, fetomaternal factors, and operator skills.^{7,19} The reported accuracy rate has been based on a small cohort of patients.

The termination of pregnancy rate for truncus arteriosus was 31% in our centre. In literature, a wide range of 22–90% is reported, but recent studies reported a similar termination rate and a comparable good surgical and echocardiographic outcome.^{8–11,19,20} Antenatal diagnosis of severe truncal valve insufficiency is considered to have a negative impact on surgical outcome. This may have influenced the decision to terminate the pregnancy

and is reflected in the low number of patients in our cohort with moderate to severe truncal valve insufficiency (two patients). The termination of pregnancy rate depends on several factors which, besides anatomy, can be related to the fetal cardiologist (i.e., positive or negative counselling based on experience and the presence of extracardiac anomalies), the parents (educational level, previous pregnancy outcomes, religious beliefs), or to culture/laws (e.g., whether it is accepted and/or allowed to terminate a pregnancy). Although our fetal cardiologists tend to have a neutral standpoint during counselling, the good clinical outcomes in our centre may have influenced their predictions about the future of these children, possibly resulting in a lower termination rate.

The best method of right ventricular outflow tract reconstruction remains a topic of debate worldwide.²⁹ Formerly, homografts were most commonly used for right ventricular outflow tract reconstruction, but scarcity moved surgeons to the preferred use of bioprosthetic valved conduits. However, literature and experience showed that small-diameter conduits are at risk of early stenosis, resulting in more (early) reinterventions.²¹ Therefore, our surgeons prefer right ventricle-to-pulmonary artery connection without a valve. Direct connection of the right ventricle to the pulmonary artery was applied in a number of centres, which showed freedom from reoperation and/or valve implantation of approximately 90% after 5 years.^{21,22} On the contrary, higher early mortality of this patient group was reported in some studies, ranging from 22 to 82%.^{23–25} This was not our experience.

The clinical outcomes of both antenatally and postnatally diagnosed live-born truncus arteriosus patients were good in our cohort. There was no early or late mortality, contrary to the reported mortality rate ranging from 22 to 43% after direct right ventricle-to-pulmonary artery reconstruction reported in literature.^{23,24} The Society of Thoracic Surgeons Congenital Heart Surgery database reported an early mortality rate of 9.5% after all types of truncus arteriosus repair.²⁶ In addition, a high risk of early mortality has been reported after conduitless repair, because of severe postoperative pulmonary hypertension.²⁴ However, when repair is performed early (first weeks of life), this complication does not seem to occur, which could explain that early mortality did not occur in our cohort.^{23,27} At latest follow-up, all patients showed good functional capacity (NYHA class I and II), which is in accordance with literature.²²

At a median follow-up of 5.4 years, freedom from any reintervention was 50% and freedom from surgical reintervention was 81%. One patient in our study did not require any at an age of 12.5 years old. At latest follow-up, 13 patients with a direct right ventricle-to-pulmonary artery connection (93%) were still free from valve implantation. The low number of reinterventions associated with direct reconstruction in our cohort corresponds with the rates reported in literature: freedom from any reintervention of 56%, and freedom from reoperation of approximately 90% 4 years after primary surgery.^{23,27,28} Right-sided reintervention rates are more common in patients who received a homograft at initial repair.²⁹ Once a valve implantation seems indicated, most patients have gained enough weight to receive an adult-size valved conduit.

During follow-up, one patient required truncal valve repair due to severe insufficiency. Echocardiographic follow-up showed truncal valve insufficiency in seven patients, however. As a small proportion of patients may progress from mild to moderate or more severe insufficiency, we may see more truncal valve interventions in this cohort in the future.²² Right ventricle-to-pulmonary artery insufficiency was severe in all patients, including

patients with an aortic or pulmonary homograft, but well tolerated with preserved systolic right ventricular function. We monitor right ventricular function closely, as ventricular dysfunction may become apparent at a later point in time. At latest follow-up, systolic function of the left ventricle was preserved and left ventricular dimensions remained stable and within the normal range.

Left pulmonary artery and/or right pulmonary artery stenosis was common during follow-up, which accounts for the relatively large number of catheter-based reinterventions. Pulmonary stenosis was absent in 15 patients and was mild in one, which showed that the diameter of the right ventricle-to-pulmonary artery connection remained sufficient after reconstruction with an autologous pericardial patch. In our centre, the tendency is to treat left pulmonary and/or right pulmonary artery stenosis quite aggressively, although other studies report high incidences of catheter-based interventions as well.^{30–32} Direct connection could have contributed to a greater extent of distortion of the pulmonary artery anatomy, although no literature supports this presumed correlation.

The retrospective nature of this study is a limitation. The small study cohort resulted in limited possibilities for statistical analyses, due to low power subgroup analyses were not feasible. In future research, we would like to look at the differences in clinical outcomes of prenatally diagnosed patients compared to postnatally diagnosed patients, as well as patients with and without genetic syndromes. Given the retrospective nature of the study, data on functional capacity and cognitive functioning could only be obtained through medical records, where a standardised questionnaire is preferred. A longer follow-up period is necessary to evaluate the long-term outcomes of these patients.

Conclusion

This study demonstrates good prenatal diagnostic accuracy of truncus arteriosus. There was no early or late mortality in the group of operated patients, and favourable clinical outcomes good functional capacity (NYHA class I and II) at mid-term follow-up with few right ventricle-to-pulmonary artery interventions. Valveless right ventricle-to-pulmonary artery connection is well tolerated without right ventricle deterioration at a median of 5.4 years after surgery. On echocardiographic evaluation, patients showed no significant ventricular dysfunction. This supports the notion that current perspectives of patients with truncus arteriosus are good, in contrast to the poor historic outcome series. The results of this study may justify more favourable counselling of (future) parents.

Acknowledgements. None.

Author contribution. Nina A. Korsuize, and Wouter Bakhuis, contributed equally to this work and shared first authorship. Felix Haas has sadly died and he did contribute to this article, but not as a first author.

All authors take responsibility for all aspects of the reliability and freedom from bias of the data presented and their discussed interpretation.

Financial support. None.

Competing interests. None.

Consent. The study was approved by the local institutional research ethics board and parents were informed of the data collection, in accordance with the General Data Protection Regulation legislation.

References

1. Cabalka AK, Edwards WD, Dearani JA. Truncus arteriosus. In: Allen HD, Shaddy RE, Penny DJ, Feltes TF, Cetta F (ed.). *Moss and Adams' Heart Disease in Infants, Children, and Adolescents, Including the Fetus and Young Adult*. Lippincott Williams & Wilkins, Philadelphia, 2021, pp 1053–1064.
2. Reller MD, Strickland MJ, Riehle-Colarusso T, Mahle WT, Correa A. Prevalence of congenital heart defects in Atlanta, 1998–2005. *J Pediatr* 2018; 153: 807–813.
3. Brown JW, Ruzmetov M, Okada Y, Vijay P, Turrentine MW. Truncus arteriosus repair: outcomes, risk factors, reoperation and management. *Eur J Cardiothorac Surg* 2001; 20: 221–227.
4. Mastropietro CW, Amula V, Sassalos P, et al. Characteristics and operative outcomes for children undergoing repair of truncus arteriosus: a contemporary multicenter analysis. *J Thorac Cardiovasc Surg* 2019; 157: 2386–2398.e4.
5. Naimo PS, Bell D, Fricke TA, et al. Truncus arteriosus repair: a 40-year multicenter perspective. *J Thorac Cardiovasc Surg* 2021; 161: 230–240.
6. Abel JS, Berg C, Geipel A, et al. Prenatal diagnosis, associated findings and postnatal outcome of fetuses with truncus arteriosus communis (TAC). *Arch Gynecol Obstet* 2021; 304: 1455–1466.
7. Sun HY, Proudfoot JA, McCandless RT. Prenatal detection of critical cardiac outflow tract anomalies remains suboptimal despite revised obstetrical imaging guidelines. *Congenit Heart Dis* 2018; 13: 748–756.
8. Lee MY, Won HS, Lee BS, et al. Prenatal diagnosis of common arterial trunk: a single-center's experience. *Fetal Diagn Ther* 2013; 34: 152–157.
9. Lytzen R, Vejstrup N, Bjerre J, et al. Live-born major congenital heart disease in Denmark: incidence, detection rate, and termination of pregnancy rate from 1996 to 2013. *JAMA Cardiol* 2018; 3: 829–837.
10. Morgan CT, Tang A, Fan CP, et al. Contemporary outcomes and factors associated with mortality after a fetal or postnatal diagnosis of common arterial trunk. *Can J Cardiol* 2019; 35: 446–452.
11. Marginean C, Gozar L, Mărginean CO, et al. Prenatal diagnosis of the fetal common arterial trunk. A case series. *Med Ultrason* 2018; 20: 100–104.
12. Thompson LD, McElhinney DB, Reddy VM, Petrossian E, Silverman NH, Hanley FL. Neonatal repair of truncus arteriosus: continuing improvement in outcomes. *Ann Thorac Surg* 2001; 72: 391–395.
13. Hraška V, Murín P. Septal defects. In: Hraška V, Murín P (ed.). *Surgical Management of Congenital Heart Disease II*. Springer, Berlin Heidelberg, 2015, pp 810–812.
14. Barron DJ, Vanderlaan RD. A staged approach for truncus arteriosus: proceed with caution. *Eur J Cardiothorac Surg* 2022; 61: 795–796.
15. Wright J, Gordijn B. Medical research on human subjects and RECs in the Netherlands. In: Beylvelde D, Townend D, Wright J (ed.). *Research Ethics Committees, Data Protection and Medical Research in European Countries*. Routledge, New York, 2017, pp 153–161.
16. Haycock GB, Schwartz GJ, Wisotsky DH. Geometric method for measuring body surface area: a height-weight formula validated in infants, children, and adults. *J Pediatr* 1978; 93: 62–66.
17. Yancy CW, Jessup M, Bozkurt B, et al. 2013 ACCF/AHA guideline for the management of heart failure. *J Am Coll Cardiol* 2013; 62: e147–e239.
18. Jayaprasad N. Heart failure in children. *Heart views* 2016; 17: 92.
19. Sivanandam S, Glickstein JS, Printz BF, et al. Prenatal diagnosis of conotruncal malformations: diagnostic accuracy, outcome, chromosomal abnormalities, and extracardiac anomalies. *Am J Perinatol* 2006; 23: 241–246.
20. Alsoufi B, McCracken C, Shashidharan S, Deshpande S, Kanter K, Kogon B. The impact of 22q11.2 deletion syndrome on surgical repair outcomes of conotruncal cardiac anomalies. *Ann Thorac Surg* 2016; 104: 1597–1604.
21. Iyer KS. The contegra bovine jugular valved conduit: living up to expectations? *Ann Pediatr Cardiol* 2012, 5:34.
22. Naimo PS, Konstantinov IE. Surgery for truncus arteriosus: contemporary practice. *Ann Thorac Surg* 2021; 111: 1442–1450.
23. Danton MHD, Barron DJ, Stumper O, et al. Repair of truncus arteriosus: a considered approach to right ventricular outflow tract reconstruction. *Eur J Cardiothorac Surg* 2001; 20: 95–104.
24. Lacour-Gayet F, Serraf A, Komiya T, et al. Truncus arteriosus repair: influence of techniques of right ventricular outflow tract reconstruction. *J Thorac Cardiovasc Surg* 1996; 111: 849–856.

25. Ivanov Y, Mykychak Y, Fedevych O, Motrechko O, Kurkevych A, Yemets I. Single-centre 20-year experience with repair of truncus arteriosus. *Interact Cardiovasc Thorac Surg* 2019; 29: 93–100.
26. Jacobs JP, Mayer JE Jr, Pasquali SK, et al. The society of thoracic surgeons congenital heart surgery database: 2019 update on outcomes and quality. *Ann Thorac Surg* 2019; 107: 691–704.
27. Padalino MA, Çelmeta B, Vedovelli L, Castaldi B, Vida VL, Stellin G. Alternative techniques of right ventricular outflow tract reconstruction for surgical repair of truncus arteriosus. *Interact Cardiovasc Thorac Surg* 2020; 30: 910–916.
28. Luo K, Zheng J, Zhu Z, et al. Outcomes of right ventricular outflow tract reconstruction for children with persistent truncus arteriosus: a 10-year single-center experience. *Pediatr Cardiol* 2018; 39: 565–574.
29. Guariento A, Doulamis IP, Staffa SJ, et al. Long-term outcomes of truncus arteriosus repair: a modulated renewal competing risks analysis. *J Thorac Cardiovasc Surg* 2022; 163: 224–236.e6.
30. Kalavrouziotis G, Purohit M, Ciotti G, Corno AF, Pozzi M. Truncus arteriosus communis: early and midterm results of early primary repair. *Ann Thorac Surg* 2006; 82: 2200–2206.
31. Lund AM, Vogel M, Marshall AC, et al. Early reintervention on the pulmonary arteries and right ventricular outflow tract after neonatal or early infant repair of truncus arteriosus using homograft conduits. *The Am J Cardiol* 2011; 108: 106–113.
32. Buckley JR, Amula V, Sassalos P, et al. Collaborative research in pediatric cardiac intensive care investigators. Multicenter analysis of early childhood outcomes after repair of truncus arteriosus. *Ann Thorac Surg* 2019; 107: 553–559.