

## Garnett Passe and Rodney Williams Memorial Lecture: New clinical tests of unilateral vestibular dysfunction

G. MICHAEL HALMAGYI M.D., F.R.A.C.P.

### Abstract

Vertigo is caused by unilateral vestibular dysfunction. Unilateral vestibular dysfunction represents either vestibular overactivity as benign positional vertigo or underactivity as in labyrinthitis or both, at different times, as in a Ménière's attack. Unilateral dysfunction could also be central rather than peripheral, such as in a lateral medullary syndrome. Unilateral vestibular dysfunction could affect any of the five different sensory areas in the labyrinth, the three semicircular canals and the two otoliths, or their brainstem connections. For rigorous diagnosis of the cause of vertigo, ideally one would have robust, reproducible, quantitative vestibular function tests sensitive to dysfunction of each of the five sensory regions in each ear. In working towards this ideal we have, over the last 15 years, developed three new vestibular function tests: (1) impulsive tests of individual semicircular canal function, (2) evoked potential tests of saccular function and (3) subjective visual horizontal tests of utricular function. The physiological rationale of these three tests is reviewed as well as the interpretation of their results in various diseases.

**Key words:** Vertigo; Vestibular Diseases; Labyrinth; Semicircular Canals; Otolithic Membrane

### Introduction

Much has been learnt about the normal and abnormal physiology of the vestibular system in the 100 or so years since the birth of Garnett Passe (25 June 1904) and in the 50 or so years since his presentation to the Royal Society of Medicine on the treatment of Ménière's disease with sympathectomy.<sup>1</sup> Most of this knowledge has come from recording the activity to single peripheral and central vestibular neurons in awake and behaving, as well as in anaesthetized, animals and from precise three-dimensional measurements of the vestibulo-ocular reflex in humans. We now know that symmetrical vestibular loss does not produce vertigo – it produces imbalance. Because peripheral vestibular neurons are symmetrically active at rest, vertigo, an illusion of motion, is due to asymmetrical vestibular dysfunction, most often of peripheral origin. Consequently the most valuable vestibular function tests are those that are sensitive to unilateral vestibular dysfunction, in other words tests that can lateralize. Since there are five vestibular organs in each inner ear, three semicircular canals (SCCs) to transduce angular acceleration of the head and two otoliths (utricle and saccule) to transduce linear acceleration, there will never be a single test for all unilateral vestibular dysfunction. Furthermore a vestibular organ can be overactive or underactive

at rest or it can be oversensitive or undersensitive when stimulated: this is static versus dynamic vestibular dysfunction.

The caloric test is still the basis of all vestibular testing. The advantages are that it is relatively simple and widely available and therefore the results it produces should be reproducible within, and perhaps between, laboratories. However, because of theoretical problems and practical limitations, this is not generally so. The caloric test measures only lateral SCC function and only at low frequency; it does not produce absolute values – normal nystagmus slow-phase velocity can vary from eight to 80 deg/s; the stimulus persists between irrigations and this can confound the whole test. There are also technical hurdles. Electro-oculography (EOG), the method generally used to measure the nystagmus, is bedevilled by drift and artefact and it is not easy to derive reliable nystagmus velocity signals from EOG. The patient must be kept alert throughout the test, the test must be done in darkness and not with eye closure. There can be problems with irrigation due to wax, exostoses or perforations; air and water-filled balloons produce less reliable results than the traditional warm- and cool-water irrigation. Finally there is no agreement on who should do the test and on who should train the person who does the test,

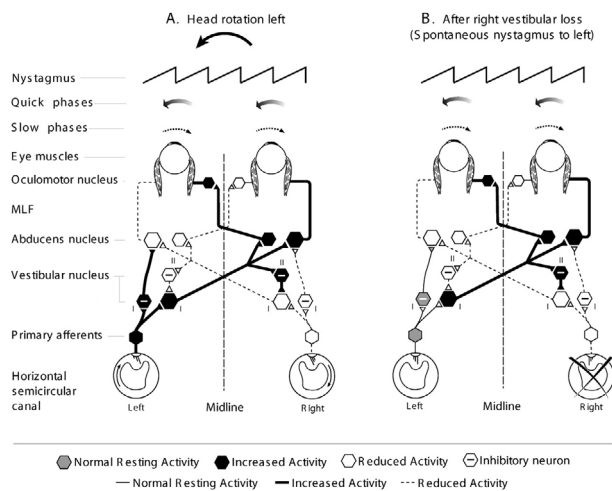


FIG. 1

Cartoon to show similarity between vestibular nucleus neural activity: (A) during a leftward head rotation, and (B) spontaneously at rest after a right vestibular deafferentation.

A. The sequence of events during a leftward head rotation is as follows: ampullopetal endolymph flow in the left lateral SCC leads to an increase in the firing rate of primary afferents in the left vestibular nerve above the normal resting rate, which leads to increased firing rate of left medial vestibular nucleus type I secondary neurons (P-V-P neurons). There is also ampullofugal endolymph flow in the right lateral SCC, which leads to decreased firing of primary afferents in the right vestibular nerve, which leads to decreased firing of right medial vestibular nucleus type I secondary neurons, which leads to decreased firing of left vestibular nucleus type II (inhibitory) neurons, which also leads to increased firing of left vestibular nucleus type I neurons. The critical point is that activation of left vestibular nucleus P-V-P neurons, the neurons which drive motoneurons innervating the right lateral and left medial recti to produce the rightward compensatory eye rotations which comprise the slow-phase of the VOR, is produced both by direct ipsilateral excitation and by indirect contralateral disinhibition.

B. After a right vestibular deafferentation there is decreased activity of right medial vestibular nucleus type I neurons at rest due to two mechanisms. There is not only loss of excitation by right vestibular nerve primary afferents, but there is also decreased activity of right vestibular nucleus type I neurons, which leads to decreased activity of left vestibular nucleus type II (inhibitory) neurons, which then leads to increased activity of left vestibular nucleus type I neurons, which then leads to increased activity of right vestibular nucleus type II neurons which then also leads to increased inhibition, i.e. decreased spontaneous resting activity of right vestibular nucleus type II neurons, which produces the rightward slow-phases of the left-beating spontaneous nystagmus, the hallmark of the right vestibular deafferentation.

and in many places it is not performed with the same attention to technical detail as are hearing tests. Infra-red video-oculography, which has become commercially available in recent years, solves some but not all of these problems.

Over the last 15 years our group has tried to develop new tests of unilateral vestibular dysfunction based on physiological and engineering principles and some of our results are reported in this lecture: head impulses to test SCC function, vestibular-evoked myogenic potentials to test saccular function and subjective visual horizontal to test utricular

function. The development of these tests has depended on robust daily collaboration between neurologists, otologists, psychologists, physiologists, electrical engineers, mechanical engineers and nurses.

## Impulsive testing of semicircular canal function

### Physiological background

The vestibular system senses the motion and the position of the head. It projects to the cerebral cortex, to the brainstem and to the spinal cord. Natural head movements produce rotations, which stimulate the SCCs, and tilts or translations that stimulate the otoliths. Cortical projections are responsible for the conscious sensations of motion; spinal projections help with balance when standing and walking; brainstem projections are responsible for the vestibulo-ocular reflex (VOR). The SCCs produce a VOR that is fully compensatory in the range of natural head movements, so that when the head rotates in one direction the eyes rotate in exactly the opposite direction at exactly the same speed as the head after a latency of only about 10 ms.

In a normal subject any head rotation, even one restricted to a single plane, will change the activity from at least one pair of SCCs, so that the brainstem signal which eventually drives the VOR is produced by an increase in neural firing rate from the resting level (i.e. excitation) from one SCC and a decrease in neural firing rate from the resting level (i.e. disfacilitation) from the other SCC of the pair, in the plane of rotation.

To illustrate this principle, consider the VOR in response to a yaw plane head rotation; this is the horizontal VOR and it arises mainly from the lateral SCCs (Figure 1). During leftward head rotation the activity of left lateral SCC primary afferent neurons increases, while at the same time the activity of right lateral SCC primary neurons decreases from the normal resting rate, which is about 90 spikes/s in the squirrel monkey.<sup>2</sup> Therefore the increase in activity of type I position-vestibular-pause (P-V-P) secondary vestibular neurons in the left medial vestibular nucleus, the neurons which drive the rightward compensatory eye rotation (i.e. the VOR), will be the result both of direct excitation from the left lateral SCC primary neurons and of indirect commissural disinhibition from the right lateral SCC primary neurons.<sup>3,4</sup> In other words the horizontal VOR normally functions as a push-pull system from the two lateral SCCs. Figure 1 also shows the similarity between the neural pathways responsible for normal vestibular nystagmus and those responsible for the nystagmus that follows acute unilateral vestibular loss.

Direct excitation and indirect disinhibition are, however, potentially asymmetrical. Although the discharge rate of a vestibular neuron can increase linearly without obvious saturation in response to a rapid yaw head rotation in the excitatory direction, i.e. in the 'on' direction, it can decrease only to zero in response to a rotation in the disfacilitatory direction, i.e. in the 'off' direction. This might be especially true for the non-linear, velocity-dependent component of the VOR which might derive from the activity of irregularly discharging primary afferents.<sup>5</sup> In

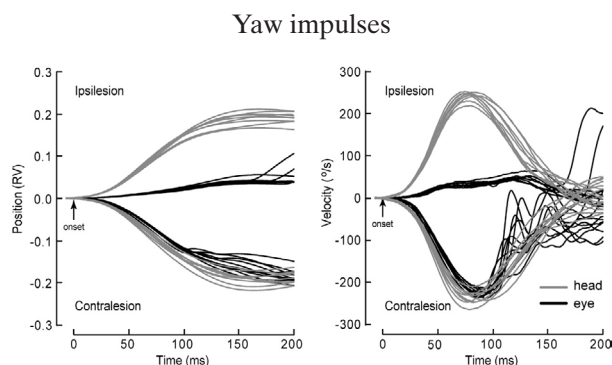


FIG. 2(a)

Horizontal head (grey) and eye (black) position and velocity during eight superimposed yaw head impulses with a peak acceleration of about 5000 deg/s in a patient 1 year after unilateral vestibular deafferentation during vestibular schwannoma surgery. With contralesional head impulses eye position approximated head position and eye velocity approximated head velocity throughout the impulse; with ipsilesional head impulses at peak head velocity of approximately 250 deg/s, eye velocity was only about 25 deg/s (gain ~ 0.1).

contrast, regularly discharging afferents, which might drive the linear component of the VOR, do not show saturation even at high head velocities.<sup>6</sup> Since most secondary SCC neurons have a lower resting rate and a higher sensitivity to angular accelerations than primary SCC neurons, they are even more easily silenced by rapid off-direction accelerations than are primary neurons<sup>7</sup> so that response asymmetry is even more marked at the level of secondary P-V-P neurons in the vestibular nuclei.

In this regard anterior and posterior SCC neurons function similarly to lateral SCC neurons. For example the mixed vertical-torsional VOR which occurs in response to a forward and clockwise (from the subject's point of view) head rotation, i.e. a head rotation in the plane of the right anterior and left posterior SCC, the so-called RALP plane, is produced by the excitation of right vestibular nucleus secondary neurons, which are themselves directly excited by right anterior SCC primary neurons and indirectly disinhibited by left posterior SCC primary neurons. However, just as in the case of lateral SCC primary neurons, direct excitation and indirect disinhibition are inherently asymmetrical. The discharge rate of primary and secondary neurons from both the anterior and the posterior SCCs can increase linearly without obvious saturation in response to rapid RALP or LARP (left anterior-right posterior) canal plane head rotations in the on-direction, but it can decrease only to zero in response to rotations in the opposite off-direction.<sup>8</sup>

#### Clinical applications

This inherent asymmetry or nonlinearity of SCC responses is not only normally concealed by the bilateral interaction between the two labyrinths, it is also artificially concealed by the methods used in most laboratories to test and analyse vestibular function: namely responses to low-acceleration

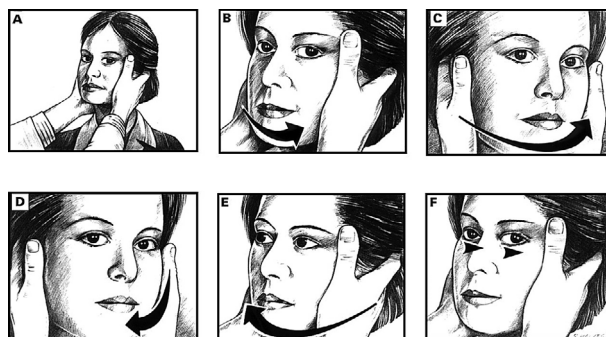


FIG. 2(b)

The horizontal head impulse test. The examiner turns the patient's head as rapidly as possible about 15 degrees to one side and observes the ability of the patient to keep fixating on a distant target. The patient illustrated has a right peripheral vestibular lesion with a severe loss of right lateral semicircular canal function. While the examiner turns the patient's head toward the normal left side (top row) the patient is able to keep fixating on target. By contrast, when the examiner turns the patient's head to the right the vestibulo-ocular reflex fails and the patient cannot keep fixating on target (E) so that she needs to make a voluntary rapid eye movement – that is, a saccade – back to target (F) after the head impulse has finished; this can be easily observed by the examiner. It is essential that the head is turned as rapidly as possible otherwise smooth pursuit eye movements will compensate for the head turn. (From Halmagyi & Cremer<sup>106</sup>).

sinusoidal rotations, analysed by algorithms which ignore threshold cut-off and directional asymmetry, and calculate gain only for the excitatory direction stimulus – i.e. standard rotational tests. All this is a pity, since the on-off asymmetry provides an excellent opportunity for the clinician to test for unilateral impairment of SCC canal function, which is the basis for most complaints of vertigo.

Testing the VOR with head 'impulses' in patients who have had a total unilateral vestibular deafferentation (uVD) yields scientifically interesting and clinically important results. Head impulses are rapid, passive, low-amplitude (10–20°), intermediate-velocity (120–180°/s), high-acceleration (3000–4000°/s<sup>2</sup>), unpredictable rotations of the head with respect to the trunk. They are delivered by an examiner who holds the patient's head firmly, and at random rapidly rotates it in the yaw plane either to the left or to the right, or in the RALP or LARP plane, either forward or backward. The patient's task is to fixate a target at 1 metre. To minimize any contribution from the cervico-ocular reflex, the visual pursuit reflex or the saccadic system, only those compensatory eye movement responses which occur in the first 150 ms after the onset of head acceleration are analysed. To represent VOR gain, eye velocity can be plotted as a function of head velocity.

In normal subjects, the horizontal VOR in response to yaw plane head impulses has a velocity gain of  $0.94 \pm 0.08$  (SD) at an arbitrary 122°/s head velocity. In contrast the vertical-torsional VOR in response to RALP and LARP plane head impulses has a gain of only 0.7 to 0.8, probably because the

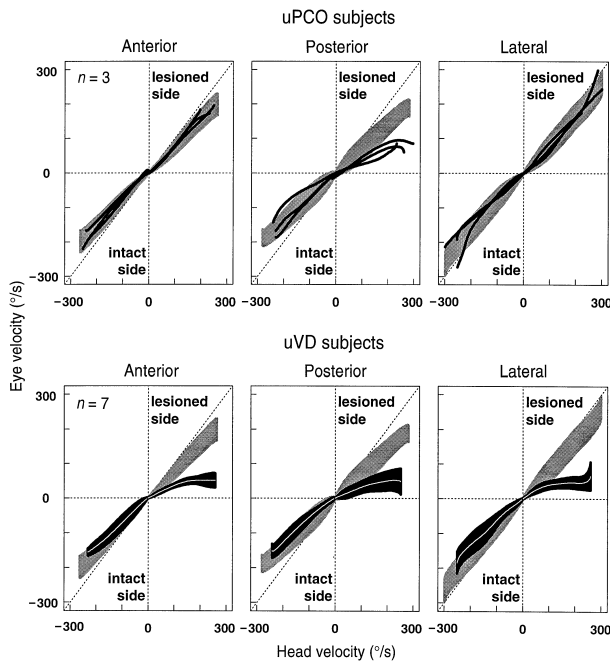


FIG. 3

Eye velocity as a function of averaged head velocity for each of three unilateral posterior SCC occlusion subjects (top row), and averaged eye velocity (95 per cent confidence intervals) for seven uVD subjects (bottom row). The VOR during head impulses directed toward the anterior SCC is shown in the left column, toward the posterior SCC in the middle column and toward the lateral SCC in the right column. The normal range (average 95 per cent confidence intervals) is shown as a grey band in each plot. The VOR during ipsilesional head impulses is shown on the right side of each graph, and for contralesional head impulses on the left side of each graph. The eye velocity is limited to  $<100^\circ/\text{s}$  during head impulses in the direction of any lesioned SCC. (From Cremer *et al.*<sup>15</sup>).

gain of the roll-torsional VOR is lower than the gain of the pitch-vertical VOR in normals. Following uVD, in response to ipsilesional yaw plane head impulses, the VOR now generated only by disfacilitation from the single functioning lateral SCC, is severely deficient.<sup>9,10</sup> Eye velocity gain decreases with increasing head velocity and appears to saturate at about 0.20 (Figure 2). In contrast, in response to contralesional yaw plane head impulses, the VOR generated by excitation from the single functioning lateral SCC, is only mildly deficient, with a maximal velocity gain of 0.92. A high-acceleration rotation saturates the ipsilesional, i.e. off-direction, horizontal VOR in the human and in the guinea pig<sup>11</sup> just as it saturates the off-direction discharge rate of lateral SCC afferents in cat, monkey, rat and guinea pig.<sup>2,12</sup>

Silencing of irregularly discharging primary lateral SCC neurons in the contralesional, i.e. intact, vestibular nerve, leading to maximal disinhibition of type I secondary lateral SCC neurons in the ipsilesional vestibular nucleus<sup>2</sup> could be the reason why a symmetrical head-rotation stimulus produces an asymmetrical eye-rotation response in a subject in whom only one SCC is being stimulated (Ewald's second law), and is also the reason why the magnitude of the response asymmetry is a function of the

magnitude of the stimulus. Furthermore, in response to high-acceleration stimulation, excitation of a single lateral SCC can by itself produce a near-normal horizontal VOR. This suggests that in humans, as well as in the monkey, disinhibition of ipsilateral type I neurons from the contralateral lateral SCC makes only a small contribution to the horizontal VOR.<sup>13,14</sup>

Following uVD the vertical-torsional VOR in response to RALP and LARP plane head impulses behaves similarly to the horizontal VOR.<sup>15</sup> In response to head impulses toward the lesioned anterior or posterior SCC, that is, in the off-direction of the intact posterior or anterior SCC, the VOR is severely deficient. With impulsive testing selective deficits of vertical SCC function can be detected in acute superior vestibular neuritis, which affects only the anterior and lateral SCC nerves, and in acute inferior vestibular neuritis, which affects only the posterior SCC nerve.<sup>16</sup> Impulsive testing can be a useful way to follow progress in patients who have had intratympanic gentamicin therapy for Ménière's disease.<sup>17</sup>

With practice it is possible to recognize VOR deficits in response to head impulses clinically. If the VOR is completely normal then the patient will be able to maintain visual fixation during head impulses in any direction. If the VOR is severely defective then the patient will not be able to maintain fixation and will need to make one or two refixating saccades, which the clinician can observe.<sup>18</sup> For example, if in response to a leftward head impulse the patient makes a rightward saccade in order to maintain fixation, this indicates that the left lateral SCC is not functioning properly (Figure 2). Similarly if in response to a backward and CW head impulse the patient makes a downward saccade, this indicates that the right posterior SCC is not working properly. In general the deficit in SCC function needs to be severe in order for the compensatory saccadic eye movements to be large enough to be observed clinically.

#### Semicircular canal occlusion

Occluding an SCC duct inactivates it by preventing endolymph flow. A procedure dating to Ewald<sup>19</sup> is now used to treat patients with intractable benign paroxysmal positional vertigo (BPPV).<sup>20,21</sup> The cause of BPPV is movement of displaced otoconia in the duct of the SCC, usually a posterior, causing cupular displacement and hence vertigo and nystagmus. Since neither humans nor animals show any static symptoms such as spontaneous nystagmus after SCC occlusion, as would be expected if the labyrinth had been damaged, primary afferents from the occluded SCC presumably continue to fire at the usual resting rate. In humans<sup>15</sup> as well as in guinea-pigs<sup>22</sup> and squirrel monkeys<sup>13</sup> but not in the toadfish<sup>23</sup> impulsive testing detects the SCC that has been occluded (Figure 3). The high-acceleration VOR deficit is permanent in humans<sup>15,24</sup> and in guinea-pigs<sup>22</sup> but only temporary in squirrel and rhesus monkeys.<sup>14,25</sup>

Confirmation that uVD produces a permanent VOR deficit in response to high-acceleration stimulation in primates,<sup>13</sup> as well as in humans<sup>26,27</sup> has

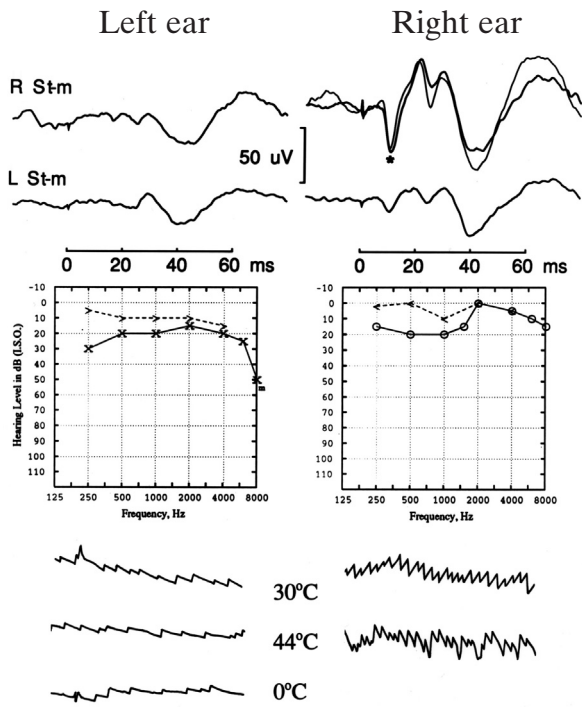


FIG. 4(a)

Effect of unilateral vestibular deafferentation on the VEMP in a patient who had previously undergone a selective left vestibular nerve section for intractable vertigo. The left part of the figure refers to results for the left ear, the right side to the right. The audiograms confirm that hearing was well preserved, while the caloric tests (bottom row) show only spontaneous right-beating nystagmus and no response to caloric stimulation of the left ear, consistent with previous vestibular deafferentation. Clicks of 100 dB intensity delivered to the right ear generate a normal  $p13^*-n23$  response in the ipsilateral right sternocleidomastoid muscles with a weak crossed response in the left sternocleidomastoid (top row). In contrast, clicks of the same intensity applied to the left ear generated no  $p13-n23$  response in either sternocleidomastoid muscle, although later potentials were still apparent. (From Colebatch *et al.*<sup>33</sup>).

implications for the diagnosis and treatment of vestibular diseases,<sup>28,29</sup> and also raises questions about the extent of the dynamic compensation that really occurs when accelerations within the range produced by natural head movements are encountered. The diagnostic significance of these observations is that it is possible to demonstrate at the bedside the severe permanent deficit in the ipsilesional VOR produced by uVD. For example a yaw head impulse toward the lesioned side will produce a clinically obvious compensatory saccade or series of saccades toward the intact side.<sup>18</sup> Low-frequency, low-acceleration sinusoidal testing of the type routinely used for testing the horizontal VOR in humans and in experimental animals is artificially restricted to the narrow linear response range of the horizontal SCC, and is therefore unsuitable for detecting or monitoring unilateral vestibular lesions. Only when high-acceleration passive head rotations are used, does the expected deficit in compensatory eye movements become apparent.<sup>30</sup>

However, some patients with unilateral impairment of lateral SCC on caloric testing can have

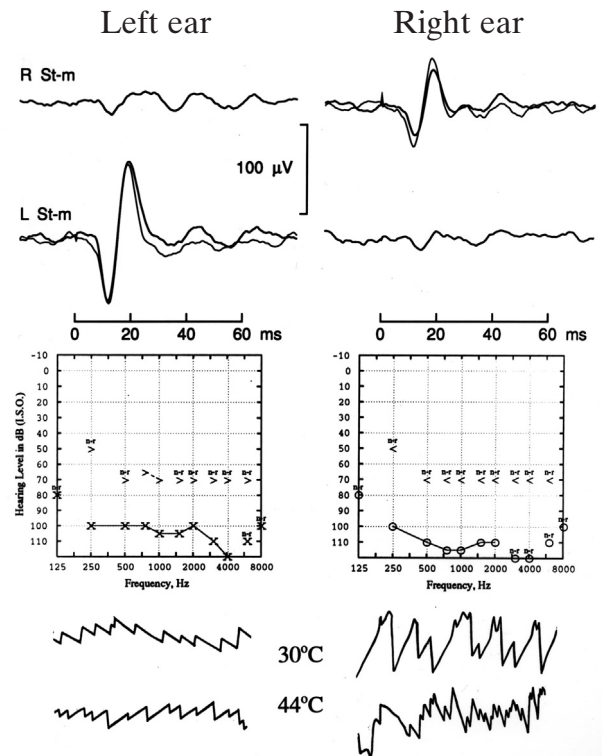


FIG. 4(b)

The lack of effect of severe cochlear loss on the VEMP in a patient with intact lateral SCC function, as indicated by preserved horizontal nystagmus in response to caloric stimulation (bottom panel). Clicks of 100 dB intensity to the left and right ears (top row) each generated normal  $p13-n23$  responses in the ipsilateral sternocleidomastoid muscles, although the patient could not hear them. (From Colebatch *et al.*<sup>33</sup>).

normal impulsive tests and conversely some patients with unilateral impairment of lateral SCC on impulsive testing have normal caloric tests.<sup>31</sup> These findings suggest the SCC pathology just as cochlear pathology can produce frequency-specific functional deficits: whereas impulsive testing represents a 4–5 Hz stimulus, the dominant frequency of the caloric test is around 0.025 Hz. Because impulsive and caloric testing examine different aspects of SCC function, there is a need to be able to measure anterior and posterior SCC function not just with impulsive but also with caloric tests.

### Evoked potential (VEMP) testing of saccular function

#### Physiological background

Brief (0.1 ms) loud (>95 db above normal hearing level, NHL) monaural clicks<sup>32,33</sup> or short tonebursts<sup>34,35</sup> produce a large (60–300 µV) short latency (8 ms) inhibitory potential in the tonically contracting ipsilateral sternocleidomastoid muscle. The initial positive-negative potential which has peaks at 13 ms ( $p13$ ) and at 23 ms ( $n23$ ) is abolished by selective vestibular neurectomy but not by profound sensorineural hearing loss (Figure 4). In other words, even if the patient cannot hear the clicks there can be nonetheless normal  $p13-n23$  responses. Later

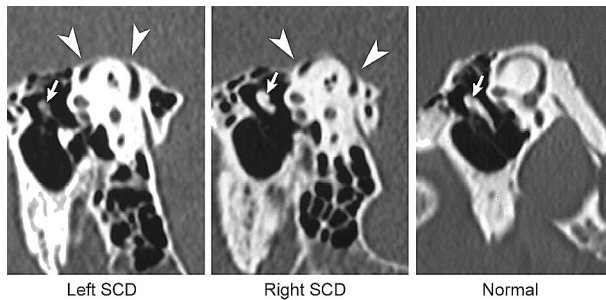


FIG. 5(a)

High-resolution CT scan of the temporal bones reconstructed in the plane of the superior SCCs in a patient with bilateral superior SCC dehiscence (SCD) into the middle cranial fossa. Although there was a bilateral SCD the patient had sound and pressure induced nystagmus only from the right. A normal CT is shown for comparison. (From Halmagyi *et al.*<sup>62</sup>).

components of the evoked response do not share the properties of the *p13–n23* potential and probably do not depend on vestibular afferents. Failure to distinguish between these early and late components could explain why earlier work along similar lines was inconclusive.

For the above reasons we called the *p13–n23* response the vestibular evoked myogenic potential or VEMP. Unlike a neural evoked potential such as the brainstem auditory evoked potential which is generated by the synchronous discharge of nerve cells, the VEMP is generated by synchronous discharges of muscle cells or rather motor units. Being a myogenic potential the VEMP can be 500–1000 times larger than a brainstem potential,<sup>36</sup> 200  $\mu\text{V}$  vs less than 1  $\mu\text{V}$ . Single motor unit recordings in the tonically contracting sternocleidomastoid muscle show a decreased firing rate synchronous with the surface VEMP (see Halmagyi *et al.*<sup>37</sup> – Figure 5).

The amplitude of the VEMP is linearly related to the intensity of the click and to the intensity of sternomastoid activation during the period of averaging, as measured by the mean rectified EMG.<sup>33</sup> Inadequate sternomastoid contraction produces spurious results by reducing the amplitude of the VEMP (e.g. Ferber-Viart *et al.*<sup>38</sup>). A conductive hearing loss abolishes the response by attenuating the intensity of the stimulus (see Halmagyi *et al.*<sup>37</sup>). In such cases the VEMP can be elicited by a tap to the forehead<sup>39</sup> or by a bone-vibrator<sup>40–42</sup> or a DC current applied to the mastoid bone.<sup>43</sup>

There are two main reasons to suppose that the VEMP arises from stimulation of the saccule. Firstly, the saccule is the most sound-sensitive of the vestibular end-organs,<sup>44,45</sup> possibly because it lies just under the stapes footplate,<sup>46,47</sup> in an ideal position to receive the full impact of a loud click delivered to the tympanic membrane. Secondly, not only do click-sensitive neurons in the vestibular nerve respond to tilts,<sup>48,49</sup> most originate in the saccular macula<sup>49,50</sup> and project to the lateral and descending vestibular nuclei, as well as to other structures.<sup>51,52</sup> The VEMP measures vestibular function through what appears to be a disynaptic vestibulo-colic reflex, originating in the saccule and

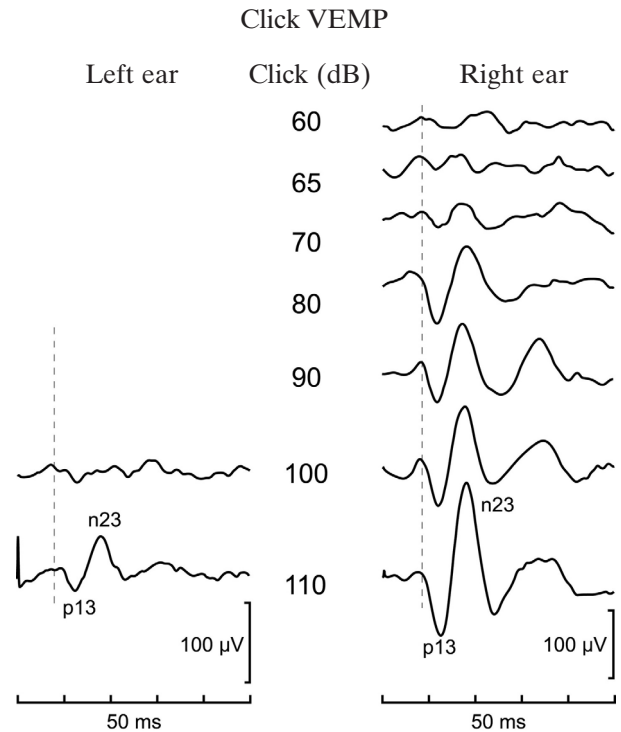


FIG. 5(b)

transmitted via the ipsilateral medial vestibulospinal tract to sternomastoid motoneurons.<sup>53</sup>

Large-amplitude, low-threshold VEMPs from the symptomatic right ear in a patient with bilateral superior semicircular canal dehiscence. There was no response from the left (or right) sternomastoid muscle in response to 70 dB click in the left ear but there was a VEMP (*p13–n23*) of about 40  $\mu\text{V}$  amplitude from the right sternomastoid muscle in response to the same 70 dB click in the right ear. From the left ear the VEMP appeared at a threshold within the normal range: 110 dB. At 110 dB the VEMP from the symptomatic right ear was about twice the amplitude of that from the asymptomatic left ear.

transmitted via the ipsilateral medial vestibulospinal tract to sternomastoid motoneurons.<sup>53</sup>

### Method

Any equipment suitable for recording brainstem auditory potentials will also record VEMPs. Since the amplitude of the VEMP is linearly related both to the intensity of the click and to the intensity of sternomastoid activation during the period of averaging, it is essential to ensure that the sound source is correctly calibrated and that the background level of rectified sternomastoid EMG activation is measured. Two reasons why the VEMPs could be absent or less than 50  $\mu\text{V}$  in amplitude are a conductive hearing loss and inadequate contraction of the sternomastoid muscles.

For clinical testing three superimposed runs of 128 averages for each ear in response to clicks of 100 dB intensity are usually sufficient. The test cannot be done on uncooperative or unconscious patients. The patient lies down and activates the sternomastoid muscles for the averaging period by keeping her or his head raised from a pillow. An alternative method – useful for example in patients with painful neck problems – is to ask the patient to turn the head, which continues to rest on the pillow, to one side. It is then possible to

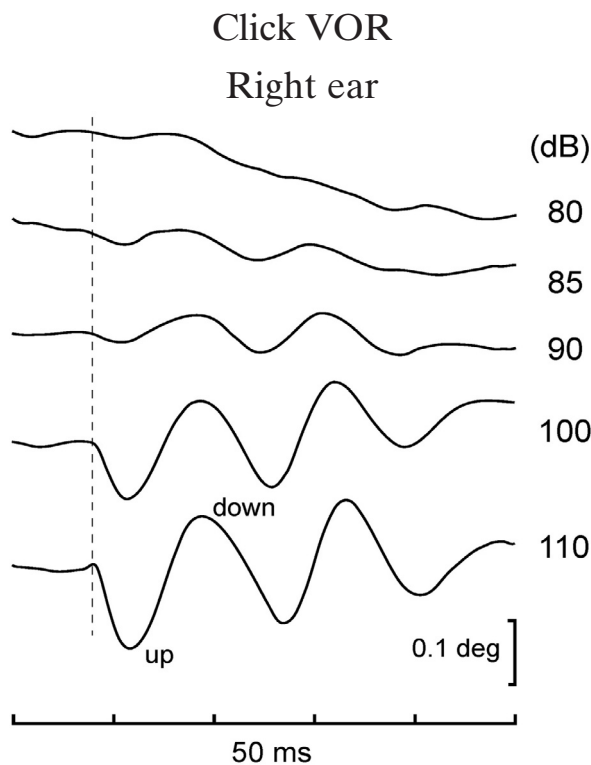


FIG. 5(c)

Click-evoked vestibulo-ocular reflex in a patient with superior semicircular canal dehiscence. Averaged vertical EOG responses of the left eye to 256, 100, 110 dB clicks to the right ear. There is a vertical vestibulo-ocular reflex with a latency to onset (dotted vertical line) of 7.5 ms, a peak-to-peak displacement of about 0.3 deg and a threshold of 85 dB. Normal subjects have responses of only 0.03 deg or less with a threshold of 100 dB or more (from Halmagyi *et al.*<sup>62</sup>).

measure the VEMP in the sternomastoid muscle on the side opposite to the rotation.

The peak-to-peak amplitude of the *p13-n23* potential from each side can be expressed relative to the level of background mean rectified EMG to create a ratio that largely removes the effect of differences in muscle activity. More accurate but more time-consuming correction can be made by making repeated observations with differing levels of tonic activation.<sup>33</sup> One ear is best evaluated by comparing the amplitude of its VEMP with the amplitude of the VEMP from the other ear. We take asymmetry ratios of 2.5 to 1 to be the upper limit of normal – a value similar to that obtained by others.<sup>54</sup> Minor left-right differences in latency commonly occur and might reflect differences in electrode placement over the muscle or differing muscle anatomy.

#### Clinical applications

**Superior semicircular dehiscence.** A third window into the bony labyrinth allows sound to activate the vestibular system in animals<sup>55,56</sup> and in humans.<sup>57–59</sup> Patients with a bony opening or dehiscence from the superior SCC to the middle cranial fossa (Figure 5), not only have sound- and pressure-induced vestibular nystagmus but also have abnormally large, low-threshold VEMPs.<sup>58–61</sup> In normal subjects the VEMP,

just like the acoustic reflex, has a threshold, usually 90–95 dB NHL. In patients with the superior SCC dehiscence the VEMP threshold is about 20 dB lower than in normals (Figure 5) and the VEMP amplitude at the usual 100–105 dB stimulus level can be abnormally large ( $> 300\mu\text{V}$ ). If a VEMP can be consistently elicited at 70 dB NHL this indicates that the patient has a superior SCC dehiscence. Patients with superior SCC dehiscence also have an abnormally large, low-threshold click-evoked VOR.<sup>62,63</sup> (Figure 5).

**Ménière's disease.** VEMPs can be either too small,<sup>64</sup> or too large<sup>65</sup> in Ménière's disease, as well as in delayed endolymphatic hydrops.<sup>66,67</sup> In some cases glycerol dehydration can reduce the size of VEMPs that are too large and increase the size of VEMPs that are too small.<sup>68,69</sup> VEMPs can be used to monitor intratympanic gentamicin therapy in patients with Ménière's disease.<sup>70</sup>

**Vestibular neuro-labyrinthitis and BPPV.** After an attack of vestibular neuritis about one patient in three will develop posterior SCC benign paroxysmal positioning vertigo (BPPV), usually within three months.<sup>71</sup> The patients who develop BPPV after vestibular neuritis have intact VEMPs, whereas those who do not have absent VEMP. In other words an intact VEMP seems to be a prerequisite for the development of post-vestibular neuritis BPPV. The reason for this could be that in those patients who develop post-vestibular neuritis BPPV, only the superior vestibular nerve – which innervates the anterior SCC, lateral SCC and the utricle – is involved. Since the inferior vestibular nerve innervates the posterior SCC and the saccule, the presence of posterior canal BPPV and the preservation of the VEMP imply that the inferior vestibular nerve must have been spared. Support for such an explanation comes from data which shows preservation of posterior SCC impulsive VOR in some patients with vestibular neuritis, patients who presumably have only involvement of the superior vestibular nerve.<sup>16,72</sup> The galvanic-current-evoked VEMPs are generally abolished in those vestibular neuritis patients in whom the click-evoked VEMPs are abolished, indicating that the site of lesion is truly in the vestibular nerve rather than, or as well as, in the labyrinth.<sup>73</sup> The VEMP can recover in patients with vestibular neuritis.<sup>74</sup>

**Vestibular schwannoma.** Although most patients with vestibular schwannoma (acoustic neuroma) present with unilateral hearing loss, some present with vestibular ataxia. This is not entirely surprising since most of these tumours arise not from the acoustic nerve but from one of the vestibular nerves, usually the inferior.<sup>75</sup> The VEMP, which is transmitted via the inferior vestibular nerve, is abnormal – of low amplitude or absent – in perhaps four out of five patients with acoustic neuromas.<sup>76–78</sup> Since the VEMP does not depend on cochlear or on

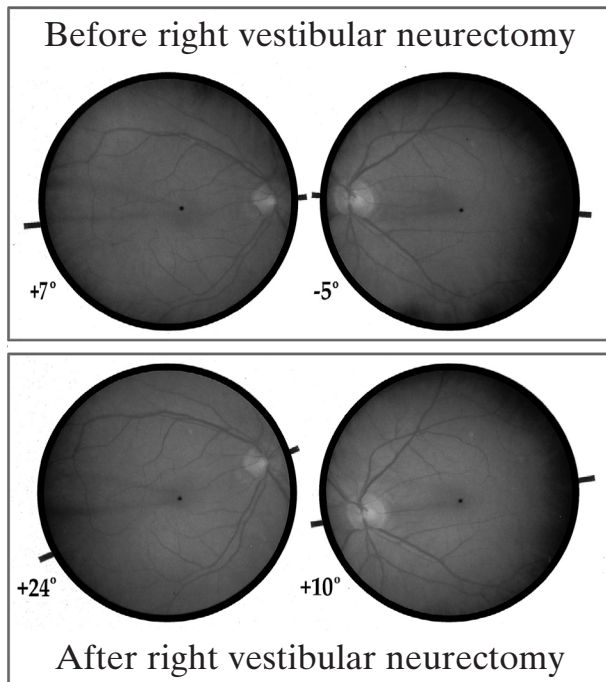


FIG. 6

Fundus photographs of the left and right eye of a patient before (top row) and 1 week after (bottom row) right vestibular neurectomy. After operation there is tonic rightward torsion of the 12 o'clock meridian of each eye toward the patient's right side. The change in torsion angle measures 18 deg in the right eye and 16 deg in the left eye. When the patient was asked to set a luminous bar to the perceived visual horizontal in an otherwise darkened room he set the bar tilted toward his right side by 14.2 deg when viewing with the right eye and 15.1 deg when viewing with the left. (From Curthoys *et al.*<sup>86</sup>).

lateral SCC function it can be abnormal with vestibular schwannomas even when caloric tests are normal or when brainstem auditory evoked potentials cannot be measured because the hearing loss is too severe. The VEMP can be preserved after vestibular schwannoma surgery<sup>79</sup> suggesting preservation of the saccular nerve.

**Multiple sclerosis.** VEMPs can also be abnormal in diseases affecting central vestibular pathways,<sup>80</sup> especially white-matter diseases such as multiple sclerosis,<sup>81,82</sup> which affect the medial vestibulo-spinal tract, the continuation of the medial longitudinal fasciculus, a site commonly involved by demyelination.

#### *Subjective visual horizontal (or vertical) testing of utricular function.*

**Peripheral vestibular lesions.** A normal subject sitting upright in a totally darkened room can accurately align a dimly illuminated bar to within one degree of the true gravitational vertical or horizontal.<sup>83</sup> Friedmann showed that patients with various unilateral vestibular lesions set such a bar so that it was no longer aligned with the gravitational vector but was consistently offset toward the side of the lesion.<sup>84,85</sup> We studied the ability of patients to set

such a light bar to the visual before and after uVD.<sup>83,86</sup> Before uVD, the patients' settings were within the normal range. After uVD, patients invariably offset the gravitationally horizontal bar toward the lesioned side, in some cases by up to 15 degrees, because they saw it as being offset toward the intact side. Although the setting of the bar returned toward the true or gravitational horizontal with time, the setting was still tilted by a mean of four degrees, six months or more after uVD so that a slight ipsilesional offset of the subjective visual horizontal (SVH) is a permanent legacy of uVD. These findings have since then been confirmed by others.<sup>87-92</sup> The offset of the SVH is enhanced by vibration over the ipsilesional mastoid bone or sternomastoid muscle.<sup>93</sup>

What could be the cause of this perceptual error? Is it an offset of the internal representation of the gravitational vertical as a result of the profound asymmetry in otolithic input to the vestibular nuclei that must occur after uVD? Arguing against this mechanism is the observation that despite the uVD, the patients do not feel that their own bodies are tilted, but on the contrary, they feel themselves to be normally upright, even in the dark. In other words although they rotate the bar toward the uVD side, it is not in order to null a perceived tilt of the bar with the body, toward the intact side.

Another possible mechanism of the SVH offset is a torsional deviation of the eyes as a part of the ocular tilt reaction. The ocular tilt reaction is a postural synkinesis consisting of head tilt, conjugate eye torsion and skew deviation, all toward the same side. Some patients develop a florid temporary ipsilesional tonic ocular tilt reaction after a unilateral peripheral vestibular lesion,<sup>94,95</sup> others just a partial one with ocular torsion and skew deviation.<sup>96-98</sup> We therefore measured torsional ocular position as well as SVH before and after uVD<sup>86</sup> and found that after uVD, there is invariably an ipsilesional deviation of torsional ocular position so that the 12 o'clock meridian of each eye is invariably rotated toward the side of the uVD (Figure 6). One week after uVD, there is up to 15 degrees of ipsilesional ocular torsion and there is a close correlation ( $r = 0.95$ ) between the magnitudes of the ocular torsion and the offset of the SVH (Figure 7). Furthermore, the ocular torsion gradually resolves with a temporal pattern identical to that of deviation of the SVH. One month after uVD both the ocular torsion and the tilting of the SVH are at half the one-week value. A slight but statistically significant ocular torsion<sup>86</sup> appears to be a permanent legacy of uVD. It is of interest that after acute uVD in frogs there is head torsion, which follows exactly the same time course as conjugate eye torsion in humans and has been used to monitor drug effects on vestibular compensation.<sup>99</sup>

While it appears that the offset of the SVH is due to ocular torsion, the mechanism of the ocular torsion itself is speculative. The conjugate ocular torsion is part of the ocular tilt reaction,<sup>94-96,98</sup> the triad of conjugate ocular torsion, head tilt and skew deviation that can occur after uVD and could be the equivalent in the otolithic system to the spontaneous nystagmus



in the SCC system. Since the setting of the SVH depends on relative resting activity in the left and right vestibular nuclei, as the patient's brainstem compensates for the uVD, the SVH returns towards normal, although a small offset of the SVH appears to be a permanent stigma of uVD.<sup>86</sup> Therefore, in analogy with spontaneous nystagmus, a return of the SVH toward normal is inevitable whether or not the labyrinth recovers. The evidence that tonic ocular torsion is utricular in origin depends in part on the argument that ocular torsion represents a tonic offset of the dynamic ocular counter-rolling mechanism which appears to be under utricular control.<sup>100,101</sup>

#### *Central vestibular lesions and settings of the subjective visual vertical*

Patients with acute focal brainstem lesions will frequently offset the subjective visual horizontal (SVH) or vertical (SVV).<sup>9,102-104</sup> Patients with lower brainstem lesions involving the vestibular nucleus (e.g. lateral medullary infarcts) offset the SVV towards the side of the lesion, whereas patients with upper brainstem lesions involving the interstitial nucleus (paramedian thalamic infarcts) offset the SVV away from the side of the lesion. In most patients, there is a deviation of torsional ocular position (also called cyclotorsion) in the same direction as the offset of the SVV. The relationship between the SVV and ocular torsion is not as tight as with peripheral lesions but is nonetheless present. In patients with peripheral vestibular lesions both ocular torsion and consequently the SVV are almost the same in the each eye; in contrast there can be significant left eye – right eye differences in both ocular torsion and in the SVV in patients with central vestibular lesions. For example in patients with lateral medullary infarcts, the excyclotorsion of the ipsilesional eye can be much larger than the incyclotorsion of the contralesional eye.

**Clinical significance.** The clinical significance of these findings is that careful standardized measurement of the SVH, using a dim light-bar in an otherwise totally darkened room, can give valuable diagnostic information. In some laboratories patients are asked to set a bar to the SVV, but we find that most patients have a better intuitive understanding of the horizontal than of the vertical and that the settings of the vertical are not the same as of the horizontal.<sup>105</sup> In any case, in order for the test to be valid either the room must be totally dark, apart from the light-bar, or there must be some other way, such as a ganzfeld or a rotating dome, that all visual cues are excluded.<sup>103</sup> A significant offset of the SVH or the SVV indicates acute vestibular hypofunction, possibly otolithic. It indicates either a lesion at the level of the end-organ, vestibular nerve or vestibular nucleus on the side to which the patient offsets the bar, or at a level above vestibular nucleus on the side opposite to which the patient rotates the bar. While the greater the deviation of the SVH or SVV the more acute as well as the more extensive is the lesion, a small permanent deviation of the SVV

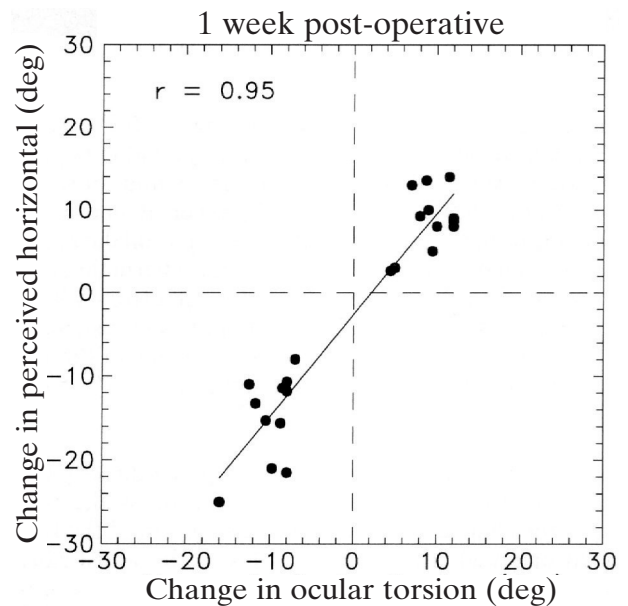


FIG. 7

Ocular torsion and the subjective visual horizontal. The relationship between the change of ocular torsion and the corresponding change in the subjective visual horizontal (SVH) one week after unilateral vestibular neurectomy in 22 patients. The average value of the change in ocular torsion was calculated for each patient and correlated with that patient's average change in the SVH. The correlation ( $r = 0.95$ ) is significant. (From Curthoys *et al.*<sup>86</sup>).

might be a permanent legacy of central and of peripheral vestibular lesions. The SVH test is the single most useful investigation in the acute phase of suspected vestibular neuritis: there is a deviation of the SVH, sometimes by more than 20 degrees, and this is always toward the side of the lesion.<sup>90,91</sup> SVH testing can also be used to follow the progress of vestibular loss and compensation after intratympanic gentamicin treatment for Ménière's disease.<sup>89</sup>

#### **Practical application of the new vestibular function tests**

I have tried to show in this lecture that clinically usable tests have now been developed for each of the vestibular organs. But how practical are they? What staff and what equipment would be required? VEMP testing of saccular function requires no new equipment for any audiology or clinical neurophysiology department capable of testing brainstem auditory evoked potential. The methods, interpretations and potential pitfalls of the VEMP test are clearly described in the literature reviewed here. SVH testing of utricular function requires only a small motor-driven light-bar linked to a computer and a test booth that can be made totally dark. Impulsive testing of individual SCC canal function requires a capital investment of about £50 000, one part-time scientific officer with electrical engineering qualifications to set up and run the equipment and one part-time nurse to test the patients. However, clinicians can learn to carry out the impulsive test at the bedside – it's not as hard as

indirect mirror laryngoscopy – and in most patients with severe unilateral and in all those with bilateral vestibular loss bedside testing can yield much useful information.

### Acknowledgments

The principal members of the team responsible for the work reported here are (in alphabetical order): Swee T. Aw, M.B., B.S., Ph.D., James G. Colebatch, M.B., B.S., Ph.D., F.R.A.C.P., Ian S. Curthoys, Ph.D., Leigh A. McGarvie, B.E., M.Biomed.E., Michael J. Todd, B.E., M.Biomed.E. and Robyn A. Yavor, R.N. Two generations of students, research assistants and clinical collaborators have all made major contributions. The work has been supported by the National Health and Medical Research Council and by the Garnett Passe and Rodney Williams Memorial Foundation. I wish in particular to thank Mr Peter Freeman, F.R.C.S., F.R.A.C.S., Chairman of Trustees of the Foundation, for his visionary guidance and support.

### References

- 1 Passe ERG. Sympathectomy in relation to Ménière's disease, nerve deafness and tinnitus. A report of 110 cases. *Proc Roy Soc Med* 1951;**88**:760–72
- 2 Goldberg JM, Fernandez C. Physiology of peripheral neurons innervating semicircular canals of the squirrel monkey. I. Resting discharge and response to constant angular accelerations. *J Neurophysiol* 1971;**34**:635–60
- 3 Shimazu H, Precht W. Inhibition of central vestibular neurons from the contralateral labyrinth and its mediating pathway. *J Neurophysiol* 1966;**29**:467–92
- 4 Scudder CA, Fuchs AF. Physiological and behavioural identification of vestibular nucleus neurons mediating the horizontal vestibuloocular reflex in trained rhesus monkeys. *J Neurophysiol* 1992;**68**:244–64
- 5 Clendaniel RA, Lasker DM, Minor LB. Differential adaptation of the linear and nonlinear components of the horizontal vestibuloocular reflex in squirrel monkeys. *J Neurophysiol* 2002;**88**:3534–40
- 6 Hullar TE, Minor LB. High-frequency dynamics of regularly discharging canal afferents provide a linear signal for angular vestibuloocular reflexes. *J Neurophysiol* 1999;**82**:2000–5
- 7 Shimazu H, Precht W. Tonic and kinetic responses of cat's vestibular neurons to horizontal angular acceleration. *J Neurophysiol* 1965;**28**:991–1013
- 8 Reisine H, Raphan T. Neural basis for eye velocity generation in the vestibular nuclei of alert monkeys during off-vertical axis rotation. *Exp Brain Res* 1992;**92**:209–26
- 9 Halmagyi GM, Curthoys IS, Cremer PD, Henderson CJ, Todd MJ, Staples MJ, et al. The human horizontal vestibulo-ocular reflex in response to high-acceleration stimulation before and after unilateral vestibular neurectomy. *Exp Brain Res* 1990;**81**:479–90
- 10 Aw ST, Haslwanter T, Halmagyi GM, Curthoys IS, Yavor RA, Todd MJ. Three dimensional vector analysis of the human vestibuloocular reflex in response to high-acceleration head rotations. I Responses in normal subjects. *J Neurophysiol* 1996;**76**:4009–20
- 11 Gilchrist DPD, Curthoys IS, Cartwright AD, Burgess AM, Topple AN, Halmagyi GM. High acceleration impulsive rotations reveal severe long-term deficits of the horizontal vestibulo-ocular reflex in the guinea pig. *Exp Brain Res* 1998;**123**:242–54
- 12 Blanks RHI, Estes MS, Markham CH. Physiologic characteristics of first-order canal neurons in the cat. II. Response to constant accelerations. *J Neurophysiol* 1975;**38**:1250–68
- 13 Lasker DM, Backous DD, Lysakowski A, Davis GL, Minor LB. Horizontal vestibuloocular reflex evoked by high-acceleration rotations in the squirrel monkey. II. Responses after canal plugging. *J Neurophysiol* 1999;**82**:1271–85
- 14 Lasker DM, Hullar TE, Minor LB. Horizontal vestibuloocular reflex evoked by high-acceleration rotations in the squirrel monkey. III. Responses after labyrinthectomy. *J Neurophysiol* 2000;**83**:2482–96
- 15 Cremer PD, Halmagyi GM, Aw ST, Curthoys IS, McGarvie LA, Todd MJ, et al. Semicircular canal plane head impulses detect absent function of individual semicircular canals. *Brain* 1998;**121**:699–716
- 16 Aw ST, Fetter M, Cremer PD, Karlberg M, Halmagyi GM. Individual semicircular canal function in superior and inferior vestibular neuritis. *Neurology* 2001;**57**:768–74
- 17 Carey JP, Minor LB, Peng GC, Della Santina CC, Cremer PD, Haslwanter T. Changes in the three-dimensional angular vestibulo-ocular reflex following intratympanic gentamicin for Ménière's disease. *J Assoc Res Otolaryngol* 2002;**3**:430–43
- 18 Halmagyi GM, Curthoys IS. A clinical sign of canal paresis. *Arch Neurol* 1988;**45**:737–9
- 19 Ewald EJR. *Physiologische Untersuchungen über das Endorgan des Nervus Octavus*. Wiesbaden: Bergmann, 1892
- 20 Pohl DV. Surgical procedures for benign positional vertigo. In: Baloh RW, Halmagyi GM, eds. *Disorders of the Vestibular System*. New York: Oxford University Press, 1996; 563–74
- 21 Agrawal SK, Parnes LS. Human experience with canal plugging. *Ann NY Acad Sci* 2001;**942**:300–5
- 22 Gilchrist DP, Curthoys IS, Burgess AM, Cartwright AD, Jinnouchi K, MacDougall HG, et al. Semicircular canal occlusion causes permanent VOR changes. *Neuroreport* 2000;**11**:2527–31
- 23 Rabbitt RD, Boyle R, Highstein SM. Influence of surgical plugging on horizontal semicircular canal mechanics and afferent response dynamics. *J Neurophysiol* 1999;**82**:1033–53
- 24 Aw ST, Halmagyi GM, Pohl DV, Curthoys IS, Yavor RA, Todd MJ. Compensation of the human vertical vestibulo-ocular reflex following occlusion of one vertical semicircular canal is incomplete. *Exp Brain Res* 1995;**103**:471–5
- 25 Hess BJ, Lysakowski A, Minor LB, Angelaki DE. Central versus peripheral origin of vestibuloocular reflex recovery following semicircular canal plugging in rhesus monkeys. *J Neurophysiol* 2000;**84**:3078–82
- 26 Tabak S, Collewijn H, Boumans LJJM, Vandersteen J. Gain and delay of human vestibulo-ocular reflexes to oscillation and steps of the head by a reactive torque helmet. I. Normal subjects. *Acta Otolaryngol (Stockh)* 1997;**117**:785–95
- 27 Tabak S, Collewijn H, Boumans LJJM, Vandersteen J. Gain and delay of human vestibulo-ocular reflexes to oscillation and steps of the head by a reactive torque helmet. II. Vestibular-deficient subjects. *Acta Otolaryngol (Stockh)* 1997;**117**:796–809
- 28 Halmagyi GM. Vestibular insufficiency following unilateral vestibular deafferentation. *Aust J Otolaryngol* 1994;**1**:510–2
- 29 Reid CB, Eisenberg R, Halmagyi GM, Fagan PA. The outcome of vestibular nerve section for intractable vertigo: the patients' point of view. *Laryngoscope* 1996;**106**:1553–6
- 30 Della Santina CC, Cremer PD, Carey JP, Minor LB. Comparison of head thrust test with head autorotation test reveals that the vestibulo-ocular reflex is enhanced during voluntary head movements. *Arch Otolaryngol Head Neck Surg* 2002;**128**:1044–54
- 31 Schmid-Priscoveanu A, Böhmer A, Obzina H, Straumann D. Caloric and search-coil head-impulse testing in patients after vestibular neuritis. *J Assoc Res Otolaryngol* 2001;**2**:72–8
- 32 Colebatch JG, Halmagyi GM. Vestibular evoked potentials in human neck muscles before and after unilateral vestibular deafferentation. *Neurology* 1992;**42**:1635–6

- 33 Colebatch JG, Halmagyi GM, Skuse NF. Myogenic potentials generated by a click-evoked vestibulocollic reflex. *J Neurol Neurosurg Psychiatry* 1994;**57**:190–7
- 34 Murofushi T, Matsuzaki M, Wu CH. Short tone burst-evoked myogenic potentials on the sternocleidomastoid muscle: are these potentials also of vestibular origin? *Arch Otolaryngol Head Neck Surg* 1999;**125**:660–4
- 35 Welgampola MS, Colebatch JG. Characteristics of tone burst-evoked myogenic potentials in the sternocleidomastoid muscles. *Otol Neurotol* 2001;**22**:796–802
- 36 Todd N. Evidence for a behavioral significance of saccular acoustic sensitivity in humans. *J Acoust Soc Am* 2001;**110**:380–90
- 37 Halmagyi, GM, Curthoys IS, Colebatch JG. New tests of vestibular function. *Baillière's Clin Neurol* 1994;**3**:485–500
- 38 Ferber-Viart C, Dubreuil C, Duclaux R. Vestibular evoked myogenic potentials in humans: a review. *Acta Otolaryngol (Stockh)* 1999;**119**:6–15
- 39 Halmagyi GM, Yavor RA, Colebatch JG. Tapping the head activates the vestibular system: a new use for the clinical reflex hammer. *Neurology* 1995;**45**:1927–9
- 40 Shekholeslami K, Murofushi T, Kermany MH, Kaga K. Bone-conducted evoked myogenic potentials from the sternocleidomastoid muscle. *Acta Otolaryngol (Stockh)* 2000;**120**:731–4
- 41 Shekholeslami K, Habiby Kermany M, Kaga K. Bone-conducted vestibular evoked myogenic potentials in patients with congenital atresia of the external auditory canal. *Int J Pediatr Otorhinolaryngol* 2001;**57**:25–9
- 42 Welgampola MS, Rosengren SM, Halmagyi GM, Colebatch JG. Vestibular activation by bone-conducted sound. *J Neurol Neurosurg Psychiatry* 2003;**74**:771–8
- 43 Watson SR, Fagan P, Colebatch JG. Galvanic stimulation evokes short-latency EMG responses in sternocleidomastoid which are abolished by selective vestibular nerve section. *Electroencephalogr Clin Neurophysiol* 1998;**109**:471–74
- 44 Young ED, Fernandez C, Goldberg JM. Responses of squirrel monkey vestibular neurons to audio-frequency sound and head vibration. *Acta Otolaryngol* 1977;**84**:352–60
- 45 Didier A, Cazals Y. Acoustic responses recorded from the saccular bundle on the eighth nerve of the guinea pig. *Hear Res* 1989;**37**:123–8
- 46 Anson BJ, Donaldson JA. *Surgical anatomy of the Temporal Bone and Ear*. Philadelphia: Saunders, 1973; 285
- 47 Backous DD, Minor LB, Aboujaoude ES, Nager GT. Relationship of the utriculus and sacculus to the stapes footplate: anatomic implications for sound-and/or pressure-induced otolith activation. *Ann Otol Rhinol Laryngol* 1999;**108**:548–53
- 48 Murofushi T, Curthoys IS, Topple AN, Colebatch JG, Halmagyi GM. Responses of guinea pig primary vestibular neurons to clicks. *Exp Brain Res* 1995;**103**:174–8
- 49 Murofushi T, Curthoys IS. Physiological and anatomical study of click-sensitive primary vestibular afferents in the guinea-pig. *Acta Otolaryngol (Stockh)* 1997;**117**:66–72
- 50 McCue MP, Guinan JJ. Sound-evoked activity in primary afferent neurons of the mammalian vestibular system. *Am J Otol* 1997;**18**:355–60
- 51 Kevetter GA, Perachio AA. Distribution of vestibular afferents that innervate the sacculus and posterior canal in the gerbil. *J Comp Neurol* 1986;**254**:410–24
- 52 Murofushi T, Curthoys IS, Gilchrist DP. Response of guinea pig vestibular nucleus neurons to clicks. *Exp Brain Res* 1996;**111**:149–52
- 53 Kushiro K, Zakir M, Ogawa Y, Sato H, Uchino Y. Saccular and utricular inputs to sternocleidomastoid motoneurons of decerebrate cats. *Exp Brain Res* 1999;**126**:410–6
- 54 Brantberg K, Fransson PA. Symmetry measures of vestibular evoked myogenic potentials using objective detection criteria. *Scand Audiol* 2001;**30**:189–96
- 55 Tullio P. *Das Ohr und die Entstehung der Sprache und Schrift*. Berlin: Urban and Schwarzenberg, 1929
- 56 Dohlman G, Money K. Experiments on the Tullio vestibular fistula reaction. *Acta Otolaryngol (Stockh)* 1963;**56**:271–8
- 57 Minor LB, Solomon D, Zinreich JS, Zee DS. Tullio's phenomenon due to dehiscence of the superior semicircular canal. *Arch Otolaryngol Head Neck Surg* 1998;**124**:249–58
- 58 Watson SR, Halmagyi GM, Colebatch JG. Vestibular hypersensitivity to sound (Tullio phenomenon): structural and functional assessment. *Neurology* 2000;**54**:722–8
- 59 Brantberg K, Bergenius J, Mendel L, Witt H, Tribukait A, Ygge J. Symptoms, findings and treatment in patients with dehiscence of the superior semicircular canal. *Acta Otolaryngol (Stockh)* 2001;**121**:68–75
- 60 Colebatch JG, Day BL, Bronstein AM, Davies RA, Gresty MA, Luxon LM, et al. Vestibular hypersensitivity to clicks is characteristic of the Tullio phenomenon. *J Neurol Neurosurg Psychiatry* 1998;**65**:670–8
- 61 Streubel S-O, Cremer PD, Carey JP, Weg N, Minor LB. Vestibular-evoked myogenic potentials in the diagnosis of superior semicircular canal dehiscence. *Acta Otolaryngol Suppl (Stockh)* 2001;**545**:41–9
- 62 Halmagyi GM, McGarvie LA, Aw ST, Yavor RA, Todd MJ. The click-evoked vestibulo-ocular reflex in superior semicircular canal dehiscence. *Neurology* 2003;**60**:1172–5
- 63 Halmagyi GM, Aw ST, McGarvie LA, Todd MJ, Bradshaw A, Yavor RA, et al. Superior semicircular canal dehiscence simulating otosclerosis. *J Laryngol Otol* 2003;**117**:553–7
- 64 de Waele C, Huy PT, Diard JP, Freyss G, Vidal PP. Saccular dysfunction in Ménière's disease. *Am J Otol* 1999;**20**:223–32
- 65 Young YH, Wu CC, Wu CH. Augmentation of vestibular evoked myogenic potentials: an indication for distended saccular hydrops. *Laryngoscope* 2002;**112**:509–12
- 66 Young YH, Huang TW, Cheng PW. Vestibular evoked myogenic potentials in delayed endolymphatic hydrops. *Laryngoscope* 2002;**112**:1623–6
- 67 Ohki M, Matsuzaki M, Sugawara K, Murofushi T. Vestibular evoked myogenic potentials in ipsilateral delayed endolymphatic hydrops. *ORL* 2002;**64**:424–8
- 68 Murofushi T, Matsuzaki M, Takegoshi H. Glycerol affects vestibular evoked myogenic potentials in Ménière's disease. *Auris Nasus Larynx* 2001;**28**:205–8
- 69 Seo T, Node M, Yukimasa A, Sakagami M. Furosemide loading vestibular evoked myogenic potential for unilateral Ménière's disease. *Otol Neurotol* 2003;**24**:283–8
- 70 de Waele C, Meguenni R, Freyss G, Zamith F, Bellalimat N, Vidal PP, et al. Intratympanic gentamicin injections for Meniere disease: vestibular hair cell impairment and regeneration. *Neurology* 2002;**59**:1442–4
- 71 Murofushi T, Halmagyi GM, Yavor RA, Colebatch JG. Vestibular evoked myogenic potentials in vestibular neuritis: an indicator of inferior vestibular nerve involvement. *Arch Otolaryngol Head Neck Surg* 1996;**122**:845–8
- 72 Fetter M, Dichgans J. Vestibular neuritis spares the inferior division of the vestibular nerve. *Brain* 1996;**119**:755–63
- 73 Murofushi T, Takegoshi H, Ohki M, Ozeki H. Galvanic-evoked myogenic responses in patients with an absence of click-evoked vestibulo-collic reflexes. *Clin Neurophysiol* 2002;**113**:305–9
- 74 Ochi K, Ohashi T, Watanabe S. Vestibular-evoked myogenic potential in patients with unilateral vestibular neuritis: abnormal VEMP and its recovery. *J Laryngol Otol* 2003;**117**:104–8
- 75 Komatsuzaki A, Tsunoda A. Nerve origin of the acoustic neuroma. *J Laryngol Otol* 2001;**115**:376–9
- 76 Murofushi T, Matsuzaki M, Mizuno M. Vestibular evoked myogenic potentials in patients with acoustic neuromas. *Arch Otolaryngol Head Neck Surg* 1998;**124**:509–12
- 77 Tsutsumi T, Tsunoda A, Noguchi Y, Komatsuzaki A. Prediction of the nerves of origin of vestibular schwannomas with vestibular evoked myogenic potentials. *Am J Otol* 2000;**21**:712–5
- 78 Murofushi T, Shimizu K, Takegoshi H, Cheng PW. Diagnostic value of prolonged latencies in the vestibular evoked myogenic potential. *Arch Otolaryngol Head Neck Surg* 2001;**127**:1069–72

- 79 Magliulo G, Gagliardi M, Appiani GC, D'Amico R. Preservation of the saccular nerve and of the vestibular evoked myogenic potential during vestibular schwannoma surgery. *Otol Neurotol* 2003;**24**:308–11
- 80 Heide G, Freitag S, Wollenberg I, Iro H, Schimrigk K, Dillmann U. Click evoked myogenic potentials in the differential diagnosis of acute vertigo. *J Neurol Neurosurg Psychiatry* 1999;**66**:787–90
- 81 Shimizu K, Murofushi T, Sakurai M, Halmagyi M. Vestibular evoked myogenic potentials in multiple sclerosis. *J Neurol Neurosurg Psychiatry* 2000;**69**:276–7
- 82 Versino M, Colnaghi S, Callieco R, Bergamaschi R, Romani A, Cosi V. Vestibular evoked myogenic potentials in multiple sclerosis patients. *Clin Neurophysiol* 2002; **113**:1464–9
- 83 Dai MJ, Curthoys IS, Halmagyi GM. Perception of linear acceleration before and after unilateral vestibular neurectomy. *Experimental Brain Research* 1989;**77**:315–28
- 84 Friedmann G. The judgement of the visual vertical and horizontal with peripheral and central vestibular lesions. *Brain* 1970;**93**:313–28
- 85 Friedmann G. The influence of unilateral labyrinthectomy on orientation in space. *Acta Otolaryngol* 1971; **71**:289–98
- 86 Curthoys IS, Dai MJ, Halmagyi GM. Human torsional ocular position before and after unilateral vestibular neurectomy. *Experimental Brain Research* 1991;**85**:218–25
- 87 Böhmer A, Rickenmann J. The subjective visual vertical as a clinical parameter of vestibular function in peripheral vestibular diseases. *J Vestib Res* 1995;**5**:35–45
- 88 Tabak S, Collewyn H, Boumans LJJM. Deviation of the subjective vertical in long-standing unilateral vestibular loss. *Acta Otolaryngol (Stockh)* 1997;**117**:1–6
- 89 Tribukait A, Bergenius J, Brantberg K. Subjective visual horizontal during follow-up after unilateral vestibular deafferentation with gentamicin. *Acta Otolaryngol (Stockh)* 1998;**118**:479–87
- 90 Vibert D, Häusler R, Safran AB. Subjective visual vertical in unilateral peripheral vestibular diseases. *J Vestib Res* 1999;**9**:145–52
- 91 Vibert D, Häusler R. Long-term evolution of subjective visual vertical after vestibular neurectomy and labyrinthectomy. *Acta Otolaryngol* 2000;**120**:620–2
- 92 Goto F, Kobayashi H, Saito A, Hayashi Y, Higashino K, Kunihiro T, et al. Compensatory changes in static and dynamic subjective visual vertical in patients following vestibular schwannoma surgery. *Auris Nasus Larynx* 2003; **30**:29–33
- 93 Karlberg M, Aw ST, Halmagyi GM, Black RA. Vibration-induced shift of the subjective visual horizontal: a sign of unilateral vestibular deficit. *Arch Otolaryngol Head Neck Surg* 2002;**128**:21–7
- 94 Halmagyi GM, Gresty MA, Gibson WPR. Ocular tilt reaction due to peripheral vestibular lesion. *Ann Neurol* 1979;**6**:80–3
- 95 Vibert D, Häusler R, Safran AB, Koerner F. Ocular tilt reaction associated in sudden idiopathic unilateral peripheral cochleovestibular loss. *ORL* 1995;**57**:310–5
- 96 Safran AB, Vibert D, Issoua D, Häusler R. Skew deviation after vestibular neuritis. *Am J Ophthalmol* 1994; **118**:238–45
- 97 Vibert D, Häusler R, Safran AB, Koerner F. Diplopia from skew deviation in unilateral peripheral vestibular lesions. *Acta Otolaryngol* 1996;**116**:170–6
- 98 Riordan-Eva P, Harcourt JP, Faldon M, Brookes GB, Gresty MA. Skew deviation following vestibular nerve surgery. *Ann Neurol* 1997;**41**:94–9
- 99 Flohr H, Abeln W, Luneburg U. Neurotransmitter and neuromodulator systems involved in vestibular compensation. *Rev Oculomot Res* 1985;**1**:269–77
- 100 Diamond SG, Markham CH. Ocular counterrolling as an indicator of vestibular otolith function. *Neurology* 1983;**33**:1460–9
- 101 MacDougall HG, Curthoys IS, Betts GA, Burgess AM, Halmagyi GM. Human ocular counterrolling during roll-tilt and centrifugation. *Ann NY Acad Sci* 1999;**871**:173–80
- 102 Dieterich M, Brandt T. Wallenberg's syndrome: lateropulsion, cyclorotation, and subjective visual vertical in thirty-six patients. *Ann Neurol* 1992;**31**:399–408
- 103 Dieterich M, Brandt T. Ocular torsion and tilt of the subjective visual vertical are sensitive brainstem signs. *Ann Neurol* 1993;**33**:292–9
- 104 Serra A, Derwenskus J, Downey DL, Leigh RJ. Role of eye movement examination and subjective visual vertical in clinical evaluation of multiple sclerosis. *J Neurol* 2003; **250**:569–75
- 105 Betts GA, Curthoys IS. Visually perceived vertical and visually perceived horizontal are not orthogonal. *Vision Res* 1998;**38**:1989–99
- 106 Halmagyi GM, Cremer PD. Assessment and treatment of dizziness. *J Neurol Neurosurg Psychiatry* 2000;**68**:129–34

Address for correspondence:

Dr G. M. Halmagyi,  
Neurology Department,  
Royal Prince Alfred Hospital,  
Camperdown,  
Sydney,  
NSW 2050,  
Australia.

Fax: + 61 2 9515 8347

Email: michael@icn.usyd.edu.au

---

Dr G. M. Halmagyi takes responsibility for the integrity of the content of the paper.

Competing interests: None declared

---