

# *Seco-limonoid* derived from *Raputia heptaphylla* promotes the control of cutaneous leishmaniasis in hamsters (*Mesocricetus auratus*)

DIANA GRANADOS-FALLA<sup>1†</sup>, ANGELA GOMEZ-GALINDO<sup>1†</sup>, ALEJANDRO DAZA<sup>2</sup>, SARA ROBLEDO<sup>2</sup>, CARLOS COY-BARRERA<sup>3</sup>, LUIS CUCA<sup>3</sup> and GABRIELA DELGADO<sup>1\*</sup>

<sup>1</sup> Research Group in Immunotoxicology, Faculty of Sciences, Universidad Nacional de Colombia, Bogota 11001, Colombia

<sup>2</sup> PECET – Medical Research Institute, School of Medicine, Universidad de Antioquia, Medellin 50010, Colombia

<sup>3</sup> Research Laboratory of Natural Plant Products, Faculty of Sciences, Universidad Nacional de Colombia, Bogota 11001, Colombia

(Received 7 September 2015; revised 10 November 2015; accepted 13 November 2015; first published online 23 December 2015)

## SUMMARY

The rational search of novel bioactive molecules against pathogens with immunomodulatory activity is presently one of the most significant approaches to discover and design new therapeutic agents for effective control of infectious diseases, such as the infection caused by *Leishmania* parasites. In the present study, we evaluated the therapeutic efficacy of the recently characterized immunomodulatory compound 11 $\alpha$ ,19 $\beta$ -dihydroxy-7-acetoxy-7-deoxoichangin, a *seco*-limonoid derived from the bark of *Raputia heptaphylla* (Pittier) using: (1) peritoneal macrophages and (2) *Mesocricetus auratus* hamsters infected with *Leishmania (V.) panamensis* and *Leishmania (L.) amazonensis*. We observed the ability of this *seco*-limonoid to induce the effective control of the parasite either *in vitro* [determining an effective concentration 50 (EC<sub>50</sub>) of 59  $\mu$ M at the infection model] and *in vivo* (inducing clinical improvement or even cure in infected animals treated compared with the groups of animals treated with vehicle solution or meglumine antimoniate).

Key words: *Leishmania*, treatment, natural products, *seco*-limonoid, hamsters.

## INTRODUCTION

*Leishmania* species are responsible for several clinical manifestations collectively known as leishmaniasis, a disease transmitted by hematophagous mosquitoes belonging to the genus *Lutzomyia* and *Phlebotomus*, and which is endemic in at least 98 countries according to reports of the World Health Organization (WHO) (WHO, 2010; Alvar *et al.* 2012).

Although pentavalent antimony salts are the drugs of first choice for the treatment of leishmaniasis, some drugs have been incorporated in the last years that may facilitate the management of patients in endemic areas with reports of drug-resistance parasites to conventional treatment (amphotericin B or miltefosine) (Berman *et al.* 2006; Santos *et al.* 2008; Clem, 2010; Dorlo *et al.* 2012), also new strategies have been introduced which allow the delivery control of the mentioned drugs or the combined therapy (liposomal amphotericin or combination of pentavalent antimony salts with imiquimod, respectively) (WHO, 2005; Meheus *et al.* 2010). However, therapy for controlling leishmaniasis is still far from being ideal due to multiple factors

still unsolved (Delgado *et al.* 1999; TDR, 2004), which makes necessary the development of alternative therapies for a more secure and adequate control of this disease.

In this sense, the rational study of bioactive molecules with antileishmanial and immunomodulatory activity (taking into account the importance of immune system in the natural control of the infection) (Awasthi *et al.* 2004; Mansueto *et al.* 2007; Mougneau *et al.* 2011), has become a remarkable approach, whose use is suggested by the WHO as one of the alternatives available to overcome this problem (TDR, 2004; El-On, 2009; Nylen and Gautam, 2010).

Previous studies has shown the *in vitro* efficacy of the *seco*-limonoid compound 11 $\alpha$ ,19 $\beta$ -dihydroxy-7-acetoxy-7-deoxoichangin using the murine macrophage cell line J774.2 as target cell of *in vitro* infection (Coy Barrera *et al.* 2011), accompanied by an immunomodulatory effect on infected phagocytic cells (murine macrophage and human dendritic cells), which appears to lead to the 'reactivation' of the microbicidal capability of infected cells (Granados-Falla *et al.* 2013). In this sense, other studies support the need to confirm the data obtained in *in vitro* assays by limonoid compounds (as Gedunin, 7-deacetylgedunin and 7-oxo-7-deacetylgedunin) for which over the past years, its potential antiparasitic activity have been assessed against species belonging to the genus *Plasmodium*,

\* Corresponding author: Pharmacy Department, Faculty of Sciences, Universidad Nacional de Colombia, Kr 45 # 26-85, Bogota, Colombia. E-mail: [lgdelgadam@unal.edu.co](mailto:lgdelgadam@unal.edu.co).

† These authors contributed equally to this work.

*Trypanosoma* and *Leishmania* (Rosas, 2005; Hay *et al.* 2007; Batista *et al.* 2009; Githua *et al.* 2010).

In the present study the ability of the compound 11 $\alpha$ ,19 $\beta$ -dihydroxy-7-acetoxy-7-deoxoichangin to induce the control of the *in vitro* and *in vivo* infection was tested, by using peritoneal macrophages from hamsters (PMH) and *Mesocricetus auratus* hamsters infected with *Leishmania (V.) panamensis* and *Leishmania (L.) amazonensis*.

#### MATERIALS AND METHODS

##### *Natural compound derived from the bark of Raputia heptaphylla*

The compound 11 $\alpha$ ,19 $\beta$ -dihydroxy-7-acetoxy-7-deoxoichangin was obtained from the bark of *R. heptaphylla* Pittier [the plant material was collected in Alban – Colombia (coordinates: 4°52'31"N 74°26'27"W, elevation 2180 m a.s.l.) by the Biologist Zaleth Cordero], reposing a specimen of this species in the National Herbarium of Colombia – Institute of Natural Sciences of the Universidad Nacional de Colombia under the code COL511102.

Briefly, the dried plant material of the bark was subjected to extraction by percolation with 96% ethanol at room temperature, and the organic solvent was removed by distillation under reduced pressure in order to obtain the crude ethanolic extract, which subsequently was subjected to extraction, using chromatographic methods.

##### *Animals*

For obtaining peritoneal macrophages (*in vitro* phase) and conducting the tests of the evaluation of the therapeutic efficacy of compound administered by intraleisional injection (*in vivo* phase), golden hamsters (*M. auratus*) of 8–12 weeks old (males and females) were used, with weights ranging from 100 to 160 g.

All the animals used in this study were obtained at the National Institute of Health of Colombia INS or belonged to the colony maintained in the animal facilities specific pathogen free of the PECET group at the Universidad de Antioquia.

Animals were kept under the recommended conditions by the Guide for the Care and Use of Laboratory Animals for the National Research Council of USA for temperature, light, and macro- and micro-environment humidity with a diet based on concentrate Rodentina<sup>®</sup> (Purina Co, Colombia) and water *ad libitum*.

##### *Chemical reagents*

Ketamine (Imalgene 1000<sup>®</sup>) and xylazine (Rompun<sup>®</sup> 2%) intramuscularly at recommended doses were used to perform the infection and animal identification protocol (Flecknell, 1996). Sodium thioglycolate at 0.4% in saline solution (Sigma Chemical Co, USA)

inoculated at the right lower quadrant was used for obtaining peritoneal macrophages derived from golden hamsters and for the euthanasia protocol, sodium pentobarbital was administered intracardially in unconscious animals at the recommended doses given by Guide euthanasia of American Veterinary Medical Association (AVMA, 2007).

##### *Peritoneal macrophages derived from M. auratus hamsters*

Isolation of peritoneal macrophages derived from *M. auratus* hamsters ( $n = 12$ ) (PMH) was conducted by the inoculation of a sterile solution of sodium thioglycollate at 0.4% (Sigma Chemical Co, USA) at the right lower quadrant of the hamsters using a sterile plastic syringe with needle 25 G (Becton Dickinson, USA). After inoculation for 3 days, the animals were observed to evaluate the grade of peritonitis through abdominal palpation, time after which the animals were sacrificed. It should be noted that for the animals that showed symptoms of pain before completing the incubation time were sacrificed for ethical reasons.

After sacrifice, the abdominal skin was removed with anatomical dissection tweezers and blunt scissors, and was inoculated 10 mL of RPMI 1640 medium (Life Technologies Corporation, USA) in peritoneal cavity. Thereafter, the incision was made in the alba line and the peritoneal cavity was exposed for taking the medium present in the cavity, which contained the peritoneal macrophages to be employed in *in vitro* infection assays (Bey and Harington, 1971).

##### *Cell culture*

The culture of PMH as well as the promastigotes of *L. (V.) panamensis* transfected with and without a plasmid that coded for the expression of the green fluorescent protein (GFP) (MHOM/88/CO/UA140irGFP and MHOM/88CO/UA140, respectively) and *L. (L.) amazonensis* (IFLA/BR/67/PH8) was performed using the culture medium RPMI-1640 (Life Technologies Corporation, USA) supplemented with 2 mM L-glutamine (Life Technologies Corporation, USA), 1% non-essential amino acids, 1000 U mL<sup>-1</sup> penicillin, 0.1 mg mL<sup>-1</sup> streptomycin, 0.25  $\mu$ g mL<sup>-1</sup> of amphotericin B (Sigma Chemical Co, USA), 24 mM sodium bicarbonate (Sigma Chemical Co, USA), 25 mM HEPES (Life Technologies Corporation, USA) and 10% of fetal bovine serum (Microgen, Colombia).

PMH were incubated at 36–37 °C in an atmosphere of 5% CO<sub>2</sub> and 90% humidity while the promastigotes of *L. (V.) panamensis* and *L. (L.) amazonensis* were cultured at 26 °C.

##### *Cytotoxic activity*

The *seco*-limonoid cytotoxicity was evaluated by its ability to induce any damage on PMH using the

test of metabolism Resazurin (O'Brien *et al.* 2000). For this, PMH were cultured in the presence of different concentrations of compound 11 $\alpha$ ,19 $\beta$ -dihydroxy-7-acetoxy-7-deoxoichangin, and after 72 h of exposure the percentage of viable cells present in each well were determined.

Cells ( $5 \times 10^4$ ) were seeded in culture dishes of 96 wells (Techno Plastic Products – TPP, Switzerland) and exposed for 72 h at 36–37 °C in an atmosphere of 5% CO<sub>2</sub> and 90% humidity at different concentrations of the compound (consecutive 1:4 dilutions). Cells exposed to the solubilization reagent [dimethylsulfoxide (DMSO)] and to the extraction solvents (ethanol, chloroform), as also cells cultured in the absence of the compound were used as controls. After this period, 100  $\mu$ L per well of a resazurin solution were added to the final concentration of 44  $\mu$ M (Sigma-Aldrich, USA) and after 4 h of incubation with the solution of resazurin, the culture plates were read in a spectrofluorometer at 535 nm excitation and 590 nm emission (Tecan, Genios). The cytotoxic concentration 50 (CC<sub>50</sub>) was determined using the statistical software package GraphPad Prism version 5.00 Demo (GraphPad Software, USA) by the application of a nonlinear regression where the data were adjusted with a sigmoidal model of maximum response variable slope, registering the normalized percentage of viability of the cells exposed to the treatment *vs* the logarithm of the concentrations evaluated. Each assay was performed in duplicate in at least three independent experiments.

#### *In vitro* evaluation of the antileishmanial activity

The antileishmanial activity against intracellular form of the pathogen was determined through parasite infection of PMH. In brief, PMH were infected with promastigotes of *L. (V.) panamensis* expressing GFP (strain MHOM/88/CO/UA140irGFP) (Pulido *et al.* 2012) in a 1:40–1:50 ratio for 6 h, time after which, the non-internalized parasites were removed through gentle washing with RPMI-1640 (Life Technologies Corporation, USA).

Once the infection was established, the cells were exposed to several concentrations of the compound (performing consecutive 1:4 dilutions) for 48 h at 36 °C in an atmosphere of 5% CO<sub>2</sub>. Finally, once the incubation period was completed, cells were transferred to cytometry tubes for the quantification of the percentage of infected cells by flow cytometry (FacsCanto II – Becton Dickinson, USA). Thus, the reduction in the percentage of infected cells was the parameter considered to relate to a potential antiparasitic activity. Infected cells treated with meglumine antimoniate (Albiventrix<sup>®</sup>, kindly donated by Arbofarma, Colombia) were used as positive controls of resolution of *in vitro* infection, while infected cells cultured in the absence of the compound were

used as negative control (complete RPMI-1640 with DMSO at 0.2%).

With these data, we obtained the effective concentration<sub>50</sub> (EC<sub>50</sub>) which corresponds to the concentration that reduces the parasitic load by 50%.

The division of the values obtained on CC<sub>50</sub> and the EC<sub>50</sub> (CC<sub>50</sub>/EC<sub>50</sub>), corresponds to a parameter related to the selectivity and safety of the tested molecule, named here as selectivity index (SI). The antileishmanial activity was evaluated in at least five independent experiments.

#### *Experimental infection with L. (V.) panamensis and L. (L.) amazonensis in golden Syrian hamsters*

Promastigotes of *L. (V.) panamensis* (MHOM/88/CO/UA140) ( $3 \times 10^6$ ) or promastigotes of *L. (L.) amazonensis* (IFLA/BR/67/PH8) ( $10$  or  $15 \times 10^6$ , male or female, respectively) in stationary phase (in sterile saline solution), were inoculated at the lumbosacral region of each animal with a sterile syringe (Becton Dickinson, USA) at a volume of 100  $\mu$ L at intradermal level (2–3 cm the base of the tail).

#### *Treatment regimen*

The start of treatment (TD0) was performed only after the skin lesions in the infected animals achieved a diameter greater than or equal to 8  $\times$  8 mm (approximately 4–5 weeks post infection). The dose used for the treatments was calculated based on the results obtained in the *in vitro* assays, and all the treatments were started simultaneously.

The administration of each treatment was made using a 1 mL syringe with 26–27 G needle (Becton Dickinson, USA) by intramuscular injection [for meglumine antimoniate (groups A and D) or intraleisional for groups treated with vehicle solution and the compound (groups C, B, E and F)].

Six (6) experimental groups were designed with the aim to evaluate the antileishmanial activity on infection model hamster *M. auratus* [three (A, B and C) for the evaluation with *L. (V.) panamensis* ( $n = 12$ ) and three (D, E and F) for infection with *L. (L.) amazonensis* ( $n = 24$ )]. The experimental groups were:

- (A) Infected animals with *L. (V.) panamensis* and treated with meglumine antimoniate at 60 mg kg<sup>-1</sup> day<sup>-1</sup> for 20 days (twenty applications) ( $n = 2$ ).
- (B) Infected animals with *L. (V.) panamensis* and treated with vehicle solution in which the compound was solubilized (DMSO at 1% in physiological saline solution) (five applications) ( $n = 5$ ).
- (C) Infected animals with *L. (V.) panamensis* and treated with the compound 11 $\alpha$ ,19 $\beta$ -dihydroxy-7-acetoxy-7-deoxoichangin at dose of 8.7 mg kg administered 2 intermediate days for 2 weeks (five applications) ( $n = 5$ ).

- (D) Infected animals with *L. (L.) amazonensis* and treated with meglumine antimoniate at 120 mg kg<sup>-1</sup> day<sup>-1</sup> for 10 days (ten applications) ( $n = 10$ ).
- (E) Infected animals with *L. (L.) amazonensis* and treated with vehicle solution in which the compound was solubilized (DMSO at 1% in physiological saline solution) (four applications) ( $n = 8$ ).
- (F) Infected animals with *L. (L.) amazonensis* and treated with the compound 11 $\alpha$ ,19 $\beta$ -dihydroxy-7-acetoxy-7-deoioichangin at dose of 8.7 mg kg<sup>-1</sup> every 4 days (four applications) ( $n = 6$ ).

The number of animals used in each experimental design, is permitted by the Ethics Committee for Animal Experimentation of the Universidad Nacional de Colombia and the Universidad de Antioquia, and is consistent with the Act 84 of 1989 of the Republic of Colombia 'National Protection Statute animal' and Resolution No. 1993 008 430 from the Ministry of Health, title V on 'Biomedical research on animals'.

#### Clinical monitoring of infected animals

Stool characteristics, behaviour of the animal, weight data, papules or ulcers on the backs and the diameter of the lesions were registered (measuring the transverse and sagittal diameter of cutaneous lesions of each animal with a digital caliper), once a week. The evolution of the lesions was evaluated by the application of the evolution index (EI = mm lesion area – initial lesion area mm/initial lesion area mm) (Henaó *et al.* 2004), and based on the reports of Robledo and cols (Robledo *et al.* 2006), we considered four clinical types of response based on their resolution.

According to the above, the parameters or groups of clinical disease progression were:

- (1) 'cure', which corresponded to animals that showed a total resolution of the lesion without parasites on histopathology or presence of induration;
- (2) 'clinical improvement', which referred to animals that showed a partial resolution of the disease, with decreased lesion size with a percentage of reduction higher than 50% of the area;
- (3) 'relapse', which correspond to animals with an initial reduction of lesion size, which after completion treatment, presented an increase in the diameter of the skin lesions;
- (4) and 'no response', which consists of those animals that despite of the reduction in the scarring or induration, this was less than 50% with respect to the initial size of the lesion.

Parasite load was quantified by microscope counting in Giemsa stained samples from hamsters infected with *L. (V.) panamensis* or limiting dilution in

samples from hamsters infected with *L. (L.) amazonensis*.

#### Analysis of skin histopathologies

At the end of the study, animals were sacrificed with euthanasia protocol as previously described. Skin biopsies were taken and stored in 10% formalin for submission to the pathology laboratory, where they realized the histopathology study.

In the case of the slides of infected animals with *L. (V.) panamensis*, to each slide coloured with haematoxylin and eosin were taken pictures with different enlargement magnitudes (100, 200 and 400 $\times$ ) with a microscope Nikon Eclipse E600 using the software AMT-1 Nikon and the corresponding signals were subsequently converted to TIF format.

The image analysis was carried out using the photos taken with 400 $\times$ , which allowed us to observe more easily the characteristics of the cell populations, whose analysis was performed using the open access software ImageJ (Abramoff *et al.* 2004; Schneider *et al.* 2012), with which the images were processed and the desired characteristics were modified as picture contrast, noise, brightness, among others. Once the image was loaded into the program in RGB format (image red, green and blue) the threshold was set in which each image would work (cleaning those structures different from the cellular infiltrate, which in our case were the population of our interest) and a visible separating features of interest with respect to non-relevant features (by setting the threshold for the hue, saturation and brightness). To highlight the colour of the characteristics to be assessed, the tool brightness and contrast were used, and then by drawing a grid on the image by using the 'cell counter plugin' (developed by Kurt De Vos University of Sheffield, Academic Neurology), semiquantitative value was obtained from an average of the different fields in tissue section per slide. To this end, at least 10 fields per slide were evaluated, which reach to cover most of the area of the slide.

For animals infected with *L. (L.) amazonensis*, biopsies from skin, liver and kidney were taken to determine toxicity of treatments. The presence of histological changes attributed to each treatment was recorded and severity of the histological changes was graded as severe, moderate or mild.

#### Chemistry blood analysis

Under anaesthesia with ketamine (Imalgene 1000<sup>®</sup>) and xylazine (Rompun<sup>®</sup> 2%) intramuscularly at recommended dose (Flecknell, 1996) and prior to euthanasia, cardiac puncture was performed for each hamster with a 1 mL syringe and 23 G needle



(Becton Dickinson, USA), obtaining an average of 1–2 mL of blood. Levels in serum of Alkaline phosphatase (ALP), urea, creatinine (as indicators of renal function) and Alanine aminotransferase (ALT) and Aspartate aminotransferase (AST) (as indicators of liver function).

The quantification of serum levels of the enzymes and products mentioned before were referred to the Veterinary Clinical Pathology Laboratory of the Universidad Nacional de Colombia for the serum of animals infected with *L. (V.) panamensis*, while quantification for the serum samples of the animals infected with *L. (L.) amazonensis* was held at the laboratory of the PECET in the Universidad de Antioquia.

### Statistical analysis

All the results were analysed according to parameters of each technique and statistical analyses were performed using the statistical software GraphPad Prism version 5.00 Demo (GraphPad Software, USA). Statistical significance was defined as *P* value less than 0.05 ( $P < 0.05$ ). The *in vivo* efficacy of the treatments used are expressed in terms of the rate of evolution of the lesion, and by the observations of the macroscopic characteristics of lesions was determined cure rate, and thereby establishing whether there was improvement, failure or therapeutic relapse to treatments (Robledo *et al.* 2006, 2012) and for the others clinical parameters evaluated was compared between treatments and controls, with the aim to evidencing significant changes.

### Ethical considerations

The housing and management of laboratory animals was governed by provisions of the Law 84 of 1989 of the Republic of Colombia, the resolution 8430 of 1993 of the Ministry of Health of the Republic of Colombia and the resolution 594 of 1996 of the National Health Institute of Colombia.

The care and use of laboratory animals was performed under conditions established by Committee on Care and Use of Laboratory Animals (CCAC, USA) and in accordance with standard operating procedures established by the bioterium of the Pharmacy Department and the installations of the PECET.

The development of the above procedures was approved by the Ethics Committee and Animal Use of Faculty of Sciences at the Universidad Nacional de Colombia (Act 4, 27 June 2009) and by the Ethics Committee and Use Animals at the Universidad de Antioquia (Act 53, 8 June 2009).

Considerations for euthanizing animals before the time arranged for the study were based on clinical observations, and euthanasia protocol used followed

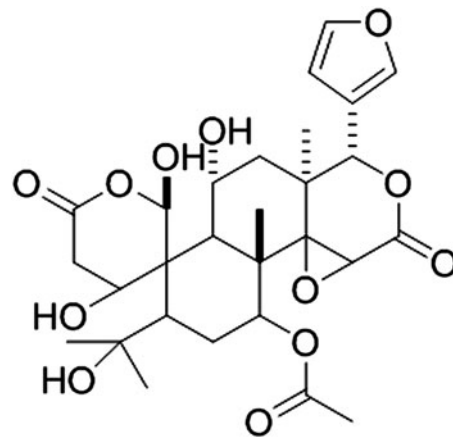


Fig. 1. *seco*-limonoid compound structure (11 $\alpha$ ,19 $\beta$ -dihydroxy-7-acetoxy-7-deoxoichangin–C<sub>28</sub>H<sub>36</sub>O<sub>12</sub>, 565·2285).

the recommendations of American Veterinary Medical Association (AVMA, 2007).

### RESULTS

#### *In vitro* evaluation of the cytotoxic and antileishmanial activity of the compound 11 $\alpha$ ,19 $\beta$ -dihydroxy-7-acetoxy-7-deoxoichangin

The compound 11 $\alpha$ ,19 $\beta$ -dihydroxy-7-acetoxy-7-deoxoichangin was obtained through conventional purification methods as reported by Coy Barrera *et al.* (2011). Ultraviolet spectroscopic, infrared, nuclear magnetic resonance of hydrogen and carbon 13, circular dichroism, NOESY experiments and data reported in the literature for this *seco*-limonoid were used for the structural elucidation, using always the previously isolated compound as standard for the comparison (Fig. 1).

To evaluate the cytotoxic activity of *seco*-limonoid 11 $\alpha$ ,19 $\beta$ -dihydroxy-7-acetoxy-7-deoxoichangin and of the control drug used (meglumine antimoniate) on monocyte/macrophage cells (which are the preferred target cells in natural infection) we used PMH, determining a CC<sub>50</sub> of 226.6 and 4394  $\mu$ M, respectively (Table 1).

Thereafter, we evaluated the antileishmanial effect of the *seco*-limonoid 11 $\alpha$ ,19 $\beta$ -dihydroxy-7-acetoxy-7-deoxoichangin on intracellular amastigotes of *L. (V.) panamensis* using PMH as target cells of *in vitro* infection, being found an EC<sub>50</sub> of 59  $\mu$ M with a SI of 3.8, which suggests that there is a greater probability of controlling this intracellular pathogen than of inducing an adverse effect on host cells (in this case, the adverse effects refers to the destruction of the target cell of *in vitro* infection by parasites of *Leishmania*). On the other hand, for the control drug used (meglumine antimoniate) we obtained an EC<sub>50</sub> of 260  $\mu$ M (Table 1).

Table 1. Cytotoxic and antileishmanial activity

Compound	$\mu\text{M}$				SI
	CC <sub>50</sub> (CI 95%)	EC <sub>50</sub> (CI 95%)	CC <sub>50</sub> (CI 95%)	EC <sub>50</sub> (CI 95%)	
11 $\alpha$ ,19 $\beta$ -dihydroxy-7-acetoxy-7-deoxoichangin	225.6	192–265	59	32.6–107.6	3.8
Meglumine antimoniate	4394	2400–8041	260	99–684	17

CC<sub>50</sub>, cytotoxic concentration 50; EC<sub>50</sub>, effective concentration 50; CI, confidence interval; SI, selective index.

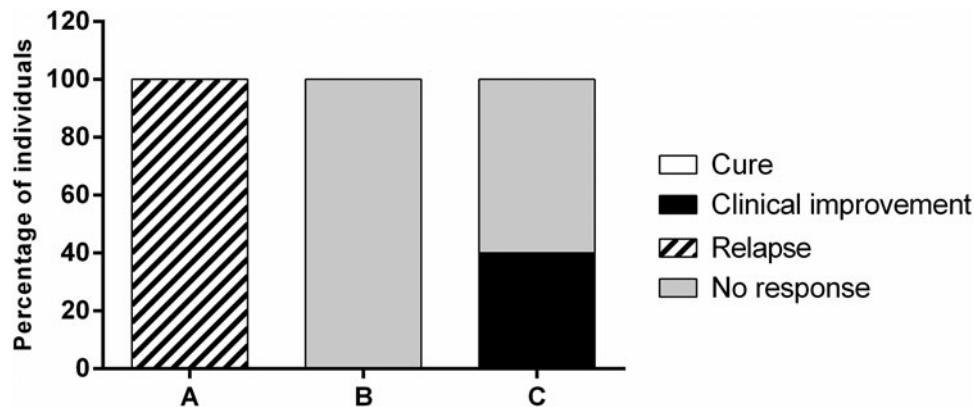


Fig. 2. Clinical response on hamsters infected with *L. (V.) panamensis* at the day 66 after initiation of the treatment (PTD50). Abbreviation: PTD, post-treatment day.

#### *Antileishmanial effect of 11 $\alpha$ ,19 $\beta$ -dihydroxy-7-acetoxy-7-deoxoichangin in golden hamsters (*M. auratus*) infected with *L. (V.) panamensis**

As we mentioned before, golden hamsters (*M. auratus*) infected with *L. (V.) panamensis* were used to evaluate the *in vivo* activity of 11 $\alpha$ ,19 $\beta$ -dihydroxy-7-acetoxy-7-deoxoichangin, and the progression or disease control were compared with the evolution of the experimental group B animals infected and treated with the solution where the compound was solubilized (DMSO at 1% in physiological saline solution) (vehicle solution), and comparing the evolution of each animal against its registration before starting treatment (as baseline).

In this way, animals belonging to the group A showed a marked decrease in the diameter of lesions since the second week of treatment, which however, was not sustained until the end of the clinical monitoring (day 66 of the clinical follow-up and 50 days post treatment ends [PTD50]), increasing in a significant form the size of the lesions, reason by which the response of the animals of this group was categorized as 'relapse' in all the individuals.

Regarding the animals of group B, no clinical improvement was observed in any of the individuals during treatment or the clinical monitoring, their outcome was classified as 'no response' category, while animals belonging to the experimental group C showed a better resolution of skin lesions during and at the end of the clinical monitoring, the

response of 40% of the individuals was classified as 'clinical improvement', showing a reduction of the size of the lesion higher than 50% compared with the baseline (Figs 2 and 3). It is important to mention that such improvement was evident since the day 8 after initiation of treatment and was maintained until day 66 of the clinical follow-up (PTD50), and statistically significant differences were observed when comparing the response obtained at the last day of clinical monitoring with response to animals of group A at the same day of follow-up (*P* value 0.0313).

#### *Semiquantitative analysis of the skin histopathologies from golden hamsters (*M. auratus*) infected with *L. (V.) panamensis**

Histopathological study of the tissue from infected animals was performed through skin biopsies, which were sent to the Veterinary Pathology Laboratory of the Universidad Nacional de Colombia. Thus, the groups A and B evidenced the presence of structures compatible with *Leishmania* (in total 10 fields were observed by cutting skin), with an average of 75 and 50 parasites per field, respectively.

Regarding the histopathological findings in the skin biopsies of the animals belonging to group A, a severe inflammatory cell infiltrate with the presence of mononuclear and plasmatic cells were found in the dermis and hypodermis. On the other hand, in the animals treated with the vehicle solution

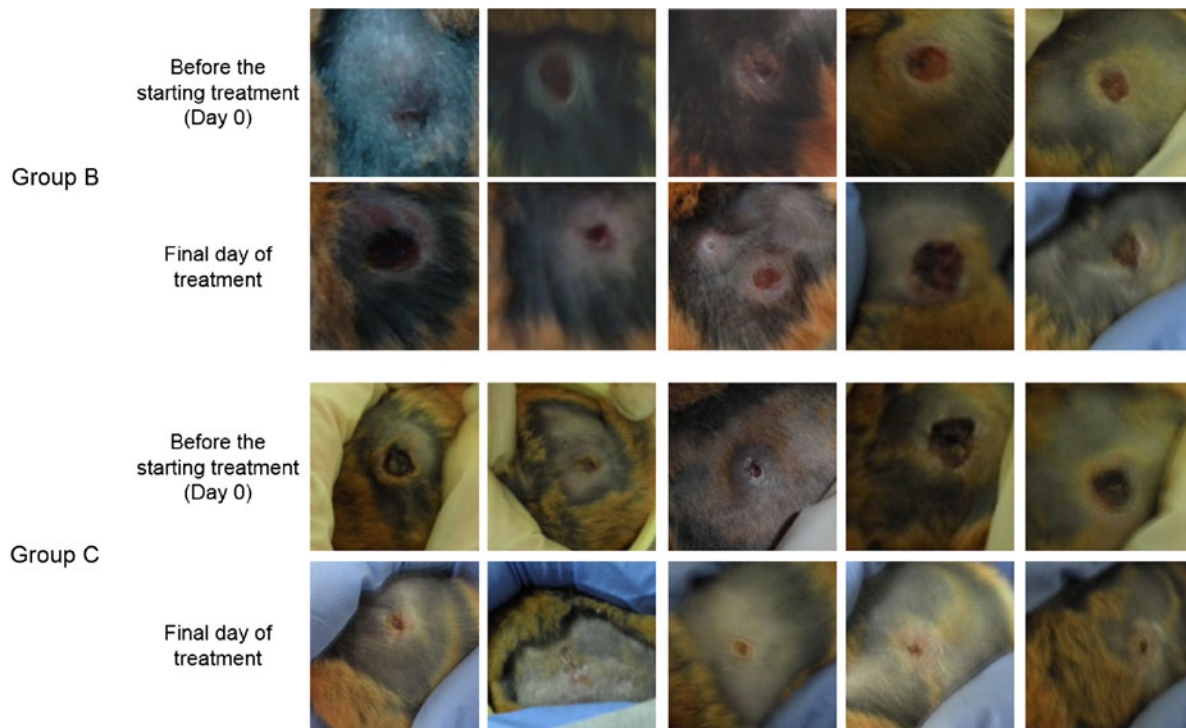


Fig. 3. Clinical assessment of the cutaneous lesions in hamsters infected with *L. (V.) panamensis* at the day 66 after initiation of the treatment (PTD50). Abbreviation: PTD, post-treatment day.

Table 2. Cellular populations finding in skin histopathologies of animals in the different groups of treatments

Group	Histiocytes		Macrophages		Neutrophils		Lymphocytes		Plasma cells		Mean of parasites
	%	S.D.	%	S.D.	%	S.D.	%	S.D.	%	S.D.	
A	21.7	8.1	46.8	30.2	3.9	5.5	25.5	16.8	2.1	0.2	75
B	10.6	0.8	36.7	30.5	7.0	2.9	42.8	25.2	2.9	1.7	50
C	19.0	14.4	7.0	9.1	14.2	6.7	43.2	15.7	3.5	3.4	17

S.D., standard deviation.

(group B) we observed that the subcutaneous tissue and muscle were affected with severe necrosis and diffuse infiltrate, which were composed mainly of plasmatic cells, neutrophils and histiocytes, with an infiltrate at the level of hypodermis, indicating the extent of infection with initial infiltrate present in the dermis (Table 2).

On the other hand, in the animals treated with  $11\alpha,19\beta$ -dihydroxy-7-acetoxy-7-deoxoichangin compound (group C) were not evidenced of basophilic structures in the mononuclear cells (whose presence is compatible with intracellular parasites of *Leishmania*) in one (1) of the five (5) animals, while in the other four (4) individuals of this group, such structures were found with an average of 17 structures (being this value lower compared with the results obtained in the other groups).

Regarding the histopathological findings of the cellular infiltrate of group C, a predominance of mononuclear infiltrate was observed, further a histiocytic infiltrates, evidenced also in one (1) of the

animals a predominance of activated macrophages (through the association of macrophages vacuolated with activated macrophages). Also, in one (1) of the five (5) animals, minor changes were observed in the normal skin architecture, a finding with good prognosis, bearing in mind that it is re-establishing the normal architecture tissue after infection process (Table 2 and Fig. 4).

*Antileishmanial effect of 11 $\alpha$ ,19 $\beta$ -dihydroxy-7-acetoxy-7-deoxoichangin in golden hamsters (M. auratus) infected with L. (L.) amazonensis and toxicity*

Analysis of therapeutic efficacy of the seco-limonoid compound on the infection caused by *L. (L.) amazonensis* (progression or adequate control of the disease) was evaluated by comparing the evolution of each group with the experimental group E animals infected and treated with the solution where the compound was solubilized (DMSO at



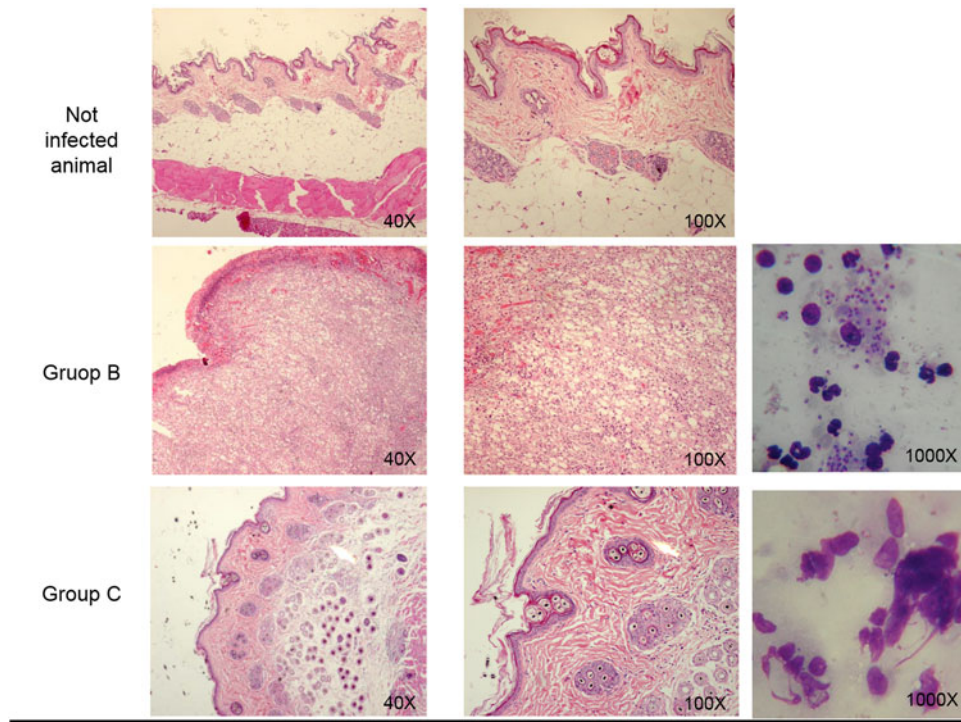


Fig. 4. Histopathology and imprints findings of skin lesions caused by *L. (V.) panamensis* in golden hamsters *M. auratus*.

1% in physiological saline solution), and comparing also the evolution of each animal against its registration before the starting of treatment (as we mentioned before). In this sense, areas of ulcer and body weight were measured every 2 weeks from the beginning of treatments to the end of the study (3 months after the completion of treatment). The overall time points of evaluation were: pretreatment day (D0), end of treatment (D14) and PTDs 30, 60 and 90, respectively) (Table 3).

Clinical parameters of disease resolution (*cure*, *clinical improvement*, *relapse* and *no response*) was also taken into consideration for categorizing each experimental group [as we show in the section for the monitoring of the therapeutic efficacy on animals infected with *L. (V.) panamensis*].

At the end of the study (90 days after the end of treatment), animals treated with meglumine antimoniate at  $120 \text{ mg kg}^{-1} \text{ day}^{-1}$  (group D), showed *cure* in eight (8) of the ten (10) animals, while the other 2 animals showed an increased in the size of lesions, categorized these animals on the clinical group of *cure* (80%) and *relapse* (20%), respectively (Fig. 5).

On the other hand, treatment with  $11\alpha,19\beta$ -dihydroxy-7-acetoxy-7-deoxychanganin compound (group F) administered once a day every 4 days during 16 days induced *cure* only in one (1) hamsters at the end of treatment (D14); however, the therapeutic response increased during the follow up period so that at PTD60 *cure* was observed in three (3) of six (6) hamsters (50%); the remaining three (3) hamsters of this group showed clinical

improvement with  $85.7 \pm 6.3\%$  of reduction in the lesion size. Unfortunately, at the end of the study, PTD90, one hamster presented *relapse* decreasing the therapeutic response from 50 to 33.3% (Fig. 5).

In turn, although the clinical improvement observed in 50% of hamsters treated with vehicle solution (DMSO at 1% in physiological saline solution) (group E) during the study (from TD16 to PTD60), is relevant to point it out that none of the individuals showed *cure* at any time during follow up, and at the end of the clinical follow scheme (PTD90), none of the individuals showed resolution of lesions size greater than 50%.

Regarding the parasitic charge for the animals treated with meglumine antimoniate (group D), vehicle (group E) and *seco*-limonoid (group F) that did not *cure* it was determined  $5.500$ ,  $25.003$  and  $5.750$  parasites  $\text{mg}^{-1}$  of tissue, respectively. Differences were statistically significant between vehicle *vs* meglumine antimoniate or *seco*-limonoid ( $P < 0.001$ ). Difference between *seco*-limonoid and meglumine antimoniate was not statistically significant ( $P > 0.005$ ).

Histological alterations attributable to treatment with vehicle or *seco*-limonoid were not observed (groups D and F); turbid degeneration and congestion, in mild degree, was observed in liver. In kidney, only congestion (in moderate degree) was detected. On the other hand, treatment with meglumine antimoniate (group D) induced in liver moderate to severe cloudiness, vacuolar and fat degeneration, karyomegaly, bi-nucleation and



Table 3. Therapeutic efficacy of *seco*-limonoid in hamsters with cutaneous leishmaniasis caused by *L. (L.) amazonensis*

Group <sup>a</sup>	Cure% (n)				Improvement% (n)				No response% (n)			
	EoT <sup>b</sup>	PTD30	PTD60	PTD90	EoT	PTD30	PTD60	PTD90	EoT	PTD30	PTD60	PTD90
D	40 (4)	100 (10)	80 (8)	80 (8)	40 (2)	0 (0)	0 (0)	0 (0)	40 (4)	0 (0)	0 (0)	0 (0)
E	0 (0)	0 (0)	0 (0)	0 (0)	50.0 (4)	75.0 (6)	50.0 (4)	0 (0)	50.0 (4)	25.0 (2)	50.0 (4)	50 (4)
F	16.7 (1)	16.7 (1)	50.0 (3)	33.3 (2)	33.3 (2)	66.7 (4)	50.0 (3)	50.0 (3)	33.3 (2)	16.7 (1)	0 (0)	0 (0)

<sup>a</sup> D, meglumine antimoniate (1 × 10 days); E, vehicle (1 × every 4 days, 16 days); F, *seco*-limonoid (1 × every 4 days, 16 days).

<sup>b</sup> EoT, end of treatment; PTD, post-treatment day.

pigmentation while in kidney fat degeneration and bi-nucleation (from mild to moderate degree) was detected. In the skin, liver and kidney biopsies of all animals of groups D, E and F lymphocytes, plasmatic cells and macrophages were present in moderate amount.

*Weight analysis in golden hamsters infected with Leishmania species*

The weight was corrected for each animal was made taking into account their initial value for the analysis associated with the loss or gain of weight of the infected and treated animals, (WI = weight g animal/initial weight in g of the same individual), obtained thus an EI, where 1 is the starting index, and increases or decreases in the values were associated with gain or weight reduction, respectively. In this respect, a downward trend in the rate of weight in group B was observed. However, no significant differences were observed in any experimental group when we compared the WI between all the treatment groups.

*Hepatic and renal function in golden hamsters infected with Leishmania species*

For evaluation of serum levels of Alanine aminotransferase (ALT), Aspartate aminotransferase (AST) (liver function), Alkaline phosphatase (AP) (as an indicator of inflammation), urea and creatinine (renal function), blood samples were taken at the endpoint of the test (Mougueau *et al.* 1995), demonstrating that the treatments did not generate toxic effects on the liver and kidneys of animals infected with *L. (V.) panamensis*, while in infected animals with *L. (L.) amazonensis* and treated with control drug (Group D) and the *seco*-limonoid (Group F) a hepatic toxic effect was determined (ALT value average of 54.8 ± 36.4 and 80.5 ± 29, respectively, – reference values of 11.6–35.9).

On the other hand, it is important to highlight that in all animals (both infected and uninfected) an increase in the serum levels of urea were found, this finding is associated with the solid diet or water (data not shown).

DISCUSSION

The treatment of leishmaniasis, which is far from ideal (TDR, 2004; Croft *et al.* 2006a) (due to several factors that includes: the high toxicity, high costs involved in the purchasing of the drugs as also the costs associated with patient care after administration of the medicament, emergence of parasite strains resistant to the drugs used) (Croft *et al.* 2006b), urgently need to develop studies on the generation of new therapies to overcome these disadvantages, and therefore, allow a more control effective

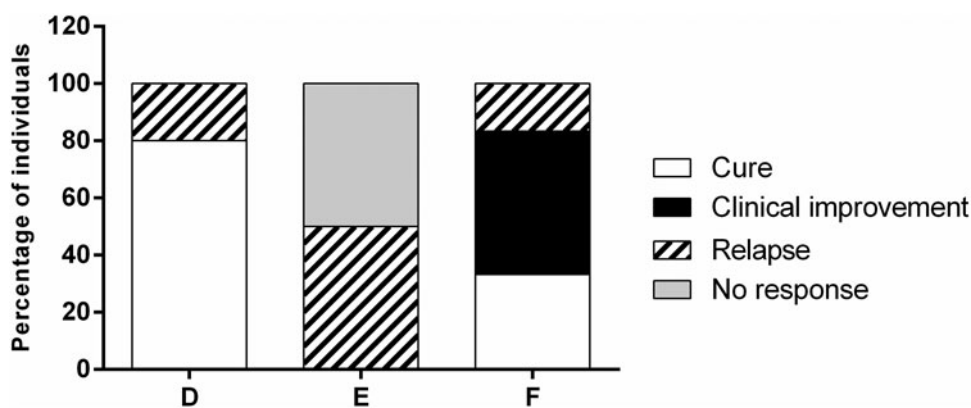


Fig. 5. Clinical response on hamsters infected with *L. (L.) amazonensis* at the day 90 after the end of the treatment (PTD90). Abbreviation: PTD, post-treatment day.

for this disease (de Carvalho and Ferreira, 2001; Newman and Cragg, 2007), being the study of bioactive molecules derived from natural products, one of the most widely explored approaches to solve this problem (de Carvalho and Ferreira, 2001; Newman and Cragg, 2007).

The *seco*-limonoid compound 11 $\alpha$ ,19 $\beta$ -dihydroxy-7-acetoxy-7-deoxoichangin has proved to be a promising antileishmanial agent allowing control of the experimental infection with *Leishmania* promastigotes on murine macrophages (Coy Barrera *et al.* 2011) also it was observed that an immunomodulatory effect of this compound on these antigen presenting cells, leads to the polarization of the immune response to a pro-inflammatory effector phenotype (Granados-Falla *et al.* 2013). Worth mentioning that this *seco*-limonoid is not the only limonoid compound for which has been described some antileishmanial activity, examples of this being 7-deacetylgedunin and 7-oxo-7-deacetylgedunin compounds (Hay *et al.* 2007).

Our results, confirm the leishmanicidal activity of the *seco*-limonoid 11 $\alpha$ ,19 $\beta$ -dihydroxy-7-acetoxy-7-deoxoichangin, showing with a dose of 8.7 mg kg<sup>-1</sup> an antileishmanial effect that led to clinical improvement in infected animals with *L. (V.) panamensis* and *L. (L.) amazonensis*. Similarly, the clinical improvement of lesions of the treated animals relative to controls of treatment showed that the effect of the compound is also associated with the promotion of a process with immunomodulatory properties showing small and favourable changes in histopathology studies of skin lesions of animals infected with *L. (V.) panamensis* (Fig. 4).

On the other hand, it was observed that once the scheme of treatment ended, most of the animals that had been treated with the reference drug in South America (meglumine antimoniate) with 60 mg kg<sup>-1</sup> day<sup>-1</sup> (which had shown clinical improvement during the administration of the drug), showed a strong *relapse* at the end of the clinical follow-up (group A), while animals of the experimental group

treated with 120 mg kg<sup>-1</sup> day<sup>-1</sup> showed a 100% clinical improvement after the second month after treatment (group D) (time at which, the animals of the group treated with 60 mg kg<sup>-1</sup> day<sup>-1</sup> for 20 days presented the relapses), and only 20% of *relapse* were completed after clinical monitoring, this treatment regimen being better than the other one for the disease control, despite the toxicity evidenced at the level of liver enzymes.

Furthermore, in connection with the experimental groups treated with the *seco*-limonoid compound 11 $\alpha$ ,19 $\beta$ -dihydroxy-7-acetoxy-7-deoxoichangin (groups C and F), the number of parasites observed or determined were 0–50 parasites per field (mean of 17 parasites) and 5.750 parasites mg<sup>-1</sup> of tissue, respectively, being the groups with the lowest average of observed parasites.

Additionally, the presence of slight changes in tissue architecture is related to the normal tissue morphology observed after developing an infection and its treatment, where apparently the etiologic agent has not only been removed, but besides the tissue organization has been restored.

Likewise, in the experimental group infected with *L. (L.) amazonensis* and treated with the *seco*-limonoid (group F) at the end of the clinical monitoring (3 months after the completion of therapy), was evidenced as cure in the 33.3% of the animals belonging to that group and a *clinical improvement* of 50% and *relapse* in 16.7%, without evidence of any episode associated with treatment failure and any toxic effect associated with this treatment.

Importantly, findings in this study in relation to the ability of the compound 11 $\alpha$ ,19 $\beta$ -dihydroxy-7-acetoxy-7-deoxoichangin to facilitate control of infection *in vivo* in animals infected with *L. (V.) panamensis* as in those infected with *L. (L.) amazonensis*, are quite striking, given that the two species studied here, have epidemiological relevance at South America, in addition those that belong to each of a different subgenus, therefore, suggest that the antileishmanial activity evidenced here, could

be extrapolated to infections caused by any of the several species associated with disease presentation.

#### ACKNOWLEDGEMENTS

We express our gratitude to the members of the Immunotoxicology Research Group, the Research Laboratory of Natural Plant Products of the Universidad Nacional de Colombia and the PECET of the Universidad de Antioquia.

#### FINANCIAL SUPPORT

This project was financed by Bogotá Research Division (DIB) at the Universidad Nacional de Colombia (grant number 15098 and 16015) and the Colombian Institute for the Development of Science and Technology – Colciencias (grant number 1101-569-34446 contract RC463-2012). In detail, for all grants, support was awarded to G. D. as principal investigator, while D. G.-F received support from the grants 16015 and 1101-559-34446, AG-G from grants 15098, 16015 and 1101-559-34446, and AD, SR, CC-B and LC from grant 1101-559-34446.

#### REFERENCES

Abramoff, M., Magalhaes, P. and Ram, S. (2004). Image processing with ImageJ. *Biophotonics International* **11**, 36–42.

Alvar, J., Vélez, I. D., Bern, C., Herrero, M., Desjeux, P., Cano, J., Jannin, J., den Boer, M. and WHO Leishmaniasis Control Team (2012). Leishmaniasis Worldwide and Global Estimates of Its Incidence. *PLoS ONE* **7**, 1–12.

AVMA (2007). *AVMA Guidelines on Euthanasia (Formerly Report of the AVMA Panel on Euthanasia)*, pp. 11–12. American Veterinary Medical Association. <https://grants.nih.gov/grants/olaw/Euthanasia2007.pdf>

Awasthi, A., Mathur, R. K. and Saha, B. (2004). Immune response to *Leishmania* infection. *Indian Journal of Medical Research* **119**, 238–258.

Batista, R., Silva Ade, J., Jr. and de Oliveira, A. B. (2009). Plant-derived antimalarial agents: new leads and efficient phytomedicines. Part II. Non-alkaloidal natural products. *Molecules* **14**, 3037–3072.

Berman, J., Bryceson, A. D., Croft, S., Engel, J., Gutteridge, W., Karbwang, J., Sindermann, H., Soto, J., Sundar, S. and Urbina, J. A. (2006). Miltefosine: issues to be addressed in the future. *Transactions of the Royal Society of Tropical Medicine & Hygiene* **100** (Suppl 1), S41–S44.

Bey, E. and Harington, J. (1971). Cytotoxic effects of some mineral dusts on Syrian hamster peritoneal macrophages. *The Journal of Experimental Medicine* **135**, 1149–1169.

Clem, A. (2010). A current perspective on leishmaniasis. *Journal of Global Infectious Diseases* **2**, 124–126.

Coy Barrera, C. A., Coy Barrera, E. D., Granados Falla, D. S., Delgado Murcia, G. and Cuca Suarez, L. E. (2011). seco-limonoids and quinoline alkaloids from *Raputia heptaphylla* and their antileishmanial activity. *Chemical and Pharmaceutical Bulletin* **59**, 855–859.

Croft, S. L., Seifert, K. and Yardley, V. (2006a). Current scenario of drug development for leishmaniasis. *Indian Journal of Medical Research* **123**, 399–410.

Croft, S. L., Sundar, S. and Fairlamb, A. H. (2006b). Drug resistance in leishmaniasis. *Clinical Microbiology Reviews* **19**, 111–126.

de Carvalho, P. B. and Ferreira, E. I. (2001). Leishmaniasis phytotherapy. Nature's leadership against an ancient disease. *Fitoterapia* **72**, 599–618.

Delgado, J., Macias, J., Pineda, J. A., Corzo, J. E., Gonzalez-Moreno, M. P., de la Rosa, R., Sanchez-Quijano, A., Leal, M. and Lissen, E. (1999). High frequency of serious side effects from meglumine antimoniate given without an upper limit dose for the treatment of visceral leishmaniasis in human immunodeficiency virus type-1-infected patients. *The American Journal of Tropical Medicine and Hygiene* **61**, 766–769.

Dorlo, T. P., Balasegaram, M., Beijnen, J. H. and de Vries, P. J. (2012). Miltefosine: a review of its pharmacology and therapeutic efficacy in the treatment of leishmaniasis. *Journal of Antimicrobial Chemotherapy* **67**, 2576–2597.

El-On, J. (2009). Current status and perspectives of the immunotherapy of leishmaniasis. *The Israel Medical Association Journal* **11**, 623–628.

Flecknell, P. (1996). *Laboratory Animal Anaesthesia*, 2nd Edn. Academic Press, New York.

Githua, M., Hassanali, A., Keriko, J., Murilla, G., Ndungu, M. and Nyagah, G. (2010). New antitrypanosomal tetranortriterpenoids from *Azadirachta indica*. *African Journal of Traditional, Complementary, and Alternative Medicines* **7**, 207–213.

Granados-Falla, D., Coy-Barrera, C., Cuca, L. and Delgado, G. (2013). seco-limonoid 11 $\alpha$ ,19 $\beta$ -dihydroxy-7-acetoxy-7-deoxoichangin promotes the resolution of *Leishmania panamensis* infection. *Advances in Bioscience and Biotechnology* **4**, 304–315.

Hay, A. E., Ioset, J. R., Ahua, K. M., Diallo, D., Brun, R. and Hostettmann, K. (2007). Limonoid orthoacetates and antiprotozoal compounds from the roots of *Pseudoecedrela kotschyi*. *Journal of Natural Products* **70**, 9–13.

Henao, H. H., Osorio, Y., Saravia, N. G., Gomez, A. and Travi, B. (2004). [Efficacy and toxicity of pentavalent antimonials (Glucantime and Pentostam) in an American cutaneous leishmaniasis animal model: lumino-metry application]. *Biomedica* **24**, 393–402.

Mansueto, P., Vitale, G., Di Lorenzo, G., Rini, G. B., Mansueto, S. and Cillari, E. (2007). Immunopathology of leishmaniasis: an update. *International Journal of Immunopathology and Pharmacology* **20**, 435–445.

Meheus, F., Balasegaram, M., Olliaro, P., Sundar, S., Rijal, S., Faiz, M. A. and Boelaert, M. (2010). Cost-effectiveness analysis of combination therapies for visceral leishmaniasis in the Indian subcontinent. *PLoS Neglected Tropical Diseases* **4**, e818.

Mougeau, E., Altare, F., Wakil, A. E., Zheng, S., Coppola, T., Wang, Z. E., Waldmann, R., Locksley, R. M. and Glaichenhaus, N. (1995). Expression cloning of a protective *Leishmania* antigen. *Science* **268**, 563–566.

Mougeau, E., Bihl, F. and Glaichenhaus, N. (2011). Cell biology and immunology of *Leishmania*. *Immunological Reviews* **240**, 286–296.

Newman, D. J. and Cragg, G. M. (2007). Natural products as sources of new drugs over the last 25 years. *Journal of Natural Products* **70**, 461–477.

Nylen, S. and Gautam, S. (2010). Immunological perspectives of leishmaniasis. *Journal of Global Infectious Diseases* **2**, 135–146.

O'Brien, J., Wilson, I., Orton, T. and Pognan, F. (2000). Investigation of the Alamar Blue (resazurin) fluorescent dye for the assessment of mammalian cell cytotoxicity. *European Journal of Biochemistry* **267**, 5421–5426.

Pulido, S. A., Munoz, D. L., Restrepo, A. M., Mesa, C. V., Alzate, J. F., Velez, I. D. and Robledo, S. M. (2012). Improvement of the green fluorescent protein reporter system in *Leishmania* spp. for the *in vitro* and *in vivo* screening of antileishmanial drugs. *Acta Tropica* **122**, 36–45.

Robledo, S. M., Puerta, J. A., Munoz, D. L., Guardo, M. and Velez, I. D. (2006). Efficacy and tolerance of pentamidine for treatment of cutaneous leishmaniasis caused by *L. (V) panamensis* in Colombia. *Biomedica* **26** (Suppl. 1), 188–193.

Robledo, S., Carrillo, L., Daza, A., Restrepo, A., Muñoz, D., Tobón, J., Murillo, J., López, A., Ríos, C., Mesa, C., Upegui, Y., Valencia-Tobón, A., Mondragón-Shem, K., Rodríguez, B. and ID, V. (2012). Cutaneous leishmaniasis in the dorsal skin of hamsters: a useful model for the screening of antileishmanial drugs. *Journal of Visualized Experiments* **e3533**, 1–9.

Rosas, L. V. (2005). Phytochemistry, chemosystematic and searching of new antichagasic and antileishmaniasis drugs: study of *Raputia praetermissa* (Rutaceae). *Tesis Universidad Federal de San Carlos – Brasil* San Carlos, 280 p.

Santos, D. O., Coutinho, C. E., Madeira, M. F., Bottino, C. G., Vieira, R. T., Nascimento, S. B., Bernardino, A., Bourguignon, S. C., Corte-Real, S., Pinho, R. T., Rodrigues, C. R. and Castro, H. C. (2008). Leishmaniasis treatment—a challenge that remains: a review. *Parasitology Research*, **103**, 1–10.

Schneider, C., Rasband, W. and Eliceiri, K. (2012). NIH image to ImageJ: 25 years of image analysis. *Nature Methods* **9**, 671–675.

TDR (2004). *Report of the Scientific Working Group meeting on Leishmaniasis*. Tropical Disease Research – World Health Organization, Geneva.

WHO (2005). *Report of a WHO Informal Consultation on Liposomal Amphotericin B in the Treatment of Visceral Leishmaniasis*. pp. 25. Rome, Italy.

WHO (2010). *Control of the Leishmaniasis (Report of a meeting of the WHO Expert Committee on the Control of Leishmaniasis)*. Geneva. [http://apps.who.int/iris/bitstream/10665/44412/1/WHO\\_TRS\\_949\\_eng.pdf](http://apps.who.int/iris/bitstream/10665/44412/1/WHO_TRS_949_eng.pdf)