

# Neuroimaging Highlight

Editors: Richard Farb, David Pelz

## The "Reversal Sign" Following a Massive Left-Hemispheric Stroke

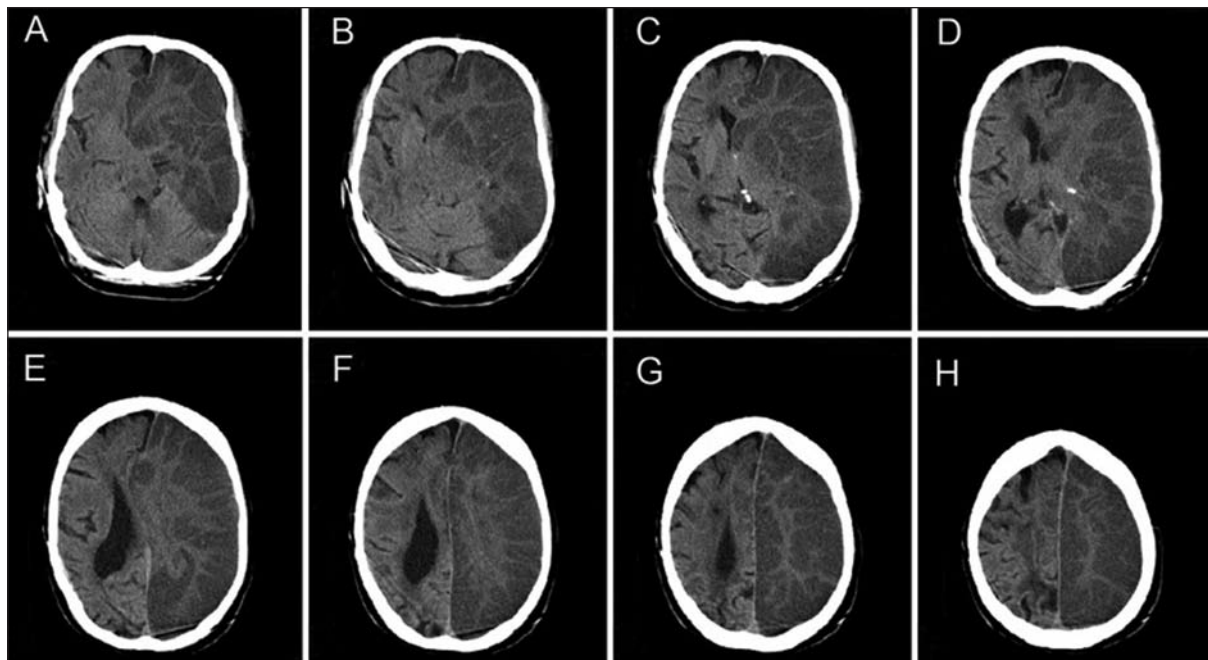
Submitted by: Philippe Huot, François Émond

Can. J. Neurol. Sci. 2010; 37: 395-396

A 71-year-old man came to the emergency room following acute onset right hemiplegia and global aphasia. The first head computed tomography (CT) scan revealed left hemispheric stroke. The following day, a follow-up head CT scan revealed an attenuated density of the grey matter, when compared to the adjacent white matter, referred to as the "reversal sign". It is believed that this finding reflects a diffuse anoxic/ischaemic cerebral injury. After discussion with the patient's family, care

was withdrawn and the patient died a few days later.

The reversal sign seems to be more common in the paediatric than in the adult population. The reversal sign has been described in association with brain hypoxia, head trauma, metabolic factors such as hyperglycaemia, hypothermia, status epilepticus, drowning, and infectious processes. In the paediatric population, child abuse might also be a cause. Regardless of its aetiology, however, the reversal sign correlates with severe brain damage



**Figure:** CT scan of the head illustrating the "reversal sign" across different brain levels in our 71-year-old patient. Images show decreased radiodensity of the left hemispheric cortical and deep grey matter compared to adjacent white matter. Normal grey-white differentiation is maintained throughout most of the right hemisphere. There is associated mass effect, with diffuse left-sided sulcal effacement, midline shift, effacement of the left lateral ventricle, and enlargement of the right lateral ventricle.

From Toronto Western Research Institute (PH), University Health Network, Toronto, Ontario; Département des Sciences Neurologiques (FE), CHAUQ-Hôpital de l'Enfant-Jésus, Québec, Canada.

RECEIVED OCTOBER 19, 2009. FINAL REVISIONS SUBMITTED DECEMBER 7, 2009.

Correspondence to: Philippe Huot: Toronto Western Research Institute, MP 12-303, Toronto Western Hospital, 399 Bathurst Street, Toronto, Ontario, M5T 2S8, Canada.

and carries a poor prognosis<sup>1,2</sup>. In a retrospective series of 20 children with reversal sign, the mortality rate ranged between 35-70%, and all of the surviving children suffered severe, irreversible brain damage<sup>3</sup>.

The pathophysiology of the reversal sign remains poorly understood. Previous reports have suggested that increased intracranial pressure, leading to impaired cerebral venous outflow and occlusion of the superficial cortical veins, could lead to development of severe oedema and neuronal necrosis in the cortex, hence the term "reverse oedema" sometimes used to refer to the phenomenon<sup>4</sup>. The higher density of the white matter when compared to the surrounding grey matter could be explained by the presence of preserved brain tissue, as well as by petechial haemorrhages and mineralised neurons<sup>3</sup>.

#### REFERENCES

1. Vergote G, Vandepierre H, De Man R. The reversal sign. *Neuroradiology*. 1992;34(3):215-6.
2. Kavanagh EC. The reversal sign. *Radiology*. 2007;245(3):914-5.
3. Han BK, Towbin RB, De Courten-Myers G, Ball WS Jr. Reversal sign on CT: effect of anoxic-ischemic cerebral injury in children. *AJNR Am J Neuroradiol*. 1989;10(6):1191-8.
4. Bird CR, Drayer BP, Gilles FH. Pathophysiology of "reverse" edema in global cerebral ischemia. *AJNR Am J Neuroradiol*. 1989;10(1):95-8.