

Familial paraganglioma

S. M. WHARTON, A. DAVIS

Abstract

Non-secreting paragangliomas are rare tumours usually present in the head and neck. We describe an unusual case of familial paraganglioma with cranial nerve palsies. After exhaustive investigation, a vagal paraganglioma was found and excised. The positive family history of paraganglioma was of significance, although this was only present in one of five generations. The diagnosis and management of non-secreting paragangliomas is discussed.

Key words: Paraganglioma; Vagus nerve; Family

Introduction

Non-secreting paragangliomas (also known as glomus tumours) are rare, largely benign tumours. They are found in many parts of the body, but are commonest in the head and neck region and are familial in about 10 per cent of cases (Coia *et al.*, 1981; Powell *et al.*, 1992; Deshmukh and Horbowyj, 1994). Up to 30 per cent of familial cases develop bilateral tumours (Coia *et al.*, 1981).

Here we describe a case of vagal paraganglioma presenting with cranial nerve palsy. There was a strong family history, but only in one out of five generations. The presentation, management and genetics of this condition are discussed.

Case report

A 59-year-old male presented to the ENT department in June 1992 with a nine-week history of sudden onset hoarse voice and 3 kg weight loss due to dysphagia of solid food. There was no other relevant past history. However, he was noted to have a strong family history of tumours in the neck (Figure 1) which by July were known to be paragangliomas. On examination there was a smooth left thyroid swelling, but no cervical lymphadenopathy. The right vocal fold was paralysed and lying in the paramedian position. There were no other cranial nerve palsies, in particular, the palate moved normally. Further investigation included basic blood tests, thyroid function tests, chest X-ray, barium swallow, thyroid ultrasonography, panendoscopy and bronchoscopy all of which were normal. Computed Tomography (CT) of the chest and neck in October 1992 showed only a slightly bulky left thyroid lobe. No masses associated with cranial nerves were noted. Provisional diagnosis at this point was of a carcinoma of the post-cricoid region, although a paraganglioma was also considered.

By March 1993, he had developed leakage of food through the nose caused by paralysis of the right side of the soft palate. The gag reflex was intact. A magnetic resonance imaging (MRI) scan May, 1993 showed no neuromas nor other abnormalities in the brain stem to account for the symptoms. There were, however, small

patches of high signal in the periventricular region considered to be ischaemic in origin. MRI scan of the neck in January 1994 showed an ovoid mass on the right side at the level of C2. It was situated posterior to the right carotid artery and compressing the internal jugular vein. Carotid angiography showed moderate blushing of the tumour.

At operation a fusiform swelling was found in the superior part of the right vagus nerve and was excised. The

Family History

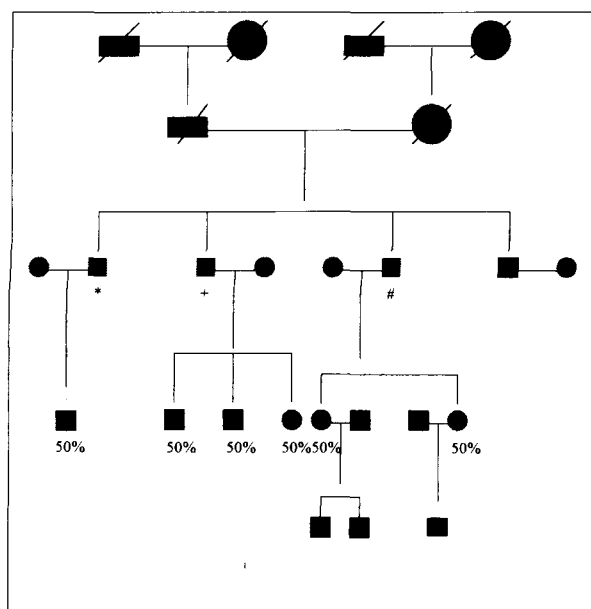


FIG. 1

Diagram showing the patient's family history with affected individuals labelled (* Bilateral carotid body tumours and left vagal paraganglioma, + Bilateral carotid body tumours, # left vagal paraganglioma (the patient). The numbers indicate the risk to the offspring of the affected individuals of carrying the gene for these tumours.

From the Department of Otolaryngology, Head and Neck Surgery, Queen Alexandra Hospital, Cosham, Portsmouth, UK.
Accepted for publication: 5 April 1995.

tumour proved to be a vagal paraganglioma. The patient has recovered well, although requiring Teflon injection into the right vocal fold to reduce aspiration.

Family history

This patient has a moderately large family including three brothers, two older and one younger (Figure 1). There are six children and three grandchildren. The eldest brother has had bilateral carotid body tumours and a left vagal paraganglioma excised, the second has had bilateral carotid body tumours excised. The third brother is the patient in the case report. The youngest brother and all other members of the family have no evidence of disease. However, full examination and investigation of all living members of the family has not been performed by this department.

Discussion

Non-secreting paragangliomas are related to secreting paragangliomas such as pheochromocytomas. The three most common types in order of frequency are: carotid body tumours, glomus jugulare and vagal paragangliomas (van der Mey *et al.*, 1989; Deshmukh and Horbowj, 1994). However, Geysens *et al.* (1989) described glomus jugulare as being more common than carotid body tumours. They are slow growing tumours with histories of 20 years or more (Westbury, 1960; Deshmukh and Horbowj, 1994) being quite common.

Although these tumours are generally benign, malignant change may occur in up to 10 per cent of cases (Granger and Houn, 1990; Powell *et al.*, 1992; Deshmukh and Horbowj, 1994). Histological predictors for malignant change include large cell nests with central necrosis, giant cells with pleomorphic nuclei and vascular invasion (Granger and Houn, 1990). However, some consider that the only certain indicator for metastatic change is the presence of metastases (Granger and Houn, 1990; Powell *et al.*, 1992).

The most common presenting symptoms in patients with these tumours are swelling in the soft tissues of the neck, cranial nerve palsies and dysphagia. Otagia and tinnitus may also be present. Up to 30 per cent of patients have some degree of cranial nerve involvement (Deshmukh and Horbowj, 1994). These tumours are found equally in males and females, although appear to present much earlier in males. In a series of 20 patients, Powell *et al.* (1992) found the median age at presentation in males to be 28 years, but 54 years in females.

Many forms of investigation are of use in the demonstration of these tumours. Most authors recommend the use of high resolution CT (Geysens *et al.*, 1989) and/or carotid angiography (Deshmukh and Horbowj, 1994; Westbury, 1960; Coia *et al.*, 1981). Radionuclide scintangiography has been used to screen large numbers of people (Ruijs *et al.*, 1978). Recently the increasing availability of MRI has stimulated its use in these tumours and it appears to be a useful tool (Deshmukh and Horbowj, 1994; Anderson and Lynch, 1993). In the case presented here, MRI proved invaluable in establishing the diagnosis.

The treatment of paragangliomas (all three types) is essentially either surgery or radiotherapy. Arterial embolisation has been used pre-operatively to shrink all three types of tumour and thus reduce operative risk (Geysens *et al.*, 1989). Complete surgical removal of these tumours is the preferred option. However, they are often intimately associated with either the carotid arteries and other vital structures, or the base of the skull. For this reason they are often not fully excised. In addition, vascular and neurolo-

gical complications are relatively common. Post-operative radiotherapy has been advocated for large tumours with extensive infiltration (Deshmukh and Horbowj, 1994). Primary radiotherapy has been advocated for patients who have inoperable tumours (Powell *et al.*, 1992), particularly glomus jugulare (Coia *et al.*, 1981). It may also be useful in those patients who have significant medical contraindications to surgery (Powell *et al.*, 1992) or have bilateral tumours where the risk of cranial nerve palsies may be high. Part of the problem with assessing the effectiveness of radiotherapy is that the tumours are slow growing and thus any reduction in tumour size or improvement in symptoms is likely to be slow. Powell *et al.*, (1992) estimated that tumour shrinkage occurs in about 70 per cent of cases following radiotherapy, and that this and symptom improvement may be sustained for up to 10 years.

Non-secreting paragangliomas may be familial in up to 50 per cent of cases (van der Mey *et al.*, 1989; Anderson and Lynch, 1993), although most authors say only about 10 per cent are familial (Coia *et al.*, 1981; Powell *et al.*, 1992; Deshmukh and Horbowj, 1994). Where there is a familial tendency, there is an increased incidence of bilateral tumours (Coia *et al.*, 1981). The genetics of this condition suggest that a single gene is responsible and it is autosomal dominant. However, only when the gene is passed down from an affected male to the offspring does the gene become active and the tumours appear. This is thought to be due to deactivation of the gene during oogenesis and reactivation during spermatogenesis, a process called genomic imprinting (van der Mey *et al.*, 1989; Irving *et al.*, 1995). An alternative is that the gene is a tumour suppressor gene which is partially inactivated during spermatogenesis. It is possible, for the gene to skip a generation. In the family presented here only three males from a single generation were affected. No pre-existing affected male carrier was present. Van der Mey *et al.* (1989) described several other families where affected siblings were born to normal parents. In addition, no formal examination or investigation of the other members of the family presented here has been done. Consequently it is possible that other members of the family may have occult tumours. Where there is a positive family history of paraganglioma the incidence of bilateral tumours is upwards of 30 per cent, whereas in non-familial cases less than five per cent are bilateral (Coia *et al.*, 1981; Geysens *et al.*, 1989; van der Mey *et al.*, 1989).

The implications for the later generations in the family presented here are as follows:

Since all those affected in this family are male, all of their offspring have a 50 per cent risk of developing one or more of these tumours, whether they are male or female. If they have not developed a tumour by the age of 45 years then the risk of them subsequently developing a tumour is very low (Geysens *et al.*, 1989).

The daughters of the patient presented here are presently unaffected. Even if they subsequently develop a tumour, then their children are at no risk of developing tumours since the gene is only transmitted if the father is affected. They would, however, be at risk of transmitting the gene onto future generations.

References

- Anderson, R. J., Lynch, H. T. (1993) Familial risk for neuroendocrine tumours. *Current Opinion in Oncology* **5**: 75–84.
- Coia, L. R., Fazekas, J. T., Farb, S. N. (1981) Familial chemodectoma. *International Journal of Radiation and Biological Physics* **7**: 949–952.

- Deshmukh, N., Horbowj, R. (1994) Paraganglioma of the vagus nerve masquerading as a carotid body tumour. *Military Medicine* **159**: 166–168.
- Geysens, P., D'Haenens, P., van Steenberge, R., Wilms, G., Baert, A. L. (1989) Familial occurrence of paragangliomas. *Journal Belge De Radiologie* **72**: 95–99.
- Granger, J. K., Houn, H.-Y. (1990) Bilateral familial carotid body paragangliomas. Report of a case with DNA flow cytometric and cytogenetic analyses. *Archives of Pathology and Laboratory Medicine* **114**: 1272–1275.
- Irving, R. M., Moffat, D. A., Maher, E. R. (1995) Genetics of familial and non-familial skull base tumours. *Clinical Otolaryngology* **20**: 5–11.
- Powell, S., Peters, N., Harmer, C. (1992) Chemodectoma of the head and neck: Results of treatment in 84 patients. *International Journal of Radiation and Biological Physics* **22**: 919–924.
- Ruijs, J. H., van Waas, G., Deltaas, G., Hoekstra, H., Nulder, P. H., Veldman, R. E. (1978) Screening of a family for chemodectoma. *Radiologica Clinica* **42**: 114–123.
- van der Mey, A. G. L., Maaswinkel-Mooy, P. D., Cornelisse, C. J., Schmidt, P. H., van der Kamp, J. J. P. (1989) Genomic imprinting in hereditary glomus tumours: Evidence for new genetic theory. *Lancet* **ii**: 1291–1294.
- Westbury, G. (1960) The management of carotid body tumours with a report of seven cases. *British Journal of Surgery* **47**: 605–611.

Address for correspondence:

Dr S. M. Wharton,
Department of Otolaryngology, Head and Neck Surgery,
Queen Alexandra Hospital,
Cosham,
Portsmouth,
Hants.