

# Comparative pathogenesis of eosinophilic meningitis caused by *Angiostrongylus mackerrasae* and *Angiostrongylus cantonensis* in murine and guinea pig models of human infection

MAHDIS AGHAZADEH<sup>1,2\*</sup>, MARINA C. HARVIE<sup>2†</sup>, HELEN C. OWEN<sup>1†</sup>, CAROLINA VERÍSSIMO<sup>3</sup>, KIERAN V. ALAND<sup>4</sup>, SIMON A. REID<sup>5</sup>, REBECCA J. TRAUB<sup>6</sup>, DONALD P. McMANUS<sup>2</sup>, JAMES S. McCARTHY<sup>2,5</sup> and MALCOLM K. JONES<sup>1,2</sup>

<sup>1</sup> *The University of Queensland, School of Veterinary Science, Gatton, Queensland 4343, Australia*

<sup>2</sup> *QIMR Berghofer Medical Research Institute, Brisbane, Queensland 4006, Australia*

<sup>3</sup> *Laboratório de Biologia Parasitária e Parasitologia Molecular, Pontifícia Universidade Católica do Rio Grande do Sul, Porto Alegre, Brazil*

<sup>4</sup> *Queensland Museum and Sciencentre, Queensland 4101, Australia*

<sup>5</sup> *The University of Queensland, School of Public Health, Herston, QLD 4006, Australia*

<sup>6</sup> *Faculty of Veterinary and Agricultural Sciences, University of Melbourne, Parkville, Victoria 3052, Australia*

(Received 3 February 2016; revised 21 March 2016; accepted 22 March 2016; first published online 9 June 2016)

## SUMMARY

This study investigated comparatively the pathogenicity of experimental infection of mice and guinea pigs, with *Angiostrongylus mackerrasae* and the closely related species *A. cantonensis*. Time course analyses showed that *A. mackerrasae* causes eosinophilic meningitis in these hosts, which suggests that the species has the potential to cause meningitis in humans and domestic animals. Both *A. mackerrasae* and the genetically similar *A. cantonensis* caused eosinophilic meningitis in mice at two time points of 14 and 21 days post infection (dpi). The brain lesions in mice infected with *A. mackerrasae* were more granulomatous in nature and the parasites were more likely to appear degenerate compared with lesions caused by *A. cantonensis*. This may indicate that the mouse immune system eliminates *A. mackerrasae* infection more effectively. The immunologic responses of mice infected with the two *Angiostrongylus* species was compared by assessing *ex vivo* stimulated spleen derived T cells and cytokines including interferon-gamma, interleukin 4 and interleukin 17 on 14 and 21 dpi. The results were similar for mice infected with *A. cantonensis* and *A. mackerrasae*. Serum from the infected animals with either *A. cantonensis* or *A. mackerrasae* recognized total soluble antigen of *A. cantonensis* female worms on Western blot.

**Key words:** *Angiostrongylus mackerrasae*, *Angiostrongylus cantonensis*, *Rattus fuscipes*, rat lungworm, eosinophilic meningitis, angiostrongyliasis.

## INTRODUCTION

Members of the genus *Angiostrongylus* belong to the superfamily Metastrongyloidea, a taxon of nematodes that occupy the circulatory system of their definitive hosts. *Angiostrongylus cantonensis* is the most widespread species of the genus. To date, *A. cantonensis* is the only species of the genus known to cause eosinophilic meningitis in humans and other non-permissive hosts (Wang *et al.* 2008; Graeff-Teixeira *et al.* 2009; Morassutti *et al.* 2012; Cowie, 2013). In severe cases, *A. cantonensis* is reported to cause eosinophilic meningo-encephalomyelitis throughout the brain and spinal cord of accidental hosts (Mason *et al.* 1976; Wright *et al.* 1991; Collins *et al.* 1992)

and fatal encephalitis in humans (Sawanyawisuth *et al.* 2009). Although rare, pneumonia caused by the presence of *A. cantonensis* adult worms has also been reported in humans (Lindo *et al.* 2004).

Two species of *Angiostrongylus* occur in Australia. *Angiostrongylus cantonensis*, a widespread species found in rats throughout the tropical world, occurs in introduced rat species *Rattus rattus* and *Rattus norvegicus* in Eastern Australia. *Angiostrongylus mackerrasae* is restricted to Australia, where it is found mainly in native bush rats, *Rattus fuscipes* (Spratt, 2015). The two species are both neurotropic and have evidently identical lifecycles in the definitive host, tracking to the lungs of its rat hosts (Bhaibulaya, 1974). Despite having an identical lifecycle to *A. cantonensis*, *A. mackerrasae* has been neglected as a potentially zoonotic parasite in Australia.

In recent years, cases of angiostrongyliasis in humans and animals have been reported from Australia (Mackie *et al.* 2013; Morton *et al.* 2013; Walker *et al.* 2015). Recent surveys of the rodent hosts for

\* Corresponding author: Mahdis Aghazadeh, Faculty of Veterinary Science, School of Life and Environment Sciences, The University of Sydney, Camperdown, NSW 2050, Australia. Tel: +61293517083. E-mail: [Mahdis.aghazadeh@sydney.edu.au](mailto:Mahdis.aghazadeh@sydney.edu.au)

† These authors contributed equally to this work.

*Angiostrongylus* (Aghazadeh *et al.* 2015a) and its intermediate host (Chan *et al.* 2015) reveal that species of *Angiostrongylus* are prevalent close to human dwellings. There is a distinct possibility that *A. mackerrasae*, like its congener *A. cantonensis*, causes infections in humans and domestic animals. This postulate is borne out by the recent discovery of adult *A. mackerrasae* from the lung of a flying fox (*Pteropus alecto*), an aberrant host, in which it was found responsible for severe pneumonia (Mackie *et al.* 2013). This study investigates the potential pathogenicity of *A. mackerrasae* to humans by comparing the pathological features of infection in non-permissive hosts (mice and guinea pigs) that are a model for human disease.

#### MATERIAL AND METHODS

##### *Maintaining the lifecycle of A. mackerrasae in the laboratory*

Experimental work was performed with approval of the Animal Ethics Committee of the QIMR Berghofer Medical Research Institute under Project P1457. First stage larvae of *A. mackerrasae* were recovered from the faeces of *R. fuscipes* which were trapped in Southeast Queensland under permit number WIS12109412, from the Department of Environment and Heritage Protection of the Queensland Government. The rats were euthanized and dissected to detect and morphologically confirm the presence of *A. mackerrasae* present in their lungs, using descriptions of Mackerras and Sandars, (1954).

In order to maintain the lifecycle of the parasite in the laboratory, four different species of terrestrial and aquatic molluscs (*Cornua spersum*, *Helix aspersa*, *Planorbis* sp. and *Austropeplea lessoni*) were evaluated to determine the most suitable intermediate host with the recovered larvae in different temperatures ranging between 18 and 26 °C. *Austropeplea lessoni* (Lymnaeidae family) was chosen to maintain the lifecycle due to its less stringent maintenance needs in the laboratory. Snails were infected by immersion in a Petri dish containing first stage larvae of *A. mackerrasae* obtained from infected rats for 4 h. A small piece of tissues from the foot of a snail was fed to Wistar rats 4 weeks after infection with *A. mackerrasae* to maintain the lifecycle in the laboratory.

##### *Infections in mice and guinea pigs*

Snails were digested using artificial gastric juice to obtain infective third-stage larvae (L3) of *A. mackerrasae* 4 weeks after infection. Twenty-four outbred Swiss mice were randomly divided into two groups and infected by oral gavage with 30 third-stage larvae of either *A. mackerrasae* or *A. cantonensis*. The same number of uninfected control mice was also randomly allocated to each group. In addition, four tri-coloured guinea pigs were infected with 35

larvae using clear gelatin capsules directed into their oesophagus using a feline tablet applicator. The animals were monitored daily post infection for changes in behaviour indicative of infection and neurological changes. Four randomly selected mice from the infected and control groups were euthanized at 7, 14 and 21 days post infection (dpi). The infected guinea pigs were euthanized 16 dpi. Brain and spinal cord were removed and stored in 10% formalin for 72 h before histopathological sections were prepared from the tissues. Haematoxylin and eosin-stained paraffin sections were examined blindly using light microscopy in order to avoid bias in scoring. The histopathological lesions of mice and guinea pigs were graded based on a scoring system developed for this study based on (Baums *et al.* 2013) in order to compare the severity of infection caused by the two species of *Angiostrongylus* (see Table 1).

##### *Splenocyte culture and flow cytometry*

Spleens were removed from each mouse and pressed through 70 µm cell strainers (Falcon). Red blood cells were lysed using red blood cell lysing buffer (Sigma-Aldrich) and the remaining live leukocytes were enumerated using the trypan blue exclusion method. Splenic cultures were plated at  $5 \times 10^5$  cells per well and incubated at 37 °C in Iscove's Modified Dulbecco's Medium (IMDM) containing 10% fetal calf serum, penicillin streptomycin, 55 µM betamercaptoethanol with phorbol myristate acetate (PMA) ( $10 \text{ ng mL}^{-1}$ ) and Ionomycin ( $1 \text{ µg mL}^{-1}$ ) in 5% CO<sub>2</sub> flow. After 1 h, brefeldin A was added at  $10 \text{ µg mL}^{-1}$ . Four hours later, cells were harvested and labelled for flow cytometry using anti-mouse CD3-BV510, CD4-Alexa Fluor700, CD8 PE-Cy7 and BD Horizon™ fixable viability stain 450 (all by BD biosciences). Cells were fixed and permeabilized using BD cytofix/Cytoperm buffer and stained for intracellular expression of cytokine using anti mouse interleukin (IL)-17 Alexa Fluor 647, IL-4 PE CF594 and interferon γ (IFNγ)-PerCp Cy5.5 (BD Biosciences). Fluorescence minus one control were also generated. Samples were collected on a BD Fortessa 4 Laser flow cytometer and the results were analysed using FACS DIVA software and GraphPad Prism version 6 using *t*-test and Wilcoxon rank sum tests to determine if any differences between the infected mice and control groups were statistically significant at a 95% level of confidence.

##### *Serological comparison*

*Antigen preparation.* Total soluble extract (TE) was obtained from harvested female worms that were macerated in liquid nitrogen and homogenized extraction buffer [phosphate-buffered saline (PBS; pH 7.4), 0.01% triton X-100 and proteases inhibitors kit (QIAGEN)]. The suspension was centrifuged at

Table 1. Histopathology scoring system used in this study to compare lesions caused by *A. mackerrasae* with those caused by *A. cantonensis* in Swiss mice

Minimal meningitis and/or cuffing	0·5
Mild patchy meningitis with mild perivascular cuffing	1a
Mild to moderate, multifocal or locally extensive meningitis	1b
Mild to moderate, diffuse meningitis	2
Mild to moderate, diffuse meningitis; mild perivascular cuffing in neuropil <b>or</b> small, focal areas of neuropil inflammation/necrosis suggestive of parasite migration	3
Mild to moderate, multifocal or locally extensive to diffuse meningitis; mild perivascular cuffing in neuropil <b>and</b> small, focal areas of neuropil inflammation/necrosis suggestive of parasite migration	4a
Mild to moderate, multifocal or locally extensive to diffuse meningitis; extensive perivascular cuffing in neuropil <b>or</b> extensive areas of neuropil inflammation/necrosis suggestive of parasite migration	4b
Severe, multifocal or locally extensive to diffuse meningitis	4c
Mild to moderate, multifocal or locally extensive to diffuse meningitis; extensive perivascular cuffing in neuropil <b>and</b> extensive areas of neuropil inflammation/necrosis suggestive of parasite migration	5a
Severe, multifocal or locally extensive to diffuse meningitis; mild perivascular cuffing <b>or</b> focal areas of neuropil inflammation/necrosis suggestive of parasite migration	5b
Severe, multifocal or locally extensive to diffuse meningitis; mild perivascular cuffing <b>and</b> focal areas of neuropil inflammation/necrosis suggestive of parasite migration	6a
Severe, multifocal or locally extensive to diffuse meningitis; extensive perivascular cuffing <b>or</b> extensive areas of neuropil inflammation/necrosis suggestive of parasite migration	6b
Areas of really severe meningitis; mild perivascular cuffing <b>or</b> focal areas of neuropil inflammation/necrosis suggestive of parasite migration	6c
Severe, diffuse meningitis; extensive perivascular cuffing <b>and</b> extensive areas of neuropil inflammation/necrosis suggestive of parasite migration	7

12 000 g for 1 h at 4 °C, and the supernatants were used to derive the TE protein concentrations was determined by Bradford assay according to the instructions of the manufacturer. TE from male worms was produced as described above.

*Sodium dodecyl sulphate-polyacrylamide gel electrophoresis (SDS-PAGE) and Western blots (WB).* One-dimensional electrophoresis of 4–12% polyacrylamide Bis-Tris gels with SDS-PAGE was used to resolve proteins of TE, which were then stained with Coomassie Brilliant Blue. For the WB resolved 100 ng, 1 µg or 3 µg of TE were electro-transferred onto nitrocellulose membranes, and then blocked with 5% powdered milk for 2 h at room temperature. The membranes were then incubated for 2 h with different sera: (1) pool of human sera (1:200 dilution), prepared from three patients diagnosed with cerebral angiostrongyliasis; (2) rat sera (1:200 dilution); and (3) guinea pig sera (1:200 dilution). After three washes, the membranes were probed with a secondary peroxidase-conjugated anti-human IgG (1:5000; Abcam, Cambridge, UK), anti-Rat IgG (1:5000; Abcam, Cambridge, UK) or anti-guinea pig IgG (1:5000; Abcam, Cambridge, UK) for 2 h at room temperature. After three washes of PBS Tween 0·05%, Clarity Western ECL Blotting Substrate (Biorad) was added.

## RESULTS

### *A. mackerrasae* infections in mice

Grossly, hyperaemia was observed on the surface of the brain tissue in all infected mice. The first group

of mice, euthanized 7 dpi, did not show any clinical neurological signs and the inflammatory reaction to the parasite was mild. Of the four mice in this group, two showed minimal meningitis and/or perivascular cuffing in the neuropil. *Angiostrongylus* larvae were present in the neuropil in two of the mice. The second group of four mice, euthanized 14 dpi, all showed moderate to marked diffuse eosinophilic meningitis with intralesional nematodes in three out of four of the mice (Fig. 3A). Multifocal, mild eosinophilic encephalitis was also observed in two out of four of these mice. In the group of mice euthanized 21 dpi, there was diffuse moderate to marked eosinophilic and granulomatous meningitis. Some nematodes appeared viable; however, degenerate parasites were also noted and were often associated with areas of granulomatous meningitis.

### *A. cantonensis* infection in mice

Most of the infected animals showed variable degrees of pathological changes in the brain tissue. The mice euthanized on 7 dpi, showed mild patchy meningitis with mild perivascular cuffing. Small numbers of viable parasite were seen in focal area of the brain in one mouse. In the second group of mice euthanized on 14 dpi, eosinophilic meningitis was observed in all mice and moderate numbers (at least three per section) of parasites were present in multiple locations in the meninges (Fig. 3B). In the group of mice euthanized on 21 dpi, moderate to severe eosinophilic meningitis was observed in all mice (Table 2). Small numbers of viable parasites were noted in three out of four of the mice.



Table 2. Histopathological scores of Swiss mice infected with the two species of *Angiostrongylus*

Time post infection	<i>A. cantonensis</i>	<i>A. mackerrasae</i>
Week 1	0.5 to 1b (0.5, 1a, 1b, 1b)	0 to 0.5 (0, 0, 0.5, 0.5)
Week 2	4a to 7 (4a, 4a, 6c, 7)	6a to 7 (6a, 6a, 6a, 7)
Week 3	5b to 7 (5b, 6a, 6c, 7)	5b to 7 (5b, 6a, 7, 7)

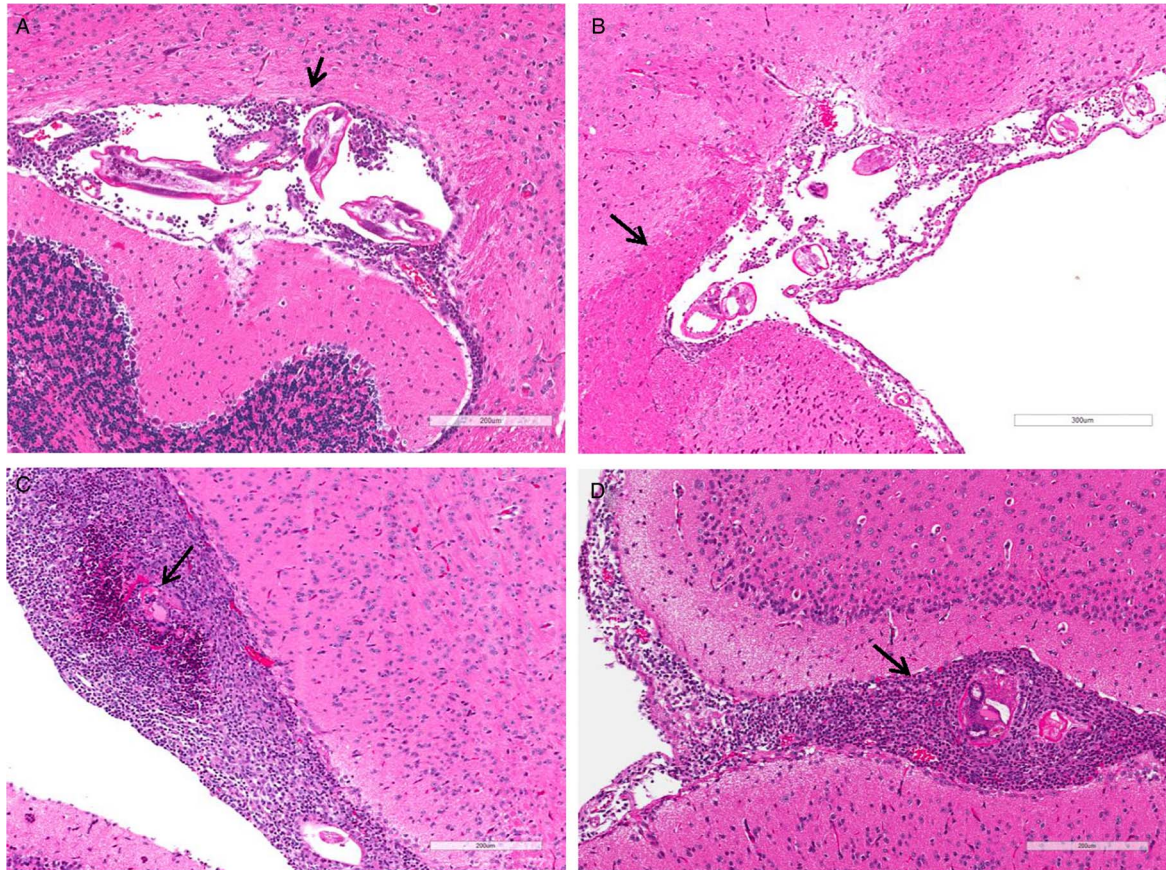


Fig. 1. Pathological section of mice brain tissue infected with *A. mackerrasae* and *A. cantonensis* 2 weeks (A, B) and 3 weeks (C, D) post infection. Arrow points at larvae.

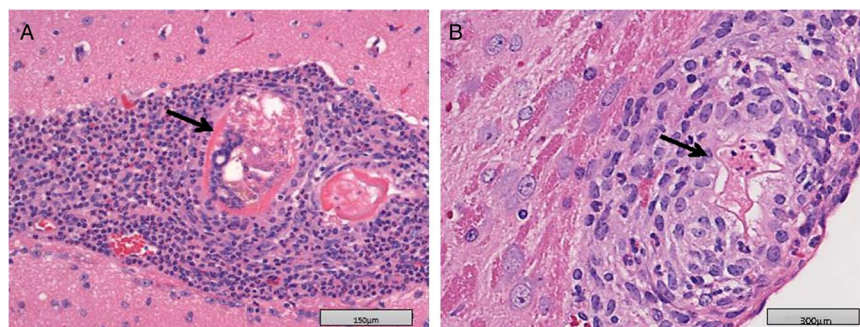


Fig. 2. Pathological section of mice brain tissue infected with *A. mackerrasae* and *A. cantonensis* and 3 weeks post infection. *A. cantonensis* larvae is still viable 3 weeks post infection (A); Degenerated larvae of *A. mackerrasae* 3 weeks post infection (B).

*Comparing pathogenicity caused by the two Angiostrongylus species*

The group of 12 mice infected with *A. cantonensis*, showed brain lesions similar to those observed in *A. mackerrasae*-infected mice. The comparison

between the two groups of mice infected with *A. cantonensis* and *A. mackerrasae* revealed that the two species cause similar lesions of similar severity in infected Swiss mice (Table 1; Figs 1 and 2). There were small points of difference however,



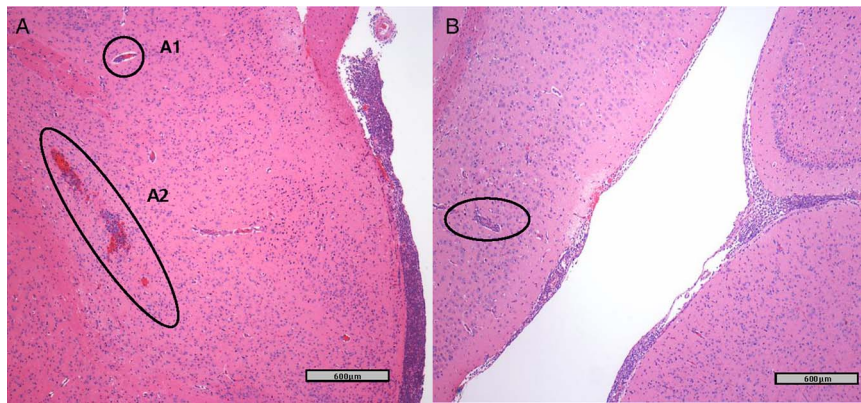


Fig. 3. Grade 7 infection with *A. mackerrasae* in mice 2 weeks post infection (A) A1: Perivascular cuffing, A2: Larvae migration track. Grade 4a infection with *A. cantonensis* in mice 2 weeks post infection; perivascular cuffing (B).

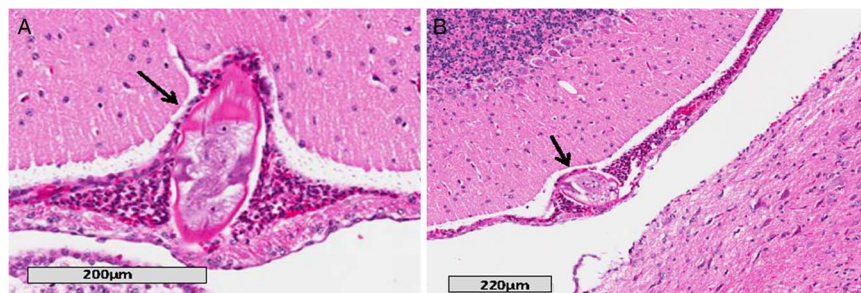


Fig. 4. Eosinophilic meningitis in infected guinea pigs with *Angiostrongylus mackerrasae*, 16 dpi. (A, B) Larvae of *A. mackerrasae* in cerebral meninges surrounded by inflammatory cells.

including a more rapid development of meningitis in the *A. cantonensis*-infected mice. Moreover, the mice infected with *A. mackerrasae* developed meningitis of a more granulomatous nature, particularly at week 3 post infection, which was associated with an increased proportion of degenerate larvae in the *A. mackerrasae*-infected mice.

#### *A. mackerrasae* infections in guinea pigs

All infected guinea pigs also showed various degrees of pathological changes (scored between 1b to 4c) in the brain sections. Larvae of *A. mackerrasae* were present in the meninges of all four animals. Within the cerebral and cerebellar meninges and variably the nerve root meninges and stroma of the choroid plexus, there were multifocal, moderate to dense populations of eosinophils, lymphocytes and macrophages in all four animals (Fig. 4). As opposed to mice, no changes were observed in cerebral neuropil and the inflammation was limited to meninges.

#### Flow cytometry analysis

The results of flow cytometric analysis of splenocyte cultures from *Angiostrongylus*-infected mice are summarized in Table 3. Data values obtained from unstimulated media only control samples were

subtracted from the values measured of PMA/Ionomycin re-stimulated samples to give the percentage values reported in Table 3.

Comparison of the T cell counts and cytokines showed almost no significant differences between infected (both species) and control groups. *Angiostrongylus cantonensis*-infected mice showed decreased numbers of splenic T cells both at 2 weeks and 2 weeks post infection in comparison with the control group. Mice infected with *A. mackerrasae* showed decreased splenic T cells 2 weeks post infection but the number of cells increased after 3 weeks. In *A. cantonensis*-infected mice, significant differences included the decreased level of CD4 IL-4 ( $P = 0.049$ ), 2 weeks post-infection, decreased expression of CD8 IL-17 ( $P = 0.041$ ) 3 weeks post infection and the reduction of CD8 IFN- $\gamma$  levels ( $P = 0.021$ ) 3 weeks post infection in comparison to the uninfected control group. There was no significant cytokine variations observed between mice infected with *A. mackerrasae* and the control group. The percentage of stimulated CD4 T cells in *A. mackerrasae*-infected mice was significantly lower ( $P = 0.03$ ) than the control group 2 weeks post infection. In addition, the percentage of stimulated CD4 and CD8 T cells were significantly higher in *A. mackerrasae*-infected mice 3 weeks post infection ( $P = 0.01$  and  $0.04$ , respectively).

Table 3. Flow cytometry analysis of splenic T cells in mice infected with *A. mackerrasae* and *A. cantonensis* on 14 and 21 dpi

	Week 2 PI (%)				Week 3 PI (%)			
	A.m.		A.c.		A.m.		A.c.	
	Control	Infected	Control	Infected	Control	Infected	Control	Infected
<b>CD4<sup>+</sup></b>								
IL-4	0.5500 ± 0.29	1.275 ± 0.89	<b>0.1500 ± 0.02<sup>a</sup></b>	<b>0.0500 ± 0.02</b>	0.5800 ± 0.33	0.1200 ± 0.09	1.300 ± 0.38	0.6250 ± 0.10
IL-17	0.1000 ± 0.040	0.2000 ± 0.14	0.1250 ± 0.094	0.1000 ± 0.057	—	—	0.8250 ± 0.27	0.2750 ± 0.15
IFN- $\gamma$	0.4000 ± 0.33	0.2250 ± 0.14	0.3500 ± 0.12	0.1250 ± 0.094	0.6400 ± 0.34	0.0200 ± 0.02	2.125 ± 0.56	1.900 ± 0.17
Total	<b>62.03 ± 5.94</b>	<b>37.75 ± 6.79</b>	49.68 ± 7.24	64.60 ± 6.58	<b>11.86 ± 2.24</b>	<b>48.26 ± 10.95</b>	24.05 ± 5.62	31.85 ± 2.25
<b>CD8<sup>+</sup></b>								
IL-4	0.4250 ± 0.246	1.400 ± 0.94	0.0250 ± 0.02	0.0250 ± 0.02	0.9000 ± 0.61	0.4400 ± 0.25	0.9750 ± 0.59	0.3500 ± 0.19
IL-17	—	—	0.2000 ± 0.13	0.0750 ± 0.047	—	—	<b>0.7750 ± 0.14</b>	<b>0.2500 ± 0.14</b>
IFN- $\gamma$	1.400 ± 1.04	2.800 ± 1.33	0.1750 ± 0.08	0.5000 ± 0.33	0.3600 ± 0.24	0.7400 ± 0.66	<b>1.700 ± 0.36</b>	<b>0.5000 ± 0.20</b>
Total	12.70 ± 2.14	13.03 ± 5.33	14.93 ± 1.58	18.78 ± 2.39	<b>2.500 ± 0.72</b>	<b>6.520 ± 1.47</b>	3.150 ± 1.31	6.600 ± 0.94

A.m., *Angiostrongylus mackerrasae*; A.c., *Angiostrongylus cantonensis*, PI, post infection.  
<sup>a</sup> Significantly different values are bolded.

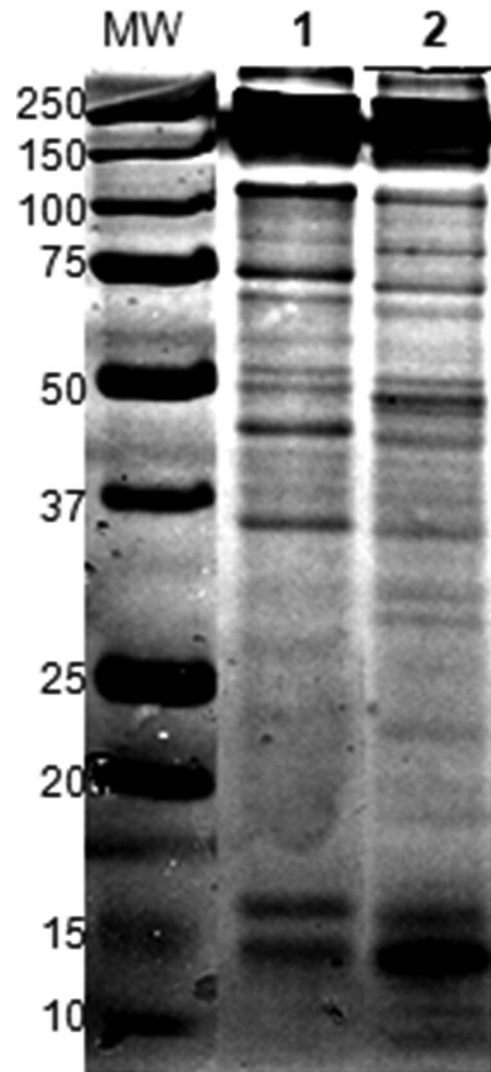


Fig. 5. SDS-PAGE of *A. mackerrasae* worms soluble total extract (TE). 1: *A. mackerrasae* female; 2: *A. mackerrasae* Male. MW: Molecular weight (kDa).

*SDS-PAGE and WBs*

The TE from female *A. mackerrasae*, female *A. cantonensis* (Australian strain), male *A. mackerrasae* and female *A. cantonensis* (Brazilian strain) all showed similar recognition at 31 kDa band to the serum from a human infected with *A. cantonensis* from Brazil (positive control), serum from experimentally infected rats and guinea pigs (Figs 5 and 6).

DISCUSSION

This research demonstrates for the first time that *A. mackerrasae* can cause severe meningitis in infected mice and guinea pigs, which is an indication that it may be pathogenic in humans, dogs and other animals. The lesions caused by *A. mackerrasae* in this study were consistent with those caused by *A. cantonensis* in humans (John and Martinez, 1975) as well as with lesions noted in previous work on guinea pigs (Perez *et al.* 1989) and mice (Sugaya

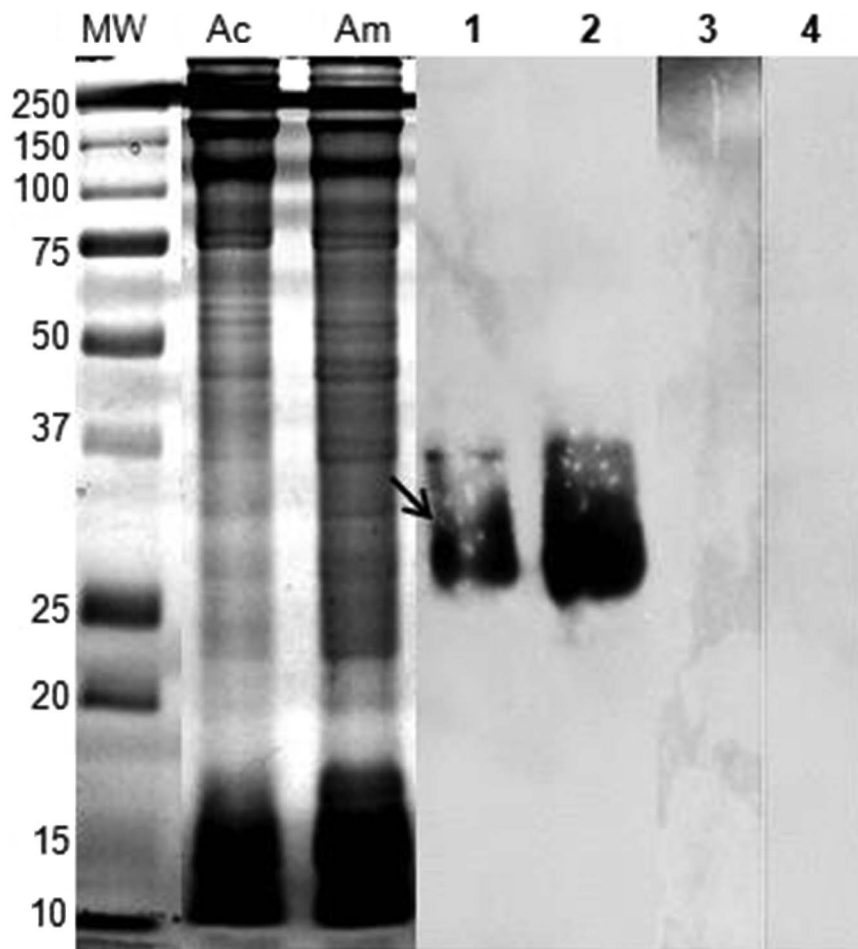


Fig. 6. Identification of 31 kDa antigen produced by *A. mackerrasae*. Female worm soluble total extract (TE) from Australian *A. cantonensis* (Ac) and *A. mackerrasae* (Am) were resolved in 1DE gel and transferred on Western blot membranes. Lane 1: Ac-TE and Lane 2: Am-TE, probed with pool of positive controls for cerebral angiostrongyliasis (from Brazil); Lane 3: Ac-TE and Lane 4: Am-TE, probed with pool of normal human sera (100 ng TE per lane).

and Yoshimura, 1988) infected with *A. cantonensis*. This result was expected as molecular comparison of *A. mackerrasae* with *A. cantonensis* showed that the two species share highly similar genetic identity (Aghazadeh *et al.* 2015b). However, the result indicates that *A. cantonensis* endures for a longer time in the brain of accidental hosts than previously reported. Although *A. mackerrasae* is genetically very similar to *A. cantonensis*, it naturally has a different host choice (native *Rattus* spp.) and it caused a more severe immune response in mice in this study. This suggests that infection caused by *A. mackerrasae* could have a different clinical outcome in humans and other accidental hosts.

Our study showed minimal cytokine activity attributable to *Angiostrongylus* infection. The percentages of IL-17 and IFN- $\gamma$  producing cells were lower in mice infected with *A. cantonensis* compared with uninfected mice in this study, consistent with the observations of Liu *et al.* (2013). This was also observed with *A. mackerrasae*-infected mice but only 3 weeks post infection. IL-17 and IFN- $\gamma$  both act as mediators in delayed type immune responses to extracellular pathogens and both are expected to

be increased in parasitic eosinophilic meningitis. Liu *et al.* (2013) speculated that the reduction of splenic IL-17 in *A. cantonensis* infection might be induced by high expression of IL-4 restricting IL-17 secretion. However, in this study IL-4 was not highly expressed in the infected mice. Sugaya *et al.* (1997) also detected a peak of IL-4 in cerebrospinal fluid of BALB/c and C57BL/6 mice on 12–15 and 20 dpi by *A. cantonensis*, but they did not study the levels of IL-17. In the present study, IL-4 was decreased at both time points in *A. cantonensis* group but CD4 IL-4 was only increased on 14 dpi in *A. mackerrasae* group. It must be noted that *A. mackerrasae*-infected animals showed slightly less pathology at this time point, which could be attributable to this difference in IL-4 production although the percentage of cells producing it is very small.

Parasites are known to actively evade the host immune responses to ensure their ongoing survival and proliferation (Schmid-Hempel, 2009). The subdued immune responses measured in this study may suggest that the parasites themselves are able to down-regulate or dampen the host immune response in some way, although the data collected



cannot confirm this. Factors such as number of larvae used to induce infection, the time post infection, mouse strain and the involvement of brain blood barrier (the brain as an immune privileged site) could also be responsible for the variation of cytokine expression in different studies. It is therefore plausible to suggest that splenic T cells and expressed cytokines in this instance could not give a clear picture of the intensity of immune response to this parasite.

This study also reveals that both proteins of *A. cantonensis* and *A. mackerrasae* are recognized by positive sera of cerebral angiostrongyliasis patients. The 31 kDa band previously described (Morassutti *et al.* 2012) from *A. cantonensis* was also observed from *A. mackerrasae*, indicating that the two species express a set of very similar proteins. Previously, Ben *et al.* (2010) demonstrated the successful use of heterologous antigens in immune diagnosis of angiostrongyliasis (*A. cantonensis* and *A. costaricensis*), and Morassutti *et al.* (2012) corroborated these data showing that the 31 kDa antigen from *A. cantonensis* TE is recognized both by sera from patients with eosinophilic meningitis and abdominal angiostrongyliasis, indicating that both species of parasites produce very similar antigens although the pathology caused by each of these two species are different. Here we found that another species of *Angiostrongylus*, *A. mackerrasae* can also be recognized by sera from human cases of eosinophilic meningitis caused by *A. cantonensis*. The cross reactivity observed between *A. cantonensis* and *A. mackerrasae* was expected. However, further research is required to determine whether *A. mackerrasae* can potentially infect humans and other animals and cause a pathogenic effect. Investigating its ability to develop to patency in humans is also a priority.

#### ACKNOWLEDGEMENTS

The authors would like to thank Dr Rogan Lee from University of Sydney and Dr John Stanic from Queensland Museum and Mr David McNeilly from QIMR Berghofer Medical Research Institute for their help and support during this study.

#### FINANCIAL SUPPORT

M. A. was supported by a University of Queensland Postgraduate Award. This research was supported by Peter and Mary Ellen Stone Memorial Fund, awarded to Malcolm Jones.

#### CONFLICT OF INTEREST

None.

#### REFERENCES

Aghazadeh, M., Reid, S. A., Aland, K. V., Restrepo, A. C., Traub, R. J., McCarthy, J. S. and Jones, M. K. (2015a). A survey of *Angiostrongylus*

- species in definitive hosts in Queensland. *International Journal for Parasitology: Parasites and Wildlife* **4**, 323–328.
- Aghazadeh, M., Traub, R. J., Mohandas, N., Aland, K. V., Reid, S. A., McCarthy, J. S. and Jones, M. K. (2015b). The mitochondrial genome of *Angiostrongylus mackerrasae* as a basis for molecular, epidemiological and population genetic studies. *Parasites and Vectors* **8**, 473.
- Baums, C. G., Hermeyer, K., Leimbach, S., Adamek, M., Czerny, C. P., Horstgen-Schwark, G., Valentin-Weigand, P., Baumgartner, W. and Steinhagen, D. (2013). Establishment of a model of *Streptococcus iniae* meningoencephalitis in Nile tilapia (*Oreochromis niloticus*). *Journal of Comparative Pathology* **149**, 94–102.
- Ben, R., Rodrigues, R., Agostini, A. A. and Graeff-Teixeira, C. (2010). Use of heterologous antigens for the immunodiagnosis of abdominal angiostrongyliasis by an enzyme-linked immunosorbent assay. *Memorias do Instituto Oswaldo Cruz* **105**, 914–917.
- Bhaibulaya, M. (1974). Experimental hybridization of *Angiostrongylus mackerrasae*, Bhaibulaya, 1968 and *Angiostrongylus cantonensis* (Chen, 1935). *International Journal for Parasitology* **4**, 567–573.
- Chan, D., Barratt, J., Roberts, T., Lee, R., Shea, M., Marriott, D., Harkness, J., Malik, R., Jones, M., Aghazadeh, M., Ellis, J. and Stark, D. (2015). The Prevalence of *Angiostrongylus cantonensis*/*mackerrasae* Complex in Molluscs from the Sydney Region. *PLoS ONE* **10**, e0128128.
- Collins, G. H., Rothwell, T. L., Malik, R., Church, D. B. and Dowden, M. K. (1992). Angiostrongylosis in dogs in Sydney. *Australian Veterinary Journal* **69**, 170–171.
- Cowie, R. H. (2013). Biology, systematics, life cycle, and distribution of *Angiostrongylus cantonensis*, the cause of rat lungworm disease. *Hawaii Journal of Medicine and Public Health* **72**, 6–9.
- Graeff-Teixeira, C., da Silva, A. C. and Yoshimura, K. (2009). Update on eosinophilic meningoencephalitis and its clinical relevance. *Clinical Microbiology Reviews* **22**, 322–348.
- John, D. T. and Martinez, A. J. (1975). Animal model of human disease. Central nervous system infection with the nematode *Angiostrongylus cantonensis*. *American Journal of Pathology* **80**, 345–348.
- Lindo, J. F., Escoffery, C. T., Reid, B., Codrington, G., Cunningham-Myrie, C. and Eberhard, M. L. (2004). Fatal autochthonous eosinophilic meningitis in a Jamaican child caused by *Angiostrongylus cantonensis*. *American Journal of Tropical Medicine and Hygiene* **70**, 425–428.
- Liu, H., Luo, X., Shen, E., Li, H., Ding, X. and Chen, D. (2013). Alteration of T cell subtypes in spleen and antibodies of serum in mice infected with *Angiostrongylus cantonensis*. *Parasitology Research* **112**, 1255–1260.
- Mackerras, M. J. and Sandars, D. F. (1954). Lifehistory of the rat lungworm and its migration through the brain of its host. *Nature* **173**, 956–957.
- Mackie, J., Lacasse, C. and Spratt, D. (2013). Patent *Angiostrongylus mackerrasae* infection in a black flying fox (*Pteropus alecto*). *Australian Veterinary Journal* **91**, 366–367.
- Mason, K. V., Prescott, C. W., Kelly, W. R. and Waddell, A. H. (1976). Letter: granulomatous encephalomyelitis of puppies due to *Angiostrongylus cantonensis*. *Australian Veterinary Journal* **52**, 295.
- Morassutti, A. L., Levert, K., Perelygin, A., da Silva, A. J., Wilkins, P. and Graeff-Teixeira, C. (2012). The 31-kDa Antigen of *Angiostrongylus cantonensis* Comprises Distinct Antigenic Glycoproteins. *Vector-Borne and Zoonotic Diseases* **12**, 961–968.
- Morton, N. J., Britton, P., Palasanthiran, P., Bye, A., Sugo, E., Kesson, A., Ardern-Holmes, S. and Snelling, T. L. (2013). Severe hemorrhagic Meningoencephalitis due to *Angiostrongylus cantonensis* among young children in Sydney, Australia. *Clinical Infectious Diseases* **57**, 1158–1161.
- Perez, O., Capron, M., Lastre, M., Venge, P., Khalife, J. and Capron, A. (1989). *Angiostrongylus cantonensis*: role of eosinophils in the neurotoxic syndrome (Gordon-like phenomenon). *Experimental Parasitology* **68**, 403–413.
- Sawanyawisuth, K., Takahashi, K., Hoshuyama, T., Senthong, V., Limpawattana, P., Intapan, P. M., Wilson, D., Tiampakao, S., Jitpimolmard, S. and Chotmongkol, V. (2009). Clinical factors predictive of encephalitis caused by *Angiostrongylus cantonensis*. *American Journal of Tropical Medicine and Hygiene* **81**, 698–701.
- Schmid-Hempel, P. (2009). Immune defence, parasite evasion strategies and their relevance for ‘macroscopic phenomena’ such as virulence. *Philosophical Transactions of the Royal Society: Biological Sciences* **364**, 85–98.
- Spratt, D. M. (2015). Species of *Angiostrongylus* (Nematoda: Metastrongyloidea) in wildlife: a review. *International Journal of Parasitology: Parasites and Wildlife* **4**, 178–189.
- Sugaya, H. and Yoshimura, K. (1988). T-cell-dependent eosinophilia in the cerebrospinal fluid of the mouse infected with *Angiostrongylus cantonensis*. *Parasite Immunology* **10**, 127–138.



**Sugaya, H., Aoki, M., Abe, T., Ishida, K. and Yoshimura, K.** (1997). Cytokine responses in mice infected with *Angiostrongylus cantonensis*. *Parasitology Research* **83**, 10–15.

**Walker, A.G., Spielman, D., Malik, R., Graham, K., Ralph, E., Linton, M. and Ward, M.P.** (2015). Canine neural angiostrongylosis: a case-control study in Sydney dogs. *Australian Veterinary Journal* **93**, 195–199.

**Wang, Q.P., Lai, D.H., Zhu, X.Q., Chen, X.G. and Lun, Z.R.** (2008). Human angiostrongyliasis. *Lancet Infectious Diseases* **8**, 621–630.

**Wright, J.D., Kelly, W.R., Waddell, A.H. and Hamilton, J.** (1991). Equine neural angiostrongylosis. *Australian Veterinary Journal* **68**, 58–60.