

Clinical Records

Conductive hearing loss: investigation of possible inner ear origin in three cases studies

HAMAD AL MUHAIMEED, M.D., YOUSRY EL SAYED, F.R.C.S., ABDULRAHMAN RABAH, F.R.C.S., ABDULRAHMAN AL-ESSA, M.D.

Abstract

This is a report of three cases of mixed hearing loss that resulted from inner ear disorders. Two cases were unilateral and the third was bilateral. The diagnosis was based on the findings of normal middle and external ears in association with the absence of round window reflexes. The contralateral stapedial reflex was present in the two unilateral cases. This is the first documentation of conductive deafness due to inner ear abnormality. This diagnosis should be considered in cases of conductive hearing loss if the middle and external ears are normal. More studies are needed to establish the pathophysiology of this entity.

Key words: Hearing Loss, Conductive; Hearing Loss, Sensorineural; Causation

Introduction

The cochlea performs two functions in the hearing mechanism. The first function is transmission of sound energy that is induced by the movement of the stapes footplate from the oval window to the basilar membrane. The sound waves travel through the perilymph from the scala vestibuli to the scala tympani via the helicotrema and vibrate the basilar membrane. The second function is transduction of the mechanical (acoustic) energy into electrical (neural) energy that is initiated by the deformation of the outer and inner hair cells of the organ of Corti.

Lesions of the hair cells will cause sensorineural hearing loss, which is the usual manifestation of cochlear disorders. On the other hand, lesions in the scala vestibuli, helicotrema, scala tympani or in the basilar membrane, which may interfere with vibration of the latter, will cause conductive hearing loss. This type of conductive hearing loss will be characterized by an absent round window reflex in addition to a normal contralateral stapedial reflex (if the other ear is normal) because of the normal external and middle ears.

The concept of inner ear conductive hearing loss was proposed as early as the 1960s by Gloris and Davis¹ and by Nixon and Glorig.² They proposed stiffness of the cochlear partition as a possible cause. Shea as quoted by Donaldson and Snyder³ found that inner ear conductive hearing loss occurs in one in 700 patients with otosclerosis.

In this paper, the authors report three cases diagnosed as inner ear mixed (mainly conductive) hearing loss.

Method

The hearing of the three cases was assessed using the following test techniques:

From the Department of Otorhinolaryngology, King Abdul Aziz University Hospital, Riyadh, Saudi Arabia.
Accepted for publication: 30 April 2002.

(1) Pure tone audiometry

The audiometer used was a GSI 10, calibrated to the American National Institute, 1969.⁴ The test frequencies were from 250 to 8000 Hz. The criteria used to determine deafness was a hearing loss greater than 20 dB HL at two or more frequencies. They were the same as those used by Todd *et al.* 1973⁵ and Odetoyinbo and Adikile 1987,⁶ based on the standards set by the American Academy of Ophthalmology and Otolaryngology in 1959.

Hood's plateau method⁷ was employed. Noise is presented to the non-test ear while a pure tone is presented to the test ear. If the patient responds, masking is increased in discrete steps until an increase in noise no longer produces a shift in threshold. The plateau level is accepted as threshold.

(2) Tympanometry

The tympanometer used was a Grayson Stadler GSI 28 middle ear analyser. Jerger's differentiation of the tympanogram into type A, B and C (Jerger and Jerger 1980)⁸ was employed to analyse the study data. An abnormality in the contralateral acoustic reflex threshold was considered elevated if the acoustic reflex threshold was 110 dB or greater at two or more frequencies from 500 through 2000 Hz.

(3) Auditory brain stem response

The machine used was a Nicolet Spirit. Averaged clicks were used for stimulation and vertex to ipsilateral ear lobule derivation was used for recording. The response threshold, waves amplitude, absolute peak latencies for waves I, III, V, as well as interpeak latencies I–III, III–V, and latency intensity curve for wave V at 80 dB, 60 dB,

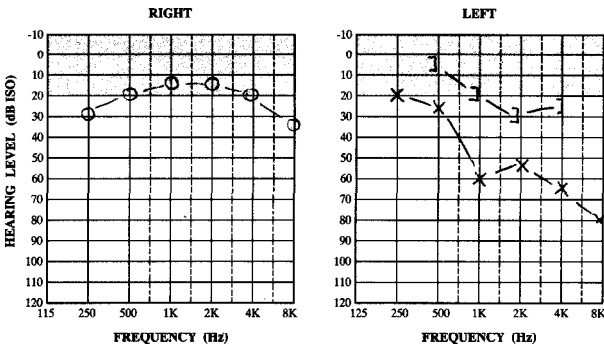


FIG. 1
Pure tone audiometry Case 1.

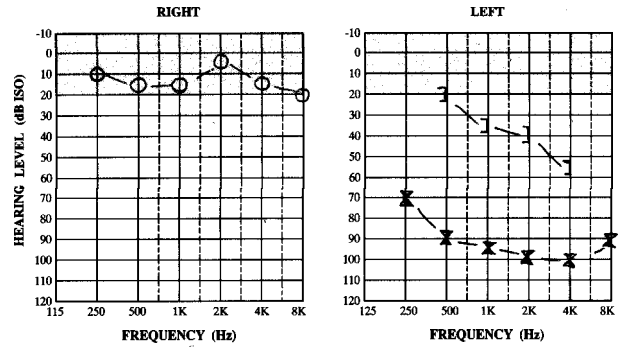


FIG. 3
Pure tone audiometry Case 2.

40 dB and 20 dB were used for interpretation. Conductive hearing loss was diagnosed when the latency of all waves was shifted with normal interpeak latencies and the intensity latency curve of wave V was parallel to the normal range.⁹

(4) Round window reflex

The round window reflex was assessed into two ways: (a) by gently striking the handle of malleus with a needle and visualizing the light reflection of the blood spot at the round window niche; (b) by gentle application of pressure with a needle to the incudo stapedial joint and visualizing the light reflex of the blood spot at the round window niche.

Case reports

Case 1

A 10-year-old boy was found to have a left ear hearing impairment during a routine school-hearing test. There was no history of trauma, ear infections and no family history of hearing loss. Otoscopy showed normal auditory canals and tympanic membranes. Tuning fork tests (using 521 Hz frequency) showed the Rinne test to be positive in the right and negative in the left. The Weber test was referred to the left side. Pure tone audiometry using a GSI 10 audiometer is shown in Figure 1. Tympanometry and impedance measurements using a GSI 28 tympanometer are shown in Figure 2. The ipsilateral stapedial reflex was absent in the left side and present (at 85 dB HL using 1000 Hz) in the right side. The contralateral stapedial reflex was elicited in the left ear. Computed tomography (CT) scan of the temporal bone showed no abnormalities in the cochlea or cochlear aqueduct and no radiological signs of cholesteatoma.

The provisional diagnosis was ossicular disruption medial to the neck of the stapes (to explain the presence of the contralateral stapedial reflex). Left tympanotomy, showed an intact and mobile ossicular chain with normal footplate movement, however, the round window reflex

was negative. Post-operatively, pure tone audiometry was the same. The auditory brainstem evoked response was carried out and confirmed the conductive nature of the hearing loss. It showed the threshold of hearing to be 50 dB HL with a shifting in the latency of all the waves and the intensity latency curve of wave V was parallel to the normal range.

Case 2

A 20-year-old girl presented with a history of progressive left hearing impairment for five years. There was no history of ear discharge, tinnitus or vertigo. The patient denied any history of trauma. The family history was negative for the same problem. Upon otoscopy both ear canals and tympanic membranes looked normal. Tuning fork tests (of 512 Hz frequency) were consistent with left conductive hearing loss. Pure tone audiometry is shown in Figure 3 and tympanometry is illustrated in Figure 4. The contralateral stapedius reflex was elicited in the left ear at a level of 85 dB HL using a stimulus of 1000 Hz. High resolution CT scan showed normal middle and inner ears. Tympanometry showed normal findings apart from a failure to elicit the round window reflex. The evoked brainstem test was carried out and it showed the threshold of hearing to be 80 dB HL with a shifting in the latency of all the waves. The intensity latency curve of wave V was parallel to the normal range.

Case 3

A 38-year-old man had presented with bilateral hearing loss with tinnitus for two years. The patient denied any history of ear discharge, vertigo or trauma. Drug and family histories were negative. Otoscopy showed normal ear canal and tympanic membranes. Rinne's test was negative bilaterally and Weber's test was central. Pure tone audiometry and tympanometry are shown in Figures 5 and 6. Right tympanometry showed a normal mobile ossicular chain but the round window reflex could not be elicited. High resolution CT scan of both cochleas did not reveal any abnormality and normal auditory canals.




FIG. 2
Tympanometry and impedance measurement Case 1.

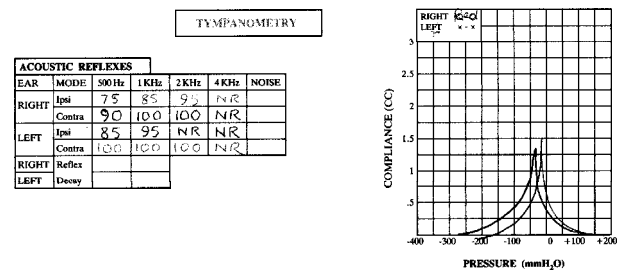


FIG. 4
Tympanometry and impedance measurement Case 2.

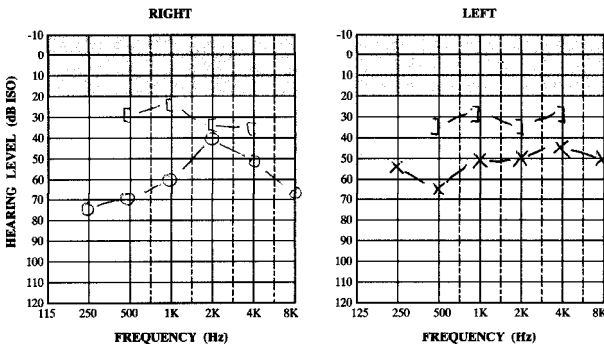


FIG. 5

Pure tone audiometry Case 3.

Discussion

Lesions of the external and the middle ears affecting the sound conduction and/or the transformer functions manifest as conductive hearing loss. Lesions affecting the hair cells of the cochlea manifest as sensorineural hearing loss due to impairment of the transduction function of the ear. However, if there is a lesion in the inner ear that spares the hair cells and affects only the scala vestibuli, helicotrema, scala tympani, or the basilar membrane, it may manifest as a conductive hearing loss since only the sound conduction mechanism is impaired.

The diagnosis and treatment of conductive hearing loss due to external or middle ear abnormalities are well documented and include clinical, audiological, radiological and on occasions histopathological examination. On the other hand, the diagnosis of inner ear conductive hearing loss is not an easy task due to inaccessibility of the inner ear structure to clinical, histopathological or surgical examination.

The conductive nature of the hearing loss should be established by clinical and electrophysiological tests. Inorganic deafness and sensorineural hearing loss (with Bhowd' bone conduction reading) should be excluded. Likewise, lesions of the external and middle ears should be excluded by all available means including tympanotomy.

The three cases presented here are of young patients with mainly conductive hearing loss, normal ossicular chain movement, and an absent round window reflex. The conductive nature of the hearing loss has been confirmed by repeated tuning fork tests, pure tone audiometry with the use of appropriate masking, and auditory-evoked brainstem responses. The presence of a stapedial reflex in the first two cases (with the stimulus applied to the normal ear in order to reach the reflex threshold) indicates objectively that the pathology lies medial to the insertion of the stapedius muscle. The contra-lateral stapedial reflex in the third cases was negative due to bilateral pathology. The presence of the contralateral stapedius reflex in unilateral cases may be caused by a fractured crura of the stapes, or ossicular disruption in the presence of soft tissue connection between the stapes and the incus. However, surgical exploration had excluded these possibilities as well as other middle-ear abnormalities such as congenital cholesteatoma. Auditory brainstem evoke responses are consistent with the conductive nature of hearing loss through the elevated threshold of hearing to 50 dB HL with shifting of the latency of all the waves. This is typical of that observed in conventional middle-ear conductive loss. Although the mechanics of the cochlea is different from that in the middle ear, the same ABR results were obtained. This might give a clue that the physiology of sound wave conduction is the same in different media. Consequently, impairment of the sound

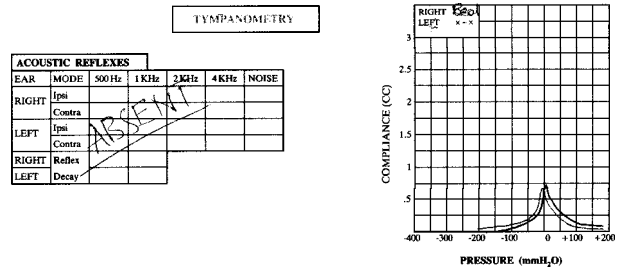


FIG. 6

Tympanometry and impedance measurement Case 3.

conduction mechanism is most likely due to an anatomical or functional lesion in the inner ear proximal to the sensory part (hair cells).

The anatomical correlate to inner ear conductive hearing loss is not completely understood, but it is hypothesized that the functional loss is due to impairment of the vibration of the basilar membrane as a result of abnormality in the scala vestibuli, helicotrema, scala tympani or in the basilar membrane.

A review of the literature showed scanty reference to this topic. The concept of inner ear conductive hearing loss was proposed as early as the 1960s by Gloris and Davis¹ and by Nixon and Glorig.² They proposed stiffness of the cochlear partition as a possible cause. However, their studies were mainly on the effect of age and noise on the cochlea.

Shea as quoted by Donaldson and Snyder³ found that inner ear conductive hearing loss occurs in one out of 700 patients with otosclerosis. Its cause is obscure. It is characterized by a valid conductive loss and normal impedance curves and stapedial reflexes.

The specific causes of inner ear conductive hearing loss are speculative. A possible cause in some cases is abnormal perilymph pressure as suggested by Cremers *et al.*¹⁰ They described mixed' hearing loss due to an abnormal communication between the cerebrospinal fluid and perilymph because of abnormalities in the cochlear aqueduct or internal auditory canal fundus. This transmits excessive pressure to the undersurface of the stapes footplate and ossicular chain. A mixed hearing loss is seen because of the extra pressure on cochlear structures and the footplate. A CT scan often shows a Mondini deformity. All the three cases described here have showed normal radiological findings.

Gacek and Schuknecht¹¹ described what they called inner ear mechanical conductive presbycusis (the other three types are sensory, neural and metabolic). They found no pathologic correlate on light microscopy and they hypothesized that the functional loss is due to stiffness of the basilar membrane. Also, in an electron microscopic study of temporal bones from individuals who had suffered from presbycusis, Nadol¹² found thickening of the basilar membrane in the basal turn of one of the three bones examined. The thickening consisted of an increased number of fibrils and an accumulation of an amorphous osmiophilic material. He suggested that changes of this nature might, for example, affect the elasticity of the basilar membrane. The first two cases of this study showed the hearing loss is mainly in the high frequencies. We suggest that stiffness of the basilar membrane may be associated with or caused by other unknown congenital or acquired causes in addition to the aging process. The first case presented in this paper is probably due to a congenital cause whilst the other two may have been acquired later in life.

The elevated bone conduction threshold seen in some frequencies may be interpreted as mixed hearing loss secondary to affection of the hair cells by the same aetiological agent that caused the conductive loss. However, correlation of bone conduction measurement with the site of the lesion is a complicated matter and great caution should be taken before reaching a firm conclusion. It is well recognized that bone conduction thresholds are not just a measure of hair cells' function. Many conductive lesions can alter bone conduction, and the changes may be reversed with resolution of the condition. Some disorders may falsely enhance the bone conduction while others may falsely decrease it.¹³ Carhart¹⁴ was the first to describe artificial bone conduction depression as a result of stapes ankylosis by otosclerosis and many authors have subsequently confirmed this. The false bone conduction reduction has been called 'the Carhart effect' by some authors.¹⁵ Similar changes have been reported in other middle-ear pathologic conditions. Dirks¹⁶ has provided a thorough review of these findings.

The first two young patients showed unilateral presentation while the third case (38 years) showed similar involvement of both ears from a hearing loss point of view. Is the main underlying pathology in all three cases the same? Is this pathology progressive and will it involve the other side with advancing years?

The authors have no valid explanation for the high admittance (compliance) reading of both affected ears. The measured admittance, however, contains contributions from the ear canal air volume, the tympanic membrane, the ossicles, ovale window, and cochlear fluids. Stiffness of any of these components would produce low admittance. On the other hand, hypermobility produces a high admittance reading. A coincident hypermobile tympanic membrane (not observed otoscopically) may be the cause.

In conclusion, three cases of mainly conductive deafness thought to be due to derangement of the sound conduction function of the inner ears have been presented. The pathophysiology of this entity is not clear due to inaccessibility of the cochlea for clinical examination and due to lack of histopathological studies. More studies are needed to clarify this matter. These patients need to be followed to see the progress of the inner ear pathology. They proposed stiffness of the cochlear partition as a possible cause. However, their studies were mainly on the affect of age and noise on the cochlea.

Shea as quoted by Donaldson and Snyder (1993)³ found that inner ear conductive hearing loss occurs in one out of 700 patients with otosclerosis. Its cause is obscure. It is characterized by a valid conductive loss and normal impedance curves and stapedia reflexes.

References

- 1 Gloris A, Davis H. Age noise and hearing loss. *Ann Otol Rhinol Laryngol* 1961;**70**:556

- 2 Nixon JC, Glorig A. Changes in air and bone conduction thresholds. *J Laryngol Otol* 1962;**76**:288–98
- 3 Donaldson JA, Snyder JM. Otosclerosis. In: Cummings CW, Fredrickson JM, Harker LA, Krause CJ, Schuller DE, eds. *Otolaryngology–Head and Neck Surgery*, 2nd edn. St Louis: The C.V. Mosby Company, 1993;2997–3016
- 4 American National Standard Institute. American National Standards Specifications for Audiometers. New York: American Standards Institute Inc., 1969
- 5 Todd G, Sergeant G, Larson M. Sensorineural hearing loss in Jamaicans with sickle cell disease. *Acta Oto-Laryngol* 1973;**76**:268–72
- 6 Odetoyinbo O, Adekile A. Sensorineural hearing loss in children with sickle cell anaemia. *Ann Otol Rhinol Laryngol* 1987;**96**:258–60
- 7 Hood J. The principles and practice of bone conduction audiometry. *Laryngoscope* 1960;**70**:1211–28
- 8 Jerger J, Jerger S. Measurement of hearing in adults. In: Paparella M, Shumrick I, eds. *Otolaryngology*. Philadelphia: W.B. Sanders, Co., 1980;1225–65
- 9 Jacobson JT, Hyde M. An introduction to auditory evoked potentials. In: Katz J, ed. *Handbook of Clinical Audiology*, 3rd edn. Baltimore: Williams & Wilkins Company, 1985; 496–533
- 10 Cremers CW, Hombergen GC, Wentges RT. Perilymph gusher and stapes surgery; a predictable complication? *Clin Otolaryngol* 1983;**8**:235
- 11 Gacek RR, Schuknecht HF. Pathology of presbycusis. *Int Audiol* 1969;**8**:199
- 12 Nadol JB Jr. Electron microscopic finding in presbycusis: Degeneration of the basal turn of the human cochlea. *Otolaryngol Head Neck Surg* 1979;**87**:818–38
- 13 Snyder JM. Audiometric correlation in otology. In: Cummings CW, Fredrickson JM, Harker LA, Krause CJ, Schuller DE, eds. *Otolaryngology–Head and Neck Surgery–Update 1*. St Louis: The C. V. Mosby Company, 1989;62–77
- 14 Carhart R. Clinical application of bone conduction. *Arch Otolaryngol Head Neck Surg* 1950;**51**:798–808
- 15 Browning GAG, Gatheouse S. Hearing in chronic suppurative otitis media. *Ann Otol Rhinol Laryngol* 1989;**98**:245–50
- 16 Dirks DD. Bone conduction. In: Katz J, ed. *Handbook of Clinical Audiology*, 3rd edn. Baltimore: Williams and Wilkins, 1985;202–23

Address for correspondence:

Professor Hamad Al Muhaimed,
ORL Department,
King Abdul Aziz University Hospital,
PO Box 245, Riyadh 11411,
Saudi Arabia.

Fax: 9661 477 5748

Professor H. Al Muhaimed takes responsibility for the integrity of the content of the paper.
Competing interests: None declared
