

PRIMARY AMENORRHEA WITH A NEW MOSAIC 46,XXqi/47,XXqi Xp-

Consideration on the X isochromosome formation and X chromosome inactivation

I. HALBRECHT, F. SHABTAI, C. KUPFERSTAIN

B. Gattegno Research Institute of Human Reproduction and Fetal Development, and Institute of Pathology, Hasharon Hospital, Petah-Tiqva, and Tel-Aviv University Medical School, Israel

A case of Turner's syndrome was found to be 46,XXqi/47,XXqi Xp-, a new mosaic. The origin of such a mosaic, the formation of the Xq isochromosome using the C-banding technique, and the X chromosome inactivation are discussed. The Xq isochromosome was apparently monocentric, but probably with two strictly close centromeres. The inactivated X seemed to be the Xqi or the normal X alternatively.

Chromosomal aberrations are relatively frequent in cases of primary amenorrhea. Their incidence varies according to the criteria for the selection of the cytogenetically studied amenorrheic patients (Hamerton 1971, Kallio 1973, Sarto 1974, Schmid et al. 1974). Approximately 10-20% of the abnormal karyotypes include an isochromosome for the long arm of the X-chromosome both in euploid (46,XXqi) or, even more frequently, in a mixoploid complement 45,X/46,XXqi. All the mixoploids which have been reported have a 45,X cell line; only in a few subjects of this group an occasional cell with 47,XXqi Xqi has been found (Hamerton 1971).

We wish to present a patient with a new type of mixoploid complement, 46,XXqi/47,XXqi Xp-.

CASE HISTORY

A 24-year-old married woman was referred for cytogenetic investigation because of suspected Turner's syndrome. She was born when her parents were over 35 and she is their only living child. Five years before her birth, a boy was born who lived only few months.

She was of normal intelligence, working as a teacher in a kindergarten. Her height 150 cm, span 155 cm, her weight 49.5 kg. She had cubitus valgus, pigmented naevi, short fourth metacarpals, and hypoplastic nails in both thumbs (Figs. 1-3). She looked older than her chronological age, axillary and pubic hair were slightly reduced and breasts and nipples were poorly developed. She never menstruated spontaneously.

Laparoscopy gave the following results: hypoplastic uterus with hypoplastic fallopian tubes, agenesis of the right ovary and a rudimentary left ovary.

X-ray examination of the skull and pituitary fossa showed no abnormality. The blood pressure was normal and there was no evidence of cardiac abnormality.

Plasma LH and FSH concentrations and urinary 17 ketosteroids and hydroxysteroids were within normal limits. Urinary estrogens were very low. Routine examinations for thyroid function were normal, but special tests showed a low thyroid response to TSH stimulation, meaning latent hypothyroidism. Thyroid antibodies were not tested.

Acta Genet. Med. Gemellol. (1977), 26: 63-69

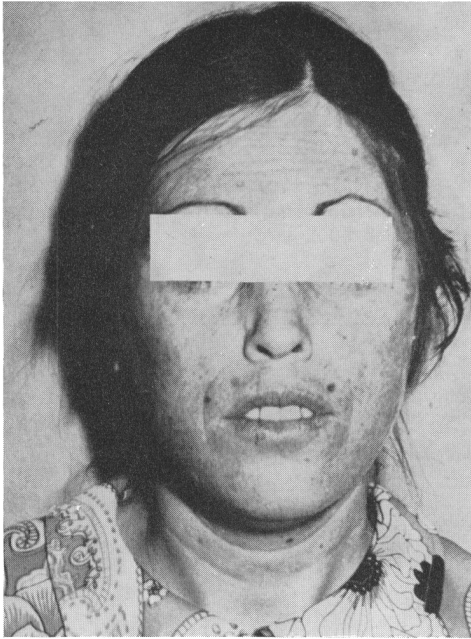

Fig. 1. The proposita.

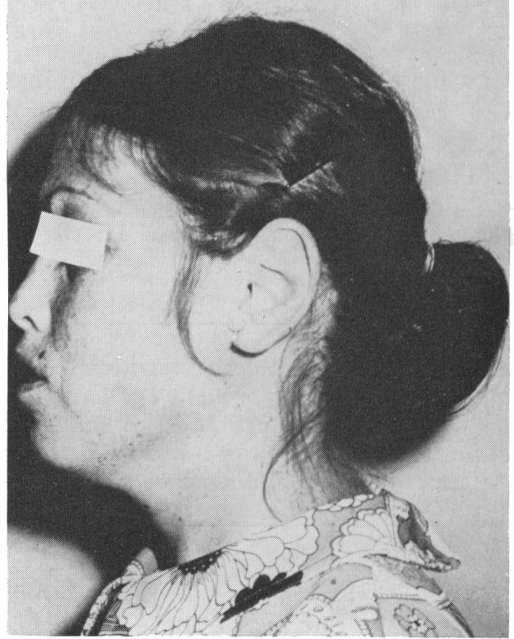


Fig. 2. Profile of the proposita.

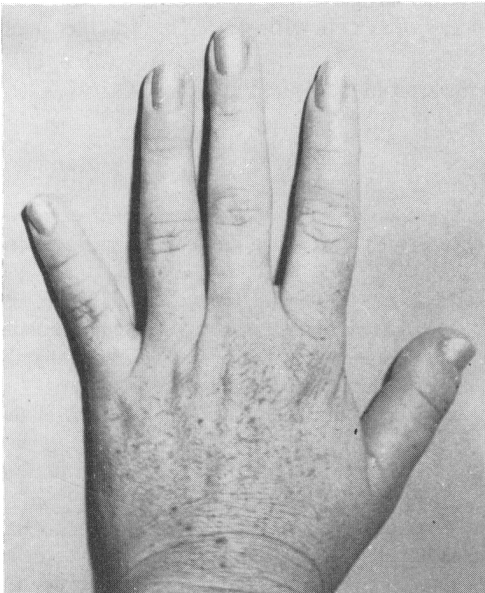

Fig. 3. Hand of the proposita.

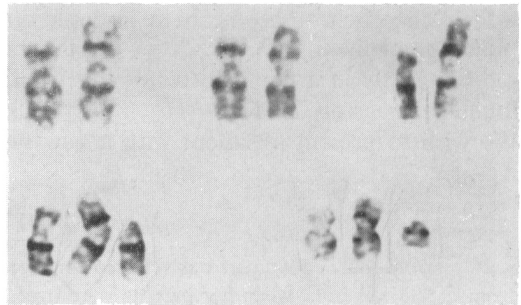


Fig. 4. Sex chromosomes of the proposita from the 46,XXqi and the 47,XXqi Xp- lines.

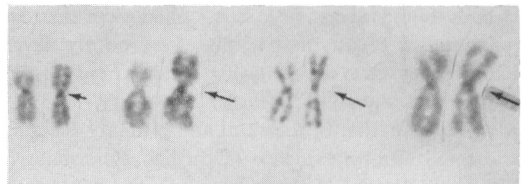


Fig. 5. C-banding of the sex chromosomes. Note the centromeric mass in the Xqi, bigger than in the normal X. On the right the only Xqi with an apparently double centromeric band.

Material and Methods

Sex chromatin determinations were made on several occasions on buccal smears stained with carbofuchsin. Each time at least 200 cells were examined. Phytohemagglutinin-stimulated peripheral blood lymphocytes were used for cytogenetic analysis, according to the method of Moorhead et al. (1960).

G-banding of the chromosomes was obtained by modification of the trypsin method of Seabright (1971), and the C-banding by the method of Arrighi and Hsu (1971).

The patient's parents were not available for studies.

Results

The proposita was sex-chromatin positive. Barr-bodies in the nuclei of the buccal smears were present in a higher proportion than usual for our laboratory (34-54%) in 4 different occasions. They were of different size. In the first occasion most of the positive cells seemed to have a large Barr-body, only rarely 2 chromatin bodies could be seen.

Cytogenetic analysis was performed on 160 metaphases: few cells with 44-45 chromosomes had a random loss, 3 were polyploids, most of the cells had 46 chromosomes and 16 (10%) had 47 chromosomes.

By G-banding the patient was found to be 46,XXq1/47,XXq1 Xp- mosaic (Fig. 4). That means that she had a trisomy or tetrasomy for the long arm and monosomy for the short arm of the X chromosome. By C-banding, the Xq- isochromosome appeared to be monocentric (except once), although the centromeric band was larger than in the normal X (Fig. 5). By C-banding, enlargement of the centromeric heterochromatin in both chromosomes 19 could also be noted.

Buccal smear examination was performed once again after the cytogenetic findings. The size of the Barr-bodies was calculated according to the method of De la Chapelle et al. (1972), and the results confirmed the visual impression of different populations of cells (Fig. 6). Their proportion was calculated in 200 cells several times in different smears taken on the same day. In 20-25% of the cells a Barr-body of normal size was present and in 9-10% a large one. In 2-10% there were two Barr-bodies. According to the cytogenetic findings and the impression of the first buccal smear examination, we expected more large Barr-bodies to be present. We therefore examined the patient two more times at several weeks' intervals. Cells with large and normal sized Barr-body were now in approximately equal proportions (15-20% of cells), while 2-10% still presented two Barr-bodies. We never met bipartite Barr-bodies.

DISCUSSION

The proposita presents most of the clinical and phenotypic features of "Turner's syndrome" and she belongs to the group of patients with a structural abnormality of the sex chromosome. The low response to TSH is also typical in this group (Doniach et al., cited by Hamerton 1971).

Isochromosome for the long arm of the X is the most frequently observed structural abnormality: in two thirds of the cases there are mosaic complements 45,XO/46,XXq1. Ford and Clegg (1969) suggest that a single event often accounts for both lines.

In our case, the mosaic has an unusual constitution. The 45,XO line is missing and, instead, a previously undescribed (to the best of our knowledge) line is present: 47,XXq1 Xp-. From the clinical or physical point of view, no relevant changes from the reported XXq1 cases

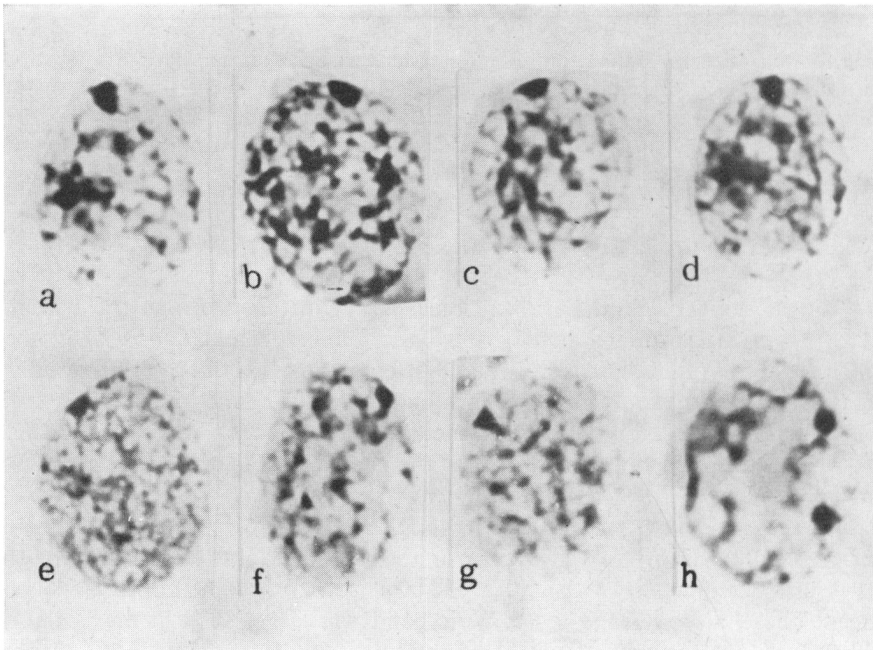


Fig. 6. Cells from the buccal mucosa smears with a large Barr-body (a, b, c, d), a normal Barr-body (e, f, g), and two Barr-bodies (h).

might be expected, as the sex chromosome complement remains abnormal, so that the gonads cannot normally develop (Jones 1965), and one of the short arms is still missing. Concerning the origin of such a line, we suggest that the zygote was originally a 47,XXX.

A similar break happened probably in two of the X, immediately next to the centromere. The acentric segment of the short arm was lost in both X chromosomes, while one of the telocentric segments gave origin to the isochromosome of the long arm: Xqi, and the second one remained deleted: Xp-. On the other hand, cells with 47,XXqi Xp- are strongly imbalanced, the deleted telocentric chromosome might have been successively eliminated and that is why such a line is found in only 10% of the cells.

The traditionally supposed mechanism of isochromosome formation is a centromere transversal misdivision (Darlington 1939, 1940). On the other hand, increasing evidence that long arm X isochromosomes are much more frequent than short arm X isochromosomes (De la Chapelle et al. 1972, Fitzgerald and Donald 1975), if they exist at all (Therman et al. 1974), suggests that usually the misdivision does not happen equally across the centromere, but preferentially towards the short arm or at its very beginning. Probably the proximal region of the short arm (Therman et al. 1974) is particularly subjected to breakages. In fact, dicentric isochromosomes of the X long arm are not rare (Schmid et al. 1974, Cohen et al. 1975).

We carefully observed all the C-banded preparations, but no evidence of more than a single centromeric band, except once, was found in the Xqi. Nevertheless, we had the impression that it was of a larger size than in the normal X (Fig. 5), compatible with the presence of two strictly closed centromeres. Schmid et al. (1974) observed that the monocentric type

of Xqi seems to be more stable than dicentrics, as all their non-mosaic cases had apparently monocentric isochromosomes. That is quite acceptable considering the difficulties of dicentric chromosomes at anaphase. Our case had no evidence of a 45,XO line. In fact, if the two centromeres are close the one to the other, dicentric chromosomes may behave as monocentric elements and do persist and replicate normally (Cohen et al. 1975). In many Xqi reported cases C-banding was not performed and other many monocentric-looking elements may have had two strictly closed centromeres appearing as an unique larger centromeric band as in our case. Besides the unusual mosaic, the buccal smears' examination was also of interest in the proposita.

It is usually accepted that in human beings structurally abnormal X chromosomes are preferentially inactivated (Jones 1965, Comings 1968). It has been proved to be so in Xq-, Xp-deletions (Hsu et al., Polani et al., cited by Hamerton 1971), in Xqi (Muldal et al. 1963), in Xpi (De la Chapelle et al. 1972, Fitzgerald and Donald 1975). It is not so in balanced or unbalanced X- autosome translocations, where usually the normal X is preferentially but not necessarily inactivated (Schmid et al. 1974, Summitt et al. 1974). The size of the sex chromatin body is proportional to that of the inactivated X.

It is not clearly established yet whether X inactivation in mammalian somatic cells is stable or not, because evidence has been contributed to one side or the other (Romeo and Migeau 1975, Rao and Jhanwar 1975).

In our case Barr-bodies in different cells were of different sizes so that we may suppose that both the normal X or the Xqi were alternatively inactivated. According to the observations of Morishima et al., Atkins and Santesson, Barton et al., and Ockey et al. (cited by Comings 1968), the inactivated late-replicating X has been found at the periphery of metaphase spreads. In our preparations both the normal X and the isochromosome for the long arm were found alternatively at the periphery or at the center of the metaphase (Figs. 7, 8). The inactivation seemed to be instable as in different occasions varied the proportion of normal or large sized Barr-bodies. The Xp- seemed to be always inactivated as up to 10% of the cells had two Barr-bodies.

Acknowledgements

The authors wish to thank Dr. I. Itelson for thyroid function evaluation, Mrs. Sara Hadar for technical help, and Mr. Joseph Sadovnik and Miss Miriam Gilden for photographic assistance.

REFERENCES

- Arrighi F.E., Hsu T.C. 1971. Localization of heterochromatin in human chromosomes. *Cytogenetics*, 10: 81-86.
- Cohen M.M., Rosenmann A., Hacham-Zadeh S., Dalan S. 1975. Dicentric X-isochromosome (Xqi dic) and pericentric inversion of No. 2 [inv(2)(p15 q21)] in a patient with gonadal dysgenesis. *Clin. Genet.*, 8: 11-17.
- Comings D.E. 1968. The rationale for an ordered arrangement of chromatin in the interphase nucleus. *Am. J. Hum. Genet.*, 20: 440-460.
- Darlington C.D. 1939. Misdivision and the genetics of the centromere. *J. Genet.*, 37: 341-364.
- Darlington C.D. 1940. The origin of isochromosomes. *J. Genet.*, 39: 351-361.
- De la Chapelle A., Schröder J., Pernu M. 1972. Isochromosome for the short arm of the X, a human 46,XXpi syndrome. *Ann. Hum. Genet.*, 36: 79-87.
- Fitzgerald P.H., Donald R.A. 1975. Isochromosome for the short arm of X: A human mosaic 45,X/46,XXpi-. *Clin. Genet.*, 7: 148-154.
- Ford C.E., Clegg H.M. 1969. Reciprocal translocations. *Brit. Med. Bull.*, 25: 110-114.
- Hamerton J.L. 1971. *Human Cytogenetics*. Vol. 2: *Clinical Cytogenetics* (pp. 65-112, 502-505). New York-London: Academic Press.
- Jones H.W. 1965. Clinical significance of anomalies of the sex chromosomes. *Am. J. Obstet. Gynecol.*, 93: 335-342.

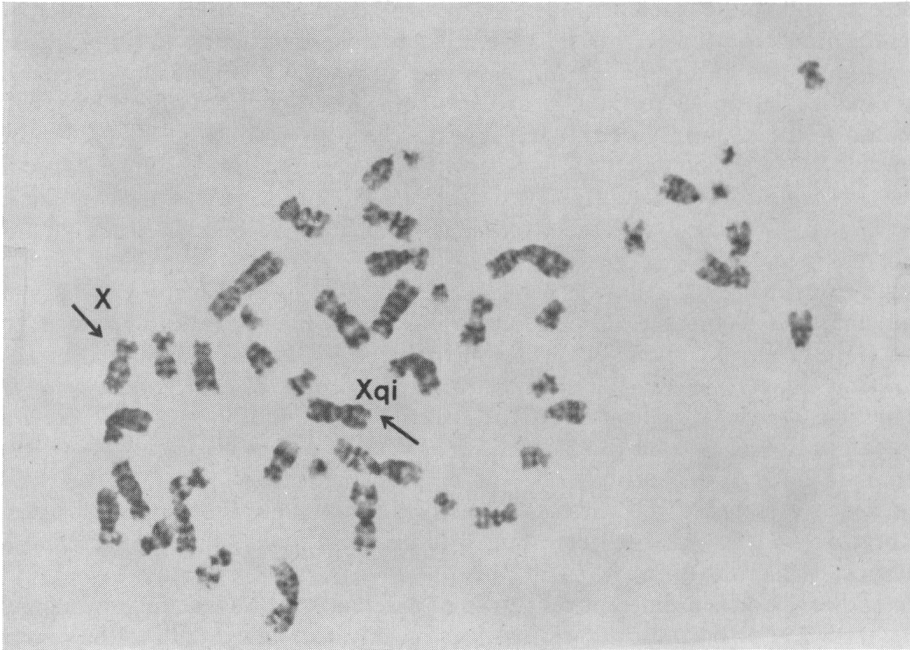


Fig. 7. The normal X at the periphery of the cell.

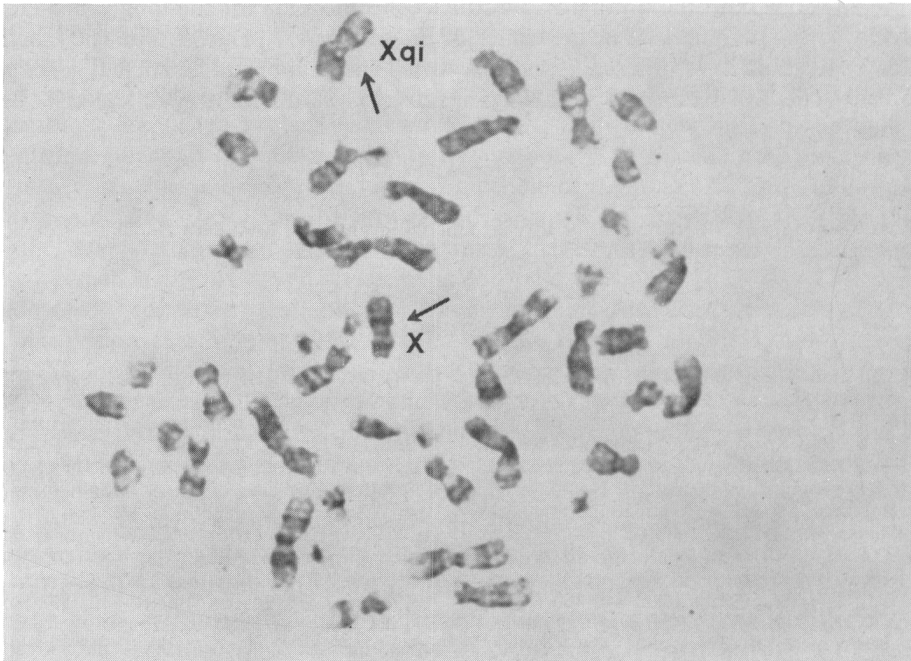


Fig. 8. The normal X at the center of the cell.

- Kallio H. 1973. Cytogenetic and clinical study of 100 cases of primary amenorrhoea. Acta Obstet. Gynecol. Scand., 52 (Suppl. 24): 1-78.
- Moorhead P.S., Nowell P.C., Mellman W.J., Battips D.M., Hungerford D.A. 1960. Chromosomes preparations of leukocytes cultured from human peripheral blood. Exp. Cell Res., 20: 613-616.
- Muldal S., Gilbert C.W., Lajtha L.G., Lindsten J., Rowley J., Fraccaro M. 1963. Tritiated thymidine incorporation in an isochromosome for the long arm of the X chromosome in man. Lancet, 1: 861-863.
- Rao S.R.V., Jhanwar S.C. 1975. Is late replication of the inactive X chromosome irreversible in all cells of mammals? Cytogenet. Cell Genet., 14: 140-149.
- Romeo G., Migeau B.R. 1975. Stability of X chromosomal inactivation in human somatic cells transformed by S.V. 40. Humangenetik, 29: 165-170.
- Sarto G.E. 1974. Cytogenetics of fifty patients with primary amenorrhoea. Am. J. Obstet. Gynecol., 119: 14-23.
- Schmid W., Naef E., Mürset G., Praeder A. 1974. Cytogenetic findings in 89 cases of Turner's syndrome with abnormal karyotypes. Humangenetik, 24: 93-104.
- Seabright M. 1971. A rapid banding technique for human chromosomes. Lancet, 2: 971-972.
- Summitt R.L., Martens P.R., Wilroy R.S. 1974. X-autosome translocation in normal mother and effectively 21-monosomic daughter. J. Pediatr., 84: 539-545.
- Therman E., Sarto G.E., Patau K. 1974. Center for Barr body condensation on the proximal part of the human Xq: A hypothesis. Chromosoma, 44: 361-366.

RIASSUNTO

Amenorrea Primaria con un Nuovo Mosaico 46,XXqi/47,XXqi Xp- — Considerazioni sulla formazione dell'isocromosoma X e sull'inattivazione del cromosoma X

In un caso di sindrome di Turner è stato riscontrato un nuovo mosaico: 46,XXqi/47,XXqi Xp-. Vengono discusse l'origine di un tale mosaico, la formazione dell'isocromosoma Xq con la tecnica del bandeggiamento C, e l'inattivazione del cromosoma X. L'isocromosoma Xq era apparentemente monocentrico, ma probabilmente con due centromeri molto vicini. L'X inattivato sembrava essere di volta in volta l'Xqi o l'X normale.

RÉSUMÉ

Aménorrhée Primaire avec une Nouvelle Mosaïque 46,XXqi/47,XXqi Xp- — Considérations sur la formation de l'isochromosome X et sur l'inactivation du chromosome X

Dans un cas de syndrome de Turner une nouvelle mosaïque a été trouvée: 46,XXqi/47,XXqi Xp-. L'origine de cette mosaïque, la formation de l'isochromosome Xq avec la technique des bandes C, et l'inactivation du chromosome X sont discutées. L'isochromosome Xq était apparemment monocentrique, mais probablement avec deux centromères très près l'un de l'autre. Le X inactivé semblait être parfois le Xqi et parfois le X normal.

ZUSAMMENFASSUNG

Primäre Amenorrhoe mit einem neuen Mosaik 46,XXqi/47,XXqi Xp- — Betrachtungen über die Formation des Isochromosoms X und die Inaktivierung des Chromosoms X

Bei einem Fall von Turner-Syndrom wurde ein neues Mosaik gefunden: 46,XXqi/47,XXqi Xp-. Erörterung des Ursprungs eines solchen Mosaiks, der Bildung des Isochromosoms Xq mit der C-Bandentechnik und der Inaktivierung des Chromosoms X. Das Isochromosom Xq war anscheinend monozentrisch, wahrscheinlich aber mit zwei ganz aneinanderliegenden Zentromeren. Das inaktivierte X schien von Fall zu Fall entweder das Xqi oder das normale X zu sein.

Prof. I. Halbrecht, Research Institute of Human Reproduction and Fetal Development, Hasharon Hospital, Petah-Tiqva, Israel.