

# Early striatal hypertrophy in first-episode psychosis within 3 weeks of initiating antipsychotic drug treatment

S. E. Chua<sup>1,2</sup>, Y. Deng<sup>1</sup>, E. Y. H. Chen<sup>1</sup>, C. W. Law<sup>1</sup>, C. P. Y. Chiu<sup>1</sup>, C. Cheung<sup>1</sup>, J. C. H. Wong<sup>3</sup>,  
N. Lienenkaemper<sup>4</sup>, V. Cheung<sup>1</sup>, J. Suckling<sup>5</sup> and G. M. McAlonan<sup>1,2\*</sup>

<sup>1</sup> Department of Psychiatry, Queen Mary Hospital, The University of Hong Kong, S.A.R. China

<sup>2</sup> State Key Laboratory for Cognitive Science, The University of Hong Kong, S.A.R. China

<sup>3</sup> Faculty of Medicine, University of Georgetown, Washington, DC, USA

<sup>4</sup> Department of Biomedical Sciences, The University of Utrecht, The Netherlands

<sup>5</sup> Cambridge Brain Mapping Unit, Department of Psychiatry, University of Cambridge, UK

**Background.** We and others have reported that patients experiencing their first episode of psychosis already have significant structural brain abnormalities. Antipsychotics seem to reverse subcortical volume deficits after months of treatment. However, the early impact of medication on brain morphology is not known.

**Method.** Forty-eight individuals in their first episode of psychosis underwent magnetic resonance imaging (MRI) brain scanning. Twenty-six were antipsychotic naive and 22 were newly treated with antipsychotic medication for a median period of 3 weeks. In each group, 80% of subjects received a diagnosis of schizophrenia. The two groups were balanced for age, sex, handedness, ethnicity, height, years of education, paternal socio-economic status (SES) and Positive and Negative Syndrome Scale (PANSS) score. Group differences in whole-brain grey matter were compared voxel by voxel, using Brain Activation and Morphological Mapping (BAMM) software. We also conducted testing of group differences with region-of-interest (ROI) measurements of the caudate nucleus.

**Results.** Relative to the untreated group, those receiving antipsychotic medication for 3–4 weeks had significantly greater grey-matter volumes in the bilateral caudate and cingulate gyri, extending to the left medial frontal gyrus. ROI analysis confirmed that, in treated patients, the right and left caudate nuclei were significantly larger by 10% ( $p < 0.039$ , two-tailed) and 9% ( $p < 0.048$ , two-tailed) respectively.

**Conclusions.** Early striatal grey-matter enlargement may occur within the first 3–4 weeks of antipsychotic treatment. Possible reasons for putative striatal hypertrophy and its implications are discussed.

Received 11 December 2007; Revised 4 July 2008; Accepted 10 July 2008; First published online 20 August 2008

**Key words:** Antipsychotic, brain, first episode, MRI, schizophrenia.

## Introduction

Brain imaging studies have generally shown that patients with schizophrenia have smaller global and regional brain volumes compared to typically developing individuals (Harrison, 1999; Shenton *et al.* 2001; Jayakumar *et al.* 2006; Chua *et al.* 2007). Smaller cortical size has been demonstrated in the prefrontal, entorhinal and anterior cingulate cortices (Harrison, 1999; Tamminga *et al.* 2000). By contrast, enlargement of subcortical regions after antipsychotic treatment has also been demonstrated (Chakos *et al.* 1994).

Never-medicated patients have smaller caudate nuclei, putamen and nucleus accumbens (Gur *et al.* 1998; Corson *et al.* 1999; Dazzan *et al.* 2004; Girgis *et al.* 2006; Chua *et al.* 2007), the size of which increases following months of typical antipsychotic treatment (Gur *et al.* 1998; Corson *et al.* 1999) and may be partly explained by increased striatal blood flow (Corson *et al.* 2002). The phenomenon is regarded as evidence of antipsychotic-induced hypertrophy (Gur *et al.* 1998).

This raises the question of whether treatment-related changes hold clues to the pathophysiology. Antipsychotic drugs markedly reduce symptoms within the first 3 weeks of treatment (Johnstone *et al.* 1978), even as early as week 2, with 68% of the improvement at 1 year achieved within the first month (Leucht *et al.* 2005). Aberrant development of

\* Address for correspondence: Dr G. M. McAlonan, Department of Psychiatry, The University of Hong Kong, 102 Pokfulam Road, Hong Kong, S.A.R. China.  
(Email: mcalonan@hkucc.hku.hk)

prefrontal–striatal circuitry during adolescence is thought to be related to the pathophysiology of schizophrenia (Laruelle, 2000). According to the dopamine hypothesis of schizophrenia, an excess of dopamine in this brain system is associated with psychosis (Carlsson, 1978) and antipsychotic drugs that block dopamine receptors are able to oppose this, a process referred to as ‘endogenous dopamine sensitization’ (Laruelle, 2000).

Forty years after antipsychotic medication revolutionized the therapeutic armory against schizophrenia, the reason why there is a time lag before antipsychotic drug treatment takes effect (Johnstone *et al.* 1978) remains obscure. It may be partly explained by the time taken for an interaction between dopamine receptors and antipsychotics to alter gene expression, leading to neurogenesis and synaptic changes (Konradi & Heckers, 2001). It has been suggested that the clinical lag period coincides with the time course of an underlying neural response to treatment (Leucht *et al.* 2005).

Neuroplastic modulation of the caudate nucleus, part of the dopamine-rich striatum, is supported by a volumetric increase after 3 (Massana *et al.* 2005) to 18 months of antipsychotic treatment (Chakos *et al.* 1994). However, after shorter periods of treatment, this effect may be less marked. For example, increases in grey matter were reported in the superior temporal gyrus and middle temporal gyrus, but not the basal ganglia, after 15 antipsychotic-naïve patients underwent 6 weeks of treatment with the atypical antipsychotic risperidone (Girgis *et al.* 2006). Another study of 13 patients suffering a relapse of schizophrenia found no effects on the basal ganglia, despite a diffuse volumetric increase throughout the cortex after 4 weeks of treatment with second-generation atypical antipsychotics, but not with haloperidol (Garver *et al.* 2005). Conceivably, the caudate nuclear volume increase was not demonstrated because of weak study power. An alternative explanation is that the effect depends upon the duration of exposure to antipsychotics.

To address this issue, we conducted a pilot study of 22 patients newly diagnosed with schizophrenia scanned for a median period of 3 weeks after starting antipsychotic medication for the first time and 26 control patients also newly diagnosed with schizophrenic but never medicated. A voxel-by-voxel whole-brain grey-matter volumetric comparison (voxel-based morphometry, VBM) of the two patient groups enabled the early effects of antipsychotic treatment in first-episode schizophrenia to be evaluated. In addition, a region-of-interest (ROI) measurement of the caudate nuclei was undertaken. An important aspect of this study was its naturalistic

design for medication selection, in that the choice of antipsychotic did not conform to a fixed protocol but instead was an entirely clinician-led decision.

## Method

### Subjects

All patients presenting to the hospital with psychosis were screened for eligibility to join the study. Inclusion criteria were: age 18–50 years; no previous history of any antipsychotic medication; and first experience of psychotic symptoms (i.e. hallucinations and/or delusions and/or thought disorder, with decline in daily functioning) according to DSM-IV (APA, 1994) confirmed by two independent specialists in psychiatry. Duration of psychosis was assessed using the Interview for the Retrospective Assessment of Schizophrenia (IRAOS; Hafner *et al.* 1992) and has been described in detail elsewhere (Chen *et al.* 2005). Exclusion criteria were: any history of neurological problems; loss of consciousness; persistent headaches; head trauma; electroconvulsive therapy; psychostimulant use; and special school attendance. The study received the approval of the Institutional Review Board of the hospital concerned. All subjects were Chinese. Patients were screened within the first day of presenting to hospital and all gave full informed written consent to participate according to the Declaration of Helsinki. These patients were part of a larger brain imaging project of first-episode psychosis patients to evaluate brain morphology compared to typically developing matched controls (results available in Chua *et al.* 2007). The Positive and Negative Syndrome Scale (PANSS; Kay *et al.* 1987) was used to assess patients’ psychopathology when they presented to hospital. The antipsychotic-treated group received a magnetic resonance imaging (MRI) brain scan 3 weeks after antipsychotic treatment had started. The antipsychotic-naïve group had an MRI brain scan just before antipsychotic treatment was initiated.

### MRI data acquisition

Patients were scanned on a GE Signa 1.5 T system (General Electric, Milwaukee, WI, USA) in Queen Mary Hospital, Hong Kong. The scan lasted for 20 minutes. A consultant radiologist (K.S.T.), blind to diagnosis, reviewed each MRI scan for any gross anomaly. Scans aligned to the AC–PC line were acquired across the whole brain as follows. PD/T2 sequence: dual-echo fast spin–echo data sets with TR 5–6 s, anterior–posterior direction 0.86 mm, right–left direction 1.15 mm, slice direction 3 mm, matrix size 256 × 192, contiguous, phase inversion time 10 ms, two

echoes with TE = 20/80 ms, number of excitations = 1, echo train length = 8. PD/T2 scans were used for computerized VBM analysis. T1 sequence: fast SPGR 3D oblique scans with 128 slices, contiguous, 1.2 mm thick, Nex = 1, TR 11.4 s, TE 4.2 ms, flip angle 15°, FOV 24 × 24, matrix 25 × 256. T1 scans were used for manual (ROI) tracing.

### Preprocessing and analysis

Group differences in grey matter were mapped using Brain Activation and Morphological Mapping (BAMM) software version 2.5 ([www.bmu.psychiatry.cam.ac.uk/BAMM/index.html](http://www.bmu.psychiatry.cam.ac.uk/BAMM/index.html)) on a SPARC workstation (Sun Microsystems Europe Inc., Surrey, UK) as described previously (Sigmundsson *et al.* 2001; McAlonan *et al.* 2002, 2005; Chua *et al.* 2007). In brief, PD/T2 images were processed to remove extracerebral tissues (Suckling *et al.* 1999a) and then segmented into grey and white matter, cerebrospinal fluid (CSF), dura and other non-cerebral tissues, which were subsequently ignored (Suckling *et al.* 1999b). The segmented images were mapped into the standard space of Talairach and Tournoux (Talairach & Tournoux, 1988) by affine transformation of each proton density image to a group-specific template (Suckling *et al.* 1999b; McAlonan *et al.* 2005; Chua *et al.* 2007), applying the derived mappings to the tissue maps and followed by smoothing with a 4.4 mm Gaussian kernel. The effect of diagnostic group was estimated at each voxel by regression of a general linear model to the estimates of grey and white matter occupancy separately. Maps of the corresponding standardized coefficient were subject to an inference procedure in which the significance of three-dimensional cluster statistics was assessed using non-parametric (permutation) methods (Bullmore *et al.* 1999). The statistical thresholds were corrected for multiple comparisons by setting the *p* value such that <1 false positive cluster was expected in each map under the null hypothesis (Suckling & Bullmore, 2004).

### ROI analysis

Caudate and lateral ventricular volumes were evaluated using the T1 dataset as described previously (Murphy *et al.* 1992; Chua *et al.* 2007). One independent operator who was blind to the groups aligned the axial scans along the AC–PC line using MEASURE software (Barta *et al.* 1997). Left and right caudate nuclei were traced according to standard anatomical boundaries. Volumes were calculated by multiplying the summed pixel cross-sectional areas by slice thickness. As all measurements were performed blind by a

single operator, only the intra-class correlation coefficient (ICC) was calculated.

## Results

### Demographic and clinical comparison of groups

In total, 50 first-episode psychotic patients were recruited for the study; of these, two patients declined the MRI scan. Of the 48 patients who underwent MRI brain scanning, 22 were antipsychotic medicated and 26 antipsychotic naive. However, the scans for three patients had movement artefacts and were not suitable for further processing. Thus, the final numbers for image analysis were 20 antipsychotic-treated and 25 antipsychotic-naive patients. Two independent clinicians gave the diagnosis of schizophrenia to 16 (80%) of the antipsychotic-treated and 21 (84%) of the antipsychotic-naive patients; for the remaining four patients in each group, diagnoses of acute and transient psychosis or schizophreniform psychosis were given. The diagnoses were also confirmed by the responsible clinician upon case-note review, 6 months after presentation. Antipsychotic medication prescribed followed a naturalistic approach, that is it was entirely clinician led according to local practice. The treated group received either typical (haloperidol in 13 patients, trifluoperazine in one patient, and sulpiride in one patient) or atypical medication (amisulpride in five patients). Both groups were balanced for age, sex, handedness, ethnicity, paternal socio-economic status (SES) and height (see Table 1).

### Brain morphological differences

#### Grey-matter volume differences

In the antipsychotic-treated group, compared to the antipsychotic-naive patient group, significant clusters of volume excess in cerebral grey matter were detected after 3–4 weeks of antipsychotic treatment, involving bilateral regions of the caudate, putamen, anterior cingulate and medial prefrontal cortex (see Fig. 1 and Table 2). When the analysis was restricted to subjects with schizophrenia, the results did not change significantly.

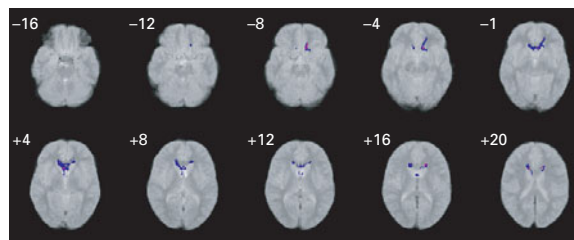
#### ROI measurements

We used ROI planimetry to trace the caudate nuclei of the striatum. The ICC of the rater was 0.94 for both left and right caudate on 10 scans performed 1 month apart. In patients treated for a median of 3 weeks, the left caudate was larger by 9% (two-tailed  $p < 0.048$ ) and the right caudate by 10% (two-tailed  $p < 0.039$ ) (see Fig. 2 and Table 3). When the analysis was

**Table 1.** Characteristics of all patients with psychosis ( $n=45$ )

Variable	Antipsychotic-treated group ( $n=20$ )	Antipsychotic-naive group ( $n=25$ )
Age (years), mean (s.d.)	29 (8.6)	32 (9.5)
Sex, % males	50	40
Handedness, % right-handed	90	76
Education (years), mean (s.d.)	12 (2.9)	10 (1.3)
Height (cm), mean (s.d.)	162 (10)	159 (8.7)
Parental SES, mean (s.d.)	3.8 (1.4)	4.2 (1.6)
PANSS score, mean	78 (23)	68 (16)
Antipsychotic CPZ equivalent (mg), mean (s.d.)	318 (245)	0
Duration of untreated psychosis (days)		
Mean (s.d.)	286 (356)	353 (547)
Median	90	105
Range	6–1095	16–2008
Antipsychotic duration (days)		
Mean (s.d.)	27 (21)	0
Median	22	
Range	5–86	

SES, Socio-economic status; PANSS, Positive and Negative Syndrome Scale; CPZ, chlorpromazine; s.d., standard deviation.



**Fig. 1.** Grey-matter differences in the antipsychotic-naive ( $n=25$ ) and antipsychotic-treated groups ( $n=20$ ). The blue colour represents regions where grey-matter volumes were significantly greater in the antipsychotic-treated group compared to the antipsychotic-naive group. The right side of the brain corresponds to the right side of the figure. The z coordinate for each axial slice in standard Talairach and Tournoux space is given in millimetres. Statistical threshold is  $p < 0.002$  corrected.

restricted to subjects with schizophrenia, the antipsychotic-treated group also had significantly larger left and right caudate nuclei by 10.7% on each side (independent  $t$  test,  $p < 0.03$ , one-tailed).

## Discussion

We report that discrete brain morphological differences related to antipsychotic treatment occur as early

as 3 weeks post-exposure. In particular, we have demonstrated for the first time that the caudate nucleus appears enlarged in patients who have undergone just a few weeks of antipsychotic treatment for first-episode schizophrenia. In this study of 48 patients, we found that, compared to the antipsychotic-naive patient group, the antipsychotic-treated group had significantly greater grey-matter volumes in the bilateral caudate nuclei and cingulate gyri, extending to the left medial frontal gyrus. ROI analysis confirmed larger striatal volumes in the treated group of the order of 9–10% in both caudate nuclei.

The present finding has an intriguing symmetry with our previous work showing that caudate volumes are as much as 11% smaller in untreated patients with first-episode schizophrenia when compared to matched healthy volunteers (Chua *et al.* 2007). This indicates that caudate volume might be ‘normalized’ or increased after antipsychotic drug administration in the very early weeks of treatment. We did not attempt to correlate caudate volumes with PANSS ratings because the latter were performed at first presentation, whereas the brain scan was conducted at two time-points (i.e. at presentation or 3 weeks after drug treatment). The groups did not differ significantly on baseline PANSS ratings, yet after 3 weeks of treatment caudate volumes were significantly greater than those

**Table 2.** Grey-matter differences in the antipsychotic-naïve ( $n=25$ ) and antipsychotic-treated groups ( $n=20$ ) ( $p < 0.002$  corrected)<sup>a</sup>

Brain region	Talairach coordinates (mm)			Cluster size (voxels)	Brodmann area (BA)
	x	y	z		
L cingulate gyrus, extending to L medial frontal, L caudate nucleus	-0.6	21.8	5.1	593	BA 0, BA 24
R cingulate gyrus, extending to R caudate nucleus	4.9	21.2	4	93	BA 0, BA 24

L, Left; R, right.

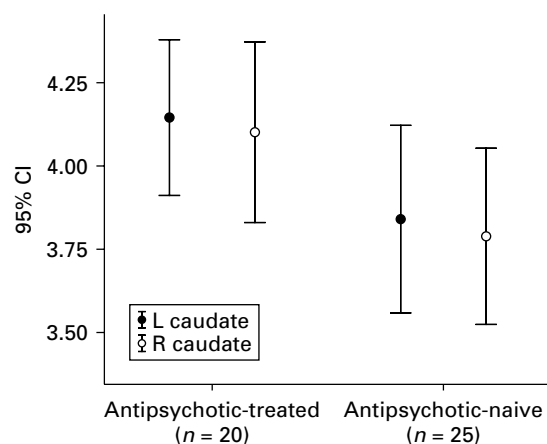
<sup>a</sup> A sample Talairach coordinate (x, y, z) is given for the approximate centre of each three-dimensional (3D) cluster but, as shown in Fig. 1, the 3D cluster is not confined to this area alone.

**Table 3.** Region-of-interest analysis of the caudate nuclei

Brain region	Volume (ml), mean (s.d.)		Group difference (%)	Independent <i>t</i> test	
	Antipsychotic-treated group ( $n=20$ )	Antipsychotic-naïve group ( $n=25$ )		<i>t</i> value	<i>p</i> value
L caudate	4.20 (0.50)	3.86 (0.68)	9	2.035	0.048*
R caudate	4.17 (0.57)	3.80 (0.62)	10	2.129	0.039*

L, Left; R, right; s.d., standard deviation.

\* Two-tailed significance,  $p < 0.005$ .

**Fig. 2.** Caudate volume differences between antipsychotic-treated and antipsychotic-naïve groups.

never treated. It is now known that the antipsychotic effect may take place as early as week 2 (Leucht *et al.* 2005), and even manifest as early as some hours post-intramuscular antipsychotic, without being due to simple reduction in agitation (Agid *et al.* 2008). Conceivably, treatment effectiveness may depend on 'rewiring' neuronal circuitry (Konradi & Heckers, 2001), and would partly account for the time needed

for clinical efficacy. The mechanism by which antipsychotic drugs cause hypertrophy of the caudate nucleus (Chakos *et al.* 1994; Shenton *et al.* 2001) and possibly also of the putamen and thalamus (Gur *et al.* 1998) remains to be fully elucidated. However, it has already been shown that antipsychotic drugs can lead to genetic modulation of neuronal function in the striatum or prefrontal cortex (Weinberger & Lipska, 1995), the putative sites of action of typical and atypical antipsychotic drugs (Pilowsky, 2001). We were intrigued that our treated group had grey-matter excess in the medial frontal and cingulate gyri because these regions are implicated in behavioural monitoring and error detection (Rushworth *et al.* 2007). Animal studies have shown that dopamine blockade with olanzapine (Wang *et al.* 2004) or haloperidol (Kippin *et al.* 2005) can stimulate new cell proliferation and therefore, taken together, the data support neuroplastic change in the fronto-limbic circuitry in the early phase of drug treatment.

The coincidence of structural abnormality and antipsychotic target in psychosis adds to the evidence that effective medication modifies those prefrontal-temporolimbic cortical networks most vulnerable to progressive tissue loss in the first 5 years after illness onset (Thompson *et al.* 2001). Although others have

shown that antipsychotic medication may increase caudate size (Chakos *et al.* 1994; Shenton *et al.* 2001), placed with our previous findings of smaller caudate volume in first-episode schizophrenia (Chua *et al.* 2007), we suggest that this constitutes a 'reversal' of pathology as early as 3 weeks into treatment. We previously proposed that reduced caudate volumes might provide a useful biomarker for psychosis and it has been argued that the excess of dopamine in patients with schizophrenia has a toxic effect on neurons, potentially inducing an increase in oxidative stress (Keshavan, 1999). The results of the present study lead us to extend our proposal and we speculate that normalized caudate volumes early in treatment might mirror the clinical response.

However, there is controversy in the field. Although patients with first-episode psychosis have been shown to have reduced caudate volumes in many recent MRI studies (Harrison, 1999; Shenton *et al.* 2001; Jayakumar *et al.* 2006; Chua *et al.* 2007), others have reported no changes in caudate volume (Crespo-Facorro *et al.* 2006). The question of whether patients were already medicated, however briefly, on entry to each study is a salient point, as is the type of medication administered. Girgis *et al.* (2006) reported no increase in caudate nucleus volume despite increases in various cortical regions following risperidone treatment. In our study the medication patients received was entirely clinician led: 2/3 received typical antipsychotics and 1/3 were treated with atypical antipsychotics reflecting the changes in treatment guidelines over time. Differences in the effect of typical and atypical antipsychotic medication on neuroplasia have been observed previously and discussed (McClure *et al.* 2006). In ongoing work, first-episode patients are usually treated with atypical antipsychotics, therefore we plan to repeat the present study in these patients.

A limitation of our study was the use of two separate patient groups. This design does not allow for the exclusion of a possible confound of inherent group differences. A longitudinal study of a single cohort of patients, each serving as their own control, would be the optimal to unequivocally demonstrate drug treatment effects on brain morphology and is currently in progress. The results presented here motivate further research into antipsychotic drug actions in patients with first-episode schizophrenia early in the course of treatment and sharpen a focus on the precise mechanisms by which medication may increase grey-matter volume and thereby reduce symptoms of psychosis.

In conclusion, our data indicate that greater striatal volumes in patients treated with antipsychotic drugs compared to never-treated patients are present after

just 3 weeks. This extends our previous report of striatal deficits in untreated patients with first-episode psychosis (Chua *et al.* 2007). We propose that, in addition to acting as a useful disease marker (Chua *et al.* 2007), caudate nuclear volume may represent a useful indicator of early recovery in schizophrenia.

### Acknowledgments

Dr S. E. Chua was supported by the University of Hong Kong Committee for Conference and Research Grants (CRCG). We thank the patients for their participation and staff of the Radiology Department, Queen Mary Hospital for MRI scanning.

### Declaration of Interest

None.

### References

- Agid O, Kapur S, Warrington L, Loebel A, Siu C (2008). Early onset of antipsychotic response in the treatment of acutely agitated patients with psychotic disorders. *Schizophrenia Research* **102**, 241–248.
- APA (1994). *Diagnostic and Statistical Manual of Mental Disorders*, 4th edn. American Psychiatric Association: Washington, DC.
- Barta PE, Dyingra L, Royall R, Schwartz E (1997). Improving stereological estimates for the volume of structures identified in three-dimensional arrays of spatial data. *Journal of Neuroscience Methods* **75**, 111–118.
- Bullmore ET, Suckling J, Overmeyer S, Rabe-Hesketh S, Taylor E, Brammer MJ (1999). Global, voxel, and cluster tests, by theory and permutation, for a difference between two groups of structural MR images of the brain. *IEEE Transactions on Medical Imaging* **18**, 32–42.
- Chakos MH, Lieberman JA, Bilder RM, Borenstein M, Lerner G, Bogerts B, Wu H, Kinon B, Ashtari M (1994). Increase in caudate nuclei volumes of first-episode schizophrenic patients taking antipsychotic drugs. *American Journal of Psychiatry* **151**, 1430–1436.
- Chen EY, Dunn EL, Miao MY, Yeung WS, Wong CK, Chan WF, Chen RY, Chung KF, Tang WN (2005). The impact of family experience on the duration of untreated psychosis (DUP) in Hong Kong. *Social Psychiatry and Psychiatric Epidemiology* **40**, 350–356.
- Chua SE, Cheung C, Cheung V, Tsang JT, Chen EY, Wong JC, Cheung JP, Yip L, Tai KS, Suckling J, McAlonan GM (2007). Cerebral grey, white matter and CSF in never-medicated, first-episode schizophrenia. *Schizophrenia Research* **89**, 12–21.
- Corson PW, Nopoulos P, Andreasen NC, Heckel D, Arndt S (1999). Caudate size in first-episode neuroleptic-naive schizophrenic patients measured using an artificial neural network. *Biological Psychiatry* **46**, 712–720.
- Corson PW, O'Leary DS, Miller DD, Andreasen NC (2002). The effects of neuroleptic medications on basal ganglia

- blood flow in schizophreniform disorders: a comparison between the neuroleptic-naive and medicated states. *Biological Psychiatry* **52**, 855–862.
- Crespo-Facorro B, Perez-Iglesias R, Ramirez-Bonilla M, Martinez-Garcia O, Llorca J, Vazquez-Barquero JL** (2006). A practical clinical trial comparing haloperidol, risperidone, and olanzapine for the acute treatment of first-episode nonaffective psychosis. *Journal of Clinical Psychiatry* **67**, 1511–1521.
- Dazzan P, Morgan KD, Orr KG, Hutchinson G, Chitnis X, Suckling J, Fearon P, Salvo J, McGuire PK, Mallett RM, Jones PB, Leff J, Murray RM** (2004). The structural brain correlates of neurological soft signs in AESOP first-episode psychoses study. *Brain* **127**, 143–153.
- Garver DL, Holcomb JA, Christensen JD** (2005). Cerebral cortical gray expansion associated with two second-generation antipsychotics. *Biological Psychiatry* **58**, 62–66.
- Girgis RR, Diwadkar VA, Nutche JJ, Sweeney JA, Keshavan MS, Hardan AY** (2006). Risperidone in first-episode psychosis: a longitudinal, exploratory voxel-based morphometric study. *Schizophrenia Research* **82**, 89–94.
- Gur RE, Cowell P, Turetsky BI, Gallacher F, Cannon T, Bilker W, Gur RC** (1998). A follow-up magnetic resonance imaging study of schizophrenia: relationship of neuroanatomical changes to clinical and neurobehavioral measures. *Archives of General Psychiatry* **55**, 145–152.
- Hafner H, Riecher-Rossler A, Hambrecht M, Maurer K, Meissner S, Schmidtke A, Fatkenheuer B, Loffler W, van der Heiden W** (1992). IRAOS: an instrument for the assessment of onset and early course of schizophrenia. *Schizophrenia Research* **6**, 209–223.
- Harrison PJ** (1999). The neuropathology of schizophrenia: a critical review of the data and their interpretation. *Brain* **122**, 593–624.
- Jayakumar PN, Venkatasubramanian G, Keshavan MS, Srinivas JS, Gangadhar BN** (2006). MRI volumetric and 31P MRS metabolic correlates of caudate nucleus in antipsychotic-naive schizophrenia. *Acta Psychiatrica Scandinavica* **114**, 346–351.
- Johnstone EC, Crow TJ, Frith CD, Carney MW, Price JS** (1978). Mechanism of the antipsychotic effect in the treatment of acute schizophrenia. *Lancet* **1**, 848–851.
- Kay SR, Fiszbein A, Opler LA** (1987). The Positive and Negative Syndrome Scale (PANSS) for schizophrenia. *Schizophrenia Bulletin* **13**, 261–276.
- Keshavan MS** (1999). Development, disease and degeneration in schizophrenia: a unitary pathophysiological model. *Journal of Psychiatric Research* **33**, 513–521.
- Kippin TE, Kapur S, van der Kooy D** (2005). Dopamine specifically inhibits forebrain neural stem cell proliferation, suggesting a novel effect of antipsychotic drugs. *Journal of Neuroscience* **25**, 5815–5823.
- Konradi C, Heckers S** (2001). Antipsychotic drugs and neuroplasticity: insights into the treatment and neurobiology of schizophrenia. *Biological Psychiatry* **50**, 729–742.
- Laruelle M** (2000). The role of endogenous sensitization in the pathophysiology of schizophrenia: implications from recent brain-imaging studies. *Brain Research Reviews* **31**, 371–384.
- Leucht S, Busch R, Hamann J, Kissling W, Kane JM** (2005). Early-onset hypothesis of antipsychotic drug action: a hypothesis tested, confirmed and extended. *Biological Psychiatry* **57**, 1543–1549.
- Massana G, Salgado-Pineda P, Junque C, Perez M, Baeza I, Pons A, Massana J, Navarro V, Blanch J, Morer A, Mercader JM, Bernardo M** (2005). Volume changes in gray matter in first-episode neuroleptic-naive schizophrenic patients treated with risperidone. *Journal of Clinical Psychopharmacology* **25**, 111–117.
- McAlonan GM, Cheung V, Cheung C, Suckling J, Lam GY, Tai KS, Yip L, Murphy DG, Chua SE** (2005). Mapping the brain in autism: a voxel-based MRI study of volumetric differences and intercorrelations in autism. *Brain* **128**, 268–276.
- McAlonan GM, Daly E, Kumari V, Critchley HD, van Amelsvoort T, Suckling J, Simmons A, Sigmundsson T, Greenwood K, Russell A, Schmitz N, Happe F, Howlin P, Murphy DG** (2002). Brain anatomy and sensorimotor gating in Asperger's syndrome. *Brain* **125**, 1594–1606.
- McClure RK, Phillips I, Jazayerli R, Barnett A, Coppola R, Weinberger DR** (2006). Regional change in brain morphometry in schizophrenia associated with antipsychotic treatment. *Psychiatry Research* **148**, 121–132.
- Murphy DG, DeCarli C, Schapiro MB, Rapoport SI, Horwitz B** (1992). Age-related differences in volumes of subcortical nuclei, brain matter, and cerebrospinal fluid in healthy men as measured with magnetic resonance imaging. *Archives of Neurology* **49**, 839–845.
- Pilowsky LS** (2001). Probing targets for antipsychotic drug action with PET and SPET receptor imaging. *Nuclear Medicine Communications* **22**, 829–833.
- Rushworth MF, Buckley MJ, Behrens TE, Walton ME, Bannerman DM** (2007). Functional organization of the medial frontal cortex. *Current Opinion in Neurobiology* **17**, 220–227.
- Shenton ME, Dickey CC, Frumin M, McCarley RW** (2001). A review of MRI findings in schizophrenia. *Schizophrenia Research* **49**, 1–52.
- Sigmundsson T, Suckling J, Maier M, Williams S, Bullmore E, Greenwood K, Fukuda R, Ron M, Toone B** (2001). Structural abnormalities in frontal, temporal, and limbic regions and interconnecting white matter tracts in schizophrenic patients with prominent negative symptoms. *American Journal of Psychiatry* **158**, 234–243.
- Suckling J, Brammer MJ, Lingford-Hughes A, Bullmore ET** (1999a). Removal of extracerebral tissues in dual-echo magnetic resonance images via linear scale-space features. *Magnetic Resonance Imaging* **17**, 247–256.
- Suckling J, Bullmore E** (2004). Permutation tests for factorially designed neuroimaging experiments. *Human Brain Mapping* **22**, 193–205.
- Suckling J, Sigmundsson T, Greenwood K, Bullmore ET** (1999b). A modified fuzzy clustering algorithm for operator independent brain tissue classification of dual echo MR images. *Magnetic Resonance Imaging* **17**, 1065–1076.

**Tamminga CA, Vogel M, Gao X, Lahti AC, Holcomb HH** (2000). The limbic cortex in schizophrenia: focus on the anterior cingulate. *Brain Research Reviews* **31**, 364–370.

**Thompson PM, Vidal C, Giedd JN, Gochman P, Blumenthal J, Nicolson R, Toga AW, Rapoport JL** (2001). Mapping adolescent brain change reveals dynamic wave of accelerated gray matter loss in very early-onset schizophrenia. *Proceedings of the National Academy of Sciences USA* **98**, 11650–11655.

**Talairach J, Tournoux P** (1988). *Co-planar Stereotaxic Atlas of the Human Brain*. Thieme: Stuttgart.

**Wang H-D, Dunnivant FD, Jarman T, Deutch AY** (2004). Effects of antipsychotic drugs on neurogenesis in the forebrain of the adult rat. *Neuropsychopharmacology* **29**, 1230–1238.

**Weinberger DR, Lipska BK** (1995). Cortical maldevelopment, anti-psychotic drugs, and schizophrenia: a search for common ground. *Schizophrenia Research* **16**, 87–110.