

# *Rhipicephalus turanicus*, a new vector of *Hepatozoon canis*

ALESSIO GIANNELLI<sup>1</sup>, RICCARDO PAOLO LIA<sup>1</sup>, GIADA ANNOSCIA<sup>1</sup>,  
CANIO BUONAVOGLIA<sup>1</sup>, ELEONORA LORUSSO<sup>1</sup>, FILIPE DANTAS-TORRES<sup>1,2</sup>,  
GAD BANETH<sup>3</sup> and DOMENICO OTRANTO<sup>1\*</sup>

<sup>1</sup> *Dipartimento di Medicina Veterinaria, Università degli Studi di Bari, Valenzano, Bari, Italy*

<sup>2</sup> *Departamento de Imunologia, Centro de Pesquisas Aggeu Magalhães (Fiocruz-PE), Recife, Pernambuco, Brazil*

<sup>3</sup> *School of Veterinary Medicine, Hebrew University, Rehovot, Israel*

(Received 14 October 2016; revised 18 November 2016; accepted 21 November 2016; first published online 21 December 2016)

## SUMMARY

The distribution of *Hepatozoon canis* mainly encompasses areas where its main tick vector, *Rhipicephalus sanguineus* sensu lato, is present. However, the detection of this pathogen in dogs, foxes and golden jackals well outside the areas inhabited by this tick species reinforced the hypothesis that additional ixodids are involved in the life cycle and transmission of this protozoon. The present study provides, for the first time, data supporting the sporogonic development of *H. canis* in specimens of *Rhipicephalus turanicus* collected from a naturally infected fox from southern Italy. The epidemiological role of *R. turanicus* as a vector of *H. canis* is discussed, along with information on the potential use of cell cultures for the experimental infection with *H. canis* sporozoites. The *in vitro* infection of canine leucocytes by sporozoites from ticks is proposed as a potential tool for future in-depth studies on the biology of *H. canis*.

Key words: *Hepatozoon canis*, *Rhipicephalus turanicus*, cells, tick, development, tick-borne pathogen, fox, sporogony.

## INTRODUCTION

The genus *Hepatozoon* (Eucoccidiorida, Hepatozoidae) includes about 340 species, which develop in reptiles, amphibians, rodents, birds or mammals. In spite of the wide variety of natural hosts involved in the life cycles of these protozoa (Smith, 1996), all *Hepatozoon* species share similar biology and a rather unique transmission pathway: the ingestion of infectious sporozoites (Smith, 1996). Indeed, once the definitive host (i.e. an haematophagous invertebrate) is ingested by a vertebrate intermediate host, sporozoites reach the blood or lymphatic circulation (Baneth *et al.* 2007). Merogony takes place in different target tissues, including lymphatic organs, muscles or the bone marrow, and micromerozoites penetrate erythrocytes of all vertebrates, but mammals and birds (Ferguson *et al.* 2012), in which gametogony occurs in leucocytes (Baneth *et al.* 2007). The life cycle completes when the invertebrate definitive host ingests blood cells parasitized by gamonts, which undergo sexual reproduction (syzygy) and sporogony in the vector haemocoel or in its gut wall, finally maturing into sporozoites enclosed within sporocysts in an oocyst (Smith, 1996).

Amongst *Hepatozoon* protozoa affecting carnivores, *Hepatozoon canis* James, 1905 is the most extensively studied and widespread species (Baneth, 2011), parasitizing dogs (*Canis familiaris*), cats (*Felis catus*) (Baneth, 2011), foxes (*Vulpes vulpes*, *Cerocyon thous*) (Alencar *et al.* 1997;

Gabrielli *et al.* 2010; Hodžić *et al.* 2015; Tolnai *et al.* 2015), jackals (*Canis aureus*, *Canis mesomelas*) (McCully *et al.* 1975; Duscher *et al.* 2013; Farkas *et al.* 2014), wild dogs (*Lycaon pictus*) (Matjila *et al.* 2008), hyenas (*Crocuta crocuta*) and lions (*Panthera leo*) (Kelly *et al.* 2014; Williams *et al.* 2014). The distribution of *H. canis* encompasses large areas of tropical, subtropical and temperate regions (Baneth, 2011), generally overlapping the dispersion range of the cosmopolitan brown dog tick *Rhipicephalus sanguineus* sensu lato (Acari, Ixodidae), its main arthropod vector (Baneth, 2011; Giannelli *et al.* 2013a, b; Ramos *et al.* 2014). However, the detection of *H. canis* in carnivores well outside the areas inhabited by *R. sanguineus* (e.g. Slovakia, Czech Republic, Austria, Hungary) (Majláthová *et al.* 2007; Duscher *et al.* 2013; Tolnai *et al.* 2015; Mitková *et al.* 2016) has reinforced the hypothesis that additional ixodid ticks are involved in the life cycle and transmission of this protozoon.

In addition to the main vector, *Amblyomma ovale*, *Rhipicephalus microplus*, *Haemaphysalis longicornis* and *Haemaphysalis flava* ticks have been confirmed as definitive hosts for *H. canis* (Murata *et al.* 1995; Rubini *et al.* 2009; de Miranda *et al.* 2011; Demoner *et al.* 2013). Conversely, the amplification of *H. canis* DNA in *Ixodes ricinus*, *Ixodes canisuga*, *Ixodes hexagonus*, *Dermacentor reticulatus*, *Dermacentor marginatus* and *Rhipicephalus turanicus* (Hornok *et al.* 2013; Latrofa *et al.* 2014; Najm *et al.* 2014) accounted for their potential vector competence (Hamšíková *et al.* 2016). However, the possibility that these tick species could have acquired

\* Corresponding author: Dipartimento di Medicina Veterinaria, Università degli Studi di Bari, Valenzano, Bari, Italy. E-mail: domenico.otranto@uniba.it

*H. canis* DNA from an infected animal during their blood feeding (Giannelli *et al.* 2013a, b), makes this question still unanswered. For instance, the development of *H. canis* in *R. turanicus*, an ixodid tick morphologically similar and genetically close to *R. sanguineus* (Dantas-Torres *et al.* 2013), has been hypothesized (Kamani *et al.* 2013; Latrofa *et al.* 2014; Aktas, 2014), but never demonstrated.

The present study reports on the sporogonic development of *H. canis* in *R. turanicus* specimens, which were collected from a naturally infected fox from southern Italy. In addition, data on the *in vitro* infection of canine leucocytes with sporozoites obtained from mature *H. canis* sporocysts developed in this ixodid species are provided.

## MATERIALS AND METHODS

### Sample collection

Ticks were collected from a young male fox, aging about 1 year, hospitalized at the Department of Veterinary Medicine of the University of Bari, following a road accident. The animal was rescued in the countryside of Valenzano municipality (41°043781N, 16°884203E, Bari province, southern Italy) and submitted to clinical investigations for a suspected fracture of the right tibia. The fox was infested by ixodid ticks and diagnosed as infected by *Hepatozoon* sp., following the detection of gamonts in blood smears, which were stained with the May-Grünwald Giemsa Quick Stain (Bio Optica, Milano, Italy). The level of parasitaemia was estimated based on the percentage of peripheral blood neutrophils containing intracellular gamonts. The blood sample was frozen, until molecularly analysed for the identification of the parasite at the species level.

### Tick identification and maintenance

A total of 19 engorged ticks were detached from the animal hair coat. Specimens were placed in plastic vials, secured with a cotton plug, and immediately identified at the stage and species level according to their morphology as *R. turanicus* ( $n=6$ , i.e. two males and four females), *I. hexagonus* ( $n=12$ , including six nymphs and six females) and *Haemaphysalis erinacei* (one female) (Manilla, 1998; Walker *et al.* 2000). In the case of *R. turanicus* specimens, the morphology of the adanal plates, accessory shields, spiracular plates and the genital opening were carefully examined (Dantas-Torres *et al.* 2013). The ticks were placed in an incubator under controlled conditions (i.e.  $20 \pm 3$  °C, RH > 80% for *I. hexagonus* and *H. erinacei*; and  $26 \pm 1$  °C, RH > 70% for *R. turanicus*), allowing the oviposition of females and moult of nymphs (Giannelli *et al.* 2013a, b). Specimens were daily monitored and, when egg

batches were laid, about 50 eggs were separated for subsequent DNA extraction (see below).

### Detection of *Hepatozoon* in dissected ticks

Ticks were dissected at different days post-collection (dpc) from the fox hair coat and examined for *Hepatozoon* oocysts, prioritizing specimens that completed the oviposition. Specimens of *R. turanicus* (two for each time-point) were analysed at the day of collection (T1), at 20 dpc (T2) and at 30 dpc (T3), whereas *I. hexagonus* specimens were examined at T2 and T3 (six ticks per each dissection time) and the female of *H. erinacei* at T3 (Table 1). Ticks were individually placed on slides containing a drop of saline solution and dissected by means of a sterile scalpel. They were incised through the spiracular plate and all the gut content, including the haemolymph, was observed under a light microscope at different magnifications. Oocysts were morphologically identified (Baneth *et al.* 2007; Giannelli *et al.* 2013b) and measurements (i.e. oocyst diameter and surface) were recorded for 15 specimens for each stage with an image analysis software (Leica®, LAS 4-1). In the case of immature oocysts, the ratio between the surface of the central nucleus and that of the oocyst was compared with Student's *t*-test. Differences were regarded significant when  $P < 0.05$ . Finally, all the dissected ticks were placed individually in sterile tubes with phosphate-buffered saline and stored at  $-20$  °C, until molecular analysis.

### Experimental infection of canine leucocytes with sporozoites

The infectivity of *H. canis* sporozoites to canine leucocytes was assessed by experimentally infecting dog monocytes. Briefly, cells were isolated from the blood of a donor dog in good clinical conditions and molecularly negative for other canine pathogens, including *H. canis*, after obtaining the owner consent. Blood samples were collected from the brachial vein in ethylenediaminetetraacetic acid (EDTA) tubes. The buffy coat was separated using Ficoll-Hypaque (Lymphedex, innotrain Diagnostik GmbH, Germany) and the leucocytes were cultured in RPMI 1640 medium, supplemented with 10% fetal calf serum (FCS) and antibiotics (penicillin  $5000$  IU mL<sup>-1</sup>, streptomycin  $2500$  µg mL<sup>-1</sup>, amphotericin B  $10$  µg mL<sup>-1</sup>). Cells were kept in a short-term culture at 37 °C. After 24 h, the medium was removed and the cells washed twice with FCS-free medium and inoculated with 100 µL tick homogenates, containing approximately 1000 *H. canis* previously activated sporozoites. Indeed, the oocysts (mechanically ruptured during dissection) and the sporocysts were suspended into 100 µL saline solution centrifuged at 250g for 10 min; the pellet was suspended in RPMI 1640

medium with 5% (w/v) fresh chicken bile and incubated at 37 °C for 30 min. Finally, the excysted sporozoites were concentrated by centrifugation (250g for 10 min), the supernatant containing the bile discarded, the pellet washed three times with saline solution, and the final aliquot was suspended in 100 µL RPMI 1640 culture medium. After an adsorption of 60 min at 37 °C, the inoculum was replaced with the FCS-free medium. The slides were removed 36 h after the inoculation and stained with the Diff Quick® (Bio Optica Spa, Italy) and examined under a light microscope. The infection procedure was performed in three short-term cultures.

#### Molecular analyses

DNA from the fox blood, ticks and eggs were extracted using a commercial kit (Qiagen, DNeasy Blood & Tissue Kit, Milan, Italy), following the manufacturer's instructions. Samples were tested by a conventional PCR for the detection of *Hepatozoon* (Inokuma *et al.* 2002). In addition, the identification of *Rhipicephalus* ticks was confirmed by generating and analysing partial mitochondrial *cox1* (600 bp) gene sequences, as already described elsewhere (Dantas-Torres *et al.* 2013). The PCR amplification was carried out in a total volume of 50 µL, including 100 ng of genomic DNA, 10 mM Tris-HCl (pH 8.3) and 50 mM KCl, 2.5 mM MgCl<sub>2</sub>, 250 µM of each dNTP, 50 pM of each primer and 1.25 U of AmpliTaq Gold (Applied Biosystems, Foster City, CA, USA). The reactions were run in a thermal cycler (2720, Applied Biosystems, Foster City, CA, USA). Negative (no DNA template, negative reference blood samples) and positive controls (*Hepatozoon* DNA from a positive tick) were included in all PCR reactions. Amplicons were resolved in ethidium bromide-stained agarose (Gellyphor, EuroClone, Milan, Italy) gels (1.5%) and sized by comparison with Gene Ruler™ 100-bp DNA Ladder (MBI Fermentas, Vilnius, Lithuania) as molecular marker, and finally gels were photographed using Gel Doc 2000 (BioRad, Hercules, CA, USA). All amplicons were resolved in GelRed-stained (2%) agarose (Biotium, California, USA) gels and sized by comparison with markers in the 1 kb DNA Ladder (MBI Fermentas, Vilnius, Lithuania). Gels were photographed using the GelLogic 100 gel documentation system (Kodak, New York, USA). Amplicons were purified and sequenced, in both directions using the same primers as for PCR, employing the Big Dye Terminator Cycle Sequencing Kit (v.3.1, Applied Biosystems, Foster City, California, USA) in an automated sequencer (ABI-PRISM 377). Sequences were compared with those available in the GenBank™ database, using Basic Local Alignment Search Tool (BLAST-<http://blast.ncbi.nlm.nih.gov/blast.cgi>).

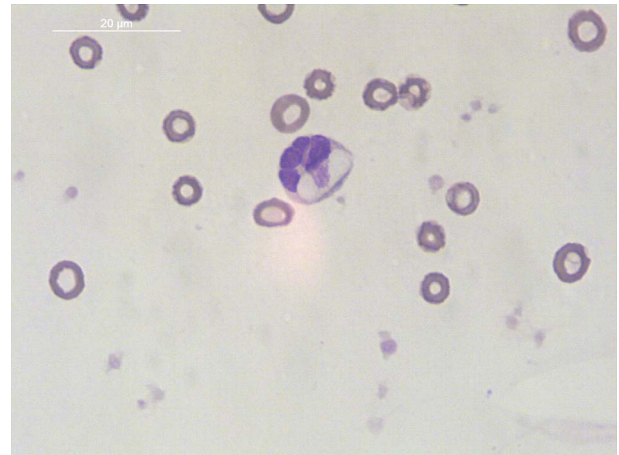


Fig. 1. Gamont of *H. canis* within fox monocyte (Diff quick stain, scale bar = 20 µm).

#### RESULTS

The *Hepatozoon* species found in the fox blood and in all positive tick specimens was molecularly identified as *H. canis*, showing 18S rRNA sequences 100% overall nucleotide BLAST identity with those of *H. canis* deposited in GenBank™ (accession number KJ605145). The level of parasitaemia in the fox was 60% (Fig. 1). All ticks survived during the observation period were dissected according to the study plan. Only three specimens of *R. turanicus* and two of *I. hexagonus* laid egg batches. None of the *I. hexagonus* nymphs moulted to adults.

The results of tick dissection for each follow-up point and tick specimen are reported in Table 1. More than 500 *H. canis* oocysts were detected in *R. turanicus* ticks, whereas the remaining ixodid species were negative. Immature oocysts were observed in ticks dissected soon after the collection (T1). They measured  $201 \pm 72.8 \times 138.8 \pm 48.6$  µm and displayed an amorphous central structure, condensed in a plasmatic matrix, similar to poached eggs (Fig. 2). Conversely, oocysts undergoing a different degree of maturation (Fig. 3) were detected in *R. turanicus* at T2, and included mature and undeveloped oocysts, lacking any sporocysts and sporozoites. In the latter, the ratio between the surface of the central nucleus and that of the oocyst (range: 32.5–82.4%) was significantly correlated with the oocyst diameter (*t*-test,  $P < 0.05$ ). Mature oval-shaped oocysts measured  $259.9 \pm 36.1 \times 246.1 \pm 33.9$  µm (Fig. 4) and contained a variable number of sporocysts, whose dimensions were  $32.1 \pm 4.7 \times 20.2 \pm 2$  µm. In ticks dissected at T3, only mature oocysts were detected, along with free sporocysts and sporozoites, with the latter being elongated in shape and measuring  $15.5 \pm 4.1 \times 3 \pm 0.6$  µm in diameter.

The positivity of all *R. turanicus* ticks examined at each time-point was molecularly confirmed, with all specimens being PCR-positive for *H. canis* and



Table 1. Number and developmental stage of *H. canis* oocysts (immature, IM or mature, M) detected in engorged ixoidid ticks (males, M; females, F; nymphs, N) examined at different dissection times, expressed as days post-collection from the fox

Dissection time	Tick stage and species	Oocysts detected/specimen
T1 (0)	2 M <i>R. turanicus</i>	I (10 IM), II (20 IM)
T2 (+20)	2 F <i>R. turanicus</i> <sup>a</sup>	I (23 IM, 43 M), II (36 IM, 103 M)
	3 N <i>I. hexagonus</i> <sup>b</sup>	–
	3 F <i>I. hexagonus</i>	–
T3 (+30)	2 F <i>R. turanicus</i>	I (121 M), I (226 M)
	3 N <i>I. hexagonus</i>	–
	3 F <i>I. hexagonus</i>	–
	1 F <i>H. erinacei</i>	–

<sup>a</sup> All females collected were allowed to oviposit, being dissected only when egg laying was concluded/interrupted.

<sup>b</sup> None of *I. hexagonus* nymphs moulted to the adult stage.

molecularly identified as *R. turanicus* (*cox1* sequences showed 100% homology to *R. turanicus* sequences deposited in GenBank™, accession number KF145153.1) None of the *I. hexagonus* and *H. erinacei* specimens examined was positive for *H. canis*, as well as the egg batches collected from all female ticks that oviposited.

Following exposure to chicken bile, sporozoites were activated and displayed gliding and flexion–extension movements, often clustering together. These cells were featured by a diaphanous body and an eccentric nucleus (Fig. 5). The percentage of monocytes infected with *H. canis* in the three short-term cultures after 36 h from the inoculation was 34, 18 and 58%, respectively, with a mean 36.7% cells parasitized by *H. canis* sporozoites, which were observed within the leucocyte cytoplasm (Fig. 5).

#### DISCUSSION

Results of this study demonstrate that *R. turanicus* is a suitable vector for *H. canis*, as corroborated by its sporogonic development to reach the sporozoite stage, and by following the successful experimental infection of canine leucocytes. So far, only a few ixoidid species (i.e. *R. sanguineus* s.l., *A. ovale*, *R. microplus*, *H. longicornis*, *H. flava*) have been considered as definitive hosts for *H. canis* (Murata *et al.* 1995; de Miranda *et al.* 2011; Demoner *et al.* 2013), whereas others (e.g. *I. ricinus* or *D. reticulatus*) have been accounted as potential vectors (Hornok *et al.* 2013; Latrofa *et al.* 2014; Najm *et al.* 2014) but their role has never been demonstrated. Besides the results of previous surveys, which highlighted the presence of the pathogen DNA in *R. turanicus* (Kamani *et al.* 2013; Aktas, 2014; Latrofa *et al.* 2014) or in other ‘cryptic’ species included in the

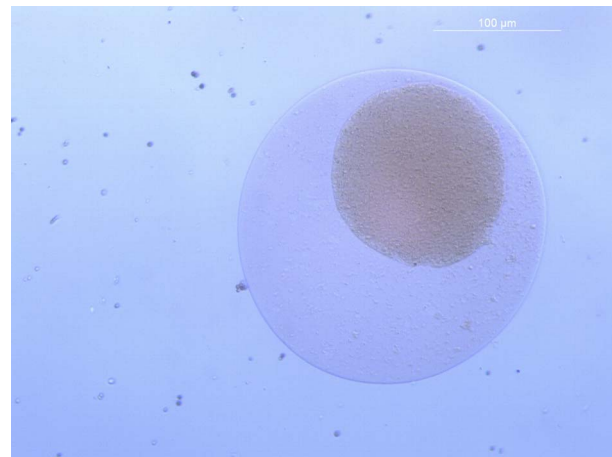

Fig. 2. Immature *H. canis* oocysts detected in the haemocoel of a male *R. turanicus* (scale bar = 100 μm) at T1.

*R. sanguineus* complex (Latrofa *et al.* 2014), the potential development of *H. canis* in *R. turanicus* has never been evaluated, until now. The detection of immature and mature *H. canis* oocysts in *R. turanicus* accounts for the transtadial transmission of this pathogen, as it most likely occurred from nymphs to adults. In addition, the potential for the interstadial transmission from larvae to nymphs cannot be ruled out, as recently found for *R. sanguineus* (Giannelli *et al.* 2013b). Due to the opportunistic collection of the infected fox, it was not possible to define the exact time when *H. canis* syzygy and sporogony occurred in *R. turanicus* ticks. Nonetheless, the finding of mature oocysts in ticks detached after 20 days indicates that the pathogen requires at least 1 month for reaching its infective stage in *R. turanicus*. This corroborates observations drawn in *R. sanguineus* nymphs, in which *H. canis* fully matures in about 30 days (Giannelli *et al.* 2013b). Conversely, the developmental time reported in *A. ovale* and *R. sanguineus* adults ranges from 11 to 14 days and from 27 to 53 days, respectively (Baneth *et al.* 2007; Rubini *et al.* 2009). The possibility that the pathogen development is affected by the moulting time of the tick species should be taken into account.

The morphology and size of *H. canis* stages detected in *R. turanicus* is consistent with that found in *R. sanguineus* s.l. (i.e. 240–300 μm) (Baneth *et al.* 2007; Giannelli *et al.* 2013a, b), *A. ovale* (210–306 μm) (Rubini *et al.* 2009) and *H. flava*/*H. longicornis* (300 μm) (Murata *et al.* 1995). Interestingly, the detection of a wide dimension range for mature oocysts (i.e. 259.9 ± 36.1 × 246.1 ± 33.9 μm) could be related to their abundance in the infected ticks. While a correlation probably exists between the number, the diameter of oocysts and the tick body dimension, results may also indicate that parasite growth can be slowed due to crowding, as already suggested for *Hepatozoon griseisciuri* in its vector *Haemogamasus reidi* (Redington and Jachowski, 1971).

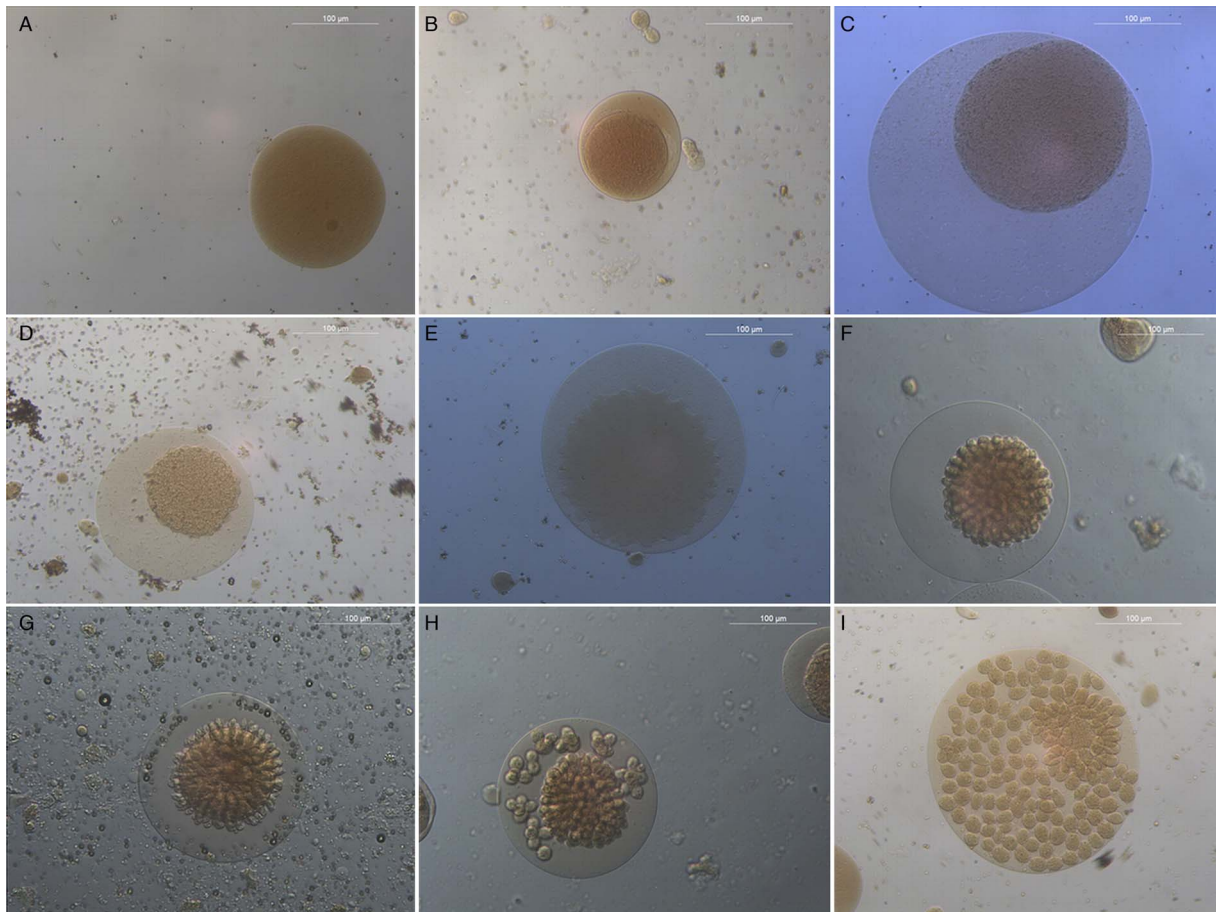


Fig. 3. Footage showing the sporogony of *H. canis* in a female *R. turanicus* at T2. Following syzyzy, a zygote develops into a small immature oocyst (A); the oocyst membrane separates from the sporont (B) and its diameter increases along with complete development (C); the sporont nucleus becomes granular (D) and ameboid processes depart from the centre (E), budding into a protrusion or sporoblast (F), that gives rise to a developing sporocyst (G). This stage progressively reaches its final club shape (G), and detaches itself from the sporont mass (H). Developing sporozoites mature within the sporocyst wall (I) (scale bar = 100 µm).

The detection of *H. canis* in *R. turanicus* might have relevant implications for understanding the distribution of this tick-borne pathogen in areas where *R. sanguineus* s.l. is not present. Unlike the brown dog tick, *R. turanicus* display a wider host preference, with the immature stages often feeding on rodents or lagomorphs, and adults on domestic and wild mammals, including cattle, sheep, goat and wildlife (e.g. hedgehogs, hares, jackals) (Manilla, 1998; Walker *et al.* 2000). *Rhipicephalus turanicus* is predominantly an exophilic tick, and its adaptability to different environmental and ecological conditions has favoured its setting and spreading in Mediterranean and dry regions, that, outside the African continent, include large parts of Asia and continental Europe (Nijhof *et al.* 2007; Waner *et al.* 2014; Toma *et al.* 2015; Çetinkaya *et al.* 2016; Millán *et al.* 2016). For example, *R. turanicus* rapidly colonized the island of Cyprus during the last 40 years, where it now seems to play an important role as spreader of zoonotic tick-borne pathogens, including *Coxiella burnetii*, *Anaplasma*

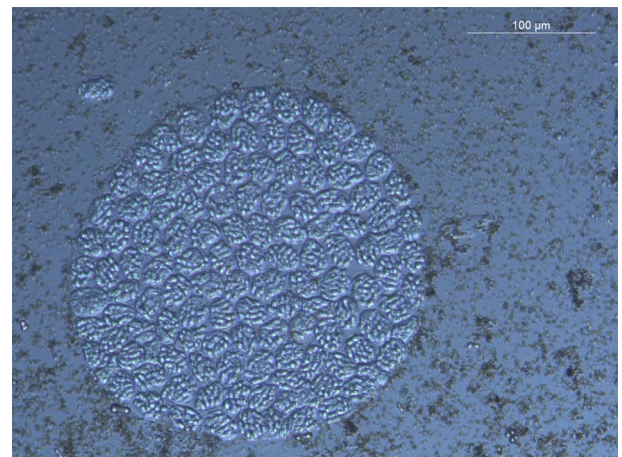


Fig. 4. Mature *H. canis* oocyst (scale bar = 100 µm) from a fed *R. turanicus* female at T3.

and *Rickettsia* species (Chochlakis *et al.* 2014). Similarly, this tick species was introduced in Austria, in areas where *R. sanguineus* s.l. ticks are not endemic (Sixl, 1972), but *H. canis* infection has

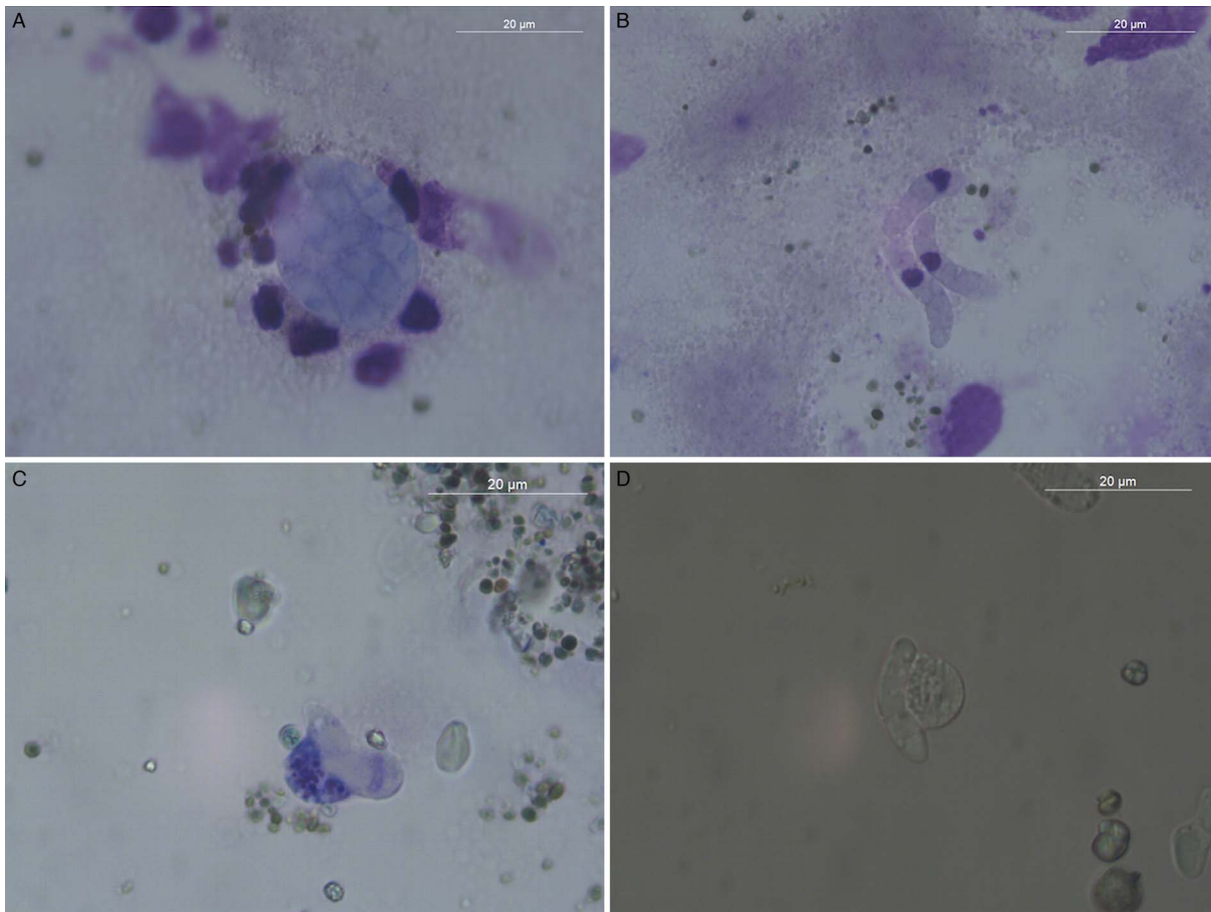


Fig. 5. *Hepatozoon canis* sporozoites following exposure to chicken bile and cell infection (scale bars = 20 µm). When not activated, sporozoites were observed within the sporocyst walls (A), or free in the cell medium (B). Early stage penetration of canine leucocytes by sporozoites (C and D).

been reported in wildlife (Duscher *et al.* 2013, 2014). Altogether, results suggest that *R. turanicus* might contribute to the spreading of this pathogen, taking part in its 'sylvatic' life cycle, as supported by the simultaneous detection of *H. canis* and *R. turanicus* in the red fox here examined. In fact, in view of their free-roaming behaviour, increasing population density and regular visits to sub-urban areas (Uspensky, 2014), foxes have been indicated as bridging hosts of several pathogens of domestic dogs, including *Echinococcus multilocularis*, *Angiostrongylus vasorum* and *H. canis* (Otranto *et al.* 2015a, b). In addition, a new species of *Hepatozoon*, (i.e. *Hepatozoon silvestris* sp. nov.) has been recently described in wild felids, enforcing the concept of pathogen circulating between wild and domestic populations, when the same ecological niches are shared (Hodžić *et al.* 2016).

The infection of canine leucocytes with *H. canis* sporozoites indicates that this procedure may represent a valid alternative to experimental infection of laboratory-raised animals for investigating the biology of this canine tick-borne pathogen. The development of *Hepatozoon* protozoa in primary and continuous cell lines has been poorly

investigated, with the exception of early attempts on *H. griseisciuri* (Hendrick and Fayer, 1973) and *Hepatozoon rarefaciens* (Ball and Chao, 1973), which were cultured in mite and mosquitoes cells, respectively. The development of *H. canis* life cycle *in vitro* might provide interesting clues for defining its pathogenic role, for exploring the immunology and treatment of canine hepatozoonosis (De Tommasi *et al.* 2014) and also for providing a solid infrastructure for in-depth studies on its biology. In particular, the use of tick cell lines (Passos, 2012) may support the discovery of association between *Hepatozoon* species and additional ixodid ticks implicated in their transmission, a hypothesis that deserves further investigations.

#### ACKNOWLEDGMENT

The authors would like to thank Rossella Panarese (University of Bari) for her support during the study.

#### FINANCIAL SUPPORT

This research received no specific grant from any funding agency, commercial or not-for-profit sectors.



## REFERENCES

- Aktas, M. (2014). A survey of ixodid tick species and molecular identification of tick-borne pathogens. *Veterinary Parasitology* **200**, 276–283.
- Alencar, N. X., Kohayagawa, A., Santarém, V. A. (1997). *Hepatozoon canis* infection of wild carnivores in Brazil. *Veterinary Parasitology* **70**, 279–282.
- Ball, G. H., Chao, J. (1973). The complete development of the sporogonous stages of *Hepatozoon rarefaciens* cultured in a *Culex pipiens* cell line. *Journal of Parasitology* **59**, 513–515.
- Baneth, G. (2011). Perspectives on canine and feline hepatozoonosis. *Veterinary Parasitology* **181**, 3–11.
- Baneth, G., Samish, M., Shkap, V. (2007). Life cycle of *Hepatozoon canis* (Apicomplexa: Adeleorina: Hepatozoidae) in the tick *Rhipicephalus sanguineus* and domestic dog (*Canis familiaris*). *Journal of Parasitology* **93**, 283–299.
- Çetinkaya, H., Matur, E., Akyazi, İ., Ekiz, E. E., Aydin, L., Toparlak, M. (2016). Serological and molecular investigation of *Ehrlichia* spp. and *Anaplasma* spp. in ticks and blood of dogs, in the Thrace Region of Turkey. *Ticks and Tick Borne Diseases* **7**, 706–714.
- Chochlakakis, D., Ioannou, I., Papadopoulos, B., Tselentis, Y., Psaroulaki, A. (2014). *Rhipicephalus turanicus*: from low numbers to complete establishment in Cyprus. Its possible role as a bridge-vector. *Parasites and Vectors* **7** (Suppl. 1), P11.
- Dantas-Torres, F., Latrofa, M. S., Annoscia, G., Giannelli, A., Parisi, A., Otranto, D. (2013). Morphological and genetic diversity of *Rhipicephalus sanguineus* sensu lato from the New and Old Worlds. *Parasites and Vectors* **6**, 213.
- de Miranda, R. L., de Castro, J. R., Olegário, M. M., Beletti, M. E., Mundim, A. V., O'Dwyer, L. H., Eyal, O., Talmi-Frank, D., Cury, M. C., Baneth, G. (2011). Oocysts of *Hepatozoon canis* in *Rhipicephalus (Boophilus) microplus* collected from a naturally infected dog. *Veterinary Parasitology* **177**, 392–396.
- De Tommasi, A. S., Giannelli, A., de Caprariis, D., Ramos, R. A., Di Paola, G., Crescenzo, G., Dantas-Torres, F., Baneth, G., Otranto, D. (2014). Failure of imidocarb dipropionate and toltrazuril/emodepside plus clindamycin in treating *Hepatozoon canis* infection. *Veterinary Parasitology* **200**, 242–245.
- Demoner, L. C., Rubini, A. S., Paduan Kdos, S., Metzger, B., de Paula Antunes, J. M., Martins, T. F., Mathias, M. I., O'Dwyer, L. H. (2013). Investigation of tick vectors of *Hepatozoon canis* in Brazil. *Ticks and Tick Borne Diseases* **4**, 542–546.
- Duscher, G. G., Kübber-Heiss, A., Richter, B., Suchentrunk, F. (2013). A golden jackal (*Canis aureus*) from Austria bearing *Hepatozoon canis* – import due to immigration into a non-endemic area? *Ticks and Tick Borne Diseases* **4**, 133–137.
- Duscher, G. G., Leschnik, M., Fuehrer, H. P., Joachim, A. (2014). Wildlife reservoirs for vector-borne canine, feline and zoonotic infections in Austria. *International Journal for Parasitology: Parasites and Wildlife* **4**, 88–96.
- Farkas, R., Solymosi, N., Takács, N., Hornyák, Á., Hornok, S., Nachum-Biala, Y., Baneth, G. (2014). First molecular evidence of *Hepatozoon canis* infection in red foxes and golden jackals from Hungary. *Parasites and Vectors* **7**, 303.
- Ferguson, L. V., Kirk Hillier, N., Smith, T. G. (2012). Influence of *Hepatozoon* parasites on host-seeking and host-choice behaviour of the mosquitoes *Culex territans* and *Culex pipiens*. *International Journal for Parasitology: Parasites and Wildlife* **2**, 69–76.
- Gabrielli, S., Kumlien, S., Calderini, P., Brozzi, A., Iori, A., Cancrini, G. (2010). The first report of *Hepatozoon canis* identified in *Vulpes vulpes* and ticks from Italy. *Vector Borne Zoonotic Diseases* **10**, 855–859.
- Giannelli, A., Ramos, R. A., Dantas-Torres, F., Mencke, N., Baneth, G., Otranto, D. (2013a). Experimental evidence against transmission of *Hepatozoon canis* by *Ixodes ricinus*. *Ticks and Tick Borne Diseases* **4**, 391–394.
- Giannelli, A., Ramos, R. A., Di Paola, G., Mencke, N., Dantas-Torres, F., Baneth, G., Otranto, D. (2013b). Transstadial transmission of *Hepatozoon canis* from larvae to nymphs of *Rhipicephalus sanguineus*. *Veterinary Parasitology* **196**, 1–5.
- Hamšíková, Z., Silaghi, C., Rudolf, I., Venčíková, K., Mahříková, L., Slovák, M., Mendel, J., Blažejová, H., Berthová, L., Kocianová, E., Hubálek, Z., Schnittger, L., Kazimírová, M. (2016). Molecular detection and phylogenetic analysis of *Hepatozoon* spp. in questing *Ixodes ricinus* ticks and rodents from Slovakia and Czech Republic. *Parasitology Research* **115**, 3897–3890.
- Hendrick, L. D., Fayer, R. (1973). Development of *Hepatozoon griseisciuri* in Cultured Squirrel Cells. *Journal of Protozoology* **2**, 550–554.
- Hodžić, A., Alić, A., Fuehrer, H. P., Harl, J., Wille-Piazzai, W., Duscher, G. G. (2015). A molecular survey of vector-borne pathogens in red foxes (*Vulpes vulpes*) from Bosnia and Herzegovina. *Parasites and Vectors* **8**, 88.
- Hodžić, A., Alić, A., Prašović, S., Otranto, D., Baneth, G., Duscher, G. G. (2016). *Hepatozoon silvestris* sp. nov.: morphological and molecular characterization of a new *Hepatozoon* species (Adeleorina: Hepatozoidae) from the European wild cat (*Felis silvestris silvestris*). *Parasitology*. doi: <https://doi.org/10.1017/S0031182016002316>.
- Hornok, S., Tanczos, B., Fernández de Mera, I. G., de la Fuente, J., Hofmann-Lehmann, R., Farkas, R. (2013). High prevalence of *Hepatozoon*-infection among shepherd dogs in a region considered to be free of *Rhipicephalus sanguineus*. *Veterinary Parasitology* **196**, 189–193.
- Inokuma, H., Okuda, M., Ohno, K., Shimoda, K., Onishi, T. (2002). Analysis of the 18S rRNA gene sequence of a *Hepatozoon* detected in two Japanese dogs. *Veterinary Parasitology* **106**, 265–271. PubMed PMID: 12062514.
- Kamani, J., Baneth, G., Mumcuoglu, K. Y., Waziri, N. E., Eyal, O., Guthmann, Y., Harrus, S. (2013). Molecular detection and characterization of tick-borne pathogens in dogs and ticks from Nigeria. *PLoS Neglected Tropical Diseases* **7**, e2108.
- Kelly, P., Marabini, L., Dutlow, K., Zhang, J., Loftis, A., Wang, C. (2014). Molecular detection of tick-borne pathogens in captive wild felids, Zimbabwe. *Parasites and Vectors* **7**, 514.
- Latrofa, M. S., Dantas-Torres, F., Giannelli, A., Otranto, D. (2014). Molecular detection of tick-borne pathogens in *Rhipicephalus sanguineus* group ticks. *Ticks and Tick Borne Diseases* **5**, 943–946.
- Majláthová, V., Hurníková, Z., Majláth, I., Petko, B. (2007). *Hepatozoon canis* infection in Slovakia: imported or autochthonous? *Vector Borne Zoonotic Diseases* **7**, 199–202.
- Manilla, G. (1998). *Fauna d'Italia, Acari-Isodida*. Edizioni Calderini, Bologna, Italy.
- Matjila, P. T., Leisewitz, A. L., Jongejan, F., Bertschinger, H. J., Penzhorn, B. L. (2008). Molecular detection of *Babesia rossi* and *Hepatozoon* sp. in African wild dogs (*Lycaon pictus*) in South Africa. *Veterinary Parasitology* **157**, 123–127.
- McCully, R. M., Basson, P. A., Bigalke, R. D., De Vos, V., Young, E. (1975). Observations on naturally acquired hepatozoonosis of wild carnivores and dogs in the Republic of South Africa. *Onderstepoort Journal of Veterinary Research* **42**, 117–133.
- Millán, J., Proboste, T., Fernández de Mera, I. G., Chirife, A. D., de la Fuente, J., Altet, L. (2016). Molecular detection of vector-borne pathogens in wild and domestic carnivores and their ticks at the human–wildlife interface. *Ticks and Tick Borne Diseases* **7**, 284–290.
- Mitková, B., Hrazdilová, K., Steinbauer, V., D'Amico, G., Mihalca, A. D., Modrý, D. (2016). Autochthonous *Hepatozoon* infection in hunting dogs and foxes from the Czech Republic. *Parasitology Research* **115**, 4167–4171.
- Murata, T., Inoue, M., Taura, Y., Nakama, S., Abe, H., Fujisaki, K. (1995). Detection of *Hepatozoon canis* oocyst from ticks collected from the infected dogs. *Journal of Veterinary Medical Sciences* **57**, 111–122.
- Najm, N. A., Meyer-Kayser, E., Hoffmann, L., Pfister, K., Silaghi, C. (2014). *Hepatozoon canis* in German red foxes (*Vulpes vulpes*) and their ticks: molecular characterization and the phylogenetic relationship to other *Hepatozoon* spp. *Parasitology Research* **113**, 2679–2685.
- Nijhof, A. M., Bodaan, C., Postigo, M., Nieuwenhuijs, H., Opsteegh, M., Franssen, L., Jebbink, F., Jongejan, F. (2007). Ticks and associated pathogens collected from domestic animals in the Netherlands. *Vector Borne Zoonotic Diseases* **7**, 585–595.
- Otranto, D., Cantacessi, C., Dantas-Torres, F., Brianti, E., Pfeffer, M., Genchi, C., Guberti, V., Capelli, G., Deplazes, P. (2015a). The role of wild canids and felids in spreading parasites to dogs and cats in Europe. Part II: helminths and arthropods. *Veterinary Parasitology* **213**, 24–37.
- Otranto, D., Cantacessi, C., Pfeffer, M., Dantas-Torres, F., Brianti, E., Deplazes, P., Genchi, C., Guberti, V., Capelli, G. (2015b). The role of wild canids and felids in spreading parasites to dogs and cats in Europe. Part I: protozoa and tick-borne agents. *Veterinary Parasitology* **213**, 12–23.
- Passos, L. M. (2012). *In vitro* cultivation of *Anaplasma marginale* and *A. phagocytophilum* in tick cell lines: a review. *Revista Brasileira Parasitologia Veterinaria* **21**, 81–86.
- Ramos, R. A., Giannelli, A., Carbone, D., Baneth, G., Dantas-Torres, F., Otranto, D. (2014). Occurrence of *Hepatozoon canis* and *Cercopithifilaria bairnei* in an off-host population of *Rhipicephalus sanguineus* sensu lato ticks. *Ticks and Tick Borne Diseases* **5**, 311–314.
- Redington, B. C., Jachowski, L. A. (1971). Syngamy and sporogony of *Hepatozoon griseisciuri* Clark, 1958 (Sporozoa: Haemogregarinidae), in its

natural vector, *Haemogamasus reidi* Ewing, 1925 (Acari: Mesostigmata). *Journal of Parasitology* **57**, 953–960.

**Rubini, A. S., Paduan, K. S., Martins, T. F., Labruna, M. B., O'Dwyer, L. H.** (2009). Acquisition and transmission of *Hepatozoon canis* (Apicomplexa: Hepatozoidae) by the tick *Amblyomma ovale* (Acari: Ixodidae). *Veterinary Parasitology* **164**, 324–327.

**Sixl, W.** (1972). Drie weitere Zeckenarten in Osterreich. *Mitteilungen der Abteilung für Zoologischen des Landesmuseums joanneum* **1**, 51–52.

**Smith, T. G.** (1996). The genus *Hepatozoon* (Apicomplexa: Adeleina). *Journal of Parasitology* **82**, 565–585.

**Tolnai, Z., Sréter-Lancz, Z., Sréter, T.** (2015). Spatial distribution of *Anaplasma phagocytophilum* and *Hepatozoon canis* in red foxes (*Vulpes vulpes*) in Hungary. *Ticks and Tick Borne Diseases* **6**, 645–648.

**Toma, L., Khoury, C., Bianchi, R., Severini, F., Mancini, F., Ciervo, A., Ricci, D., Fausto, A. M., Quarchioni, E., Di Luca, M.** (2015). Preliminary investigation on tick fauna in the neighbourhood

of Tarquinia, Lazio, Italy. *Annali dell'Istituto Superiore di Sanità* **51**, 67–70.

**Uspensky, I.** (2014). Tick pests and vectors (Acari: Ixodoidea) in European towns: introduction, persistence and management. *Ticks and Tick Borne Diseases* **5**, 41–47.

**Walker, J. B., Keirans, J. E., Horak, I. G.** (2000). *The Genus Rhipicephalus (Acari, Ixodidae): A Guide to the Brown Ticks of the World*. Cambridge University Press, Cambridge, UK.

**Waner, T., Keysary, A., Eremeeva, M. E., Din, A. B., Mumcuoglu, K. Y., King, R., Atiya-Nasagi, Y.** (2014). *Rickettsia africae* and *Candidatus Rickettsia barbariae* in ticks in Israel. *American Journal of Tropical Medicine and Hygiene* **90**, 920–922.

**Williams, B. M., Berentsen, A., Shock, B. C., Teixeira, M., Dunbar, M. R., Becker, M. S., Yabsley, M. J.** (2014). Prevalence and diversity of *Babesia*, *Hepatozoon*, *Ehrlichia*, and *Bartonella* in wild and domestic carnivores from Zambia, Africa. *Parasitology Research* **113**, 911–918.