

Re-evaluation of endogenous development of *Eimeria bareillyi* Gill, Chhabra and Lall, 1963 in water buffalo (*Bubalus bubalis*)

Research Article

Cite this article: Dubey J P (2018). Re-evaluation of endogenous development of *Eimeria bareillyi* Gill, Chhabra and Lall, 1963 in water buffalo (*Bubalus bubalis*). *Parasitology* **145**, 1845–1852. <https://doi.org/10.1017/S0031182018000604>

Received: 16 February 2018

Revised: 13 March 2018

Accepted: 13 March 2018

First published online: 25 April 2018

Key words:

Bubalus bubalis; *Eimeria bareillyi*; macrogamonts; microgamonts; oocysts

Author for correspondence:

J. P. Dubey, E-mail: jitender.dubey@ars.usda.gov

J. P. Dubey

United States Department of Agriculture, Agricultural Research Service, Animal Parasitic Diseases Laboratory, Beltsville Agricultural Research Center, Beltsville, Maryland 20705-2350, USA

Abstract

Water buffalo (*Bubalus bubalis*) is important for the economy of Asia, South America and parts of Europe. Coccidiosis is an important cause of neonatal mortality in livestock, including buffalo. Of more than 12 species of *Eimeria* in buffalo, *Eimeria bareillyi* is the most pathogenic. There are uncertainties concerning its asexual and sexual development. During a previously reported outbreak of fatal enteritis associated with *E. bareillyi* in buffaloes in the Netherlands, sections of small intestine were re-evaluated histologically and by transmission electron microscopy (TEM) to seek details of endogenous development. Profuse asexual multiplication occurred in the jejunum and ileum. Light microscopic examination revealed that parasites divided in two (probably endodyogeny) or more organisms. There were two or more generations of morphologically different merozoites; some of these observations were confirmed by TEM. Details of gametogonic development, including oocyst wall formation are provided. Schizogonic and gametogonic development described in the present study can serve as a guide for differential diagnosis of *Eimeria* species in histological sections of intestines of buffaloes.

Introduction

The water buffalo (*Bubalus bubalis*) is important to the economy of several countries in Asia and South America, and there are isolated herds in Europe. In India, buffalo is the main dairy animal. Coccidiosis due to *Eimeria* is an important cause of diarrhoea in livestock, including buffalo. Buffalo and cattle (*Bos taurus*, *Bos indicus*) are considered to have more than 10 common species of *Eimeria* (Levine and Ivens, 1970); of these *Eimeria bovis*, *Eimeria zuernii*, *Eimeria auburnensis* and *Eimeria alabamensis* are considered the most pathogenic for cattle (Levine, 1973) but I am not aware of any report of histologically confirmed clinical coccidiosis in buffalo associated with these five *Eimeria* species. Instead, *Eimeria bareillyi* has been documented to be the main pathogenic species in buffaloes; it is not transmissible to cattle (Sanyal *et al.* 1985).

Eimeria bareillyi was first described from buffalo in India (Gill *et al.* 1963). Since then its oocysts have also been reported in buffalo feces from Brazil, Italy and Turkey (Sayin, 1973; Barbosa *et al.* 1992; Cringoli *et al.* 1998). *Eimeria bareillyi* is pathogenic in experimentally infected buffaloes (Shastri *et al.* 1973; Shastri and Ghafoor, 1982; Sanyal *et al.* 1985). Clinical coccidiosis in buffalo has been reported from India (Shastri *et al.* 1974, 1976; Shastri and Krishnamurthi, 1975), Brazil (Bastianetto *et al.* 2008; de Meireles *et al.* 2012) and the Netherlands (Dubey *et al.* 2008). Although endogenous development of *E. bareillyi* has been reported previously (Pande *et al.* 1971; Shastri *et al.* 1974, 1976; Shastri and Krishnamurthi, 1975; Shastri and Ghafoor, 1982; Dubey *et al.* 2008) many details are missing.

The purpose of the present communication is to describe in detail asexual and sexual development of *E. bareillyi* in a naturally infected buffalo.

Materials and methods

Materials and methods were same as described previously (Dubey *et al.* 2008). An outbreak of coccidiosis occurred in a well-managed buffalo farm in Limburg, the Netherlands. Nine of 22 calves born in November–December 2007 died after clinical illness with diarrhoea. The calves were born on slatted floor and then separated from dams. For one month, calves were housed individually in an igloo and then housed with other calves. Each calf received colostrum from its dam for the first 2 days and then were fed milk replacer. Diarrhoea was noticed in 3–6 weeks old calves and the calves died after 1 or 2 days after the farmer noticed diarrhoea. The present study is from a 22-day-old calf that was euthanized. A complete necropsy was performed and the cause of diarrhoea investigated. Other than *Eimeria*, bacterial, viral and other parasitic agents were not detected. A section of the jejunum and ileum was used for the present study. Numerous 3–4 μm sections stained with haematoxylin and eosin (HE), periodic acid Schiff (PAS) reaction with haematoxylin as counter stain, were examined for parasitic stages. Pieces of the jejunum from the paraffin block were deparaffinized and processed for

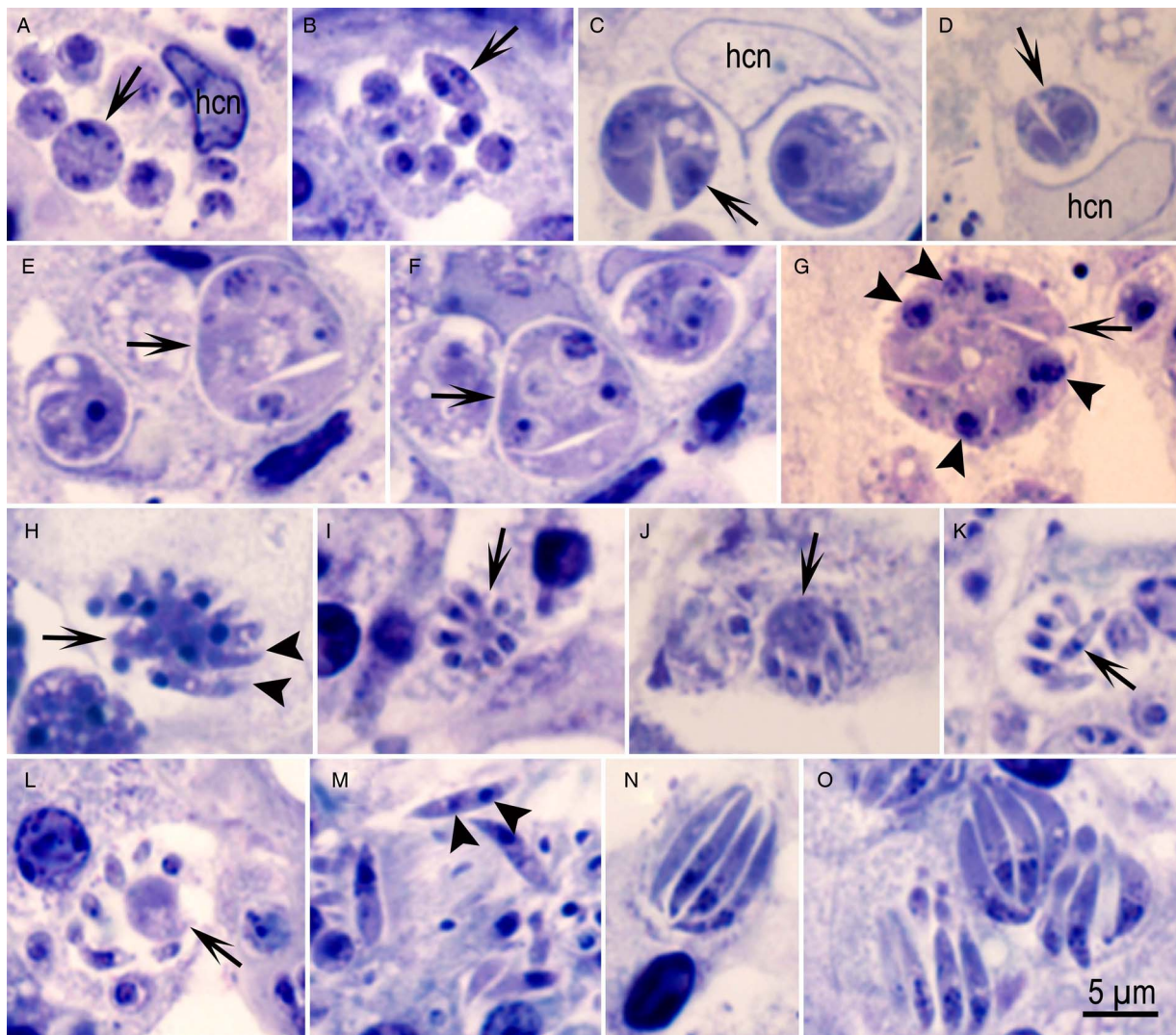


Fig. 1. Asexual stages of *Eimeria bareillyi* in the jejunum of a naturally infected 22-day-old buffalo. One micrometre sections stained with Toluidine blue. Bar applies to all parts. hcn = host cell nucleus. (A) A group of six different sized globular zoites in a parasitophorous vacuole of an enterocyte. Arrow points to a zoite with two or three nuclei. (B) A group of zoites with one or two nuclei. Arrow points to an organism divided into two. (C, D) Organisms dividing into two (arrows). (E, F) Groups with a merozoite separating (arrows) from the multinucleated mass. (G) A schizont with at least six nuclei (arrowheads) and merozoite (arrow). (H) Schizont (arrow) with merozoites (arrowheads) forming/separating at the periphery. (I) Schizont with small-sized merozoites attached to a central residual body (arrow). (J) Schizont with large residual body (arrow). (K) Small-sized merozoites with a central nucleus (arrow). (L) Schizont with a large residual body (arrow) and loosely arranged merozoites. (M) Elongated merozoites. Note two nuclei-like structures (arrowheads) in a merozoite. (N) Schizont with four longitudinally cut merozoites. (O) A group of schizonts with relatively large merozoites.

transmission electron microscopy (TEM) examination (Trupkiewicz *et al.* 2016). For this, numerous 1 µm sections were stained with Toluidine blue and examined by light microscope. For light microscopy, all sections of intestine were examined at 1000× magnification, photographed and endogenous stages were measured using a digital camera (DP 73) fitted on an Olympus AX 70 microscope.

Results

The preservation was sub-optimal but still allowed certain aspects to be examined but not the ultrastructural details. Profuse asexual multiplication occurred both in the jejunum and ileum, but more in the jejunum than the ileum (Figs 1 and 2). Organisms were seen in enterocytes throughout the villus, from the tip to the tunica muscularis mucosae. Crypts were heavily infected, and the lumens were packed with schizonts and merozoites. Even in

1 µm sections, there was overcrowding making it difficult to discern individual parasite outlines.

Numerous individual uninucleated structures were seen, but it was not possible to discern if they were merozoites or gamonts. By light microscopy, three types of merozoites/division were seen. Figure 1A and B show groups of organisms with different sized globular parasites in individual parasitophorous vacuoles (Fig. 1A and B). Figure 1B shows an organism dividing into two, whereas others in the same vacuole are uninucleated or binucleated; the two merozoites in division are $5.0 \times 1.0 \mu\text{m}$ and have a central nucleus. Figure 1C and D shows globular organisms dividing into two zoites that are much larger ($7 \times 4 \mu\text{m}$) than the merozoites in Fig. 1B. Other globular organisms contained up to eight nuclei and some merozoites appeared to split off the main mass (Fig. 1E–G). Figure 1H–L shows merozoites arising from different-sized residual bodies; the merozoites are small, 3–4 µm. Figure 1M shows a 7 µm long merozoite apparently with two nuclei. The merozoite formation in small schizonts

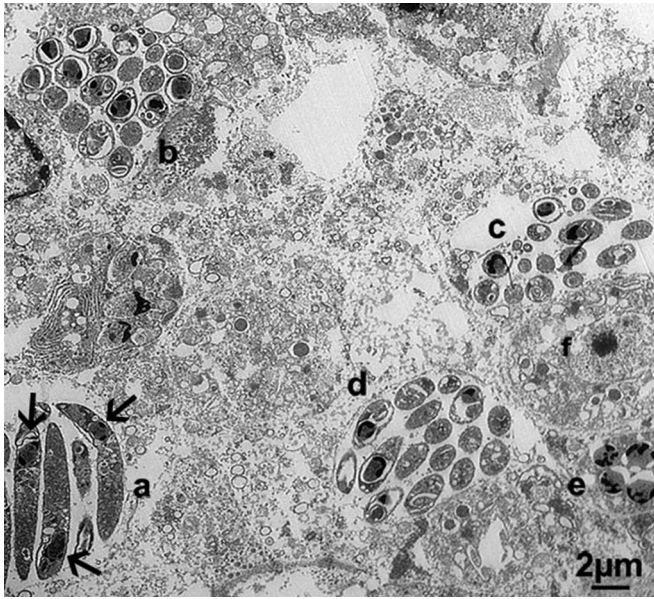


Fig. 2. Transmission electron microscopic observations on asexual and sexual stages of *Eimeria bareillyi* in the jejunum of a naturally infected 22-day-old buffalo. Note four schizonts (a–d), a microgamont (e) and a macrogamont (f). Also, note arranged head to tail arrangement of merozoites (arrows) in schizont (a). Merozoites in schizonts (b–d) are cut in cross-section or obliquely.

appeared to be asynchronous; some merozoites were protruding at the periphery of a multinucleated mass/residual body while others were not (Fig. 1H–L). Small-sized merozoites were 3–5 μm long and had a central nucleus (Fig. 1K).

Most schizonts contained elongated sickle-shaped merozoites (Fig. 1N and O); these schizonts were often 3–5 μm wide and contained 8–11 μm long merozoites (Fig. 1N and O). In these sickle-shaped merozoites, the nucleus was located at the broader end.

In the present buffalo, there were more than two generations of schizonts. The number and sequence of schizont generation was not known in this naturally infected calf.

By TEM, numerous individual and groups of merozoites were identified (Fig. 2). The maximum dimension of schizonts was 12 μm in any direction and a maximum of 16 merozoites were identified in any schizont. The merozoites were sometimes arranged with their apical ends in opposite direction (Fig. 2). Early schizonts were difficult to distinguish from early microgamonts (Fig. 3A). Although merozoites were not well preserved, numerous micronemes, few dense granules and a nucleus located at the narrow (non-conoidal) end can be seen in Fig. 3B. The stages in asexual division were not observed that would have helped answer question on the mechanism of division.

Gamonts were seen both in the jejunum and ileum, but more so in the ileum (Figs 4–7). By light microscopy, the earliest recognizable microgamont identified had eight peripherally located

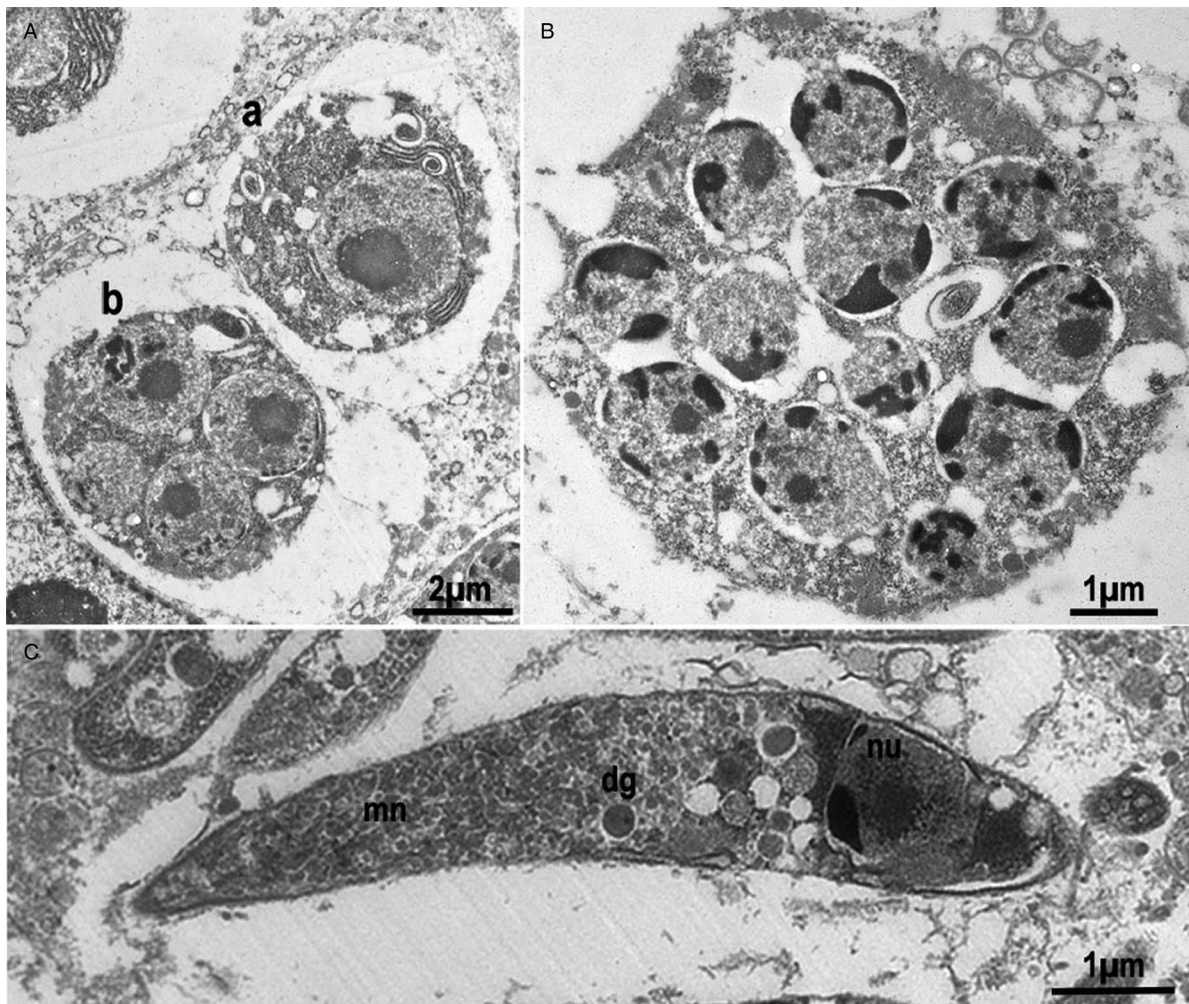


Fig. 3. Transmission electron microscopic observations on asexual stages of *Eimeria bareillyi* in the jejunum of a naturally infected 22-day-old buffalo. (a) One-nucleated with unidentified stage (a), and a four-nucleated organism (b), probably an early schizont. (B) A schizont-like structure with 12 nuclei. (C) Higher magnification of a merozoite showing the posteriorly located nucleus (nu), few dense granules (dg) and numerous micronemes (mn) towards the conoidal end.

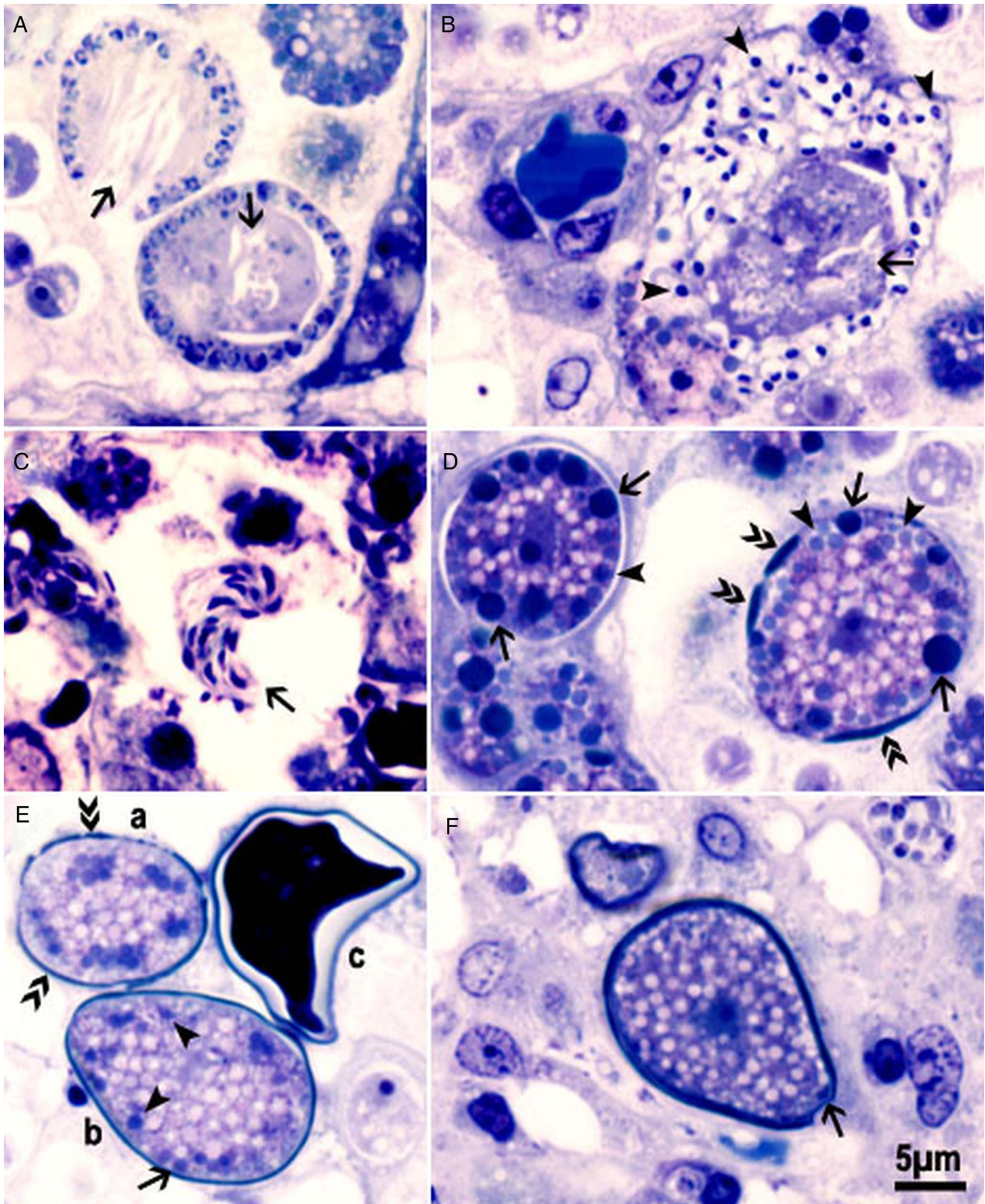


Fig. 4. Gametogony of *Eimeria bareillyi* in the jejunum of a naturally infected 22-day-old buffalo. One micrometre sections stained with Toluidine blue. Bar applies to all parts. (A) Two developing microgamonts with peripherally located nuclei and residual bodies of different density (arrows). (B) A nearly mature microgamont with numerous microgametes (arrowheads) and a large residual body (arrow). (C) Free microgametes with two flagella (arrow). (D) Two macrogamonts. The macrogamont on the left has both types of wall-forming bodies (WFB1, WFB2). Type WFB1 bodies (arrows) stain more intensely than the type 2 (arrowheads). The empty white areas are probably polysaccharide granules. The macrogamont on the right shows wall formation in patches (double arrowheads). WFB1 are fewer than WFB2. (E) Three oocysts in different stages of maturation. (a) Wall formation in patches (double arrowheads). (b) One oocyst wall (arrow) has formed and only WFB2 are visible (arrowheads). (c) Cross-section of a mature oocyst. (F) Longitudinal section of a fully formed oocyst with central nucleus, numerous amylopectin granules (empty spaces) and the micropyle (arrow).

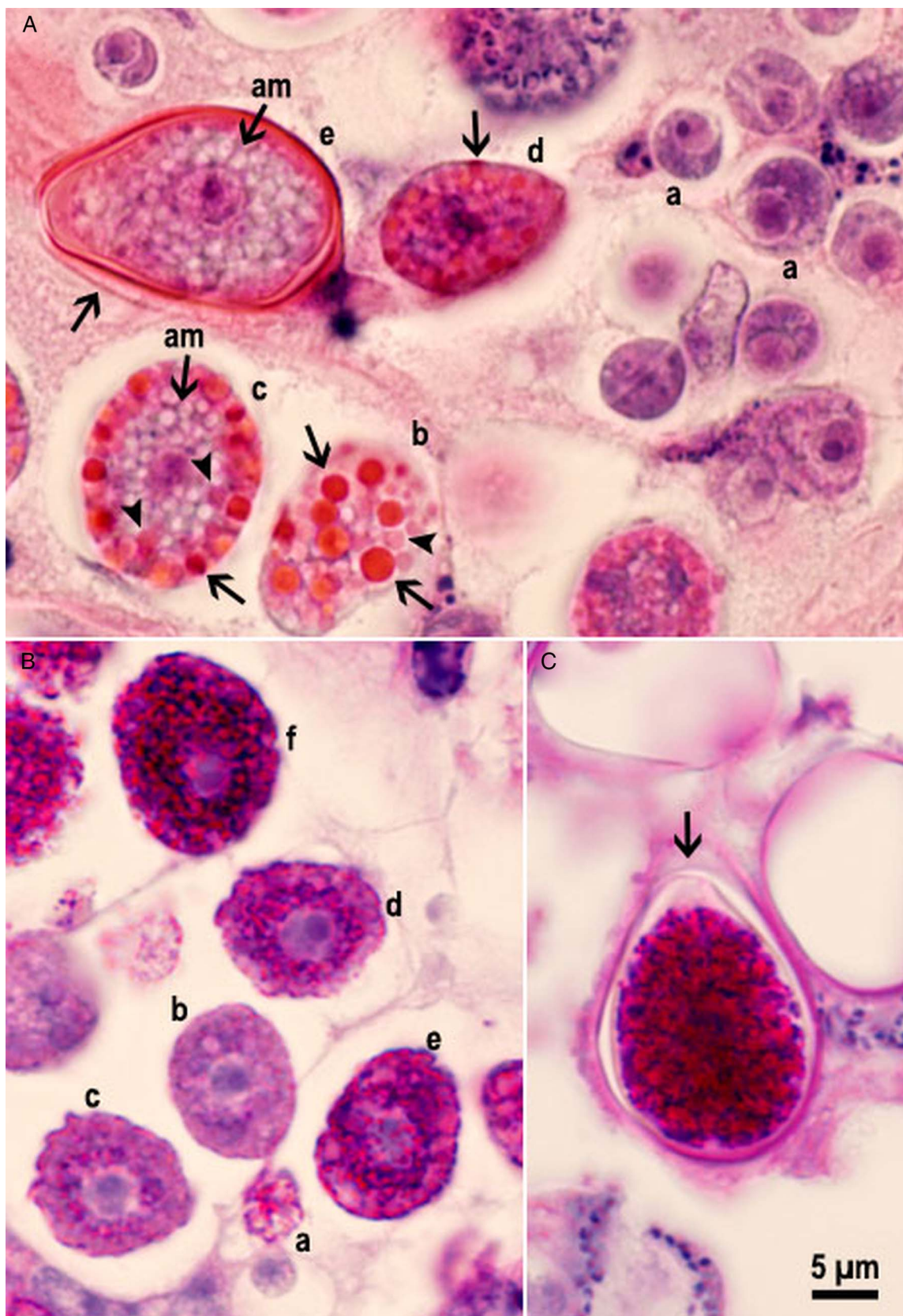


Fig. 5. Macrogamonts and oocysts of *Eimeria bareillyi* in the jejunum of a naturally infected 22-day-old buffalo. The 3–5 μm sections stained with haematoxylin and eosin (A) and (B, C) periodic acid Schiff (PAS) reaction counter stained with haematoxylin. Bar applies to all parts. (A) Macrogamonts in presumed order of development (a–e). Earliest macrogamont (a) with a large nucleus and without wall-forming bodies (WFB) and amylopectin granules. (b, c) Macrogamonts and developing oocysts with WFB1 (arrows) and WFB2 (arrowheads). An immature oocyst (d) with part of the wall formed (arrow). (e) Longitudinally cut oocyst with darkly stained oocyst wall and an outer covering (arrow). Also, note the centrally located nucleus with a nucleolus, and numerous polysaccharide granules (empty spaces) and no WFB. (B) Macrogamonts with varying intensity (a–f) of PAS positivity. The earliest macrogamont (a) is PAS-negative, (b, c, d, e) have PAS-positive granules around the nucleus and (f) entire gamont is PAS-positive. (C) Longitudinally cut pear-shaped oocyst with a truncated anterior end (arrow). The sporont occupies the entire width of the oocyst and is intensely PAS-positive.

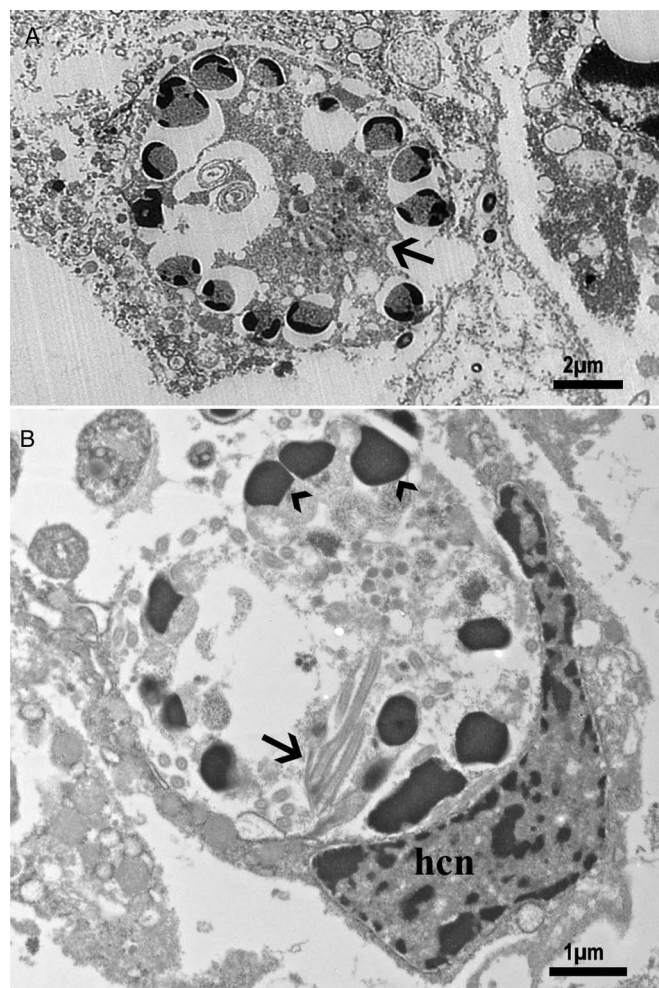


Fig. 6. Transmission electron microscopic observations on microgamonts of *Eimeria bareillyi* in the jejunum of a naturally infected 22-day-old buffalo. (A) Nearly mature microgamont with peripherally located nuclei and a residual body (arrow). (B) An intracellular degenerating microgamont. Note flagella (arrow), peripheral nuclei (arrowheads). Also, note the host cell nucleus (hcn).

nuclei and had a residual body. Large microgamonts with peripherally located nuclei were up to $12\text{--}40 \times 8\text{--}29 \mu\text{m}$ (average 26.4×20 , $n = 12$) and contained up to 30 nuclei and one or two residual bodies in one plane of focus (Fig. 4A and B); however, some nuclei were located towards the centre. Mature microgametes were up to $2.5 \mu\text{m}$ long and had two flagella (Fig. 4C).

By light microscopy, the earliest macrogamonts could be recognized by the presence of PAS-positive granules (amylopectin granules) and the two types of wall-forming bodies (WFB, also called plastic bodies) (Fig. 4A and D). The PAS-positive granules were initially located centrally around the nucleus. Subsequently, more PAS-positive granules appeared as the gamonts became larger (Fig. 5B). The WFB appeared after the appearance of PAS-positive granules, and WFB2 appeared sooner than WFB1. The WFB1 were stained darker with HE and Toluidine blue than WFB2 (Fig. 5A). The oocyst wall laid down in patches, and the WFB were not seen in fully formed oocysts (Figs 4 and 5).

TEM confirmed the light microscopic observations on microgamonts (Fig. 6). Even by TEM, it was difficult to distinguish young microgamonts from schizonts. The peripheral location of nuclei and the presence of flagella-like structures helped in definitive identification (Fig. 4A and C).

The light microscopic findings on macrogamonts were confirmed by TEM (Fig. 7). The WFB1 were electron dense, whereas WFB2 were spongy, both were $1\text{--}2 \mu\text{m}$ in diameter (Fig. 7). Fully

formed oocysts had two oocyst layers with the total thickness of $1 \mu\text{m}$ (Fig. 8). The inner oocyst layer was homogenous, and approximately 375 nm thick. The outer oocyst layer was denser and approximately 500 nm thick. The two oocyst layers were separated by an electron lucent space, probably an artefact. Both oocyst layers were truncated at the anterior end, with no interruption of the inner oocyst layer. The outer oocyst layer was thinned out at the conical (micropylar end) (Fig. 8A). Remnants of WFB were still recognizable in fully formed oocysts (Fig. 8B). Longitudinally cut oocysts in sections were $22\text{--}29 \times 14\text{--}18 \mu\text{m}$ (average 25.8×18.7 , $n = 10$).

Discussion

By light microscopy, the results described here are broadly similar to those reported previously (Pande *et al.* 1971; Shastri and Ghafoor, 1982; Sanyal *et al.* 1985; Dubey *et al.* 2008). Shastri and Ghafoor (1982) orally inoculated 2-day-old buffaloes with one million *E. bareillyi* oocysts and necropsied them 5, 10 or 14 days post-inoculation (p.i.). Endogenous development occurred in the jejunum and ileum. On day 5 p.i., only uninucleated, $3.2\text{--}5.7 \mu\text{m}$ in diameter organisms (trophozoites) were seen in enterocytes in crypts of Lieberkühn in the mid-jejunum. On day 10 p.i., immature and mature schizonts were seen in lower 2/3 of the small intestine. Mature schizonts were $11.5\text{--}20.7 \mu\text{m}$ and contained 24–36 slender $10\text{--}15 \mu\text{m}$ long merozoites. On day 14 p.i., only gamonts and oocysts were found. Macrogamonts were $12.5\text{--}23.3 \times 11.1\text{--}16.7 \mu\text{m}$, and microgamonts were $15\text{--}30 \times 10\text{--}23 \mu\text{m}$. Whether the measurements of schizonts and gamonts were from smears or histological sections was not stated. Unfortunately, the photographs of schizonts and gamonts are very poor, and therefore, it is impossible to judge the accuracy of description. The line drawings appear to be schematic. In the present study, the schizonts were small and contained no more than 16 merozoites. Additionally, the size of merozoites varied, indicating several generations.

Pande *et al.* (1971) first reported *E. bareillyi* gamonts and oocysts in specimens of small intestine obtained from an abattoir; nothing was known of clinical status or age of the buffalo; this animal also had concurrent infection with other *Eimeria*. They observed characteristic *E. bareillyi* oocysts in scrapings made from polyp-like raised areas. Only gamonts and oocysts were seen. The oocysts were $23.3\text{--}27 \times 13.3\text{--}17 \mu\text{m}$, and the mature microgamonts were $20\text{--}37 \times 18\text{--}25 \mu\text{m}$ in histological sections; these measurements are similar to those in the present study.

In the present study, both asexual and sexual stages were seen concurrently. This is probably related to trickle infection. Only *E. bareillyi* oocysts were seen in feces. Therefore, I assumed that endogenous stages observed belonged to *E. bareillyi*. Experimental *E. bareillyi* infections of newborn buffalo calves reared in coccidia-free conditions will be needed to confirm endogenous stages observed here. The present study has shown that newborn calves are highly susceptible to *E. bareillyi* infection.

The present study provided for the first time details of asexual and sexual multiplication of *E. bareillyi*. In most *Eimeria* species, the asexual development is considered by a divisional process of schizogony where sporozoites round up after invasion of host cells leading to a uninucleated organism called the trophozoite (Levine, 1973). Subsequent development occurs by schizogony wherein the parasite nucleus divides in to four or more nuclei before merozoite formation occurs (Levine, 1973). Some non-eimerid coccidia (*Toxoplasma*, *Neospora*) in the intermediate host divide by a process called endodyogony where the mother cell divides into two daughter organisms, consuming the mother cell. To accommodate this divisional process, Levine (1973) used

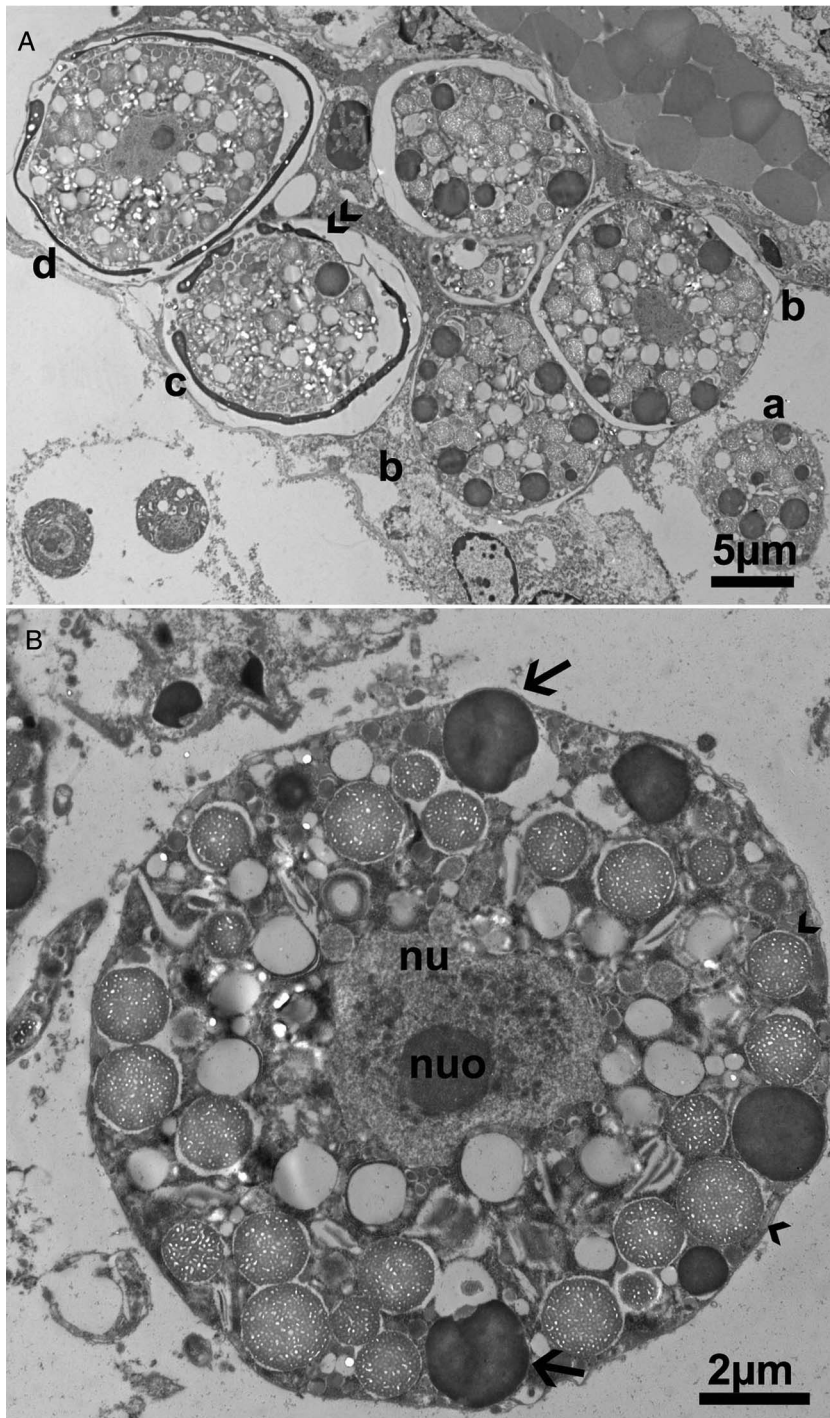


Fig. 7. Transmission electron microscopic observations on gamonts and oocysts of *Eimeria bareillyi* in the jejunum of a naturally infected 22-day-old buffalo. Note, nucleus (nu), nucleolus (nuo), wall-forming bodies (WFB)1 (arrows) and 2 (arrowheads). (A) Gametogony and oocyst wall formation in presumed order of development (a–d). (a,b) developing macrogamonts with numerous WFB1, 2. (c) Oocyst wall formation in patches (double arrowheads) with WFB1 and several WFB2. (d) Almost completed oocyst wall. (B) Higher magnification of a macrogamont. Note a centrally located nu and nuo, electron-dense WFB1 (arrows), electron-lucent WFB2 (arrowheads).

the term meront instead of the conventional term schizont. Here, I have used the term schizont loosely, although some organisms appeared to divide into two. To my knowledge, endodyogeny has not been demonstrated previously in any species of *Eimeria*. In the present study with *E. bareillyi*, some organisms divided in to two but the observations could not be confirmed by TEM. Confirmation of endodyogeny in *Eimeria* will require well-preserved specimens; only paraffin-embedded tissue was available for the present study.

The development of *E. bareillyi* oocyst wall is unknown. In *Eimeria* species, the oocyst wall is initiated by the secretions of WFB. Most *Eimeria* species have two types of WFB, type 1 and type 2. The WFB1 are electron dense and larger in size than WFB2, and their characteristics are species-specific (Ferguson *et al.* 2003). The WFB arise during the maturation of the

macrogamont and form the oocyst wall. In some *Eimeria* species, there are additional veil-forming bodies (VFB); they form a veil-like outer covering on the oocyst wall that disappears when the oocysts are excreted in feces (Ferguson *et al.* 2003); VFB were not identified in the present study of *E. bareillyi*.

The prepatent period of *E. bareillyi* in experimentally infected buffaloes is 12–15 days, probably dependent on the age of buffaloes and the dose. The shortest prepatent period of 12 days was observed in 2-day-old buffaloes fed 115 000 oocysts (Shastri *et al.* 1973) and the 15th day prepatent period was observed in a 1-month-old calf fed 100 000 oocysts. In the present study, the calf was excreting numerous *E. bareillyi* oocysts in feces and had severe enteritis (Dubey *et al.* 2008). The buffalo calf was housed individually, and was fed milk replacer. It is unlikely that the calf ingested *E. bareillyi* oocysts as a single bolus of

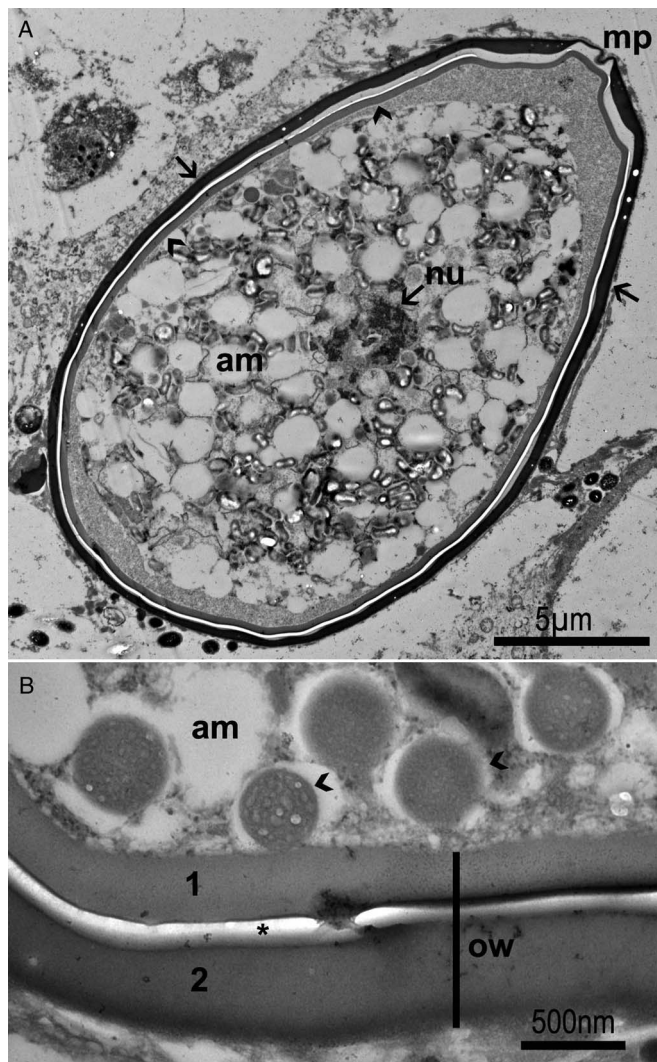


Fig. 8. Transmission electron microscopic observations on an *Eimeria bareillyi* oocyst in the jejunum of a naturally infected 22-day-old buffalo. Note outer oocyst layer (arrows), inner oocyst layer (arrowheads), wall-forming bodies (1, 2) and empty spaces (amylopectin/lipid bodies). (A) The oocyst is $27 \times 15 \mu\text{m}$. Note the sporont occupying almost of the oocyst interior. The two oocyst layers differ in density, the outer layer (arrow) is denser than the inner layer (arrowhead). The oocyst is truncated at the micropylar end (mp) with thinning of the outer layer. (B) Higher magnification of oocyst layers. The two oocyst walls (1,2) are separated by an empty space (*), probably fixation artefact. Also, note WFB1, 2 (arrowheads).

infection, but more likely infected over several days. The calf was only 22 days old, and considering the short prepatent period, *E. bareillyi* probably became infected soon after birth. The affected farm was well managed, the calf was not malnourished and no concurrent infectious agent was found. Nothing is known of the pathogenicity of different strains of *E. bareillyi*.

This is the first full description of asexual and sexual development of any *Eimeria* species in buffalo and the results should be helpful in differential diagnosis of *Eimeria* species in the intestines of buffaloes.

Acknowledgements. I would like to thank Camila Cezar, Fernando Antunes, Shiv Kumar Verma and Oliver Kwok for their help with this manu-

script and Joseph Mowery for electron micrographs. I am grateful to Professor David Ferguson for his help with interpretations of electron micrographs.

Financial support. This research received no specific grant from any funding agency, commercial or not-for-profit sectors.

Conflict of interest. None.

Ethical standards. Not applicable

References

- Barbosa MA, et al. (1992) Natural parasitism of buffalo cows in Botucatu, SP, Brazil – III. Dynamics of gastro-intestinal parasitism in cows and calves. *Memorias do Instituto Oswaldo Cruz* **87**(Suppl. 1), 37–41.
- Bastianetto E, et al. (2008) Primeiro diagnóstico de *Eimeria bareillyi* (Apicomplexa: Eimeriidae) nas fezes de bezerros bubalinos (*Bubalus bubalis*) naturalmente infectados no estado de Minas Gerais, Brasil. *Revista Brasileira de Parasitologia Veterinária* **17**(Suppl. 1), 234–238.
- Cringoli G, et al. (1998) Diffusion dynamics of *Eimeria* spp. in infected buffalo herds. *Parassitologia* **40**(Suppl. 1), 38.
- de Meireles GS, et al. (2012) Surto de coccidiose em bezerros búfalos (*Bubalus bubalis*) por *Eimeria bareillyi* Gil, et al., 1963 (Apicomplexa: Eimeriidae) – relato de casos. *Revista Brasileira de Parasitologia Veterinária* **34**, 116–120.
- Dubey JP, Wouda W and Muskens J (2008) Fatal intestinal coccidiosis in a three week old buffalo calf (*Bubalus bubalis*). *Journal of Parasitology* **94**, 1289–1294.
- Ferguson DJP, et al. (2003) The development of the macrogamete and oocyst wall in *Eimeria maxima*: immuno-light and electron microscopy. *International Journal for Parasitology* **33**, 1329–1340.
- Gill BS, Chhabra MB and Lall NB (1963) A new species of coccidium, *Eimeria bareillyi* n. sp. from buffaloes. *Archiv für Protistenkunde* **106**, 571–574.
- Levine ND (1973) *Protozoan Parasites of Domestic Animals and of Man*. 2nd edn., Minneapolis, Minnesota, USA: Burgess Publishing Company, pp. 1–406.
- Levine ND and Ivens V (1970) *The Coccidian Parasites (Protozoa, Sporozoa) of Ruminants*. Urbana, IL: University of Illinois Press. Illinois Biological Monographs no. 44. pp. 1–278.
- Pande BP, Bhatia BB and Chauhan PPS (1971) Sexual stages and associated lesion in *Eimeria bareillyi* of buffalo calves. *Indian Journal of Animal Sciences* **41**, 151–154.
- Sanyal PK, Ruprah NS and Chhabra MB (1985) Chemotherapeutic efficacy of sulphadimidine, amprolium, halofuginone and chloroquine phosphate in experimental *Eimeria bareillyi* coccidiosis of buffaloes. *Veterinary Parasitology* **17**, 117–122.
- Sayin F (1973) The presence of *Eimeria bareillyi* (Gill, Chhabra and Lall, 1963) in buffalo in Turkey. *Ankara Üniversitesi Veteriner Fakültesi Dergisi* **20**, 38–42.
- Shastri UV and Ghafoor MA (1982) Observations on the developmental stages of *Eimeria bareillyi* Gill, Chhabra and Lall, 1963, in buffalo-calves. *Indian Journal of Animal Sciences* **52**, 309–313.
- Shastri UV and Krishnamurthi R (1975) A note on pathological lesions in clinical bubaline coccidiosis due to *Eimeria bareillyi*. *Indian Journal of Animal Sciences* **45**, 46–47.
- Shastri UV, Krishnamurthi R and Ghafoor MA (1973) Some observations on pathogenicity of *Eimeria bareillyi* in buffalo calves. *Indian Journal of Animal Research* **7**, 23–25.
- Shastri UV, Krishnamurthi R and Ghafoor MA (1974) A note on clinical coccidiosis in buffalo calves due to *Eimeria bariellyi* Gill, Chhabra and Lall, 1963 in Maharashtra. *Indian Veterinary Journal* **51**, 301–302.
- Shastri UV, Ghafoor MA and Krishnamurthi R (1976) Some observations on coccidian lesions associated with endogenous phases in buffalo calves. *Indian Journal of Animal Sciences* **46**, 556–561.
- Trupkiewicz JG, et al. (2016) Acute, fatal *Sarcocystis calchasi*-associated hepatitis in Roller pigeons (*Columba livia f. dom.*) at Philadelphia Zoo. *Veterinary Parasitology* **216**, 52–58.