

Chondrosarcomas of the skull base and temporal bone

L R LUSTIG, J SCIUBBA*, M J HOLLIDAY*

Abstract

Objective: To evaluate the clinical presentation and outcomes of treatment for patients with chondrosarcomas involving the skull base and temporal bone.

Study design: Retrospective review.

Setting: Tertiary medical centre.

Patients: Cases of histologically confirmed chondrosarcoma involving the skull base and temporal bones.

Intervention: Surgery.

Main outcome measures: Demographic features of presenting patients; presenting symptoms and signs; surgical approach employed; use of post-operative radiation therapy; histological grade of tumour; and interval of post-operative follow up.

Results: Twelve patients were identified with chondrosarcomas involving the skull base, with post-operative follow up ranging from three to 33 years. The average age at presentation was 42 years. The most common presenting symptoms were diplopia, decreased visual acuity and headaches. Five of the 12 patients required multiple surgical procedures.

Conclusions: Patients with chondrosarcoma involving the skull base and temporal bone may present in a variety of ways. Surgical resection, even subtotal, in combination with radiation therapy, can often provide good tumour control over many years for these rare tumours.

Key words: Skull Base Neoplasms; Chondrosarcomas; Otologic Surgical Procedures

Introduction

Chondrosarcomas are primary bone neoplasms which may arise spontaneously in normal bone and secondarily in diseased bone.¹ Although they account for up to one-third of primary malignant bone tumours, intracranial chondrosarcomas are considerably rarer, making up less than 1 per cent of all intracranial tumours.² The embryology of these tumours explains their sites of origin.³ Within the skull, they are believed to arise anywhere that endochondral bone ossifies intramembranously, leading to a predilection within the clivus and petrous bone and near the sella turcica and frontoethmoid region.^{4–9} It is hypothesised that the tumours arise within rests of fetal cartilage and notochord in these regions, where the petroclival, sphenopetrosal, petro-occipital and sphenopetrous synchondroses converge.^{9,10}

Although they more commonly occur spontaneously, chondrosarcomas may also arise as a result of malignant degeneration in endochondromas, seen both in Maffucci's syndrome (a mesodermal dysplasia causing enchondromas and haemangiomas) and in Ollier's disease (manifesting

as multiple enchondromas).^{3,10} They are also reported to arise in association with Paget's disease, osteocartilaginous exostoses and bone trauma.^{11,12}

As a rule, chondrosarcomas are locally invasive and rarely metastasise, causing injury through compression and invasion of critical structures within the skull base, including the cranial nerves and the carotid artery.¹³ Because of the complex anatomy of the skull base, margin-free tumour extirpation in this region is often not possible without significant morbidity to the patient. As a result, treatment has focused on local control, using a combination of surgery and radiation or proton beam radiotherapy.^{1,14,15}

In an effort to further characterise these uncommon neoplasms, we performed a retrospective review of patients with chondrosarcomas involving the temporal bone and skull base, treated at our institution over the past 30 years.

Patients and methods

We undertook a retrospective review of all patients with chondrosarcomas involving the skull base and

From the Department of Otolaryngology – Head & Neck Surgery, University of California, San Francisco, California, and the *Department of Otolaryngology – Head & Neck Surgery, Johns Hopkins University, Baltimore, Maryland, USA.
Accepted for publication: 30 October 2006.

temporal bone, treated at our institution over the past 30 years. Patients were identified through a review of clinical and operative records and of a pathology database. Patients were excluded from the study if there was insufficient clinical data, including lack of current clinical information (within the past five years) or clear documentation in the medical records of the final outcome (e.g. death). Patients were also excluded if there was not a clear histopathologic diagnosis of chondrosarcoma.

From the clinical records, data were tabulated on each patient, including gender, age at presentation, presenting symptoms and signs, and treatment (both surgical and radiotherapeutic). Data tabulated also included length of survival from initial presentation, and whether the patient was currently either: free of disease (e.g. gross total surgical resection had been undertaken and there had been a normal post-operative magnetic resonance imaging (MRI) screening); alive with disease (e.g. subtotal resection of tumour, with or without radiation therapy and persistence of tumour on MRI screening, or initial gross total resection with recurrence on MRI); deceased from disease; or deceased from an unrelated cause.

This study comprised a review of existing clinical data with patient identifiers removed. It qualified for exemption from an institutional review board protocol based upon Department of Health and Human Services criteria 45 CFR 46.101(b)(4). The determination that this study was exempt from a protocol requirement was made by the joint committee on clinical investigation of the Johns Hopkins University School of Medicine.

Results

Patient demographics

A total of 12 patients were identified who met all the criteria for inclusion in this retrospective review (Table I). There were eight females and four males. The average age at presentation was 42 years, with a range of six to 67 years.

Anatomical presentation

The chondrosarcomas involved a variety of structures throughout the skull base (Table II). The most common site of involvement was the clivus, in eight patients (67 per cent). Four patients (33 per cent) had involvement of the petrous apex, three (25 per cent) had involvement of the sella turcica with suprasellar extension, three (25 per cent) had involvement of the cavernous sinus, three (25 per cent) had involvement of the sphenoid and three (25 per cent) had involvement of the ethmoid. Two patients (17 per cent) had involvement of the orbit, internal carotid artery and maxilla. One patient (8 per cent) had involvement of the jugular bulb.

Presenting symptoms and signs

The most common presenting features were diplopia and facial pain or headache, in association with cranial nerve deficits (Tables I and II). Diplopia

was due to a VIth cranial nerve deficit in four patients and proptosis in one patient. Headache or facial pain was noted in three patients (25 per cent). Other presenting symptoms included visual loss or blindness ($n = 3$), facial dysaesthesias ($n = 2$), a bulging mass in the nose ($n = 1$), and otalgia ($n = 1$). When evaluated by cranial nerve deficits at presentation (Table II), the VIth cranial nerve was the most commonly affected ($n = 4$), followed by the IIIrd ($n = 3$), Vth ($n = 2$), VIIIth ($n = 1$), IXth ($n = 1$) and the Xth ($n = 1$).

Patients requiring a single operation

All patients underwent some form of surgical excision of their tumour (Table I). Seven of the 12 patients (58 per cent) only required a single operation to achieve control of the disease. Of these, three also underwent post-operative radiation therapy. Of these seven cases, three had well differentiated (grade one) tumours, three had moderately differentiated (grade two) tumours and one had a poorly differentiated (grade three) tumour. All of these seven patients were free of disease at the time of writing, after a follow up ranging from five to 33 years from their original presentation. There did not appear to be any unique anatomical features of the tumour in these seven (single operation) patients, as compared with those who underwent multiple procedures for persistent disease or recurrence (see below). However, there did appear to be an association between the histologic grade of the tumour and the need for more than one surgical procedure. Patients with well differentiated tumours (i.e. grade one) were more likely to require only a single operation (3/4 patients) as opposed to those with grade two tumours (2/6 needed only a single operation). Both patients with grade three tumours underwent only one operation, although one of these patients had an inoperable recurrence 17 years later, to which she subsequently succumbed.

Of these seven patients requiring only one operation, three underwent anterior approaches (Table I). Patient six, with maxillary and orbital involvement, and patient seven, with maxillary, septal and palatal involvement, both underwent a mid-face degloving procedure for tumour removal. Patient 10, with clival and sphenoid involvement, underwent a transsphenoidal approach. Three of the seven patients underwent laterally based infratemporal fossa approaches. Patient three underwent an infratemporal fossa approach to the skull base for tumour involving the petroclival region, extending down to the jugular bulb, and involving the internal carotid, internal auditory canal and cavernous sinus (Figure 1). Patient five underwent an infratemporal fossa approach and an anterior petrosectomy for tumour involvement of the petroclival junction, cavernous sinus and sphenoid. Patient five underwent an infratemporal pre-auricular approach for tumour involving the petroclival junction (Figure 2). The last patient who required only a single operation (patient 11) underwent a frontal

TABLE I
CLINICAL INFORMATION

Patient	Gender	Structures involved	Age* (years)	Presenting symptoms & signs	Treatment	Follow up & outcome†	Tumour grade
1	M	PA, C, PF	39	HA	Craniotomy × 3 (1981, 1987, 1997) XRT 1982 Medialisation thyroplasty + PEG 1997 Transtemporal resection + labyrinthectomy 2001	Multiple recurrences, last 2001 CN palsies VII–XII FOD @ 22 yrs	II
2	M	Eth	6	Bulging mass in nose	Excision × 3 Mid-face degloving procedure	FOD @ 16 yrs	II
3	F	C, PA, JB, IAC, ICA, CS	67	Diplopia (CN VI)	Large skull base excision	FOD @ 7 yrs	II
4	F	NP, Sph, Eth, C, Orb, Sella	54	Dysphagia (CN IX, X) Facial dysaesthesia (CN V) Visual loss (CN III)	Post-op XRT Bilat mid-face degloving 1995	AWD @ 8 yrs	II
5	F	PA, C, Sph, CS	23	Frontal HAs Otagia Diplopia (CN VI) Facial dysaesthesia (CN V)	Transcranial resection 1999 Inferotemporal fossa 2001 Excision, petrosectomy, removal of sphenoid Post-op XRT	FOD @ 7 yrs	II
6	M	Max, Orb	64	Proptosis Visual loss Diplopia	Maxillectomy + orbital exenteration	FOD @ 10 yrs	II
7	F	Max, septum, palate	26	Facial pressure & pain	Maxillectomy	FOD @ 11 yrs	III
8	F	PA, C	44	Diplopia (CN VI)	Reconstruction with fibula free flap Infratemporal preauricular approach Disarticulation of mandible ICA decompression	Resolved CN VI palsy FOD @ 5 yrs	I
9	F	C, Sella, Sph, Eth	37	Blindness (CN III)	Excision @ 37 yrs; blind R eye Recurrence 17 yrs later w/ L eye vision decrease XRT	DOD 1973	III
10	M	C, Sph	54	Diplopia (CN VI) Ataxia	Transsphenoidal approach	LTF after 30 yrs	I
11	F	C, Sella	33	Visual loss (CN III) Calcification on plain films	R frontal craniotomy XRT (4500 Rads)	FOD @ 33 yrs	I
12	F	PA, C	51	Temporal HAs	Subtemporal/infratemporal fossa approach + petrous apicectomy Re-excision for residual tumour @ 2 mths w/ petrous carotid artery mobilisation	FOD @ 5 yrs	I

*At first presentation. †Length of time is from first operation to time to writing. Yrs = years; M = male; PA = petrous apex; C = clivus; PF = posterior fossa; HA = headache; XRT = radiotherapy; CN = cranial nerve; PEG = percutaneous endoscopic gastrostomy; FOD = free of disease; Eth = ethmoid; F = female; JB = jugular bulb; IAC = internal auditory canal; ICA = internal carotid artery; CS = cavernous sinus; NP = nasopharynx; Sph = sphenoid; Orb = orbit; Sella = sella turcica; bilat = bilateral; AWD = alive with disease; Max = maxilla; R = right; L = left; DOD = died of disease; w/ = with; LTF = lost to follow up; mths = months

TABLE II

STRUCTURES RESPONSIBLE FOR PRESENTING CLINICAL FEATURES OF CHONDROSARCOMAS

Structure affected	Patients (n)
<i>Anatomical location</i>	
Clivus	8
Petrous apex	4
Sella	3
Sphenoid	3
Ethmoid	3
Cavernous sinus	3
ICA	2
Maxilla	2
Orbit	2
IAC	1
Jugular bulb	1
<i>Cranial nerve</i>	
II	0
III	3
IV	0
V	2
VI	4
VII	0
VIII	1
IX	1
X	1
XI	0
XII	0

Sella = sella turcica; ICA = internal carotid artery; IAC = internal auditory canal

craniotomy for tumour in the region of the sella, with suprasellar extension.

Patients requiring multiple operations

The remaining five patients required multiple operations due to tumour recurrence or persistence. Patient one (Table I) required four operations over a 20 year period. This patient had originally presented in 1981 with a petroclival chondrosarcoma extending into the posterior fossa (Figure 3). He had undergone a large suboccipital, posterior fossa resection, with post-operative radiation therapy, for a medium (grade two) chondrosarcoma. He had two additional recurrences in 1987 and 1997, requiring resection via the same approach. Because of subsequent recurrence within the temporal bone, in 2001 he underwent a complete labyrinthectomy with gross total tumour removal. At the time of writing, he had unilateral deficits of cranial nerves VII to XII and was alive without obvious disease (by MRI) two years from his last procedure and 22 years from his initial presentation.

Patient two (Table I) presented with a bulging nose at the age of six years. Investigations revealed a chondrosarcoma involving the ethmoid sinuses (Figure 4). He underwent a mid-face degloving procedure for excision. However, due to tumour persistence, the patient required an additional operation, via the same approach, within a year of the initial surgery. Histopathology demonstrated a moderately differentiated (grade two) tumour. At his most recent follow up, 16 years after the initial surgery, this patient was free of disease.

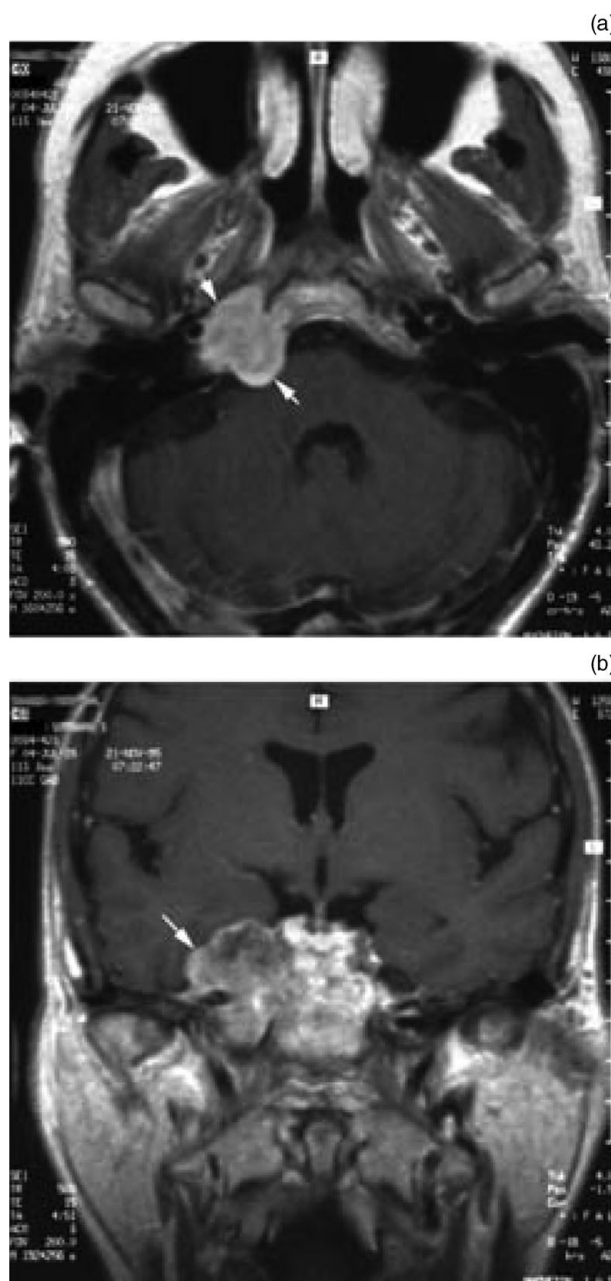


FIG. 1

(a) Axial and (b) coronal magnetic resonance imaging scans for patient three. The tumour (arrows) involves the petroclival region, extends down to the jugular bulb, and involves the internal carotid artery, internal auditory canal and cavernous sinus.

Patient four (Table I) presented at the age of 54 years with progressive visual loss, headaches and otalgia. Investigations demonstrated a large chondrosarcoma involving the nasopharynx, sphenoid, ethmoid, clivus, sella turcica and orbit (Figure 5). The patient originally underwent a mid-face degloving procedure in 1995. Histopathological analysis of the tumour identified a grade two chondrosarcoma. Four years later, because of tumour recurrence, the patient underwent a transcranial re-resection. A third recurrence two years later led to resection via an infratemporal fossa approach. Eight years after

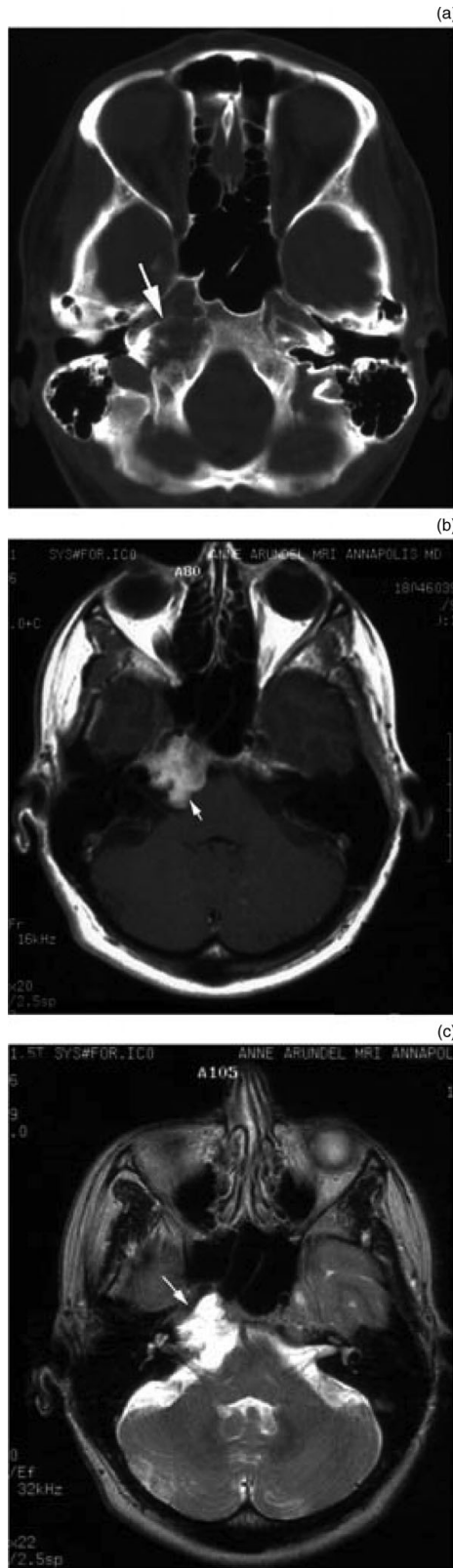


FIG. 2

Patient five presented with tumour involvement of the petroclival junction, cavernous sinus and sphenoid. (a) Axial computed tomography scan showing an expansive lesion adjacent to the sphenoid and carotid artery (arrow). (b) T1-weighted magnetic resonance image (MRI) demonstrating the tumour in the petroclival region (arrow). (c) T2-weighted MRI showing the same tumour, just anterior to the internal auditory canal (arrow).

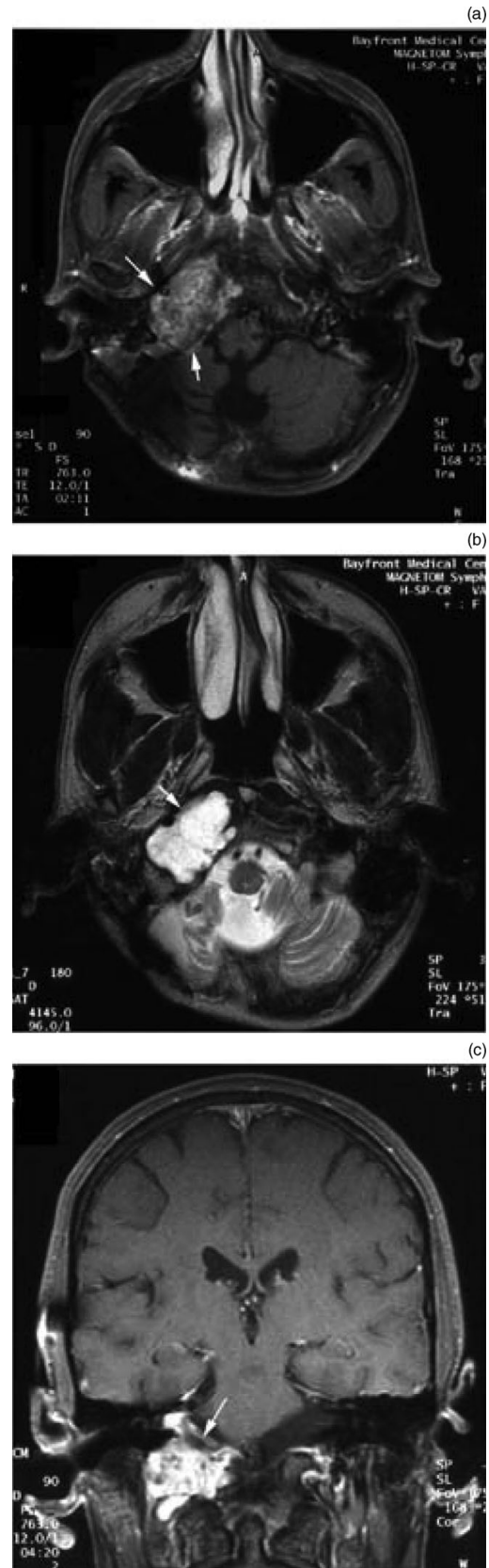

FIG. 3

Patient one. (a) Axial T1-weighted magnetic resonance image (MRI) showing tumour (arrows) in the petroclival region, extending into the posterior fossa. (b) The same tumour (arrow) viewed on a T2-weighted MRI. (c) Coronal T1-weighted MRI of the same tumour (arrow), with contrast enhancement.

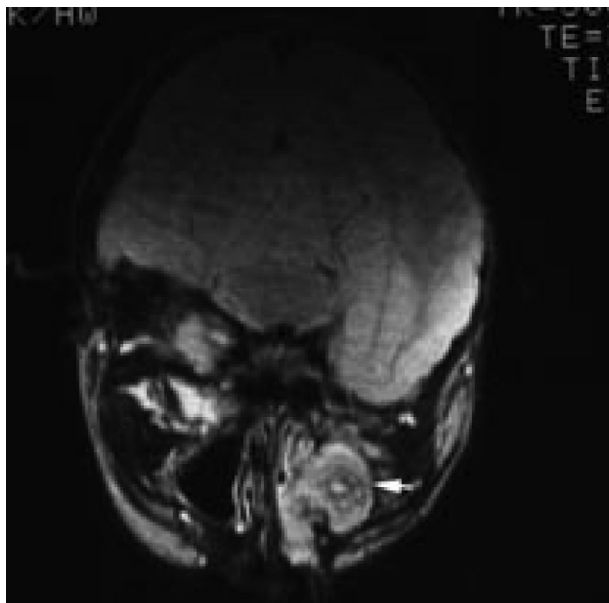


FIG. 4

Patient two; T1-weighted magnetic resonance image showing a chondrosarcoma (arrow) involving the ethmoid sinuses.

her initial presentation and two years after her most recent infratemporal fossa excision, the patient was alive with residual disease that appeared stable.

Patient nine presented at the age of 37 years with progressive visual loss. Investigation led to the diagnosis of a skull base tumour involving the clivus and sella, with extension to the suprasellar region and to the sphenoid and ethmoid bones. She underwent an anterior approach to the skull base via a mid-face degloving procedure. Histopathological analysis of the tumour identified a high grade (grade three) chondrosarcoma. The patient did well until 17 years later, when she re-presented with visual loss in her only seeing eye. Evaluation demonstrated a large recurrence of the tumour, which was felt to be unresectable. Despite receiving radiation therapy, the patient died secondary to central nervous system compression following radiation treatment.

Patient 12 presented at the age of 51 with temporal headaches. Evaluation led to the diagnosis of a tumour involving the petroclival region of the skull base, adjacent to the intrapetrous carotid artery (Figure 6). She underwent a subtemporal-infratemporal fossa approach with an anterior petrous apicectomy. Histopathological analysis of the tumour identified a low grade (grade one) chondrosarcoma. Because of persistent disease, the patient underwent a re-excision of the residual tumour, with mobilisation of the petrous carotid artery, two months later. At her most recent follow-up, five years post-operatively, she was free of disease.

Long-term follow up

The duration of patients' follow up ranged from five to 33 years from their initial presentation. Only one patient died as a result of the tumour or its treatment (patient nine). At the time of writing, the remaining

patients were either free of disease (by MRI evaluation; nine patients), or alive with persistent disease (by MRI; one patient). One patient (patient 10) had been noted to be free of disease at their 30 year follow up, but was lost to follow up over the past five years.

Long-term results were also compared for each histological grade. Of the four patients with low grade (i.e. grade one) chondrosarcoma (Figure 7), all were free of disease at follow up ranging from five to 33 years. Of these four cases, three achieved tumour control after one operation, while one (patient 12) required a second operation within two months of the first for persistent disease. Six patients had grade two chondrosarcoma (Figure 8); five were free of disease after follow up ranging from seven to 22 years, and one was alive with disease at eight years. Of these six individuals with grade two tumours, two had complete tumour removal in a single operation, while four required multiple surgical procedures for tumour control, due to recurrence. Two individuals had poorly differentiated (grade three) chondrosarcoma (Figure 9). One was free of disease 11 years following her operation (patient seven), while the second died as a result of a large tumour recurrence 17 years after her original surgery (patient nine).

Discussion

Chondrosarcomas involving the temporal bone and skull base are uncommon lesions, accounting for less than 1 per cent of tumours within the head and neck, and approximately 6 per cent of skull base lesions in some series.^{16,17} Other series have shown a much smaller incidence in the skull base.^{2,10}

As already noted from its embryologic origins, chondrosarcomas tend to arise in areas of synchondrosis. Within the skull base, this occurs in the petroclival, petro-occipital, sphenoid-occipital and sphenoid-petrosal synchondroses.⁹ The findings in this current series of 12 patients support this assertion, as chondrosarcomas were most likely to arise in relation to the petroclival junction, occurring here in two-thirds of patients, while the remainder arose in relation to the sella, sphenoid and ethmoid regions (Table II). Extension of these tumours also caused involvement of additional critical structures, including the cavernous sinus in three patients, the orbit in two, the internal auditory canal in one and the jugular bulb in one patient.

These areas of tumour involvement are similar to findings from previous studies. In a review of 200 cases of chondrosarcoma of the skull base, Rosenberg and colleagues⁴ also showed that two-thirds of cases involved the petroclival junction, approximately one-fourth of cases arose from the sphenoid-occipital region and 6 per cent were centred in the sphenoid-ethmoid complex. In contrast, in a literature review of 48 patients with skull base chondrosarcoma, Seidman *et al.*¹⁰ showed a 44 per cent involvement of the petrous bone, but only an 8 per cent involvement of the clivus.

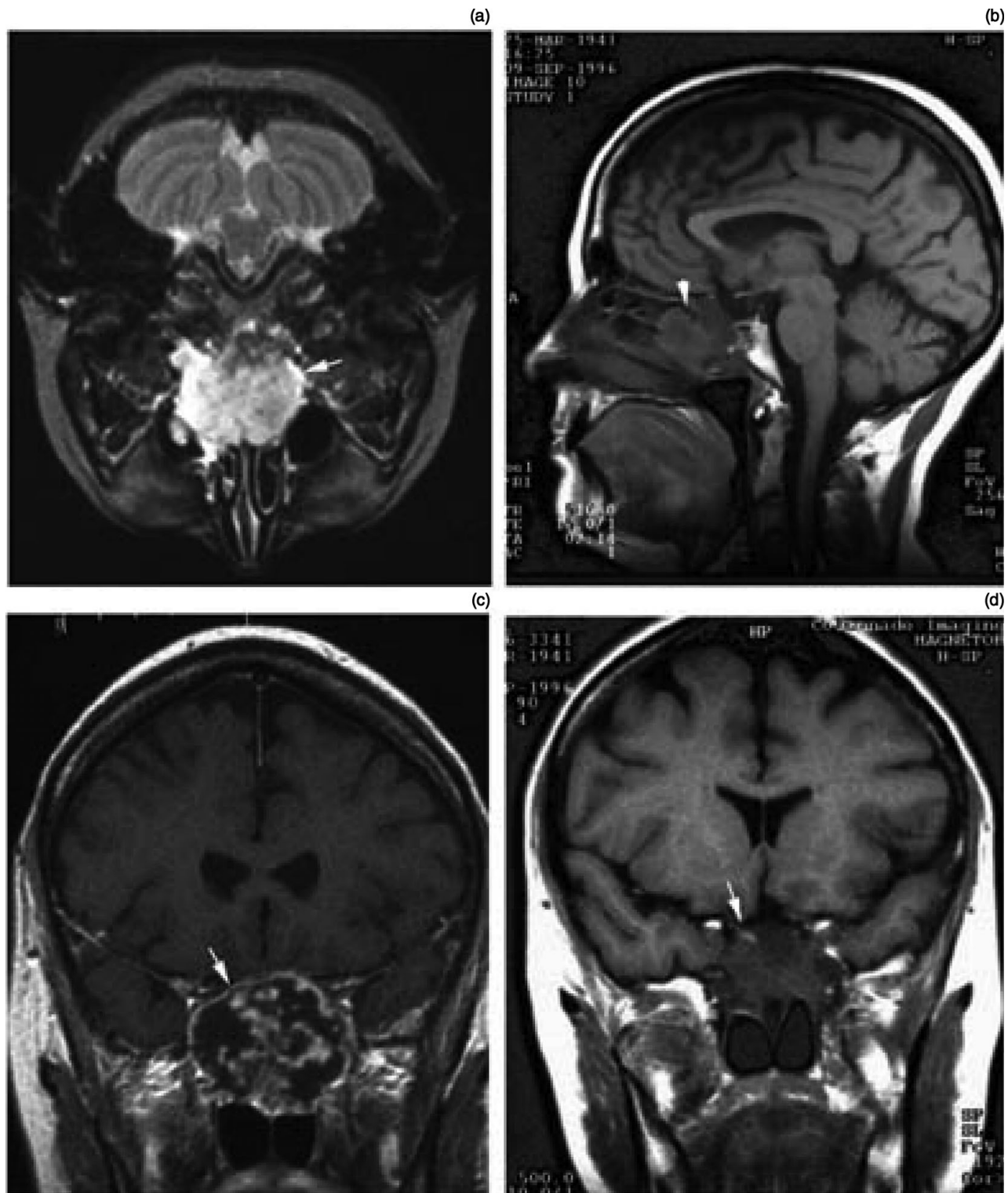


FIG. 5

Magnetic resonance imaging (MRI) series from patient four. (a) Axial T2-weighted MRI showing a large chondrosarcoma (arrow) eroding into the sphenoid and ethmoid sinuses and nasopharynx. (b) Sagittal T1-weighted MRI demonstrating tumour involvement (arrowhead) of the sella turcica and upper clivus. Coronal T1-weighted MRI images are also shown, (c) without and (d) with contrast enhancement.

Clinically, the patients in our study presented with a variety of symptoms (Table II), although ophthalmologic complaints were most likely, occurring in two-thirds of patients. Eye complaints included diplopia, due to involvement of the abducens nerve

(VIth cranial nerve; four patients), proptosis (one patient) or loss of vision due to involvement of the optic nerve (IIrd cranial nerve; three patients). This is not surprising, since prior reports have shown that approximately 50 per cent of patients

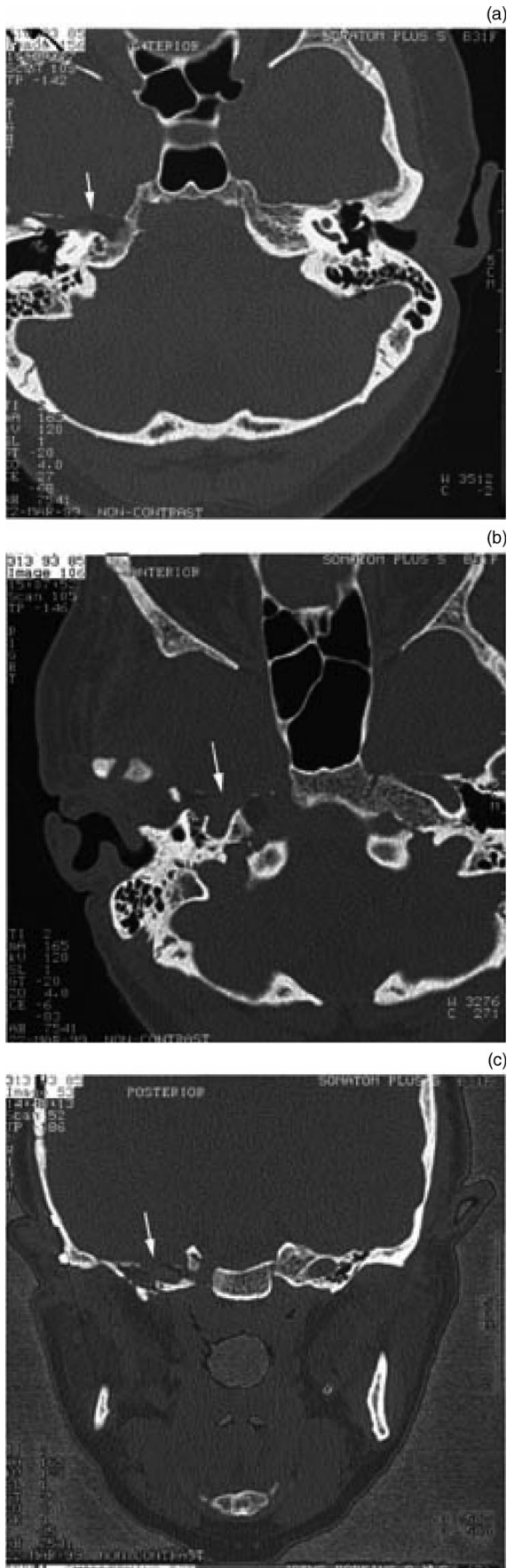


FIG. 6

Axial (a & b) and coronal (c) computed tomography images of patient 12; arrows indicate the tumour.

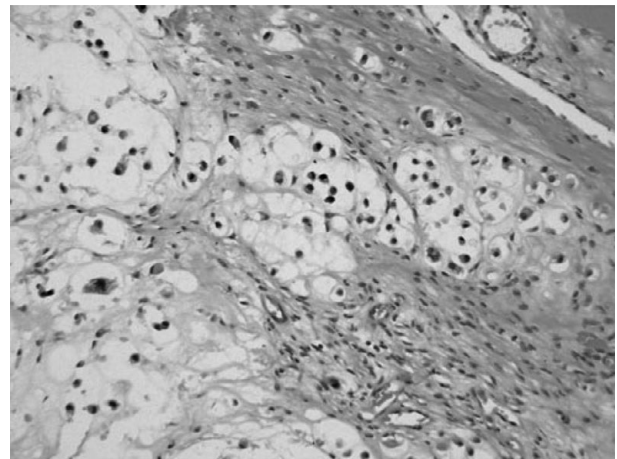


FIG. 7

Histopathology of a well differentiated (grade one) chondrosarcoma, characterised by spindle cell stroma containing chondrocytes in lacunae with a lobular configuration. There is minimal cellular atypia, with only occasional mitotic figures (H&E; original magnification $\times 400$).

with chondrosarcomas involving the skull base will present with ocular symptoms (i.e. diplopia or visual impairment) as the initial manifestation of the disease.¹⁸

Headache or facial pain was another common presenting feature, being reported by three patients. Facial dysaesthesias due to involvement of the trigeminal nerve (Vth cranial nerve) occurred in two patients. In contrast, in the report by Seidman *et al.*,¹⁰ hoarseness and dysphasia were the most common presenting symptoms in patients with temporal bone and skull base chondrosarcomas.

When evaluating our cases according to the cranial nerves involved, we found that the VIth cranial nerve

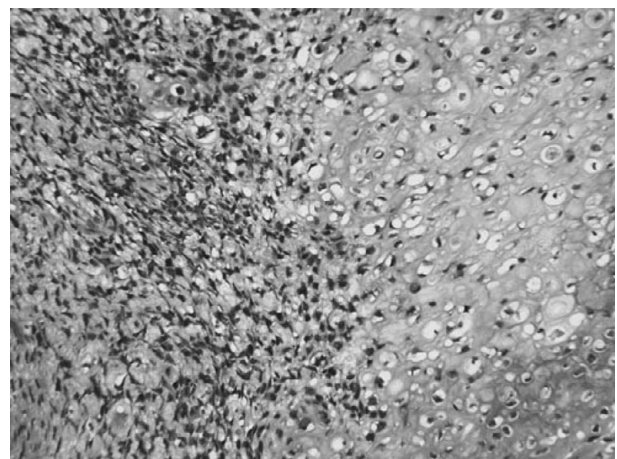


FIG. 8

Histopathology of a moderately differentiated (grade two) chondrosarcoma, showing a cellular, sarcomatous stroma at an interface with chondroid material containing dysplastic chondrocytic elements within lacunae. The latter shows vesicular nuclear chromatin, hyperchromatic staining and pleomorphic features. The stroma is highly cellular, being composed of streaming, predominantly spindle-shaped elements (H&E; original magnification $\times 400$).

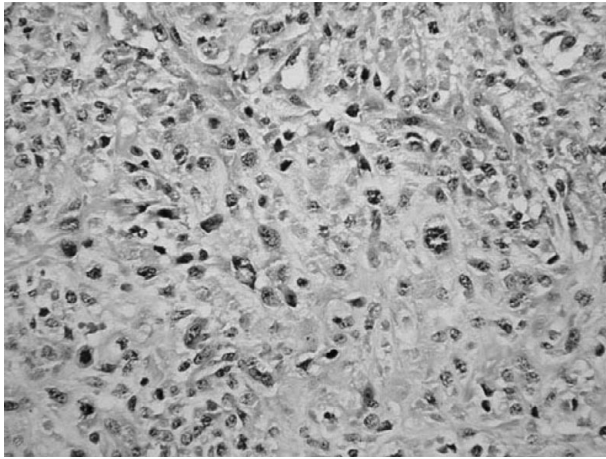


FIG. 9

Histopathology of a poorly differentiated (grade III) chondrosarcoma, showing a central area with marked cellular pleomorphism and nuclear aberrations, with only minimal chondroid differentiation (H&E; original magnification $\times 400$).

was the most commonly injured by tumour, followed by the IIIrd cranial nerve. In contrast, Seidman's report showed that the Xth cranial nerve was most commonly involved, followed by the VIth cranial nerve. Another series of temporal bone chondrosarcomas, reported by Coltrera *et al.*,⁷ showed that 75 per cent of their 12 patients presented with VIth cranial nerve deficits, similar to our study.

Most contemporary studies rely on MRI for characterisation and diagnosis of chondrosarcomas, while earlier studies relied upon computed tomography (CT). While CT is useful for defining the extent of bony destruction (Figures 2 and 6), MRI is superior in defining the tumour extent and the involvement of critical structures within the skull base (Figures 1–5).¹² The characteristic MRI appearance of chondrosarcoma is a low to medium signal on T1-weighted images, a high signal on T2-weighted images and enhancement with contrast (e.g. gadolinium). These lesions will often have a 'soap bubble' appearance, helping differentiate them from other bony lesions such as chordomas. Following treatment (radiation or surgery), serial post-operative MRIs are recommended for screening for recurrent disease. Whereas the MRI appearance of post-operative changes will be fairly stable over several scans spanning one to two years, recurrent disease will manifest as an enlarging lesion.

Histopathologically, chondrosarcomas are divided into four sub-types: conventional (hyaline/myxoid), dedifferentiated, clear cell and mesenchymal.^{4,19} Within the skull base, the conventional type is overwhelmingly the most common.⁴ These conventional chondrosarcomas can be further subdivided, based upon cellular features, into low grade or well differentiated (grade one), medium grade or moderately differentiated (grade two), and high grade or poorly differentiated (grade three), based upon the tumour's cellularity and atypia (although some features of grade three tumours overlap with those of

the undifferentiated variety).⁴ In the current study, four patients (33 per cent) had grade one tumours, six patients (50 per cent) had grade two tumours and two patients (17 per cent) had grade three tumours (Figures 7–9). These numbers are in contrast to Rosenberg's pathological review of 200 cases of skull base chondrosarcomas, which found 50 per cent grade one tumours, 21 per cent grade two tumours and no grade three tumours. The reason for the preponderance of grade two tumours in our current series is unclear.

Generally, chondrosarcomas, particularly the lower grade varieties, rarely metastasise but cause morbidity through local invasion of surrounding structures.²⁰ Thus, treatment has focused upon complete surgical excision, with radiation therapy being reserved for high grade tumours or following incomplete tumour resection. Within the skull base, the close proximity of chondrosarcomas to vital structures makes these guiding treatment principles even clearer. However, because these are in fact benign, often low grade lesions, the aim of treatment should be disease control with minimal surgical morbidity.

Because these tumours can arise in a variety of locations within the skull base, it is not surprising that a variety of surgical approaches, both anteriorly and laterally based, have been described. These ingenious approaches include the infratemporal fossa approach (as popularised by Fisch),²¹ the petrosal approach and its variations,^{22–24} the extended frontal approach,²⁵ the supra-infratentorial presigmoid avenue,²⁶ the transsphenoidal approach,²⁷ and the combined intradural presigmoid transversarium transcondylar approach,²⁸ to name just a few. As can be shown from this and prior series, the variable anatomic locations of these tumours require the surgeon to be familiar with a variety of anterior and lateral approaches to the skull base, depending upon the specifics of the presentation.

The decision to operate, particularly on asymptomatic lesions, can be a challenging one. Morbidity from these lesions results from growth and impingement upon surrounding structures. For asymptomatic lesions, an initial, conservative 'watch and wait' approach can be adopted, together with serial scanning. For those lesions showing rapid expansion or ones that become symptomatic during the observation period, intervention can then be planned.

In the current series, four of the patients required some form of lateral approach to reach the tumour; these approaches included variations on the infratemporal fossa approach type B or C.²¹ In contrast, six patients required anterior approaches to the tumour. These included mid-face degloving approaches in five patients and a transsphenoidal approach in one case. One patient required a standard suboccipital posterior fossa craniotomy, while another required a frontal craniotomy. In each case, the approach was based upon the specifics of the tumour, and was decided upon after consultation between our institution's skull base surgeons and neurosurgeons. As noted by Crockard *et al.*,²⁹ such a multidisciplinary

team approach is critical for effective management of these tumours.

Radiation therapy was used in five of the 12 patients in this series. The literature suggests that radiation therapy for chondrosarcomas is generally ineffective.¹ However, in this series, it was reserved for cases in which there was subtotal tumour resection or recurrence in the setting of inoperable tumour. Radiation treatment was given to one of the patients with a grade one tumour, three patients with grade two tumours and one patient with a grade three tumour. The only death in the series occurred in the patient with a 17-year recurrence of an inoperable grade three tumour, who received radiation in an attempt to control further tumour growth. At the time of writing, tumour growth in the remaining patients had been controlled, after follow up ranging from seven to 33 years. Other large series have shown similar efficacy for radiation therapy, as an adjunct to surgery, for treatment and control of chondrosarcoma.⁴ Proton radiation has also been advocated as a more useful modality by some,¹ although none of the patients in the current series received it.

- **This study evaluated the clinical presentation and treatment outcomes in 12 patients with chondrosarcomas involving the skull base and temporal bone**
- **Patients with chondrosarcomas involving the skull base and temporal bone may present in a variety of ways**
- **The decision to operate, particularly on asymptomatic lesions, can be a challenging one**
- **For asymptomatic lesions, an initial, conservative 'watch and wait' approach can be adopted, with serial scanning. For those lesions showing rapid expansion or becoming symptomatic during the observation period, intervention can then be planned**

Perhaps the strongest feature of the current series is the extended follow-up data available for all patients, over time periods ranging from six to 67 years from the original presentation and from three to 33 years from the most recent treatment. As some of the patients within this series demonstrate, recurrence can occur many years after treatment for these insidious tumours (as many as 17 years in this report). Thus, even five-year survival rates may not accurately reflect a tumour-free state. Prior studies have conflictingly shown that survival rates may either be related to histologic grade¹⁹ or bear no relation to histologic grade.⁴ In the large series of 200 patients reported by Rosenberg *et al.*,⁴ the five- and 10-year local control and disease-specific survival rates were approximately 98 per cent for all tumours, regardless of histological type. In contrast, in the review by Seidman *et al.*,¹⁰ 10-year survival rates were reported to be 83, 64 and 29 per cent for grade one, two and three tumours, respectively. By comparison, in the current study, five-year local

control and disease-specific control rates were 92 and 83 per cent, respectively. While those with grade one tumours were more likely to have their disease controlled with a single operation than those with grade two tumours, the data from our study suggest that the long-term control rates did not differ greatly between these histologic grades. However, as only two patients in the current study had grade three tumours, meaningful survival statistics cannot be generated.

These results, combined with data from prior studies, show that patients with chondrosarcomas, despite the anatomically challenging location within the skull base, can be effectively treated with a combination of surgery and radiation therapy. Even with recurrences or persistent disease, long-term control rates of over 10 years are generally possible.

References

- 1 Hug E, Slater J. Proton radiation therapy for chordomas and chondrosarcomas of the skull base. *Neurosurg Clin N Am* 2000;**11**:627–38
- 2 Berkmen Y, Blatt E. Cranial and intracranial cartilaginous tumours. *Clin Radiol* 1968;**19**:327–33
- 3 Jaffe H. *Tumours and Tumourous Conditions of the Bone and Joints*. Philadelphia: Lea Ferbigier, 1958;314–40
- 4 Rosenberg A, Nielsen P, Keel SB, Renard LG, Fitzek MM, Munzenrider JE *et al.* Chondrosarcomas of the base of skull. *Am J Surg Path* 1999;**23**:1370–8
- 5 Dahlin D, Unni K. Giant cell tumor in bone tumors: General aspects and data on 8542 cases. In: Thomas C, ed. *Osteoblastoma*, 4th edn. Springfield, Illinois: McGraw-Hill, 1986;119–40
- 6 Adegbite AB, McQueen JD, Paine KW, Rozdilsky B. Primary intracranial chondrosarcoma: a report of two cases. *Neurosurgery* 1985;**17**:490–4
- 7 Coltrera MD, Gooze PB, Harrant TJ, Hyams VJ, Schiller AL, Goodman ML. Chondrosarcoma of the temporal bone. Diagnosis and treatment of 13 cases and review of the literature. *Cancer* 1986;**58**:2689–96
- 8 Naufal PM. Primary sarcomas of the temporal bone. *Arch Otolaryngol* 1973;**98**:44–50
- 9 Lau DP, Wharton SB, Antoun NM, Bottrill ID, Moffat DA. Chondrosarcoma of the petrous apex. Dilemmas in diagnosis and treatment. *J Laryngol Otol* 1997;**111**:368–71
- 10 Seidman MD, Nichols RD, Raju UB, Mehta B, Levy HG. Extracranial skull base chondrosarcoma. *Ear Nose Throat J* 1989;**68**:626–32, 635
- 11 Burkey BB, Hoffman HT, Baker SR, Thornton AF, McClatchey KD. Chondrosarcoma of the head and neck. *Laryngoscope* 1990;**100**:1301–5
- 12 Brown E, Hug EB, Weber AL. Chondrosarcoma of the skull base. *Neuroimaging Clin N Am* 1994;**4**:529–41
- 13 Weber A, Brown E, Hug E, Liebsch N. Cartilaginous tumors and chordomas of the cranial base. *Otolaryngol Clin N Am* 1995;**28**:453–71
- 14 Korten A, ter Berg H, Spincemaille G, van der Laan R, Van de Wel A. Intracranial chondrosarcoma: review of the literature and report of 15 cases. *J Neurol Neurosurg Psychiatry* 1988;**65**:88–92
- 15 Munzenrider J, Liebsch N, Efrid J. Chordomas and chondrosarcomas of the skull base: treatment with fractionated X-ray and proton radiotherapy. In: Johnson J, Didolkar M, eds. *Head and Neck Cancer*. New York, NY: Elsevier Science Publishers, 1993;649–54
- 16 Koch BB, Karnell LH, Hoffman HT, Apostolakis LW, Robinson RA, Zhen W *et al.* National cancer database report on chondrosarcoma of the head and neck. *Head Neck* 2000;**22**:408–25
- 17 Kveton JF, Brackmann DE, Glasscock ME 3rd, House WF, Hitselberger WE. Chondrosarcoma of the skull base. *Otolaryngol Head Neck Surg* 1986;**94**:23–32

- 18 Volpe NJ, Liebsch NJ, Munzenrider JE, Lessell S. Neuro-ophthalmologic findings in chordoma and chondrosarcoma of the skull base. *Am J Ophthalmol* 1993; **115**:97–104
- 19 Evans HL, Ayala AG, Romsdahl MM. Prognostic factors in chondrosarcoma of bone: a clinicopathologic analysis with emphasis on histologic grading. *Cancer* 1977; **1**:818–31
- 20 Sheth DS, Yasko AW, Johnson ME, Ayala AG, Murray JA, Romsdahl MM. Chondrosarcoma of the pelvis. Prognostic factors for 67 patients treated with definitive surgery. *Cancer* 1996; **78**:745–50
- 21 Fisch U. Infratemporal fossa approach to tumours of the temporal bone and base of the skull. *J Laryngol Otol* 1978; **92**:949–67
- 22 Al-Mefty O, Fox JL, Rifai A, Smith RR. A combined infratemporal and posterior fossa approach for the removal of giant glomus tumors and chondrosarcomas. *Surg Neurol* 1987; **28**:423–31
- 23 Blevins NH, Jackler RK, Kaplan MJ, Gutin PH. Combined transpetrosal-subtemporal craniotomy for clival tumors with extension into the posterior fossa. *Laryngoscope* 1995; **105**:975–82
- 24 Megerian CA, Chiocca EA, McKenna MJ, Harsh GFT, Ojemann RG. The subtemporal-transpetrous approach for excision of petroclival tumors. *Am J Otol* 1996; **17**:773–9
- 25 Sekhar LN, Schramm VL Jr, Jones NF. Subtemporal-preauricular infratemporal fossa approach to large lateral and posterior cranial base neoplasms. *J Neurosurg* 1987; **67**:488–99
- 26 Samii M, Ammirati M. The combined supra-infratentorial pre-sigmoid sinus avenue to the petro-clival region. Surgical technique and clinical applications. *Acta Neurochir (Wien)* 1988; **95**:6–12
- 27 Lalwani AK, Kaplan MJ, Gutin PH. The transsphenoid approach to the sphenoid sinus and clivus. *Neurosurgery* 1992; **31**:1008–14
- 28 Ammirati M, Ma J, Cheatham ML, Mei ZT, Bloch J, Becker DP. The mandibular swing-transcervical approach to the skull base: anatomical study. Technical note. *J Neurosurg* 1993; **78**:673–81
- 29 Crockard HA, Steel T, Plowman N, Singh A, Crossman J, Revesz T *et al.* A multidisciplinary team approach to skull base chondrosarcomas. *J Neurosurg* 2001; **95**:175–83

Address for correspondence:

Dr Lawrence R Lustig,
Associate Professor,
Department of Otolaryngology – Head & Neck Surgery,
400 Parnassus Avenue,
A746, Box 0342,
San Francisco,
CA 94143-0342, USA.

E-mail: llustig@ohns.ucsf.edu

Dr L R Lustig takes responsibility for the integrity of the content of the paper.

Competing interests: None declared
