


Zhangwei Wang<sup>1</sup> , Kai Ma<sup>1</sup>, Yaobin Zhu<sup>2</sup> and Shoujun Li<sup>1</sup>

## Review

**Cite this article:** Wang Z, Ma K, Zhu Y, and Li S (2024) Innovation in surgical treatment of hypertrophic obstructive cardiomyopathy in children. *Cardiology in the Young* **34**: 1172–1181. doi: [10.1017/S104795112400057X](https://doi.org/10.1017/S104795112400057X)

Received: 13 February 2024  
Accepted: 7 March 2024  
First published online: 11 April 2024

**Keywords:**

children; hypertrophic obstructive cardiomyopathy; minimally invasive beating-heart surgery; progress

**Corresponding author:**

S. Li; Email: [drlishoujunfw@163.com](mailto:drlishoujunfw@163.com)

<sup>1</sup>Department of Cardiovascular Surgery, Chinese Academy of Medical Sciences and Peking Union Medical College, National Center for Cardiovascular Diseases, Fuwai Hospital, Beijing, China and <sup>2</sup>Department of Cardiac Surgery, Beijing Children's Hospital, Capital Medical University, National Children's Medical Center, Beijing, China

**Abstract**

Hypertrophic cardiomyopathy is the second most common cardiomyopathy affecting children and adolescents and is the main cause of sudden death of young athletes. The natural prognosis of children with severe hypertrophic obstructive cardiomyopathy is not optimistic, and it is not uncommon for children with hypertrophic obstructive cardiomyopathy who do not respond to medication. Surgical treatment is often the only solution. Conventional surgical methods in the past include classic or modified extended Morrow operation, classic or modified Konno operation, and Ross-Konno operation. In recent years, with the development of minimally invasive surgery, various minimally invasive surgical methods have emerged endlessly. Because the incision of minimally invasive cardiac surgery is significantly smaller than that of traditional surgery, it causes less trauma, recovers quickly after surgery, and has the advantage of no difference in surgical effect compared with traditional median sternotomy. Tally endoscopic transmitral myectomy, RTM, minimally right thoracotomy, and other surgical methods have achieved encouraging results in adults and some older children with hypertrophic obstructive cardiomyopathy. The appearance of transapical beating-heart septectomy has brought the treatment of hypertrophic obstructive cardiomyopathy from the era of cardiopulmonary bypass and cardiac arrest to a new era of minimally invasive beating-heart surgery. In the past, there were few articles about the treatment of children with hypertrophic obstructive cardiomyopathy. This article reviewed the new progress and prognosis of surgical treatment of children with hypertrophic obstructive cardiomyopathy at home and abroad.

Hypertrophic cardiomyopathy is a heterogeneous and often familial myocardial disease. About 50% of children with hypertrophic cardiomyopathy have Mendelian dominant inheritance, which is caused by mutation of one of the 10 genes encoding myocardial sarcomere protein. The most characteristic pathological abnormality of hypertrophic cardiomyopathy is left ventricular hypertrophy. The ventricular cavity is usually small or normal. The most common one is asymmetric ventricular septum hypertrophy, namely idiopathic hypertrophic cardiomyopathy.<sup>1</sup> Under the microscope, we can see a wide range of hypertrophic cardiomyocytes, myocardial scars, and abnormal intramuscular small coronary arteries. Hypertrophic cardiomyopathy is divided into three types according to whether there is an obstruction in the left ventricular outflow tract: Resting obstruction type (when the patient is quiet, the left ventricular outflow tract systolic pressure gradient is greater than 50 mmHg); Latent obstruction type (when the patient is quiet, the left ventricular outflow tract systolic pressure gradient is 0–30 mmHg, but when isoproterenol is given or Valsalva is performed, the pressure gradient rises immediately and exceeds 50 mmHg); Non-obstructive type (whether the patient is quiet or under induced conditions, the left ventricular outflow tract systolic pressure gradient is less than 30 mmHg). In some patients, the pressure gradient is formed in the middle of the ventricular cavity under the aortic valve during the systole, which is called hypertrophic obstructive cardiomyopathy. Subaortic obstruction is often caused by the systolic anterior motion of the mitral valve towards the hypertrophic ventricular septum. Systolic anterior motion is caused by ventri force caused by high-speed outflow tract blood flow and mitral regurgitation. Symptomatology and clinical manifestations vary from asymptomatic to severe restrictive symptoms, such as angina, dyspnoea, syncope, and even sudden cardiac death. The pathophysiological mechanisms leading to hypertrophic cardiomyopathy symptoms mainly include left ventricular outflow tract obstruction, mitral regurgitation, systolic anterior motion, ventricular diastolic dysfunction, and ventricular arrhythmia.

Hypertrophic cardiomyopathy is the second most common cardiomyopathy affecting children and adolescents, which is the main cause of sudden death in young athletes.<sup>2</sup> Children with hypertrophic cardiomyopathy are usually asymptomatic, and the overall case fatality rate of children with hypertrophic cardiomyopathy after the first year is 1%. However, hypertrophic cardiomyopathy with clinical symptoms and hypertrophic cardiomyopathy-induced SD can be seen in childhood. It is estimated that the incidence rate of sudden death in children and

adolescents is as high as 6.2/100000, and 36% of paediatric sudden death can be attributed to hypertrophic cardiomyopathy.<sup>3</sup> The causes of hypertrophic cardiomyopathy in paediatric population include congenital metabolic defects, malformation syndrome, neuromuscular disorders, and idiopathic hypertrophic cardiomyopathy, among which idiopathic hypertrophic cardiomyopathy accounts for the highest proportion, up to 74.2%.<sup>2</sup> Biventricular obstruction, myocardial bridge, and abnormal ventricular anatomy are common phenotypic components.<sup>4</sup> The causes of patients with symptoms before the age of 1 year are the most extensive. The main cause of infant hypertrophic cardiomyopathy is Noonan syndrome, and the prognosis is the worst. However, among children with i-hypertrophic cardiomyopathy who survived beyond 1 year of age, survival was independent of age at diagnosis, and the annual mortality rate was no different from that found in population-based adult studies. The most common cause of death in children with hypertrophic obstructive cardiomyopathy is progressive congestive heart failure. Death from congestive heart failure usually occurs shortly after diagnosis, and the risk of sudden death persists. The presence of heart failure symptoms and a large cardi thoracic proportion are significant risk factors for heart failure-related death in children with hypertrophic obstructive cardiomyopathy.<sup>5</sup> In children with symptomatic hypertrophic obstructive cardiomyopathy, risk factors include a family history of sudden death, ventricular septal thickness greater than 30 mm, and a history of ventricular tachycardia and syncope.<sup>6</sup> The risk factors for death or transplantation in long-term follow-up of children with hypertrophic obstructive cardiomyopathy include symmetric left ventricular hypertrophy, onset age less than 1 year, low initial fractional shortening z-score, and high left ventricular posterior wall thickness z-score.<sup>7</sup> In the past, there was little literature about the treatment of children. This article reviewed the new progress and prognosis of surgical treatment of children with hypertrophic obstructive cardiomyopathy at home and abroad.

## History of surgical procedures for hypertrophic cardiomyopathy

### Conventional surgical procedures

In the 1950s, Teare et al.<sup>8</sup> pointed out that the pathological feature of hypertrophic obstructive cardiomyopathy was asymmetric myocardial hypertrophy. Brock et al. first found and described the characteristics of left ventricular outflow tract obstruction, and first proposed the necessity of surgical treatment. In 1964, Braunwald et al.<sup>9</sup> named it idiopathic hypertrophic subaortic stenosis. In the same year, Goodwin et al.<sup>10</sup> named it hypertrophic obstructive cardiomyopathy, pointing out that the systolic anterior motion is related to the anterior leaflet of the mitral valve, and performed subaortic hypertrophy myocardial resection. Trimble et al.<sup>11</sup> proposed a simple method to remove the hypertrophic muscle under the aortic valve. Later, Morrow et al.<sup>12</sup> proposed the classic Morrow operation, namely, septectomy under the aortic valve, which significantly reduced the mortality and complications of the surgery. In 1976, Cooley et al.<sup>13</sup> used the method of subvalvular septectomy and mitral valve replacement to avoid the left ventricular outflow tract obstruction caused by systolic anterior motion. In the late 1980s, gene research on hypertrophic cardiomyopathy began. Jarcho et al.<sup>14</sup> first found that the pathogenic gene of familial hypertrophic cardiomyopathy encodes myosin heavy chain, which is located on autosomal 14q1. Tanigawa et al.<sup>15</sup> found that mutations in genes encoding

sarcomere proteins can lead to familial hypertrophic cardiomyopathy, thus starting the molecular genetics study of hypertrophic cardiomyopathy. In recent years, some scholars have found that the main reason for recurrent stenosis after surgery is that hypertrophic muscle resection is not complete. They have learned that some patients not only have subvalvular myocardial hypertrophy but also have fusiform hypertrophy, central hypertrophy, apical hypertrophy, and other different forms. Only removing the subvalvular muscle can not completely solve the problem, so they have modified extended Morrow operation.<sup>16,17</sup> Compared with the rectangular resection of the classic Morrow operation, the modified Morrow operation expands the resection scope to the left and right sides and the apex, continuing the previous "one well" score, that is, the classic Morrow operation may only dredge a quarter of the shallow mud near the wellhead, while the modified Morrow operation dredges up half a circle of mud and reaches the bottom of the well. Recent studies have shown that for apical hypertrophic hypertrophic cardiomyopathy, septectomy via apical incision can effectively expand the volume of the ventricular chamber, improve the cardiac ejection fraction, and joint aortic incision can relieve left ventricular outflow tract obstruction. For patients with complex hypertrophic obstructive cardiomyopathy, including left ventricular outflow tract obstruction and hypertrophy involving 7 cm or more below the aortic valve, combined with middle obstruction, apical hypertrophy, apical thinning, or ventricular aneurysm formation, compared with the simple aortic incision, the combined aortic and apical incision may be more effective in relieving the obstruction and improving the patient's cardiac function.<sup>18,19</sup> The surgical experience of paediatric population is limited, but septectomy can safely and effectively reduce the left ventricular outflow tract obstruction. In more serious cases in children, Konno-Rastan operation, modified Konno-Rastan operation, or Ross-Konno operation may also be performed, with good long-term outcomes.<sup>20,21</sup>

### Treatment of abnormal mitral valve and subvalvular structure

At present, most hypertrophic obstructive cardiomyopathy patients requiring surgery can relieve left ventricular outflow tract obstruction and mitral regurgitation caused by systolic anterior motion through modified Morrow operation. However, 10–20% of patients still have symptoms that cannot be relieved after operation,<sup>22</sup> which is mainly due to the failure to fully remove hypertrophic muscles and to properly handle the prolonged mitral valve leaflet and abnormal structures under the mitral valve. Left ventricular outflow tract obstruction, systolic anterior motion, and mitral regurgitation interact with each other. Left ventricular outflow tract obstruction can cause increased left ventricular outflow tract pressure gradient and accelerated blood flow velocity in the left ventricular outflow tract. When the left ventricular contracts, the impact of high-speed blood flow in the left ventricular outflow tract will further aggravate the forward motion of the mitral valve leaflet, which can lead to systolic anterior motion, and mitral regurgitation due to poor valve adhesion. Prolonged anterior mitral leaflet, abnormal papillary muscle position, and morphology will not only cause mitral regurgitation but also systolic anterior motion and aggravate left ventricular outflow tract obstruction. Therefore, some scholars suggest that for patients with hypertrophic obstructive cardiomyopathy who have only mild or moderate mitral regurgitation but no definite mitral valve organic disease, simply modified and expanded Morrow

operation can eliminate mitral regurgitation without mitral valve repair. However, for hypertrophic obstructive cardiomyopathy patients with moderate or higher mitral regurgitation or with organic lesions in the mitral valve, mitral valve repair should be actively performed during the modified extended Morrow procedure to eliminate systolic anterior motion and mitral regurgitation as much as possible. For complicated hypertrophic obstructive cardiomyopathy patients with prolonged mitral valve anterior leaflet, abnormal adhesion of mitral valve leaflet and ventricular wall, some scholars have adopted “RPR” technique (R, reservation, enlarged resection of hypertrophic muscle; P, duplication, folding of anterior leaflet of mitral valve; R, release, abnormal subvalvular structure release of mitral valve) in recent years, and achieved satisfactory clinical results.<sup>22,23</sup> Ferrazzi *et al.*<sup>24</sup> first proposed partial secondary chordae resection and reported excellent results. The study of Eilon Ram<sup>25</sup> showed that in hypertrophic obstructive cardiomyopathy patients, the removal of the secondary chordae while performing septectomy would increase the aortic-mitral valve angle, thereby retracting the mitral valve anterior leaflet from the left ventricular outflow tract during the systolic period. Small aortic-mitral angle helps systolic anterior motion, allowing the anterior leaflet to approach left ventricular outflow tract. In their study, Varghese *et al.*<sup>26</sup> showed that a too-small angle (<110°) is an independent predictor for systolic anterior motion that results in left ventricular outflow tract obstruction and recurrent mitral regurgitation.

#### *Minimally invasive surgery and the beating-heart era*

Over the past decades, attempts to reduce surgical trauma and improve visualisation have led to the application of minimally invasive techniques with thoracoscopic or robotic assistance or right mini-thoracotomy.<sup>27,28</sup> With the development of invasive surgery, right mini-thoracotomy is increasingly used in minimally invasive cardiac surgery.<sup>29,30</sup> Meiju’s team recently published the experience of their centre. The modified expanded Morrow operation and “edge to edge” mitral valvoplasty via right mini-thoracotomy incision are safe and effective for the treatment of hypertrophic obstructive cardiomyopathy with mitral regurgitation, which can not only effectively relieve left ventricular outflow tract obstruction but also effectively eliminate mitral regurgitation and systolic anterior motion.<sup>30</sup> The previous surgical methods were all performed under cardiac arrest with the support of cardiopulmonary bypass. The perioperative period is a particularly important time because anaesthesia, surgical stress, and the immune stimulation effect of the cardiopulmonary bypass circuit together cause a systemic inflammatory reaction.<sup>31</sup> Recently, Wei Xiang’s team reported an animal study on septectomy in beating hearts of pigs by minimally invasive method, which showed that it was feasible to perform ventricular septal muscle resection under beating hearts.<sup>32</sup> They then reported the technique of transapical beating-heart septectomy in patients with hypertrophic obstructive cardiomyopathy and achieved considerable early results.<sup>45</sup>

#### **Indication of surgical treatment for hypertrophic obstructive cardiomyopathy patients**

The purpose of surgical treatment is to reduce ventricular contractility, increase ventricular volume, improve ventricular compliance, increase the inner diameter of left ventricular outflow tract, and reduce left ventricular outflow tract pressure gradient: (1) hypertrophic obstructive cardiomyopathy that did not respond to

medication or interventional therapy; (2) The left ventricular outflow tract pressure gradient in resting state was > 50 mm Hg; (3) There was no obvious pressure gradient at rest, but the left ventricular outflow tract pressure gradient under drug stress was > 50 mm Hg; (4) Patients with atrial fibrillation who can be considered for surgical treatment; (5) Patients with clear family history and risk of sudden death, even if asymptomatic, are suitable for surgical treatment.<sup>33</sup>

#### **Surgical methods**

##### *Classic morrow procedure*

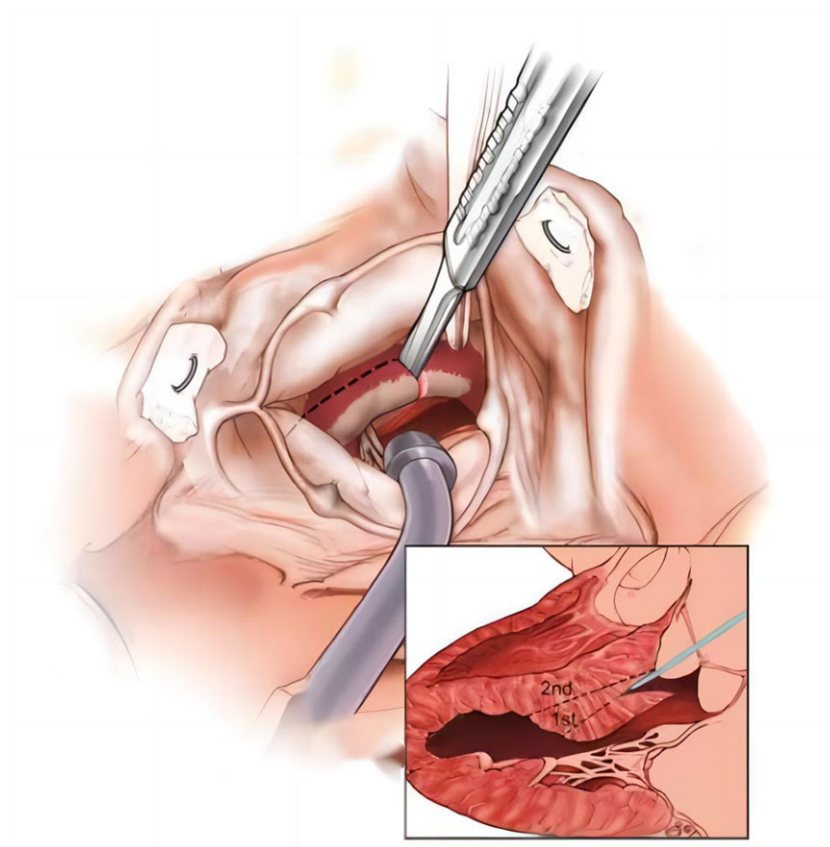
Median sternotomy was performed, and left ventricular outflow tract was fully exposed through a transverse aortic incision to explore the hypertrophic ventricular septum and the subvalvular structure of the mitral valve. Make a longitudinal incision downward from the junction of the right and left coronary valves, and then make a second longitudinal incision downward at the lowest point of the right coronary valve. Make a transverse incision 1 cm below the valve to connect the two longitudinal incisions, extending downward by 12–15 mm. Cut the hypertrophic ventricular septum in a rectangle, and pay attention to avoiding the membranous ventricular septum and His bundle. After the heart returned to beating, ultrasound showed that the flow velocity of the outflow tract was slow or normal, and left ventricular outflow tract pressure gradient was less than 30 mmHg, which indicated that the surgical effect was satisfactory.

##### *Modified morrow procedure*

The aortic transverse incision was made from the root of the aortic artery to the direction of the coronary sinus. A transverse incision was made below the right coronary sinus in the direction of the junction of the left coronary sinus and the anterior mitral valve, down to the root of the papillary muscle to the apex of the heart. The papillary muscle root can be seen directly through the aortic root incision. When there is an abnormal subvalvular structure of the mitral valve, the abnormal adhesion between the papillary muscle root and the left ventricular surface is released and the abnormal attachment tendinous cord between the anterior leaflet of the mitral valve and the ventricular septum is removed. The resected thickness is generally 40%~50% of the interventricular septal thickness. During operation, attention should be paid to aortic valve and mitral valve (Fig. 1).

##### *Konno-Rastan procedure*

Konno operation has been widely used in hypertrophic obstructive cardiomyopathy patients with multilevel left ventricular outflow tract obstruction or double ventricular outflow tract obstruction. Konno type incision between left and right coronary valves was determined. Cut the aorta, extend the incision into the interventricular septum through the right ventricle, and then remove the narrowed aortic valve leaflet. The artificial valve can be implanted from the rear edge of the aortic valve ring. The anterior wall of left ventricular outflow tract was reconstructed by enlarging the ventricular septum, suturing the artificial valve onto the patch, and enlarging the ascending aorta. If there is obstruction of the right ventricular outflow tract at the same time, the right ventricular outflow tract incision shall be expanded with a pericardial patch.<sup>34</sup>



**Figure 1.** Modified Morrow procedure.

#### Modified Konno-Rastan procedure

This technique should be considered as an alternative to hypertrophic obstructive cardiomyopathy with extensive hypertrophy, associated right heart obstruction, and secondary hypertrophic obstructive cardiomyopathy. The modified Konno-Rastan procedure was limited to the expansion of left ventricular outflow tract obstruction and did not include the aortic annulus. The aorta was opened by a vertical incision extending towards the aortic coronary sinus junction, and the right ventricular septum was exposed as an oblique incision towards the coronary sinus junction at the right ventricular funnel. The right-angle clamp is inserted through the aortic valve. The head end of the right-angle clamp is guided as a transmural incision of the ventricular septum. The interventricular septum incision extends to the junction of the aortic coronary sinus and extends to the left as far as possible below the incision to avoid damaging the conduction bundle and the septal branch. The aorta was opened by a vertical incision extending towards the aortic coronary sinus junction, and the right ventricular septum was exposed as an oblique incision towards the coronary sinus junction at the right ventricular funnel. The right-angle clamp is inserted through the aortic valve. The head end of the right-angle clamp is guided as a transmural incision of the ventricular septum. The interventricular septum incision extends to the junction of the aortic coronary sinus and extends to the left as far as possible below the incision to avoid damaging the conduction bundle and the septal branch. The hypertrophic myocardium was resected through the interventricular septal incision. The interventricular septal incision was closed again with a pericardial patch. Double ventricular outflow tract incisions were expanded with an autologous pericardial patch.<sup>33</sup>

#### Ross-Konno technique

The combination of classic Konno-Rastan procedure and Ross procedure can relieve all subaortic, aortic stenosis, and right ventricular outflow tract stenosis in patients with hypertrophic obstructive cardiomyopathy. After aortic clamp, the aortic root and aortic valve were completely removed. Freed coronary artery and retain a large button-shaped aortic wall at the coronary artery opening. The autologous pulmonary valve was harvested. According to Konno, an incision was made on the ventricular septum to open the subaortic region and aortic annulus. The autologous pulmonary artery valve was sutured to the bottom of the left ventricle. The left coronary artery was implanted. The distal anastomosis of allogeneic valved pulmonary artery allograft was constructed to reconstruct the right ventricular outflow tract. The distal anastomosis of the aorta was completed before implantation of the right coronary artery<sup>34</sup> (Fig. 2).

#### Tally endoscopic transmitral myectomy

The main operating incision is taken from the front of the fourth intercostal axillary line of the right chest to the midclavicular line for 3.0 ~ 3.5 cm. The incision soft tissue protective sheath, aortic perfusion needle, and surgical instruments were placed. Take the fourth intercostal cavity close to the midline of the axilla to make a 1.5 cm incision, place the incision protective sheath, and enter the thoracoscope. A 1.5 cm incision was made near the posterior axillary line of the fifth intercostal space, and a protective sheath was placed for the access of the aortic clamp, left atrial drainage tube, and pericardial suspension wire. From the root of the ascending aorta to the root of the inferior vena cava, the



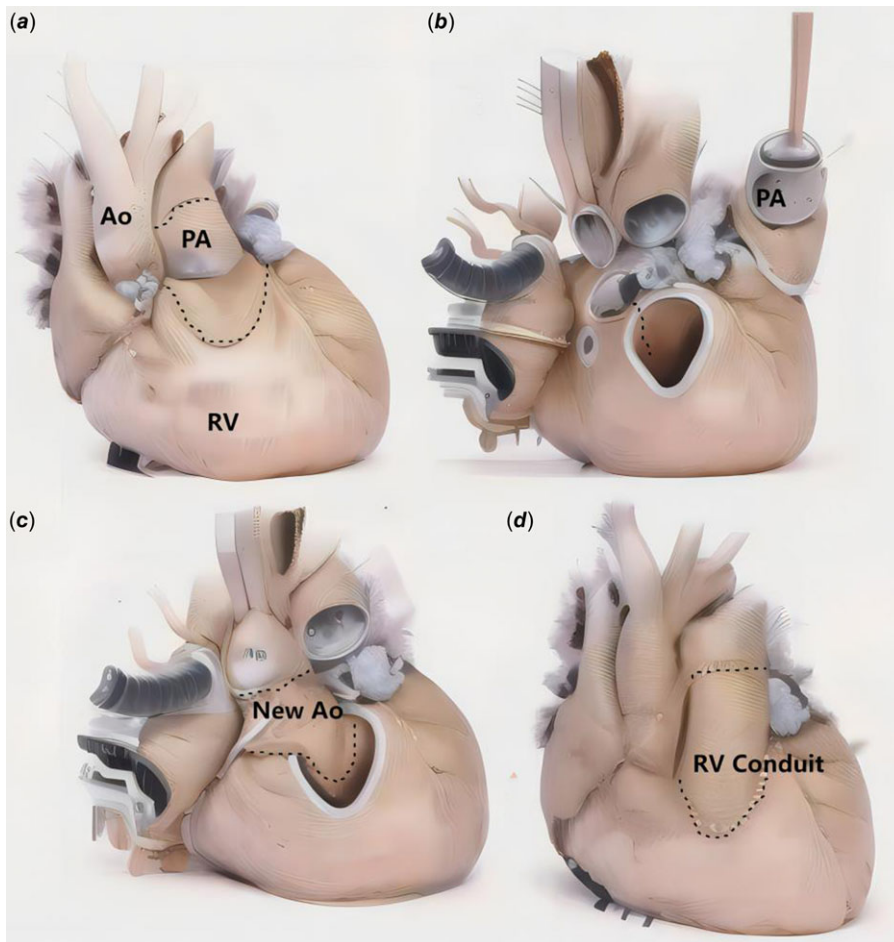


Figure 2. Ross-Konno procedure.

pericardium was cut about 2 cm above the phrenic nerve. After clamp of the aorta and perfusion of the HKT solution, the interatrial groove was incised, and then septectomy was performed via the mitral valve. Because the mitral valve approach can better expose the middle segment of the ventricular septum and the apex, the resection range can be extended to the apex and papillary muscle root.<sup>35</sup>

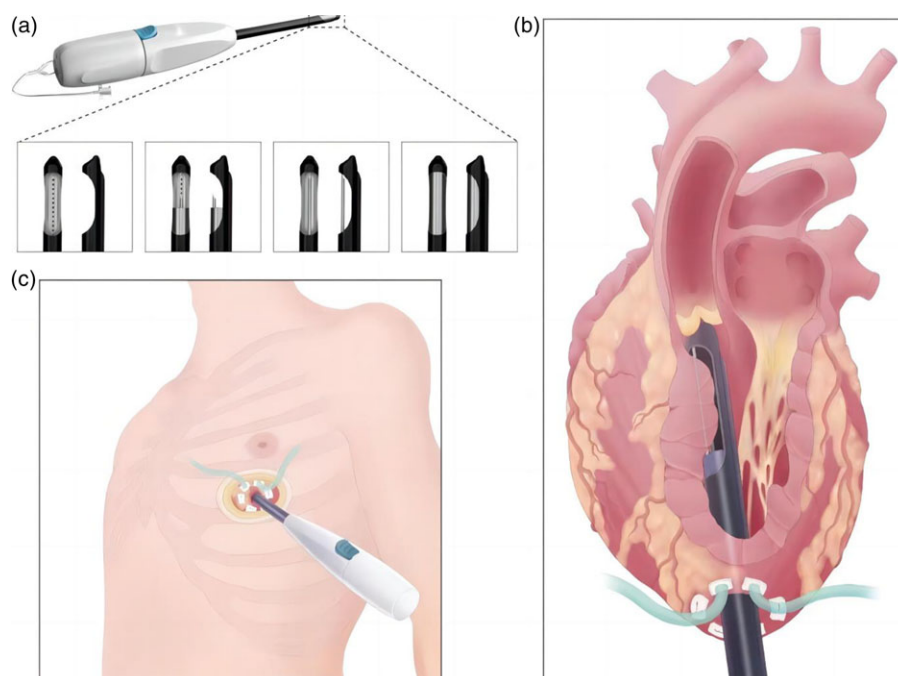
#### Extended septectomy via robotic transmitral approaches (RTM)

The working port and trocar ports are made first before heparinization. The 3-cm working port is placed in the 4th intercostal space around the right anterior axillary line. The right arm is inserted into the 6th intercostal space and the left arm into the 3th intercostal space. The left atrial retractor is inserted into the 4th intercostal space. Next, cardiopulmonary bypass is established with routine peripheral cannulation through the right femoral artery and vein. A cardioplegic needle and aortic cross-clamp are inserted through the working port, and antegrade cardioplegic solution is delivered. Routinely, a left atrial approach is adopted, with an incision through Sondergaard's plane. The mitral valve is exposed using an atrial retractor. Size the anterior leaflet first, using a sizing template. Once the size is determined, make a bovine pericardial patch using the template. The size also determines the posterior annuloplasty ring. Then take down the anterior mitral leaflet. The leaflet is detached from commissure to commissure, which allows the surgeon to evaluate the septum

from the aortic annulus to the left ventricular apex. The aortic valve is carefully checked to avoid injuring either it or the annulus; the presence of a jet lesion should also be checked and any lesions removed completely. The hypertrophied left ventricular muscle, including the apical muscle, is removed completely using this approach.<sup>44</sup>

#### Modified expanded morrow procedure via right mini-thoracotomy incision

After successful general anaesthesia, the patient was intubated with double lumen trachea in supine position, and the right chest and back were raised by 30°. Femoral artery cannula is used as arterial blood supply pipe, and femoral vein cannula is used to drain the blood of vena cava to establish cardiopulmonary bypass. Enter the chest through the third intercostal transverse incision at the right anterolateral side of the sternum, cut the pericardium longitudinally and suspend it to expose the heart. The hypertrophic septal myocardium, abnormal muscle trabeculae or hypertrophic muscle bundles, and fused papillary muscles were removed through the oblique incision at the root of the ascending aorta, using the coronary sharp knife and minimally invasive scissors, and using the modified expanded Morrow procedure. Explore the mitral valve disease, and determine that it is caused by functional mitral insufficiency or prolonged mitral valve anterior leaflet. Apply nerve retractor to pull and align the anterior and posterior leaflets of the mitral valve to determine the suture site. Apply 5-0 Prolene suture to suture the anterior and posterior



**Figure 3.** Transapical beating-heart septectomy.

leaflets of the mitral valve with “edge to edge” technology, to form a “double hole” mitral valve. Apply nerve retractor again to pull and explore the mitral valve and its subvalvular structure, to avoid mitral stenosis after operation. After cardiopulmonary bypass was stopped, intraoperative transesophageal echocardiography was used to evaluate the patency effect of left ventricular outflow tract, mitral regurgitation, and systolic anterior motion.<sup>36</sup>

#### Transapical beating-heart septectomy

The patients were positioned supine and draped for left mini-thoracotomy or sternotomy. Mini-thoracotomy was mostly performed in the fifth or the sixth intercostal space at the left midclavicular line, as determined by the TTE-identified location of the left ventricular apex. Following incision and suspension of the pericardium, double-circumferential purse-string sutures with Teflon felt pledgets were placed in the avascular zone of the apex and secured with snares to provide haemostasis and left ventricular entrance for the beating-heart myectomy device. Left ventricular apical pressure, which represents the highest pressure generated by left ventricular outflow tract obstruction, was measured using a manometric catheter inserted through the purse string. The systolic pressure gradient between the apical pressure and the peripheral arterial pressure, reflecting the left ventricular outflow tract pressure gradient, was calculated. An isoproterenol provocation test was performed if the resting LVOTG was less than 50 mmHg. An apical puncture was produced inside the purse string and was dilated using a dilator along a guidewire. After deairing, the beating-heart myectomy device in the OFF state was introduced into the left ventricular outflow tract through the apical puncture under the navigation of Transoesophageal echocardiography. The location of the resection window was three-dimensionally identified by Transoesophageal echocardiography. Specifically, the depth of the beating-heart myectomy device tip was identified in the mid-esophageal long-axis view. The orientation of the resection window was identified in the transgastric short-axis views at the basal and mid-ventricular

levels. The first resection was performed in the basal anterior septum, which was located 5–10 mm beneath the nadir of the right aortic cusp in the long-axis view, and to the midpoint of the septum in the short-axis view, corresponding to the orifice of the right coronary artery. Based on the first resection, the second resection was performed in the basal anterior septum parallel but slightly anterior to the first resection. The orientation of the second resection was identified on the short-axis view and was achieved by rotating the device 60–120° clockwise from the first resection. The morphology of the septal bulge, the left ventricular outflow tract pressure gradient, the mitral regurgitation grade, and the remaining thickness of the target septum was evaluated after each resection<sup>27</sup> (Fig. 3).

#### Prognosis

##### Natural course of children with hypertrophic obstructive cardiomyopathy

The natural course of hypertrophic obstructive cardiomyopathy progresses at different speeds, and the prognosis varies from person to person. It can show asymptomatic, heart failure, and sudden death. The severity of symptoms is related to the severity of left ventricular outflow tract obstruction, not the age of the patient. Most hypertrophic obstructive cardiomyopathy children have no symptoms and their life expectancy is similar to that of the general population. However, 25–30% of patients have significant hypertrophic obstructive cardiomyopathy-related symptoms or sudden death. Restrictive symptoms are caused by the complex interaction of left ventricular outflow tract obstruction, mitral regurgitation, diastolic dysfunction, and arrhythmia. Infants with severe left ventricular hypertrophy are prone to heart failure, with high sudden death rate, history of syncope, and family history. Without surgical treatment, the 5-year mortality of symptomatic patients was 15%, and the 10-year mortality was 25%. Heart failure is the most common cause in children, followed by sudden death. Peta M. A. Alexander<sup>8</sup> reported a national cohort study on the long-

term prognosis of children with hypertrophic cardiomyopathy in Australia, with a median follow-up time of 15 years for survivors. The greatest risk of death or transplantation for children with hypertrophic cardiomyopathy is in the first year after diagnosis, with 14% of study subjects achieving this combined end-point, compared to 0.4% per year thereafter. From multivariable analyses, risk factors for death/transplantation included symmetric left ventricular hypertrophy at the time of diagnosis, Noonan syndrome, higher posterior wall thickness z-score, and lower fractional shortening z-score during follow-up. Children with hypertrophic cardiomyopathy who are alive one year after diagnosis have low long-term rates of death or transplantation. The majority of surviving subjects have no symptoms. Alan W. Nugen et al.<sup>36</sup> reported a longitudinal cohort study in which all Australian children with primary cardiomyopathy between the ages of 0 and 10 were included between January 1, 1987 and December 31, 1996. A total of 80 hypertrophic cardiomyopathy subjects were identified. The freedom from death or transplantation after 5 years of onset was 83%, and the freedom from death or transplantation after 10 years of onset was 76%. The prevalence of hypertrophic cardiomyopathy in children is low, and the causes of hypertrophic cardiomyopathy are diverse. The leading cause of infantile hypertrophic cardiomyopathy is Noonan syndrome. Further, there is a secondary hypertrophic cardiomyopathy with various causes such as storage disease and mitochondria cardiomyopathy in children. Only 30–50 % of patients with suspected hypertrophic cardiomyopathy have been identified as showing a sarcomere genetic mutation, with the cause unknown in the remaining cases. Etsuko Tsuda's team reported long-term outcomes based on different types of hypertrophic cardiomyopathy in children.<sup>37</sup> They reviewed the medical records of 100 patients with hypertrophic cardiomyopathy at their hospital between 1977 and 2015. The age at the time of the diagnosis ranged from 0 to 15 years with a median of 8 years. The number of patients with Noonan syndrome and hypertrophic obstructive cardiomyopathy, i-hypertrophic cardiomyopathy, and s-hypertrophic cardiomyopathy was 13, 13, 65, and 9, respectively. A dilated phase of hypertrophic cardiomyopathy occurred in 24 patients. Nineteen of the 24 patients died of heart failure, and two underwent heart transplantation. Eight of the 24 patients had s-hypertrophic cardiomyopathy. The median age when a dilated phase occurred was 15 years old, and the median interval from the initial diagnosis to the dilated phase was 8 years. The median time from the diagnosis of a dilated phase to death was 1.6 years. The 20-year survival rates were as follows: Noonan syndrome 84%; hypertrophic obstructive cardiomyopathy 82%; i-hypertrophic cardiomyopathy 71%; and s-hypertrophic cardiomyopathy 17%. Overall, the survival rates at 10, 20, and 30 years were 83, 69, and 63%, respectively. The overall cardiac event-free survival rates at 10, 20, and 30 years were 57, 39, and 32%, respectively. Colan SD et al.<sup>36</sup> reported the epidemiology and cause-specific outcomes of 855 cases of hypertrophic cardiomyopathy in children according to the Children's Cardiomyopathy Registration Form. Of 855 patients < 18 years of age with hypertrophic cardiomyopathy, 8.7% had congenital metabolic defects, 9.0% had malformation syndromes, 7.5% had neuromuscular disorders, and 74.2% had i-hypertrophic cardiomyopathy. Children with hypertrophic cardiomyopathy associated with congenital metabolic defects and malformation syndromes have significantly worse survival than the other two groups. Patients with i-hypertrophic cardiomyopathy diagnosed before 1 year of age had worse survival from the time of diagnosis than those diagnosed after 1 year of age.

Patients with i-hypertrophic cardiomyopathy who survived to at least 1 year of age, however, had an annual mortality rate of 1% that was similar regardless of whether they were diagnosed before or after 1 year of age. In children, hypertrophic cardiomyopathy is a diverse disorder with outcomes that depend largely on cause and age. Patients presenting before 1 year of age have the broadest spectrum of causes and the poorest outcome. In those children with idiopathic hypertrophic cardiomyopathy who survive beyond age 1, however, survival is independent of age at diagnosis, with an annual mortality rate that is much lower than previously reported in children and is not different from what has been found in population-based studies in adults. Hiroki Mori et al.<sup>37</sup> reported the first multicenter retrospective observational study on hypertrophic cardiomyopathy in children in Japan. There are 20 institutions involved. They analysed the long-term survival rate of hypertrophic cardiomyopathy patients under 18 years of age between 1990 and 2014. A total of 180 patients were identified. The median age at diagnosis was 5.8 years, and the observation time was 8.3 years. Although 3% deteriorated to hypertrophic cardiomyopathy expansion stage, no patient received heart transplantation. At the ages of 1, 5, 10, and 20, the freedom from death was 97, 92, 84, and 80%, respectively. Twenty-six people died. Among them, 11 cases died suddenly, possibly due to arrhythmia, and 15 cases died of heart failure.

### *Prognosis of surgical intervention in children with hypertrophic obstructive cardiomyopathy*

#### *Conventional operation*

For patients with hypertrophic obstructive cardiomyopathy whose left ventricular outflow tract pressure gradient exceeds 50 mmHg and whose symptoms cannot be relieved by drugs, interventricular septal volume reduction is required. At present, the most widely used surgical methods for hypertrophic obstructive cardiomyopathy children include classic or modified Morrow procedure, classic or modified Konno procedure, and Ross-Konno procedure. According to the published results of such operations, encouraging achievements have been made at home and abroad. Fuwai Hospital describes the clinical manifestations and relevant surgical results of hypertrophic obstructive cardiomyopathy in Chinese children.<sup>38</sup> A total of 117 consecutive children with hypertrophic obstructive cardiomyopathy aged 0.6–17.5 years who underwent septectomy at their institution between February 2009 and December 2018 were included. In their study, the anatomical and physiological characteristics of childhood hypertrophic obstructive cardiomyopathy were highly heterogeneous, with simultaneous right ventricular outflow tract obstruction in 22 patients (18.8%), coronary myocardial bridging in 25 patients (21.4%), and intraventricular anatomical abnormalities in 61 patients (52.1%). left ventricular outflow tract pressure gradient, interventricular septal thickness, and degree of mitral regurgitation significantly decreased after surgery. During follow-up, 3 SCD were noted. The overall survival rates at follow-up were 100% at 1 year and 96.5% at 3 years. The overall survival rates free from reoperation were 99.1% at 1 year and 98.0% at 3 years. They indicated that biventricular obstruction, myocardial bridging, and ventricular anatomic abnormalities were common phenotypic components in the cohort of children with hypertrophic obstructive cardiomyopathy undergoing septectomy. Altarabheh et al.<sup>38</sup> reported the maximum number of children with hypertrophic obstructive cardiomyopathy who received septectomy between 1975 and 2010 (n = 127). The overall 5, 10, 15, and 20-year survival rates were 98.6%, 94.9%,



92.4%, and 92.4%. The survival rates free from reoperation were 91.2%, 87.8%, 78.7%, and 72.7%. The injury rate of aortic valve was 5.5%. If subaortic stenosis in children with hypertrophic obstructive cardiomyopathy is caused by aortic valve injury or aortic valve dysplasia, then classic or modified Konno operation is required. Tabatabaie et al. reported their experience in performing classic Konno operation for diffuse subaortic stenosis.<sup>39</sup> Their average age was  $12.8 \pm 7$  years. The left ventricular outflow tract pressure gradient decreased from  $91.3 \pm 39.3$  mmHg before operation to  $28.1 \pm 17.7$  mmHg after operation. The early mortality rate was 11.5%. In the other 23 patients, there was no late mortality. For children with hypertrophic obstructive cardiomyopathy without aortic valve or supravalvular stenosis, modified Konno operation may be a suitable choice. Mikael Laredo et al.<sup>40</sup> evaluated the results of their institution's use of modified Konno operation for children with hypertrophic obstructive cardiomyopathy. A total of 79 consecutive children who underwent the modified Konno operation in their centre between 1991 and 2016 were included. Clinical features included age less than 5 years (38%), maximal septal thickness 25 mm or more (32%), extension to the left ventricular apex (29%), and right ventricular outflow tract obstruction (28%). In total, 25% of patients had Noonan syndrome. Five children (6%) aged less than 15 months with Noonan syndrome and biventricular obstruction died in the hospital. Five children (6%) aged less than 15 months with Noonan syndrome and biventricular obstruction died in the hospital. Survival without death and heart transplantation was 82% at 20 years. Atrioventricular block occurred in 9 patients (11%) and was associated with right ventricular outflow tract obstruction and surgery before 2010. Death, sudden death, and appropriate implantable defibrillator were associated with preoperative maximal septal thickness and need for concomitant procedures. There was no case of recurrent obstruction. Reoperation was required in 4 patients (5%) for other reasons. They indicated that the modified Konno operation provided lasting obstructive relief and good long-term survival for children with severe hypertrophic obstructive cardiomyopathy.

In addition, Ross-Konno operation has become one of the main surgical methods to treat children with congenital left ventricular outflow tract obstruction due to its good haemodynamic characteristics, growth potential, and the advantages of no anticoagulation treatment. Especially for Hypertrophic obstructive cardiomyopathy children or adolescents with aortic valve disease who cannot perform aortic valvoplasty or valve replacement, sometimes it becomes the only choice. Ruzmetov et al.<sup>40</sup> reported that the early and late mortality of Ross-Konno operation was significantly higher than that of Ross operation. Sames Dolzer et al.<sup>41</sup> reported the Ross-Konno operation on 44 children < 3 months of age, 35 of whom were neonates, with an operative mortality of 7% and late mortality of 2%. The average follow-up time was 5.9 years. There was no case of reoperation of left ventricular outflow tract. The medium and long-term results were satisfactory. Aszyk et al.<sup>42</sup> reported 16 infants undergoing Ross-Konno operation, with a median age of 4.2 months and a 5-year actual survival rate of 93%. However, the incidence of early complications was high. The long-term disadvantage of Ross-Konno operation is that it turns the problem of one valve into the problem of two valves. Both the new aortic valve and pulmonary valve face long-term failure and re-intervention. Therefore, its clinical application has been controversial. Schneider et al.<sup>43</sup> reported the follow-up results of 155 cases of Ross Konno for 22 years after operation, which showed that the survival rate of Ross group and Ross-Konno group reached 91 and 86% respectively

20 years after operation, and the rate of free from aortic valve re-intervention was 70%. Lo Rito et al.<sup>44</sup> reported the long-term results of Ross-Konno operation in a group of children with less than 18 months of age, which showed that the long-term risk of avoiding aortic root dilation and aortic regurgitation in children less than 18 months of age was significantly lower than that in older children, suggesting that the pulmonary valve remodelling potential of younger children could be better than that of older children.

#### *Minimally invasive surgery*

The median sternal incision, as a common surgical approach for the treatment of cardiovascular diseases, can effectively complete the septectomy, but it has a large surgical trauma and a poor aesthetic incision, which brings great mental burden to patients. In recent years, with the development of minimally invasive surgery technology, right mini-thoracotomy is increasingly applied to the surgical treatment of cardiovascular diseases. The literature on the right mini-thoracotomy for the correction of hypertrophic obstructive cardiomyopathy in adults has been published. The report on the right anterolateral mini-thoracotomy for the correction of hypertrophic obstructive cardiomyopathy in children is rare, most of which are about the experience of the right mini-thoracotomy for the correction of congenital heart disease. Jiang Zhaolei et al.<sup>30</sup> treated hypertrophic obstructive cardiomyopathy with mitral regurgitation with modified extended Morrow operation and "edge to edge" mitral valvuloplasty via right mini-thoracotomy incision to treat 54 patients with hypertrophic obstructive cardiomyopathy complicated with moderate or above mitral regurgitation. All patients were complicated with systolic anterior motion before operation. Before operation, the left ventricular outflow tract pressure gradient was ( $93.6 \pm 32.8$ ) mmHg, and the mean ventricular septal thickness was ( $24.8 \pm 2.8$ ) mm. All patients successfully completed the operation. There were no death cases, no conversion to median sternal incision, and no ventricular septal perforation during the perioperative period. Before discharge, re-examination of transthoracic echocardiography showed that the left ventricular outflow tract pressure gradient was ( $18.1 \pm 6.2$ ) mmHg, and the mean ventricular septal thickness was ( $14.5 \pm 2.1$ ) mm, both of which were significantly improved compared with those before operation. The mitral valve was closed well without mitral stenosis and systolic anterior motion. Follow-up for 6–132 months after operation showed that there were no dead cases, no late PPM, and re-examination of transthoracic echocardiography showed that the average left ventricular outflow tract pressure gradient was ( $19.4 \pm 5.7$ ) mmHg, the average ventricular septal thickness was ( $14.2 \pm 1.5$ ) mm, and there was no systolic anterior motion. The right mini-thoracotomy for correction of Hypertrophic obstructive cardiomyopathy may be a choice for older children with Hypertrophic obstructive cardiomyopathy in the future. The incision is smaller and more beautiful. It is noteworthy that with the popularisation of endoscopic technology, tally endoscopic transmitral myectomy seems to be another alternative to minimally invasive surgery. The surgical approach is from the mitral valve, which is minimally invasive and visible. The thoracoscopic wound is beautiful and minimally invasive, which is easy to be accepted by patients. It can shorten the time of cardiopulmonary bypass and aortic clamp, and subsequently shorten the nursing time in the ICU ward as much as possible. Endoscopic instruments are fine and small in size, which are more suitable for operations with narrow space such as heart surgery. The mitral valve approach does not pass through the aortic valve,



causing less damage to the aortic valve leaflet, and reducing surgical complications. RTM is similar to tally endoscopic transmitral myectomy. In 2017, Nai Kuan Chou *et al.*<sup>44</sup> described an RTM approach to resolve ventricular septal hypertrophy and eliminate mitral regurgitation through a cardiac incision and compared the results of this approach with those of the open full-sternotomy approach. They retrospectively analysed 20 adult patients with hypertrophic obstructive cardiomyopathy who exhibited concomitant severe mitral regurgitation and systolic anterior motion. The two groups comprised 12 standard open full-sternotomy approach and eight Robotic transmitral approaches. There was no statistically significant difference in baseline data between the two groups before operation. Mitral regurgitation of all patients decreased to below grade II after operation. Compared with Open full-sternotomy approach group, the left ventricular outflow tract obstruction in Robotic transmitral approaches group was relieved more completely after operation. The operation time is shorter. Using an Robotic transmitral approaches approach to treat patients with hypertrophic obstructive cardiomyopathy is feasible. Through 1 atrial incision, it is possible to resolve hypertrophy of the septum and eliminate both severe mitral regurgitation and systolic anterior motion. Robotic transmitral approaches and tally endoscopic transmitral myectomy have similar advantages, such as minimally invasive visualization, beautiful incision, and more conducive to teaching. Such minimally invasive operation has been applied to adult hypertrophic obstructive cardiomyopathy patients and has achieved considerable results. It is also a new operation that can be selected by older hypertrophic obstructive cardiomyopathy children in the future.

#### *Off-pump beating-heart surgery*

It is worth noting that Jing Fang *et al.*<sup>45</sup> have recently invented a new operation, transapical beating-heart septectomy, which subverts all previous operations assisted by cardiopulmonary bypass. Transapical beating-heart septectomy is a safe and effective minimally invasive method for surgical reduction of heterogeneous hypertrophic obstructive cardiomyopathy. Compared with traditional septectomy, transapical beating-heart septectomy has better visibility and less surgical trauma. The septectomy can be seen in the geometric cross section of the left ventricle realised by real-time echocardiography, eliminating the necessity of sternotomy and aortotomy. During the whole operation, the stability of haemodynamics can be well maintained without using cardiopulmonary bypass. Under the guidance of real-time echo, repeated resection can be easily performed to adjust the scope of resection of septal myoma and fully eliminate left ventricular outflow tract obstruction and mitral regurgitation. Of the 47 patients enrolled, 89.4% achieved surgical success, which was defined by the resting/stimulating left ventricular outflow tract pressure gradient. Compared with the traditional septectomy, transapical beating-heart septectomy has the advantages of minimally invasive off-pump approach with accurate navigation and real-time echo monitoring and evaluation during the operation. The efficiency has been significantly improved and revolutionary progress has been made. Importantly, transapical beating-heart septectomy seems to apply to all morphological subtypes of hypertrophic obstructive cardiomyopathy, with low technical requirements and easy dissemination. In their cohort, there were two children aged 12–18 years with good prognosis, indicating that the operation method was also applicable to older hypertrophic obstructive cardiomyopathy children.

#### **Conclusion**

The natural prognosis of children with severe hypertrophic obstructive cardiomyopathy is not optimistic, and it is not uncommon for children with hypertrophic obstructive cardiomyopathy who do not respond to medication. There are few relevant reports and large-scale clinical experience in the surgical treatment of paediatric patients with ablation. For such children, surgical treatment is often the only solution. Conventional surgical methods in the past include classic or modified extended Morrow operation, classic or modified Konno operation, and Ross-Konno operation. In recent years, with the development of minimally invasive surgery, various minimally invasive surgical methods have emerged endlessly. Because the incision is significantly smaller than the traditional, minimally invasive cardiac surgery has less trauma, recovers quickly after surgery, and has the advantage of no difference in surgical effect compared with median sternotomy. Tally endoscopic transmitral myectomy, Robotic transmitral approaches, and right mini-thoracotomy have achieved encouraging results in adult hypertrophic obstructive cardiomyopathy and some older hypertrophic obstructive cardiomyopathy children. The appearance of Transapical beating-heart septectomy has brought the treatment of hypertrophic obstructive cardiomyopathy from the era of cardiopulmonary bypass and cardiac arrest to the new era of minimally invasive beating-heart surgery, avoiding the shortcomings brought by cardiopulmonary bypass. In the future, transapical beating-heart septectomy may be the new standard for the treatment of children with hypertrophic obstructive cardiomyopathy.

**Data availability statement.** The data that support the findings of this study are available from the first author upon reasonable request.

**Acknowledgements.** We acknowledge the roles of our colleagues, perfusionists, nurses, and others involved in the care of the study participants.

**Author contribution.** Zhangwei Wang: Conceptualisation; Data curation; Formal analysis; Investigation; Methodology; Software; Validation; Visualisation; Writing—original draft. Kai Ma, Yaobin Zhu, Shoujun Li: Writing—review & editing.

**Financial support.** None.

**Competing interests.** None.

**Ethical standard.** All procedures performed in studies involving human participants were in accordance with the ethical standards of the institutional and national research committee and with the 1964 Helsinki Declaration and its later amendments or comparable ethical standards.

#### **References**

1. Maron BJ, Maron MS. Hypertrophic cardiomyopathy. *Lancet* 2013; 381: 242–255.
2. Colan SD, Lipshultz SE, Lowe AM, *et al.* Epidemiology and cause-specific outcome of hypertrophic cardiomyopathy in children: findings from the pediatric cardiomyopathy registry. *Circulation* 2007; 115: 773–781.
3. Pahl E, Sleeper LA, Canter CE, *et al.* Incidence of and risk factors for sudden cardiac death in children with dilated cardiomyopathy: a report from the pediatric cardiomyopathy registry. *J Am Coll Cardiol* 2012; 59: 607–615.
4. Zhu C, Wang S, Ma Y, *et al.* Childhood hypertrophic obstructive cardiomyopathy and its relevant surgical outcome. *Ann Thorac Surg* 2020; 110: 207–213.
5. Mori H, Yoshikawa T, Kimura H, *et al.* Outcomes of hypertrophic cardiomyopathy in Japanese children: a retrospective cohort study. *Heart Vessels* 2022; 37: 1075–1084.

6. Borisov KV, Bockeria LA, Sinyov AF. Surgical treatment of hypertrophic obstructive cardiomyopathy in pediatric patients with severe hypertrophy. *Artif Organs* 2008; 32: 856–863.
7. Alexander P, Nugent AW, Daubeney P, et al. Long-term outcomes of hypertrophic cardiomyopathy diagnosed during childhood: results from a national population-based study. *Circulation* 2018; 138: 29–36.
8. Teare RD. Obstructive cardiomyopathy: pathology. *Proc R Soc Med* 1964; 57: 445–446.
9. Braunwald E, Lambrew CT, Rockoff SD, Ross JJ, Morrow AG. Idiopathic hypertrophic subaortic stenosis. I. A description of the disease based upon an analysis of 64 patients. *Circulation* 1964; 30: 3–4.
10. Goodwin JF. Cardiac function in primary myocardial disorders. I. *Br Med J* 1964; 1: 1527–1533.
11. Trimble AS, Bigelow WG, Wigle ED, Chrysohou A. Simple and effective surgical approach to muscular subaortic stenosis. *Circulation* 1964; 29: 125–129.
12. Morrow AG, Reitz BA, Epstein SE, et al. Operative treatment in hypertrophic subaortic stenosis. Techniques, and the results of pre and postoperative assessments in 83 patients. *Circulation* 1975; 52: 88–102.
13. Cooley DA, Wukasch DC, Leachman RD. Mitral valve replacement for idiopathic hypertrophic subaortic stenosis. Results in 27 patients. *J Cardiovasc Surg (Torino)* 1976; 17: 380–387.
14. Jarcho JA, McKenna W, Pare JA, et al. Mapping a gene for familial hypertrophic cardiomyopathy to chromosome 14q1. *N Engl J Med* 1989; 321: 1372–1378.
15. Tanigawa G, Jarcho JA, Kass S, et al. A molecular basis for familial hypertrophic cardiomyopathy: an alpha/beta cardiac myosin heavy chain hybrid gene. *Cell* 1990; 62: 991–998.
16. Kotkar KD, Said SM, Dearani JA, Schaff HV. Hypertrophic obstructive cardiomyopathy. The Mayo Clinic experience. *Ann Cardiothorac Surg* 2017; 6: 329–336.
17. Yacoub MH, Afifi A, Saad H, Aguib H, ElGuindy A. Current state of the art and future of myectomy. *Ann Cardiothorac Surg* 2017; 6: 307–317.
18. Sun D, Schaff HV, Nishimura RA, Geske JB, Dearani JA, Ommen SR. Transapical ventricular remodeling for hypertrophic cardiomyopathy with systolic cavity obliteration. *Ann Thorac Surg* 2022; 114: 1284–1289.
19. Sun D, Schaff HV, Nishimura RA, Geske JB, Dearani JA, Ommen SR. Transapical septal myectomy for hypertrophic cardiomyopathy with midventricular obstruction. *Ann Thorac Surg* 2021; 111: 836–844.
20. Laredo M, Khraiche D, Raisy O, et al. Long-term results of the modified Konno procedure in high-risk children with obstructive hypertrophic cardiomyopathy. *J Thorac Cardiovasc Surg* 2018; 156: 2285–2294.e2.
21. Luxford JC, Ayer JG, Betts K, et al. The Ross/Ross-Konno procedure in infancy is a safe and durable solution for aortic stenosis. *J Thorac Cardiovasc Surg* 2022; 163: 365–375.
22. Swistel DG, Balaran SK. Surgical myectomy for hypertrophic cardiomyopathy in the 21st century, the evolution of the “RPR” repair: resection, plication, and release. *Prog Cardiovasc Dis* 2012; 54: 498–502.
23. Ibrahim M, Rao C, Ashrafian H, Chaudhry U, Darzi A, Athanasiou T. Modern management of systolic anterior motion of the mitral valve. *Eur J Cardiothorac Surg* 2012; 41: 1260–1270.
24. Ferrazzi P, Spirito P, Iacovoni A, et al. Transaortic chordal cutting: mitral valve repair for obstructive hypertrophic cardiomyopathy with mild septal hypertrophy. *J Am Coll Cardiol* 2015; 66: 1687–1696.
25. Ram E, Schwammenthal E, Kuperstein R, et al. Secondary chordal resection with septal myectomy for treatment of symptomatic obstructive hypertrophic cardiomyopathy. *Eur J Cardiothorac Surg* 2021; 60: 699–707.
26. Varghese R, Itagaki S, Anyanwu AC, Trigo P, Fischer G, Adams DH. Predicting systolic anterior motion after mitral valve reconstruction: using intraoperative transoesophageal echocardiography to identify those at greatest risk. *Eur J Cardiothorac Surg* 2014; 45: 132–138.
27. Chou NK, Okano R, Tedoriya T, et al. Robotic transmitral approach for hypertrophic cardiomyopathy with systolic anterior motion. *Circ J* 2018; 82: 2761–2766.
28. van der Merwe J, Casselman F, Van Praet F. Endoscopic port access(TM) left ventricle outflow tract resection and atrioventricular valve surgery. *J Vis Surg* 2018; 4: 100.
29. Lawrance CP, Henn MC, Miller JR, et al. A minimally invasive Cox maze IV procedure is as effective as sternotomy while decreasing major morbidity and hospital stay. *J Thorac Cardiovasc Surg* 2014; 148: 955–962.
30. Jiang Z, M. J, Tang M, et al. Surgical treatment for hypertrophic obstructive cardiomyopathy with moderate-to-severe mitral regurgitation through right mini-thoracotomy. *Chin J Clin Thorac Cardiovasc Surg* 2020; 27: 754–757.
31. Wang Z, Ding N, Yi H, et al. Application of sutureless technique in total anomalous pulmonary venous connection repair. *J Card Surg* 2022; 37: 3769–3775.
32. Fang J, Wang R, Liu H, et al. Transapical septal myectomy in the beating heart via a minimally invasive approach: a feasibility study in swine. *Interact Cardiovasc Thorac Surg* 2020; 30: 303–311.
33. Yan J, Duan Y. Surgical treatment for hypertrophic cardiomyopathy in children. *Chin J Pract Pediatr* 2019; 34: 371–374.
34. Haider M, Carlson L, Liu H, Baird C, Mayer JE, Nathan M. Management of complex left ventricular outflow tract obstruction. A comparison of konno and modified konno techniques. *Pediatr Cardiol* 2021; 42: 614–627.
35. Chen Z, Liu J, Tang Y, et al. Totally endoscopic transmitral myectomy and traditional thoracotomy for hypertrophic obstructive cardiomyopathy: a propensity score matching analysis. *Chin J Clin Thorac Cardiovasc Surg* 2021; 28: 656–662.
36. Nugent AW, Daubeney PE, Chondros P, et al. Clinical features and outcomes of childhood hypertrophic cardiomyopathy: results from a national population-based study. *Circulation* 2005; 112: 1332–1338.
37. Tsuda E, Ito Y, Kato Y, Sakaguchi H, Ohuchi H, Kurosaki K. Thirty-year outcome in children with hypertrophic cardiomyopathy based on the type. *J Cardiol* 2022; 80: 557–562.
38. Altarabsheh SE, Dearani JA, Burkhart HM, et al. Outcome of septal myectomy for obstructive hypertrophic cardiomyopathy in children and young adults. *Ann Thorac Surg* 2013; 95: 663–669, 669.
39. Tabatabaie MB, Ghavidel AA, Yousefnia MA, Hoseini S, Javadpour SH, Raesi K. Classic Konno-Rastan procedure: indications and results in the current era. *Asian Cardiovasc Thorac Ann* 2006; 14: 377–381.
40. Ruzmetov M, Geiss DM, Shah JJ, Buckley K, Fortuna RS. The Ross-Konno is a high-risk procedure when compared with the Ross operation in children. *Ann Thorac Surg* 2013; 95: 670–675.
41. Sames-Dolzer E, Wickenhauser E, Kreuzer M, et al. The Ross-Konno procedure in neonates and infants less than 3 months of age. *Eur J Cardiothorac Surg* 2018; 54: 71–77.
42. Aszyk P, Thiel C, Sinzobahamya N, et al. Ross-Konno procedure in infants: mid-term results. *Eur J Cardiothorac Surg* 2012; 42: 687–694.
43. Schneider AW, Bokenkamp R, Bruggemans EF, Hazekamp MG. Twenty-year experience with the Ross-Konno procedure. *Eur J Cardiothorac Surg* 2016; 49: 1564–1570.
44. Lo RM, Davies B, Brawn WJ, et al. Comparison of the Ross/Ross-Konno aortic root in children before and after the age of 18 months. *Eur J Cardiothorac Surg* 2014; 46: 450–457, 457.
45. Fang J, Liu Y, Zhu Y, et al. First-in-human transapical beating-heart septal myectomy in patients with hypertrophic obstructive cardiomyopathy. *J Am Coll Cardiol* 2023; 82: 575–586. DOI: [10.1016/j.jacc.2023.05.052](https://doi.org/10.1016/j.jacc.2023.05.052).